

High-Risk BCC Of the Lower Eyelid in Patient with Presternal Located Cutaneous Melanoma and BCC Of the Shoulder: Melolabial Advancement Flap Combined with Undermining Surgical Approach As Promising Complex One Step Treatment Option!

Georgi Tchernev^{1,2*}, Ilija Lozev³, Ivan Pidakev³, Irina Yungareva¹, Tanya Naskova-Popova⁴, Ivanka Temelkova¹

¹Medical Institute of Ministry of Interior (MVR), Department of Dermatology, Venereology and Dermatologic Surgery, General Skobelev Nr 79, Sofia, Bulgaria; ²Onkoderma - Polyclinic for Dermatology and Dermatologic Surgery, General Skobelev 26, Sofia, Bulgaria; ³Medical Institute of the Ministry of Interior, Surgery, Sofia, Bulgaria; ⁴Department of Clinical Hematology University Multiprofile Hospital for Active Treatment "Sveti Ivan Rilski", 15, Acad. Ivan Geshov Blvd., Sofia 1431, Bulgaria

Abstract

Citation: Tchernev G, Lozev I, Pidakev I, Yungareva I, Naskova-Popova T, Temelkova I. High-Risk BCC Of the Lower Eyelid in Patient with Presternal Located Cutaneous Melanoma and BCC Of the Shoulder: Melolabial Advancement Flap Combined with Undermining Surgical Approach As Promising Complex One Step Treatment Option! Open Access Maced J Med Sci. <https://doi.org/10.3889/oamjms.2018.408>

Keywords: Melanoma; High risk BCC; Collision tumours; Melolabial flap

***Correspondence:** Georgi Tchernev, Medical Institute of Ministry of Interior (MVR), Department of Dermatology, Venereology and Dermatologic Surgery, General Skobelev Nr 79, Sofia, Bulgaria; Onkoderma-Polyclinic for Dermatology and Dermatologic Surgery, General Skobelev 26, Sofia, Bulgaria. E-mail: georgi_tchernev@yahoo.de

Received: 08-Nov-2018; **Revised:** 13-Nov-2018; **Accepted:** 14-Nov-2018; **Online first:** 21-Nov-2018

Copyright: © 2018 Georgi Tchernev, Ilija Lozev, Ivan Pidakev, Irina Yungareva, Tanya Naskova-Popova, Ivanka Temelkova. This is an open-access article distributed under the terms of the Creative Commons Attribution-NonCommercial 4.0 International License (CC BY-NC 4.0).

Funding: This research did not receive any financial support

Competing Interests: The authors have declared that no competing interests exist

BACKGROUND: It is assumed that the occurrence of keratinocyte and melanocytic tumours is multifactorial driven. Certain risk factors such as solar radiation, p53 protein and Melanocortin-1 receptor (MC1R) prove to be common to their development, which at the same time shows that their simultaneous manifestation in the same patients, for example, is quite possible. Such a manifestation could be observed as collision tumours within the same solitary lesion or as a simultaneous occurrence within two completely different lesions that are clearly distinguished from one another.

CASE REPORT: An 85-year-old patient is presented with three primary cutaneous tumours located in region presternal, infraorbital sinistra and scapularis extra. The lesions were removed during a single surgical session. For the high-risk basal cell carcinoma (BCC) in the lower eyelid, the so-called melolabial advancement flap was applied, and for the tumours located in the other two areas, the undermining surgical approach was applied. The subsequent histological analysis found that the case referred to two keratinocyte tumours (BCC) and one melanocyte tumour (cutaneous melanoma).

CONCLUSIONS: The patient presented is interesting with regard to 1) the simultaneous presentation of three primaries with different localization (so far not described in the world literature, namely 2 basal cell carcinomas and one melanoma in the same patient concurrently), 2) one of the basal cell tumours belongs to the group of high-risk (according to the localization) and meanwhile advanced BCC (according to the infiltration degree of the underlying tissue-infiltration of the musculature) and 3) their simultaneous successful surgical treatment in a single surgical session under local anaesthesia.

Introduction

Solar radiation could be considered a major etiologic/risk factor for the occurrence of basal cell carcinoma and malignant melanoma [1], [2]. The combination of mutations in the p53 gene and UV radiation increases the risk of development of melanoma and non-melanoma skin tumours [3], [4]. There are some regulatory proteins that may prove to

be key but also common for the development of both melanomas and basal cell carcinomas [5], [6] [7], [8].

For example, the p53 protein and Melanocortin-1 receptor (MC1R) are considered as risk factors for both malignant melanoma (MM) and basal cell carcinoma (BCC), as well as for spinocellular carcinoma (SCC) development [5] [6] [9]. These data allow us to conclude that the simultaneous manifestation of melanocytic and keratinocyte cutaneous tumours should be entirely possible [10] [11].

Case report

An 85-year-old patient is presented with some concomitant diseases: arterial hypertension, chronic congestive heart failure, high grade aortic, mitral and tricuspid insufficiency, atrial fibrillation, pulmonary hypertension, cholelithiasis, hiatal hernia, iron deficiency anaemia and idiopathic thrombocytopenia. Treatment with Eltrombopag (25 mg x 1/day) is given with good results for idiopathic thrombocytopenia. The patient was hospitalised for scheduled surgical co-removal of the tumour formations located in the lower eyelid, back and sternum. During the dermatological examination, three lesions of different nature and localisation were identified. In the region pre sternalis a pigimentary lesion with irregular edges, clinically and dermatoscopically suspected for melanoma, was identified (Figure 1d and 1e). In the area, scapularis extra, an exophytic oval tumorous formation with an ulcerative and at the same time heavily bleeding surface, with a diameter of approximately 6-7,8 cm, was additionally noted (Figure 1a). In regio infraorbitalis sinistra, immediately next to the lower eyelid, an exophytic tumorous formation with a centrally located erosive surface covered with hemorrhagic crusts and a slightly raised peripheral edge were observed (Figure 1b and 3a). Surgical removal of the three formations was planned under local anaesthesia within one surgical session. The lesion located in regio presternal, suspected for malignant melanoma, was removed by elliptical excision under local anaesthesia, with a surgical safety margin of 0.5 cm in all directions (Figure 1f). The resulting surgical defect was closed by single interrupted stitches (Figure 1g).

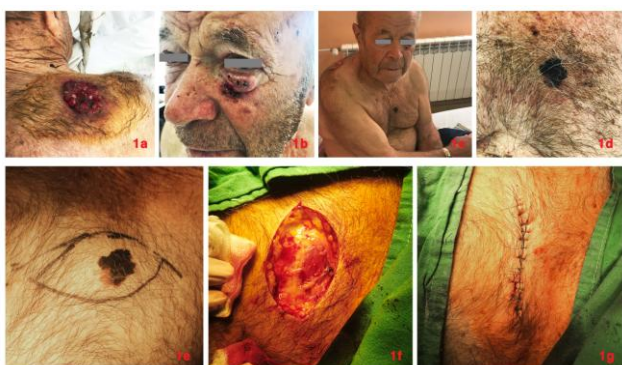

Figure 1: a) Clinical view of the lesion in regio scapularis extra-exophytic oval tumorous formation with ulcerative and at the same time heavily bleeding surface, with a diameter of approximately 7/8 cm; b) Exophytic tumorous formation with a centrally located erosive surface covered with hemorrhagic crusts and a slightly raised peripheral edge in regio infraorbitalis sinistra; c) Simultaneous clinical view of the three lesions during the first dermatological examination; d) Regio pre sternalis-pigmentary lesion with irregular edges; e) Preoperative outlining of the pigmentary lesion surgical margins; f) Intraoperative finding-elliptical excision of the melanocytic lesion; g) Postoperative view following the removal of the melanocytic lesion-closure of the defect with single interrupted stitches

The histological analysis showed that it was malignant melanoma, superficial progression type, III Clark's level, 2 mm Breslow's thickness, no ulceration, high mitotic activity, abundant lymphocytic infiltration in the stroma, no spontaneous regression, clear resection lines, IB (T2aNxM0) stage.

The lesion localised in regio scapularis extra, suspected for spinocellular carcinoma, was removed by extensive elliptical excision under local anaesthesia (Figures 2b, 2c and 2d). This was followed by careful dissection of the subcutaneous tissue to the muscles in all directions to a better adaptation of the wound edges (Figure 2e). The resulting surgical defect was recovered by stretch plastics (Figure 2f). The histological analysis found that it was a basal cell carcinoma with clear resection lines, I stage. The tumour formation in the area of regio infraorbitalis sinistra, which was the cause of hospitalisation and suspected for basal cell carcinoma, was surgically removed in stages by melolabial advancement plastics.

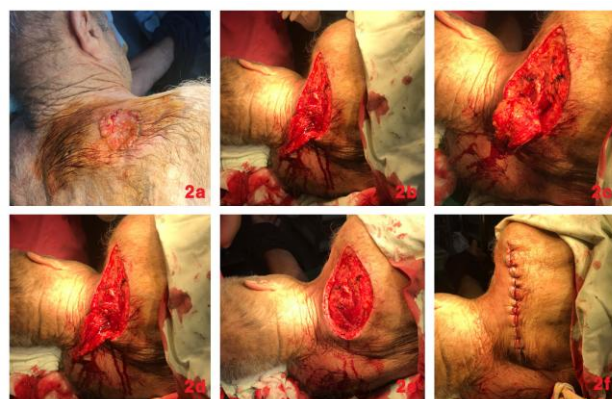


Figure 2: a) Preoperative view of the lesion in the shoulder area-disinfection; b), c), d) and e) Intraoperative view-elliptical excision of the exophytic lesion in regio scapularis extra; f) Postoperative closure of the surgical defect by stretch plastics and single interrupted stitches

The lesion was initially contoured with a surgical safety margin of 0.2-0.3 cm medially to the nose, laterally to the ear and caudally to the upper lip, and cranially due to the proximity to the lower eyelid, with a distance of approximately 0.1 cm (Figure 3a). In the second stage, the lesion was excised in the form of a quadrangle with oval edges, and a small part of the underlying muscle was also removed (Figure 3b and 3c). After stopping the bleeding, the skin integrity in the area of the resulting skin defect was restored by a melolabial advancement flap. Expansion of the defect was initiated by conducting an initial single oblong incision parallel to the melolabial fold, followed by skin erosion laterally to the incision and finally transposition of the skin upward using slight rotation (Figure 3d). The transposition flap was carefully adapted to the edge of the lower eyelid by single subcutaneous stitches, and then by skin stitches (Figure 3e and 3f). Histological verification showed

that it was an advanced high-risk basal cell carcinoma with clear resection lines, II stage.

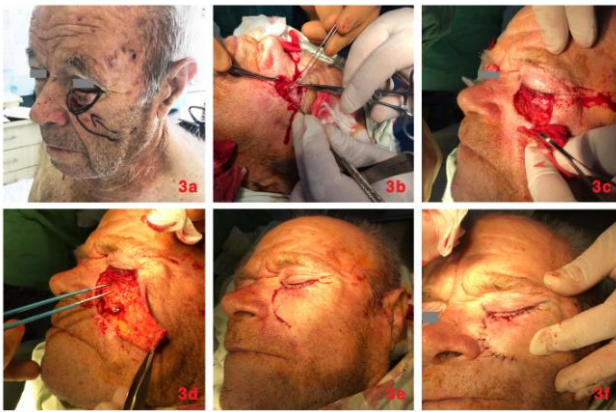

Figure 3: a) Preoperative outlining of the safety surgical margins; b), c) Oval excision of the lesion located in regio infraorbitalis sinistra; d) Intraoperative finding-stopping the bleeding by electrocautery; e) Postoperative view after the melolabial advancement flap; d) Clinical postoperative status-single interrupted stitches

At the time of the surgical intervention, there was no apparatus or laboratory evidence of progression of both melanoma and the keratinocyte tumours.

About the histologically established melanoma, it was recommended to perform a re-excision with safety surgical margin of 1.5 cm within 14 days, and detect the draining lymph node within the same surgical session.

Discussion

About the BCC and MM occurrence, UV radiation is referred to as an exogenous etiological factor of paramount importance [1], [2]. In turn, a large number of regulatory proteins are considered to be the key endogenous factors in the pathogenesis of melanoma and non-melanoma skin tumours [5], [6], [7], [8]. P53 protein and Melanocortin-1 receptor (MC1R) are identified as risk factors for the development of malignant melanoma (MM), basal cell carcinomas (BCC) and spinocellular carcinomas (SCC) [5], [6], [9]. P53 gene mutations lead to overproduction of long-life mutant forms of p53 protein, which in combination with the additional influence of sunlight significantly increases the risk of developing BCC and malignant melanoma [3], [4]. Similar dependence is seen with combined UV radiation and various gene variants of the Melanocortin-1 receptor (MC1R) [5], [6]. These common risk factors and mechanisms in the genesis of melanocytic and keratinocyte tumors suggest their possible simultaneous presentation in the same

patient [1], [2], [3], [4], [5], [6], [7], [8], [9], [10], [11], [12].

The simultaneous manifestation of melanocyte and keratinocyte skin tumours may be seen in the form of the so-called 1) collision tumours – when they are established within the same lesion (clinically, dermatoscopically and/or histologically) and 2) simultaneous occurrence of two or more histologically distinct primary malignancies [12], [13]. The presence of two different malignant tumours at the same time, located within the same histological sample, is referred to as the so-called collision tumours [14], [15]. However, depending on the boundaries between cells, the simultaneous manifestation of two histologically distinct tumours is subdivided into two types: 1) collision type, in which each cellular type is distinct, and 2) intermingled type, in which the two cell types are “intimately related” [16]. The predominant number of documented cases in the world literature represents the BCC and MM combination [12], [14], [15], [16]. In this respect, their correlation is interesting, defined as parasitism, i.e. BCC colonization by MM [14], [17], [18], [19]. A two-phase and three-phase manifestation in the form of a squamomelanocytic tumour, basomelanocytic tumour or basosquamous melanocytic malignant tumour [20], [21], [22] is also possible, though relatively rare. Even in the form of a collision tumour, the ability of the malignant melanoma to provide metastasis is retained [15], [23]. In some cases, metastasis may manifest as blue nevi, thus simulating the clinical picture of a benign lesion [15]. All possible options of coexistence between melanocytic and keratinocyte tumours are most safely demonstrated histopathologically and immunohistochemically [15], [18], [20], [21].

Unlike collisional tumours, the simultaneous occurrence of two different primary histological carcinoma types is extremely rare [10], [11]. To our knowledge, we present for the first time in the world literature a unique case of a patient with simultaneous occurrence of three primary cutaneous tumours with different localisation – two keratinocyte tumours (2 basal cell carcinomas) in combination with presteral localised superficial melanoma.

Two cases of patients with BCC, SCC and MM have been documented in the world literature [10], [11]. In one case, the data simultaneously manifests the three types of tumours [10], and the other described case refers to a patient with metastatic melanoma in combination with 2 keratinocyte tumours (BCC and SCC with different localisation) [11].

Patients with BCC, MM, SCC are at increased risk of development of subsequent cutaneous tumours of the same or another type [24], [25], [26]. Cutaneous melanoma diagnosis is considered a risk of developing multiple cutaneous (pre-) malignancies [25]. Patients with BCC may subsequently develop other forms of cancer, such as testicular cancer,

breast cancer, and non-Hodgkin lymphoma [27]. This requires their regular analysis (clinical and apparatus diagnostic procedures in the framework of selected screening programs).

Basal cell carcinomas located in the so-called H-zone of the face (nasolabial fold, nasal alar, orbital area and auricular area, are considered to be high risk regarding the occurrence of possible recurrence [28].

High-risk cases substantially include long-term tumors (not defined), localized midface/ear (basalioma adjacent to the lower eyelid/this criterion is met in our patient), diameter over 2 cm (basalioma in proximity to the lower eyelid/this criterion is met in our patient also), aggressive histological subtypes, perivascular/perineural infiltration, prior radiation therapy or other types of treatment failure [29]. Advanced BCCs are defined as III stage (with musculature infiltration, as described in our patient) or IV stage tumours, and when their size is more than 5 cm, they are classified as giant BCC [29]. There is often a criteria overlap between the high-risk and advanced BCCs, as well as failure of the lesion to meet all the requirements specified in the definitions.

Both types often require the application of more sophisticated surgical techniques [28], [30].

In conclusion, concomitant surgical treatment of risk basal cell carcinoma with facial muscular infiltration combined with cutaneous melanoma of presternal localisation and additional resection of basal cell carcinoma on the shoulder is a serious challenge for most of the dermatosurgeons. We at this moment inform for the first time in the world literature about the simultaneous diagnosis of 2 keratinocyte and one melanocytic tumour in the form of primaries with different localisation, as well as their successful surgical treatment within one surgical session.

References

- Rosso S, Zanetti R, Pippione M, Sancho-Garnier H. Parallel risk assessment of melanoma and basal cell carcinoma: skin characteristics and sun exposure. *Melanoma Res.* 1998; 8(6):573-83. <https://doi.org/10.1097/00008390-199812000-00013> PMID:9918420
- Armstrong B, Kricger A. The epidemiology of UV induced skin cancer. *J Photochem Photobiol B.* 2001; 63(1-3):8-18. [https://doi.org/10.1016/S1011-1344\(01\)00198-1](https://doi.org/10.1016/S1011-1344(01)00198-1)
- Giglia-Mari G, Sarasin A. TP53 mutations in human skin cancers. *Hum Mutat.* 2003; 21(3):217-28. <https://doi.org/10.1002/humu.10179> PMID:12619107
- Shea C, McNutt N, Volkenandt M, Lugo J, Prioleau P, Albino A. Overexpression of p53 protein in basal cell carcinomas of human skin. *Am J Pathol.* 1992; 141(1):25-29. PMID:1632467 PMID:PMC1886589
- Box N, Duffy D, Irving R, Russell A, Chen W, Griffyths L, Parsons P, Green A, Sturm R. Melanocortin-1 receptor genotype is a risk factor for basal and squamous cell carcinoma. *J Invest Dermatol.* 2001; 116(2):224-9. <https://doi.org/10.1046/j.1523-1747.2001.01224.x> PMID:11179997
- Kennedy C, ter Huurne J, Berkhouit M, Gruis N, Bastiaens M, Bergman W, Willemze R, Bavinck J. Melanocortin 1 receptor (MC1R) gene variants are associated with an increased risk for cutaneous melanoma which is largely independent of skin type and hair color. *J Invest Dermatol.* 2001; 117(2):294-300. <https://doi.org/10.1046/j.0022-202x.2001.01421.x> PMID:11511307
- Tchernev G, Orfanos CE. Downregulation of cell cycle modulators p21, p27, p53, Rb and proapoptotic Bcl-2-related proteins Bax and Bak in cutaneous melanoma is associated with worse patient prognosis: preliminary findings. *J Cutan Pathol.* 2007; 34(3):247-56. <https://doi.org/10.1111/j.1600-0560.2006.00700.x> PMID:17302609
- Fecker LF, Geilen CC, Tchernev G, Trefzer U, Assaf C, Kurbanov BM, Schwarz C, Daniel PT, Eberle J. Loss of proapoptotic Bcl-2-related multidomain proteins in primary melanomas is associated with poor prognosis. *J Invest Dermatol.* 2006; 126(6):1366-71. <https://doi.org/10.1038/sj.jid.5700192> PMID:16528364
- Koseoglu RD, Sezer E, Eyibilen A, Aladag I, Etikan I. Expressions of p53, cyclinD1 and histopathological features in basal cell carcinomas. *J Cutan Pathol.* 2009; 36(9):958-65. <https://doi.org/10.1111/j.1600-0560.2009.01204.x> PMID:19187116
- Hagedorn M, RuBwurm R, Sommer B, Thomas C. Simultaneous Occurrence Of A Basal Cell Carcinoma, Squamous Cell Carcinoma And Malignant Melanoma In A Patient. *The American Journal of Dermatopathology.* 1994; 16(1):101. <https://doi.org/10.1097/00000372-199402000-00043>
- Grampurohit V, Dinesh U, Rao R. Multiple cutaneous malignancies in a patient of xeroderma pigmentosum. *J Cancer Res Ther.* 2011; 7(2):205-7. <https://doi.org/10.4103/0973-1482.82932> PMID:21768716
- Medeiros P, Alves N, Silva C, Faria P, Barcaui C, Pi-eiro-Maceira J. Collision of malignant neoplasms of the skin: basosquamous cell carcinoma associated with melanoma. *An Bras Dermatol.* 2015; 90(3 Suppl 1):39-42. <https://doi.org/10.1590/abd1806-4841.20153845> PMID:26312670 PMID:PMC4540504
- Nakahara H, Kitamura R, Shirasuna K. Simultaneous malignant melanoma and squamous cell carcinoma of the oral cavity: a case report. *J Oral Maxillofac Surg.* 1995; 53(12):1455-7. [https://doi.org/10.1016/0278-2391\(95\)90676-2](https://doi.org/10.1016/0278-2391(95)90676-2)
- Mancebo S, Marchetti M, Hollmann T, Marghoob A, Busam K, Halpern A. Melanoma in situ colonizing basal cell carcinoma: a case report and review of the literature. *Dermatol Pract Concept.* 2015; 5(1):25-30. <https://doi.org/10.5826/dpc.0501a04> PMID:25692077 PMID:PMC4325687
- King R, Lyons J, Meyers A, Googe P, Page R, Gupta V. Primary invasive melanoma and basal cell carcinoma (collision tumor) with blue nevus-like cutaneous metastases. *J Cutan Pathol.* 2007; 34(8):629-33. <https://doi.org/10.1111/j.1600-0560.2006.00677.x> PMID:17640233
- Braun-Falco M. Combined malignant melanoma and basal cell carcinoma tumor of the intermingled type. *J Cutan Pathol.* 2007; 34(9):731-5. <https://doi.org/10.1111/j.1600-0560.2006.00703.x> PMID:17696923
- Burkhalter A, White W. Malignant melanoma in situ colonizing basal cell carcinoma. A simulator of invasive melanoma. *Am J Dermatopathol.* 1997; 19(3):303-7. <https://doi.org/10.1097/00000372-199706000-00019> PMID:9185921
- Wang H, Benda P, Piepkorn M. Parasitism of basal cell carcinoma by lentigo maligna melanoma. *J Am Acad Dermatol.* 2003; 48(5 Suppl):S92-4. <https://doi.org/10.1067/mjd.2003.237> PMID:12734489
- Goeser M, Dimaio D. A colonization of basal cell carcinoma by malignant melanoma in situ resembling a malignant basomelanocytic tumor. *Am J Dermatopathol.* 2014; 36(11):e179-82. <https://doi.org/10.1097/DAD.000000000000047> PMID:24752214

20. Miteva M, Herschthal D, Ricotti C. A rare case of a cutaneous squamomelanocytic tumor: revisiting the histogenesis of combined neoplasms. *Am J Dermatopathol.* 2009; 31(6):599–603. <https://doi.org/10.1097/DAD.0b013e3181a88116> PMID:19590411
21. Erickson L, Myers J, Mihm M. Malignant basomelanocytic tumor manifesting as metastatic melanoma. *Am J Surg Pathol.* 2004; 28(10):1393–96. <https://doi.org/10.1097/01.pas.0000135526.19189.31> PMID:15371958
22. Cornejo K, Deng A. Malignant melanoma within squamous cell carcinoma and basal cell carcinoma: is it a combined or collision tumor?—a case report and review of the literature. *Am J Dermatopathol.* 2013; 35(2):226–34. <https://doi.org/10.1097/DAD.0b013e3182545e27> PMID:22588546
23. Sharma S, Agrawal U, Gupta P, Bhatnagar A, Jairajpuri Z. Malignant melanoma and basal cell carcinoma of the face: a rare coexistence. *Ann Saudi Med.* 2013; 33(3):304–6. <https://doi.org/10.5144/0256-4947.2013.304> PMID:23793437 PMID:PMC6078527
24. van der Leest R, Hollestein L, Liu L, Nijsten T, de Vries E. Risks of different skin tumour combinations after a first melanoma, squamous cell carcinoma and basal cell carcinoma in Dutch population-based cohorts: 1989–2009. *J Eur Acad Dermatol Venereol.* 2018; 32(3):382–389. <https://doi.org/10.1111/jdv.14587> PMID:28898461
25. van der Leest R, Flohil S, Arends L, de Vries E, Nijsten T. Risk of subsequent cutaneous malignancy in patients with prior melanoma: a systematic review and meta-analysis. *J Eur Acad Dermatol Venereol.* 2015; 29(6):1053–62. <https://doi.org/10.1111/jdv.12887> PMID:25491923
26. Flohil S, van der Leest R, Arends L, de Vries E, Nijsten T. Risk of subsequent cutaneous malignancy in patients with prior keratinocyte carcinoma: a systematic review and meta-analysis. *Eur J Cancer.* 2013; 49(10):2365–75. <https://doi.org/10.1016/j.ejca.2013.03.010> PMID:23608733
27. Frisch M, Hjalgrim H, Olsen J, Melbye M. Risk for subsequent cancer after diagnosis of basal-cell carcinoma. A population-based, epidemiologic study. *Ann Intern Med.* 1996; 125(10):815–21. <https://doi.org/10.7326/0003-4819-125-10-199611150-00005> PMID:8928988
28. Yalcin O, Sezer E, Kabukcuoglu F, Kilic A, Sari A, Cerman A, Altunay I. Presence of ulceration, but not high risk zone location, correlates with unfavorable histopathological subtype in facial basal cell carcinoma. *Int J Clin Exp Pathol.* 2015; 8(11):15448–15453. PMID:26823913 PMID:PMC4713699
29. Wollina U, Steinbach F, Verma S, Tchernev G. Penile tumours: a review. *Journal of the European Academy of Dermatology and Venereology.* 2014; 28(10):1267–76. <https://doi.org/10.1111/jdv.12491> PMID:24684236
30. Choi J, Kim Y, Kim H, Nam S, Woong Y. Distribution of Basal Cell Carcinoma and Squamous Cell Carcinoma by Facial Esthetic Unit. *Arch Plast Surg.* 2013; 40(4):387–391. <https://doi.org/10.5999/aps.2013.40.4.387> PMID:23898436 PMID:PMC3724000