

Endovascular Treatment of Wide Neck Aneurysms

Menka Lazareska^{1*}, Vjolca Aliji¹, Elizabeta Stojovska-Jovanovska¹, Jasna Businovska², Vladimir Mircevski³, Milenko Kostov³, Marija Papazova⁴

¹University Institute of Radiology, Faculty of Medicine, Ss Cyril and Methodius University of Skopje, Skopje, Republic of Macedonia; ²University Clinic of Anesthesiology, Resuscitation and Intensive Care, Faculty of Medicine, Ss Cyril and Methodius University of Skopje, Skopje, Republic of Macedonia; ³University Clinic of Neurosurgery, Faculty of Medicine, Ss Cyril and Methodius University of Skopje, Skopje, Republic of Macedonia; ⁴Institute of Anatomy, Faculty of Medicine, Ss Cyril and Methodius University of Skopje, Skopje, Republic of Macedonia

Abstract

Citation: Lazareska M, Aliji V, Stojovska-Jovanovska E, Businovska J, Mircevski V, Kostov M, Papazova M. Endovascular Treatment of Wide Neck Aneurysms. Open Access Maced J Med Sci. <https://doi.org/10.3889/oamjms.2018.443>

Keywords: Intracranial aneurysm; Endovascular treatment; Wide neck; Intracranial stent; Flow diverter; Occlusion classification

***Correspondence:** Menka Lazareska. University Institute of Radiology, Faculty of Medicine, Ss Cyril and Methodius University of Skopje, Skopje, Republic of Macedonia. E-mail: mlazareska@gmail.com

Received: 31-Oct-2018; **Revised:** 26-Nov-2018; **Accepted:** 27-Nov-2018; **Online first:** 10-Dec-2018

Copyright: © 2018 Menka Lazareska, Vjolca Aliji, Elizabeta Stojovska-Jovanovska, Jasna Businovska, Vladimir Mircevski, Milenko Kostov, Marija Papazova. This is an open-access article distributed under the terms of the Creative Commons Attribution-NonCommercial 4.0 International License (CC BY-NC 4.0)

Funding: This research did not receive any financial support

Competing Interests: The authors have declared that no competing interests exist

BACKGROUND: An aneurysm is an abnormal focal dilatation of an artery. Most of the unruptured aneurysms are asymptomatic and discovered incidentally or some of them symptomatic with mass effect or nerve palsy, but rupture of aneurysm results in a potentially life-threatening subarachnoid haemorrhage. Aneurysms with wide necks are defined by neck diameters greater than 4 mm or dome-to-neck ratios less than 2 and are the most difficult to treat with the endovascular method.

AIM: This study aimed to analyse the endovascular treatment of intracranial aneurysms with a wide neck.

METHODS: The study population included 37 patients with 46 aneurysms referred to the University Clinic of Radiology in Skopje, the Republic of Macedonia for endovascular treatment during the period January 2013 to May 2018. This study included 24 females and 13 males, ranging in age from 25 to 74 years.

RESULTS: From total 46 treated aneurysms 13 were ruptured and 33 unruptured. Six patients were with multiple aneurysms. In these study complex aneurysms were treated with combined technique, 5 with balloon-assisted coiling, 25 with stent-assisted coiling, 6 stents, 2 with flow diverter assisted coiling, 6 FD and 2 with partial coil filling without assistance device.

CONCLUSION: Aneurysms with wide neck remain a challenge for endovascular treatment. But the development of new techniques and materials in the treatment of aneurysms makes endovascular treatment of intracranial aneurysms safe and feasible.

Introduction

An aneurysm is an abnormal focal dilatation of an artery (derived from the Greek word *aneurýnein*, to dilate) [1]. Most of the unruptured aneurysms are asymptomatic and discovered incidentally but rupture of aneurysm results in a potentially life-threatening subarachnoid haemorrhage (SAH) [2]. Unruptured aneurysms can be symptomatic with the mass effect of the brain or causing hydrocephalus, but usually symptoms of cranial nerves palsy. Originally, open direct surgery was the most common to treat aneurysms by placing a clip across the neck of an aneurysm to eliminate flow from the parent artery into

the aneurysm sac [3]. Endovascular treatment methods offer an alternative method for the treatment of intracranial aneurysms.

Endovascular management of intracranial aneurysms using detachable platinum coils was introduced in 1990 by Guido Guglielmi, an Italian neurosurgeon. Despite advances, however, the treatment of wide-necked aneurysms (aneurysms with a fundus-to-neck ratio less than 2 remains problematic [4].

Endovascular treatment of intracranial aneurysms is associated with lower morbidity and mortality rates compared with traditional microsurgical clipping. However, despite advances in devices and

techniques, aneurysms with wide necks, defined by neck diameters greater than 4 mm or dome-to-neck ratios less than 2, are the most difficult to treat with the endovascular method. In wide-necked intracranial aneurysms, complete coil embolisation is often technically difficult owing to the risks of distal coil migration or coil impingement on the parent vessel [5].

Some techniques and devices can be used in the treatment of wide-necked aneurysms. These include balloon remodelling, use of three-dimensional (3D) coils, combined use of stents and coils, flow diverters, use of intrasaccular flow disruption (like WEB), simultaneous deposition of more than one coil in an aneurysm, intentional partial aneurysm embolisation, and combined extra- and intrasaccular treatment.

So far in the literature, none of the classifications includes the entire spectrum of current endovascular aneurysm treatment, irrespective to treatment technique.

This study aimed to analyse the options and efficiency of different modalities of endovascular treatment of aneurysms with a wide neck.

Material and Methods

The study population included 37 patients with 46 aneurysms, 6 patients were with multiple aneurysms, referred to the University Clinic for Radiology in Skopje, the Republic of Macedonia for endovascular treatment of aneurysms with wide neck during the period January 2013 to January 2018. The group of patients was comprised of 13 men and 24 women, aged 25 to 74 years.

From total treated 46 aneurysms, 16 were ruptured and 30 unruptured. In this study complex aneurysms were treated with combined techniques: 5 with balloon-assisted coiling, 25 with stent-assisted coiling, 6 with a stent, 2 with FD assisted coiling, 6 with FD and 2 with partial coil filling without assistance device.

This study was approved by the Ethics Committee of the Medical Faculty of Ss Cyril and Methodius University of Skopje, Skopje, Republic of Macedonia.

Before the procedure, all patients underwent computed tomography angiography (CTA) or digital subtraction angiography (DSA) for diagnostic evaluation. The morphologic characteristics of an aneurysm were carefully evaluated, including the size of the neck, height, width and length; the diameter and tortuosity of the parent artery; and major branches originating from the aneurysmal neck. The detailed strategies for the endovascular treatment of

aneurysms depended on the angiographic findings.

All therapeutic procedures were performed through the femoral artery under general anaesthesia or conscious sedation.

Femoral access was obtained through a percutaneous femoral artery puncture, the introducer was placed, and the guiding catheter was inserted into the parent vessel. A microcatheter depends on technique one or two or balloon, and microcatheter was advanced over the micro-guidewire into the normal distal artery beyond an aneurysm, by 2 cm and one in the aneurysmal sac.

Systemic heparin was administered in the following manner: a bolus of 3-5000 IU of heparin was administered intravenously at the beginning of the procedure of unruptured aneurysms, and after microcatheter placement into the aneurysms in cases of ruptured aneurysm. An additional 1000 IU bolus of heparin was administered in every hour.

Pre-procedural angiograms were then obtained in orthogonal planes. After the decision was made about the endovascular treatment approach, the aneurysm was treated either with a balloon or stent-assisted treatment. The patients that was planned for a stent or flow diverter were put on double antiplatelet therapy (Clopidogrel 75 mg x 1 and Aspirin protect 100 mg x 1) five days before in unruptured and loading dose one-day pre-procedural in risky of the previously ruptured aneurysm with min 3 x 75 mg Clopidogrel and 300 mg Aspirin. For ruptured if its possible first partial coil is filling with the sac and then in second procedure stenting.

Post-procedure care was done in the intensive care unit with close monitoring of all vital functions. The patients with stent or FD are kept on heparin infusion for 24 hours (intravenous 25 000 IU for 24 hours). After the procedures, these patients were put on therapy with Clopidogrel 75 mg x 1 at least 6 months (some authors recommend 3 months) and Aspirin 100 mg x 1 for a lifetime. Following the procedure, to prevent vasospasm, some patient was kept on nimodipine.

Patients were advised to come for follow-up visits at the end of 6 and 12 months, and yearly after that. The angiographic control was performed with three-dimensional time-of-flight magnetic resonance angiography (MRA) or contrast MRA and sometimes DSA.

Results

In this study, 37 patients with 46 wide neck aneurysms were treated during the 5-year study period. All of the aneurysms had a neck width of more

than 4 mm or a dome-to-neck ratio less than 2. None of the ruptured aneurysms had been previously treated. The diameter of aneurysms was in the range from 3 mm to more than 25 mm. According to the size of the aneurysms, they have divided into three groups: 9 aneurysms were small, 15 were medium, 13 aneurysms were large and 9 giants.

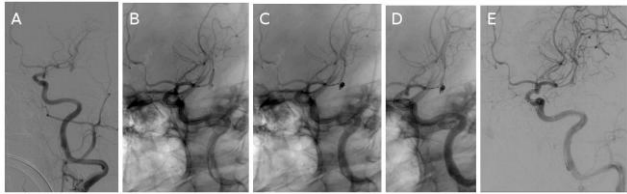


Figure 1: Unruptured M2 small aneurysm treated with balloon-assisted coiling (a, b, c); balloon deflation and protrusion of coil (d) and then stent placement, integrated branch reduced in calibre (e)

In our study wide-neck aneurysms were treated with: partial coil embolisation, balloon-assisted coiling, stent, stent-assisted coiling, flow diverter (FD), FD and coil.

For partial coil filling and balloon-assisted coiling, we used Raymond ray classification

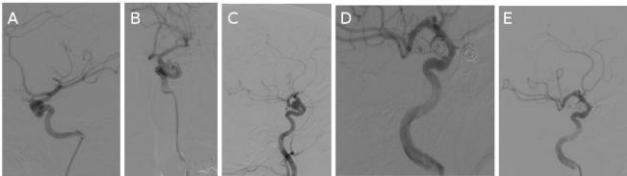


Figure 2: Left ICA (clinoid and ophthalmic segment) 2 aneurysms (a, b) and right ICA (cavernous and communicating segment) 2 aneurysms (c, d, e)-ruptured one on communicating segment all four treated with stent-assisted coiling on both ICA in one session

But together with wide neck aneurysms where we used flow modification devices, extra saccular (stents and FD) we used a modification of classification proposed from H.S. Cekirge and I. Saatci, for immediate DSA result in all treated aneurysms and 23 patient follow up.

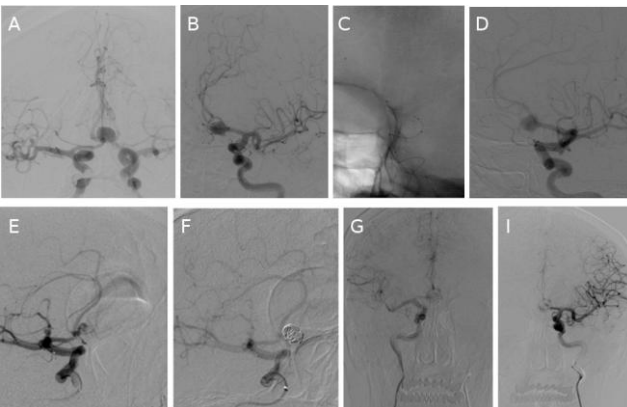


Figure 3: Unruptured Acom aneurysm filling from both ICA (a); treated with the stent in left A1/A2 (b, c, d) and coiling from the right side (e, f); control angiograms from both ICA-complete occlusion g, i

Grading of occlusion for all types of treatment:

1. Complete occlusion of the aneurysm sac was found in 22 (47.82%).
2. Residual neck in 6 aneurysms (13.04%).
3. A residual aneurysm was observed in 5 (10.86%).
4. Aneurysmal filling immediate postoperative result-end of treatment DSA with flow modification treatment (from 39 aneurysms treated with flow modification).
 - a. With contrast stagnation 9 (23.07%)
 - b. Without contrast stagnation 4 (10.25%)
5. Stable remodelling with flow modification [from 39 aneurysms treated with FM only 23 (58.97%) were followed up on 6 and 12 months] – 5 aneurysms with residual neck, 4 aneurysms with a residual aneurysm, 7 aneurysms from 4a and 3 aneurysms from 4b.

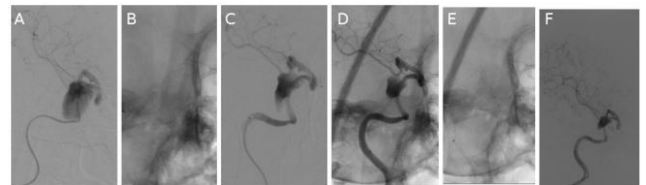


Figure 4: Giant unruptured aneurysm of right ICA (cavernous segment), partially thrombosed (a); treated with FD (b) and immediate contrast stagnation (c) and progressive thrombosis (d); balloon dilatation of the FD in proximal stenotic part (e); control angiogram after finished treatment (f)

Only two of all followed up aneurysms showed regrowth-recanalisation and need of retreatment.

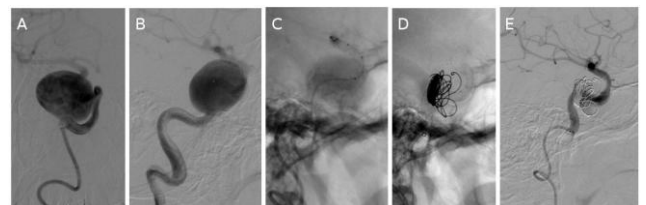


Figure 5: Giant unruptured right ICA aneurysm with cranial nerve palsy (a); treated first with stent because of tortuous anatomy of the parent vessel (b, c); placement of some coils in the sac, balloon dilatation of the stent on the stenosed part (d) and then placement in stent flow diverter(e) with total occlusion

In this study, there were ten cases (27.02%) of procedure-related complications in our patients. In two patients (5.40%) in-stent thrombosis was observed. In one patient in-stent thrombosis was resolved with IA and IV Aggrastat but with small distal embolus and small infarction zone and neurological deficit that was improved with rehabilitation.

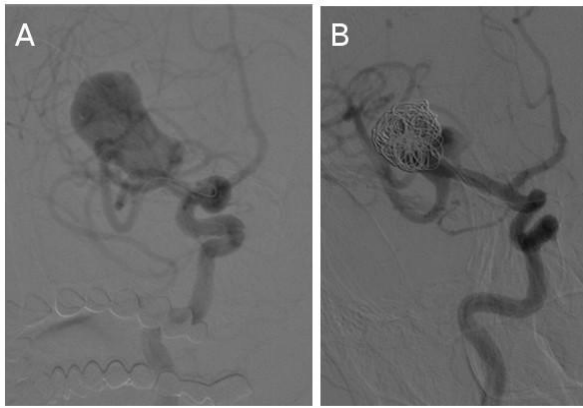


Figure 6: Giant right MCA a trifurcation aneurysm with mass effect (a); treated with stent-assisted coiling, the stent in M1/M2 inferior trunk and partial coil filling of the 2/3 of the sac (b)

The second patient presents thrombosis of the flow diverter immediately after placing the device, but there were sufficient cross filling and no neurological deficit. The thromboembolism was resolved without neurological deficits.

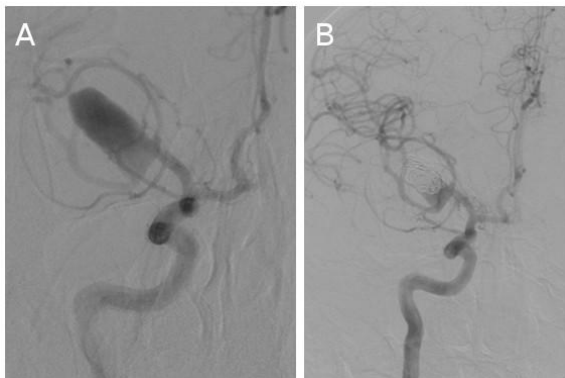

Figure 7: Ruptured right MCA a large aneurysm with wide neck and branches integrated (a); treated with intentional partial coiling, residual neck (b)

The spasm was observed in 7 (18.91%) of the patients, which was resolved spontaneous or with nimodipine. In this study in one patient (2.70%) spontaneous coil detaches successfully retrieved with the micro snare. Except for these complications, there was no evidence of other procedure-related complications such as coil protrusion during the procedure.

In this study, we didn't have death outcome.

Discussion

Aneurysms, both ruptured and unruptured, may be treated via craniotomy by surgical clip ligation and microsurgical clip(s) placed on the aneurysm neck to remove an aneurysm from the circulation and

prevent possible rupture (or if an aneurysm had already ruptured, to stop bleeding and prevent re-rupture).

Based on the published literature, concerning safety events, there was a higher mortality rate reported with open surgery, i.e., 13.8% vs 10.7% for surgical clipping and traditional coiling, respectively. Patient age has been shown to be a strong indicator of poor surgical outcome [6]. It has also been shown that surgical clipping carries an increased risk of seizures both in short and long-term follow up where Molyneux et al., showed that 4.1% of open surgical patients (compared to 2.5% of the endovascular treated patients) had seizures associated with re-bleeding after receiving treatment for their aneurysm. Furthermore, as previously discussed in Section 2.2, open surgical clipping may be limited concerning accessibility to treat certain aneurysms based on their location in the neurovasculature (e.g., posterior circulation aneurysms in perforator rich regions) [7].

Endovascular treatment methods offer an alternative method for the treatment of intracranial aneurysms. Treatment of intracranial aneurysms is increasingly performed by endovascular means as an alternative to microsurgical clipping with lower morbidity and mortality rates in selected cases [8]. However, each aneurysm should be assessed by an interdisciplinary approach, with the aim being to choose the best option for each patient [9].

Wide neck bifurcation aneurysms remain a challenge, both for surgical as well as endovascular techniques [10]. Treating wide-neck intracranial aneurysms is a difficult endeavour. From a surgical standpoint, they are technically demanding to dissect, especially when they reside in the posterior circulation or near the cranial skull base. Although initially considered by endovascular surgeons to be "poor open-surgery candidates," patients with wide-neck aneurysms have posed problems for catheter-based therapy as well.

Soon experience showed 2 main challenges for aneurysm coiling: (1) some aneurysms were not easy to treat because of their shape (large and giant aneurysms, fusiform aneurysms, large neck aneurysms, aneurysms with unfavourable size relationship between aneurysm dome, neck, and parent artery) [11]. The risk of coil protrusion into the parent vessel, subtotal aneurysm occlusion and recanalisation of an aneurysm are still major limitations of image-guided, endovascular treatment of cerebral aneurysms [8].

This led to the development of new techniques and technologies, including balloon-assisted coiling (known as the remodelling technique), aneurysm coiling supported by stenting, and the more recent introduction of flow diversion/disruption [11].

One characteristic that makes an aneurysm ideal for endovascular therapy is a fundus-to-neck

ratio greater than 2. The greater this ratio, the greater the disparity between the orifice and the body, thus making coil deposition easier and coil stability within the lesion greater. As the ratio drops, it is more difficult to prevent coils from herniating out of the fundus, through the neck, and into the parent vessel. In some cases, "wide necked" can be considered a neck that exceeds the diameter of the widest diameter coil available. This diameter depends on the system used for embolisation [4].

Neck size, the size of the opening that connects the parent artery to the aneurysm body, is also an important descriptor for aneurysms and can dictate treatment options. Aneurysms with a neck > 4 mm in diameter or dome to neck ratio < 2 are typically classified as wide-neck [3].

Such aneurysms can be difficult to treat and are less amenable to coiling alone or surgical clipping in comparison to aneurysms with smaller necks [12].

Zubillaga et al. originally defined a "wide neck" as an absolute neck diameter of 4.0 mm. Debrun et al., defined "wide-neck" aneurysms as those with dome-to-neck ratios of < 2.0. These early definitions were created by success with endovascular coil therapy when the technique was in its infancy. Cloft et al. later noted that the technical advance of complex coil shapes allowed successful endovascular therapy of aneurysms with a dome-to-neck ratio of > 1.5 [13].

Results from early studies using single-dimensional coils alone demonstrated 72% to 80% complete occlusion when the ratio was greater than 2, and 53% when it was lower. Inability to keep coils within these lesions, the post-treatment presence of a residual aneurysm, and the occurrence of delayed aneurysm recanalisation led investigators to seek new ways to embolize these lesions safely and effectively [4].

Moret et al. first described the clinical use of the balloon-assisted technique in humans and described their results on 52 aneurysms in 50 patients, achieving complete occlusion in 77%, subtotal occlusion in 17%, and incomplete occlusion in 6% [14], [15].

In the 34 aneurysms treated by the remodelling technique with Hyper Form balloon, immediate angiographic results consisted of total occlusion in 31 cases (91.2%) and partial occlusion in three cases (8.8%). There were five procedure-related complications (14.7%), including two coil protrusions and three thromboembolisms; Except one patient, all were successfully resolved without permanent neurologic deficit. No new bleeding occurred during the follow-up. Twenty patients (59%) underwent angiographic follow-up from 2 to 33 months (mean 9.2 months) after treatment. Focal recanalisation with coil compaction of the neck portion was observed in 5 cases (25%). Only one case showed major

recanalisation and underwent stent-assisted coil embolisation [15].

In general, treatment of wide-neck and wide-neck bifurcation aneurysms by using endovascular techniques is challenging. Embolisation of these aneurysms without the use of adjunctive devices is difficult because of the instability of the coil mass leading to the risk of coil protrusion into the parent artery. The risk of coil protrusion often makes attenuated packing of an aneurysm difficult or impossible to achieve, which can lead to lower rates of complete occlusion [16].

Follow-up imaging showed recanalisation in 25.0% (2/8) of initially completely occluded aneurysms and 50.0% (5/10) of neck-remnants or residual aneurysms resulting in an overall recanalisation rate of 38.5%. Recanalisation from neck remnants to residual aneurysms was observed in 28%. The follow-up in aneurysms after treatment with stent implantation with a mean of 22 months (range 2–79 months) is the longest observation period reported so far. Recanalization was found in 14.3% (1/7) of dome/neck ratio 92 aneurysms and in 66.7% (4/6) of dome/neck ratio > 2 aneurysms.

Fiorella et al. reported 23% of recanalisation in 3–6 months' follow-up with 52% showing progressive thrombosis, 25% showed no change [17].

Biondi et al. reported a mean follow-up of 9 months (range 3 to 24 months). Initially, occluded aneurysms remained occluded, and 36% of neck remnants and 33% of residual aneurysms progressed to complete occlusion. Recanalisation to residual aneurysms was observed in 28% of the neck remnants [18].

The study Cerebral Aneurysm re-rupture after Treatment [19] reported that the degree of aneurysm occlusion after treatment was strongly associated with risk of re-rupture, but aneurysm re-treatment may or may not carry a higher risk than the stable incomplete occlusion or recanalisation [7], [20]. Unfortunately, this mostly originates from coiled aneurysms and cannot be generalised to the entire population of cerebral aneurysms, especially for those aneurysms treated with new devices that modify flow from inside or outside of the aneurysm sac. Flow modifiers (FM) (dedicated extra saccular flow diverters, multiple stent-in-stent applications, and intra saccular flow disrupters) have been introduced as a new concept for treatment of IA [17], [21].

The Raymond-Roy Occlusion Classification, also known as the Montreal scale [22] has been the most widely used, and it classifies the results after aneurysm coiling, which can be applied immediately after the treatment as well as during the follow up (class I: complete obliteration; class II: residual neck; class III: residual aneurysm; class IIIa: contrast opacification within the coil interstices of a residual aneurysm; class IIIb: contrast opacification outside the

coil interstices, along the residual aneurysm wall) [22, 23]. Modification proposed Mascitelli et al., a study that found class IIIa aneurysms progress to complete occlusion more than class IIIb aneurysms and a validation study by Stapleton et al., [24], [25].

Introduction of the extra saccular flow diverters created a need for different classifications, not only to describe the initial results but also to anticipate the outcome, including the risk of infrequent but severe complications of postoperative rupture [19], [20].

A new classification is proposed for cerebral aneurysms treated with any endovascular technique, coiling with or without adjunctive devices, flow diversion, intra saccular flow modifiers, or any combination of the above. Raymond-Roy Occlusion Classification is expanded with novel subgroups such as class 1 represents complete occlusion and is subdivided if a branch is integrated too, or originated from, the aneurysm sac; class 2 represents neck filling; class 3 represents incomplete occlusion with an aneurysm filling as in the previous classification; and class 4 describes the immediate postoperative status after extra- or intra saccular flow modification treatment. A new concept, "stable remodelling," is included as class 5, which represents filling in the neck region that stays unchanged or reduced, as shown with at least 2 consecutive control angiographies, at least 6 months apart, for not < 1 year, or the remodeled appearance of a dilated and/or tortuous vessel in continuation with the parent artery without sac filling [26], [27], [28].

In conclusion, wide-necked aneurysms remain difficult to treat and occlude permanently. In some cases, endovascular treatment is the only possible option for treatment of the wide neck aneurysms. According to our experience, despite some troubles during the treatment, endovascular treatment of intracranial aneurysms was revealed safe and feasible.

The goal of endovascular treatment in intracranial aneurysms is preventing rupture meaning secured aneurysm with or without a perfect angiographic appearance. In complex aneurysms where "perfect" anatomic results can't be achieved or have increased risks, then, "remodelling" is an acceptable option because provide stability.

For long-term result for successful treatment of wide-neck aneurysms, there is a need of more accurate classification of immediate DSA result and more studies with longer follow up due to the introduction of new flow modification devices extra and intra saccular.

References

1. Davim ALS, Neto JFS, Albuquerque DF. Anatomical variation of the superior cerebellar artery: a case study. *J Morphol Sci.* 2010; 27(3-4):155-6.
2. Kocur D, Slusarczyk W, Przybyłko N, Bazowski P, Własczuzuk A, Kwiek S. Stent-assisted endovascular treatment of anterior communicating artery aneurysms – literature review. *Pol J Radiol.* 2016; 81:374-9. <https://doi.org/10.12659/PJR.896818> PMID:27559426 PMCID:PMC4981124
3. Johnston SC, Adams DR, Gress DR, Ono L. Surgical and endovascular treatment of unruptured cerebral aneurysms at University Hospitals. *Neurology.* 1999; 52(9):1799. <https://doi.org/10.1212/WNL.52.9.1799> PMID:10371526
4. Horowitz M, Levy EI. Endovascular management of wide-necked aneurysms. *Contemporary Neurosurgery.* 2001; 23(7):1-8. <https://doi.org/10.1097/00029679-200104150-00001>
5. Kim JW, Park YS. Endovascular treatment of wide-necked intracranial aneurysms: techniques and outcomes in 15 patients. *J Korean Neurosurg Soc.* 2011; 49(2):97-101. <https://doi.org/10.3340/jkns.2011.49.2.97> PMID:21519497 PMCID:PMC3079106
6. Wiebers DO. Unruptured intracranial aneurysms: natural history, clinical outcome, and risks of surgical and endovascular treatment. *Lancet.* 2003; 362(9378):103–10. [https://doi.org/10.1016/S0140-6736\(03\)13860-3](https://doi.org/10.1016/S0140-6736(03)13860-3)
7. Molyneux AJ, Kerr RS, Birks J, et al; ISAT Collaborators. Risk of recurrent subarachnoid haemorrhage, death, or dependence and standardised mortality ratios after clipping or coiling of an intracranial aneurysm in the International Subarachnoid Aneurysm Trial (ISAT): long-term follow-up. *Lancet Neurol.* 2009; 8:427–33. [https://doi.org/10.1016/S1474-4422\(09\)70080-8](https://doi.org/10.1016/S1474-4422(09)70080-8)
8. Mordasini P, Walser A, Gralla J, Wiest R, Ozdoba C, Reinert M, Schroth G. Stent placement in the endovascular treatment of intracranial aneurysms. *Swiss Med Wkly.* 2008; 138(43-44):646-54. PMID:19005870
9. Joseph S, Kamble R. Current trends in endovascular management of intracranial aneurysm (including posterior fossa aneurysms and multiple aneurysms). *Indian J Radiol Imaging.* 2008; 18(3):256-63. <https://doi.org/10.4103/0971-3026.41841> PMID:19774171 PMCID:PMC2747444
10. Singh R, Vani K, Goel G, Mahajan A. Endovascular treatment of a complex broad neck bifurcation aneurysm at peripheral center by pCONus stent: a new neck bridging device. *Indian J Vasc Endovasc Surg.* 2018; 5:53-5. <https://doi.org/10.4103/ijves.ijves.64.17>
11. Pierot L, Wakhloo AK. Endovascular treatment of intracranial aneurysms: current status. *Stroke.* 2013; 44(7):2046-54. <https://doi.org/10.1161/STROKEAHA.113.000733> PMID:23798560
12. Kwon BJ, Seo DH, Ha YS, Lee KC. Endovascular treatment of wide-necked cerebral aneurysms with an acute angle branch incorporated into the sac: novel methods of branch access in 8 aneurysms. *Neurointervention.* 2012; 7(2):93-101. <https://doi.org/10.5469/neuroint.2012.7.2.93> PMID:22970418 PMCID:PMC3429850
13. Brinjikji W, Cloft HJ, Kallmes DF. Difficult aneurysms for endovascular treatment: overdue or undertall? *Am J Neuroradiol.* 2009; 30(8):1513-7. <https://doi.org/10.3174/ajnr.A1633> PMID:19461057
14. Moret J, Cognard C, Weill A, Castaings L, Rey A. The "remodelling technique" in the treatment of wide neck intracranial aneurysms. Angiographic results and clinical follow-up in 56 cases. *Intervention Neuroradiol.* 1997; 3:21-35. <https://doi.org/10.1177/159101999700300103> PMID:20678369
15. Youn SO, Lee JI, Ko JK, Lee TH, Choi CH. Endovascular treatment of wide-necked intracranial aneurysms using balloon-assisted technique with Hyper Form balloon. *J Korean Neurosurg Soc.* 2010; 48(3):207-12.

<https://doi.org/10.3340/jkns.2010.48.3.207> PMID:21082046
PMCID:PMC2966720

16. Zhao B, Yin R, Lanzino G, Kallmes DF, Cloft HJ, Brinjikji W. Endovascular coiling of wide-neck and wide-neck bifurcation aneurysms: a systematic review and meta-analysis. *Am J Neuroradiol.* 2016; 37(9):1700-5.

<https://doi.org/10.3174/ajnr.A4834> PMID:27256850

17. Fiorella D, Lylyk P, Szikora I, et al. Curative cerebrovascular reconstruction with the Pipeline embolization device: the emergence of definitive endovascular therapy for intracranial aneurysms. *J Neurointerv Surg.* 2009; 1:56–65.

<https://doi.org/10.1136/jnis.2009.000083> PMID:21994109

18. Biondi A, Janardhan V, Katz JM, Salvaggio K, Riina HA, Gobin YP. Neuroform stent-assisted coil embolization of wide-neck intracranial aneurysms strategies in stent deployment and midterm follow-up. *Neurosurgery.* 2007; 61:460-68.

<https://doi.org/10.1227/01.NEU.0000290890.62201.A9>
PMid:17881956

19. Johnston SC, Dowd CF, Higashida RT, et al; CARAT Investigators. Predictors of rehemorrhage after treatment of ruptured intracranial aneurysms: The cerebral aneurysm rerupture after treatment (CARAT) study. *Stroke.* 2008; 39:120–25.

<https://doi.org/10.1161/STROKEAHA.107.495747> PMID:18048860

20. Crobeddu E, Lanzino G, Kallmes DF, et al. Review of 2 decades of aneurysm-recurrence literature, part 2: managing recurrence after endovascular coiling. *Am J Neuroradiol.* 2013; 34:481-5. <https://doi.org/10.3174/ajnr.A2958> PMID:22422182

21. Ding YH, Lewis DA, Kadirvel R, et al. The Woven EndoBridge: a new aneurysm occlusion device. *Am J Neuroradiol.* 2011; 32:607–11. <https://doi.org/10.3174/ajnr.A2399> PMID:21330397

22. Roy D, Milot G, Raymond J. Endovascular treatment of unruptured aneurysms. *Stroke.* 2001; 32:1998–2004.

<https://doi.org/10.1161/hs0901.095600> PMID:11546888

23. Raymond J, Guilbert F, Weill A, et al. Long-term angiographic recurrences after selective endovascular treatment of aneurysms with detachable coils. *Stroke.* 2003; 34:1398–403.

<https://doi.org/10.1161/01.STR.0000073841.88563.E9>

PMid:12775880

24. Mascitelli JR, Moyle H, Oermann EK et-al. An update to the Raymond-Roy occlusion classification of intracranial aneurysms treated with coil embolization. *J Neurointerv Surg.* 2015; 7(7):496-502. <https://doi.org/10.1136/neurintsurg-2014-011258>

PMid:24898735

25. Stapleton CJ, Torok CM, Rabinov JD, et al Validation of the modified Raymond–Roy classification for intracranial aneurysms treated with coil embolization. *J Neurointerv Surg.* 2016; 8(9):927-33. <https://doi.org/10.1136/neurintsurg-2015-012035>

PMid:26438554

26. O'Kelly CJ, Krings T, Fiorella D, et al. A novel grading scale for the angiographic assessment of intracranial aneurysms treated using flow diverting stents. *Interv Neuroradiol.* 2010; 16:133–37.

<https://doi.org/10.1177/159101991001600204> PMID:20642887

PMCID:PMC3277972

27. Kamran M, Yarnold J, Grunwald IQ, et al. Assessment of angiographic outcomes after flow diversion treatment of intracranial aneurysms: a new grading schema. *Neuroradiology.* 2011; 53:501-8. <https://doi.org/10.1007/s00234-010-0767-5> PMID:20838782

28. Cekirge HS, Saatci I. A new aneurysm occlusion classification after the impact of flow modification. *Am J Neuroradiol.* 2016; 37(1):19-24. <https://doi.org/10.3174/ajnr.A4489> PMID:26316566