

Multiple Primary Cutaneous Melanomas in a Bulgarian Patient: The Possible Role of One Step Melanoma Surgery (OSMS) As the Most Adequate Treatment Approach!

Georgi Tchernev^{1,2*}, Ivanka Temelkova¹

¹Medical Institute of Ministry of Interior (MVR), Department of Dermatology, Venereology and Dermatologic Surgery, General Skobelev Nr 79, Sofia, Bulgaria; ²Onkoderma - Polyclinic for Dermatology and Dermatologic Surgery, General Skobelev 26, Sofia, Bulgaria

Abstract

Citation: Tchernev G, Temelkova I. Multiple Primary Cutaneous Melanomas in a Bulgarian Patient: The Possible Role of One Step Melanoma Surgery (OSMS) As the Most Adequate Treatment Approach! Open Access Maced J Med Sci. <https://doi.org/10.3889/oamjms.2018.487>

Keywords: Melanoma; OSMS; Treatment outcome; Survival benefit; Surgery

***Correspondence:** Georgi Tchernev, Medical Institute of Ministry of Interior (MVR), Department of Dermatology, Venereology and Dermatologic Surgery, General Skobelev Nr 79, Sofia, Bulgaria; Onkoderma-Polyclinic for Dermatology and Dermatologic Surgery, General Skobelev 26, Sofia, Bulgaria. E-mail: georgi_tchernev@yahoo.de

Received: 08-Nov-2018; **Revised:** 11-Nov-2018; **Accepted:** 12-Nov-2018; **Online first:** 21-Nov-2018

Copyright: © 2018 Georgi Tchernev, Ivanka Temelkova. This is an open-access article distributed under the terms of the Creative Commons Attribution-NonCommercial 4.0 International License (CC BY-NC 4.0)

Funding: This research did not receive any financial support

Competing Interests: The authors have declared that no competing interests exist

BACKGROUND: Simultaneous occurrence of multiple primary melanomas is a rare, however possible phenomenon, and it is believed that older, male, white, Atypical Mole Syndrome carriers (sporadic and familial) are part of the possible risk factors for its occurrence. In these patients, it is possible to observe involutinal changes or (partial/complete) regression of melanocytic lesions, which are likely to be caused by the generation of a spontaneous immune reaction against specific tumour antigens.

CASE REPORT: A 58-year-old male patient is presented with two melanocytic lesions located in the right clavicle (subclavicular area) and left the scapular area that meets clinically and dermatoscopically the requirements for malignant melanoma. The lesions were removed by a radical excision with 0.5 cm surgical safety margin in all directions. During the subsequent histological verification it was established it was melanoma with a tumour thickness of 1 mm that in one case, and the other 2 mm. A week later, according to the recommendations of the current guidelines, a re-excision was performed with a surgical safety margin of 1.5 cm in all directions. Considering the complications that are possible during the parallel removal of a draining lymph node recommended for these tumour thicknesses, the patient definitively refused its detection and removal.

CONCLUSION: A rare case of a Bulgarian patient with multiple primary, however partially involutinal melanomas existing for over 20 years, is described. The individual recommendations of dermato-oncologists for the patient (according to AJCC) were not in favour of radicality but of a more sparing, individualised approach, appropriate for that patient. Unfortunately, the approach we used, in this case, was inconsistent with the AJCC or OSMS guidelines. The reason for individualising the approach in the case we have described is due to the variability of the recommendations for surgical treatment of melanomas laid down in the AJCC.

Introduction

The incidence of the so-called multiple primary melanomas (MPM) is between 1.3 and 8.0% [1]. The presence of primary melanoma increases the risk of subsequent development of the same melanocytic lesion, which most often occurs several years after the diagnosis of the primary formation and usually affects parts of the body that is different from its initial location [2]. The family history of malignant melanoma, as well as the presence of dysplastic nevus (in the relevant patient groups), are thought to be risk factors for MPM occurrence [1], [2], [3], [4].

These result in two interesting groups of patients with multiple primary melanomas: 1) within the so-called sporadic form of the syndrome of dysplastic nevi-AMS (atypical mole syndrome), 2) Familial atypical multiple melanoma (FAMMM) syndromes, 3) Xeroderma pigmentosum should also be considered a disease, in which there may be multiple primary melanomas, 4) Complete involution of malignant melanomas (MMs) is an extremely rare phenomenon; on the other hand, partial regression occurs in 10% to 35% of the cases, regardless of Breslow tumour thickness, 5) In this respect, clinical and histopathological criteria for MMs regression have been established [5]. Each patient with malignant melanoma or multiple primary

melanomas should be considered a combination of individual specificities that should determine the choice of strategy for subsequent treatment [6].

Case report

A 58-year-old male patient is presented in good general status. The patient was hospitalised for the first time in Oncoderma Dermatology and Dermatologic Surgery Clinic, Sofia, for surgical removal of two pigment lesions located in the right clavicle (subclavicular area) and left scapular area. The lesions occurred 15 years ago, but within the last year, the patient has observed an increase in the intensity of the black colour and size of one of the lesions, as well as involution in the scapular area. During the dermatological examination, two melanocytic lesions with uneven boundaries and irregular distribution of the pigment were found in the right subclavicular and left scapular areas (Figures 1a-1f).

Clinically and dermatoscopically, these findings met the requirements for a malignant melanocytic lesion. Further tests were carried out: 1) paraclinical – without substantial changes, 2) lymph node ultrasound – no enlarged lymph nodes were visualized in the neck, two axil and inguinal area; 3) lung and heart radiology – preserved transparency of pulmonary parenchyma without active disease alterations – no focal changes were observed; clear costophrenic sinuses; heart shadow – normal, 4) S-100-0.036 (< 0.1); LDH – 314.00 IU (240.00-480.00).

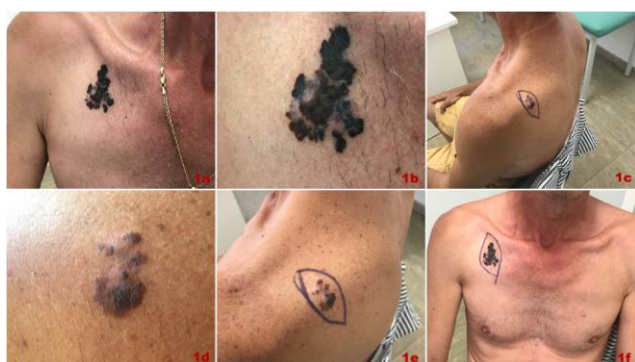

Figure 1: a), b) Clinical picture of primary cutaneous melanoma located on the right- subclavicular. Lesion with uneven pigmentation and uneven boundaries; c), d) Clinical view of melanoma showing uneven pigmentation, uneven edges and data about involution located in the left scapular area; e), f) Outlining the 0,5 cm operational security boundaries in all directions, preoperative finding

The lesion localised to the right, in the subclavicular area, was removed by radical excision. A surgical margin of 0.5 cm was used in all directions (Figure 2a). The resulting surgical defect was recovered by a single interrupted suture (Figure 2b).

Histological verification showed that it was mixed, superficially advancing and nodular malignant melanoma, Clark's level III, Breslow's thickness 2 mm, no ulceration, high mitotic activity, moderate stromal lymphocytic reaction, no spontaneous regression, T2aN0M0 stage.

In the left scapular area, a primary excision of the melanocytic lesion was performed with a surgical safety margin of 0.5 cm in all directions (Figure 2c). The defect was corrected using stretch plastics (Figure 2d). The histological examination of the lesion removed from the left scapular area showed superficially advancing malignant melanoma, Clark's level II, Breslow's thickness 1 mm, no ulceration, T1bN0M0 stage.

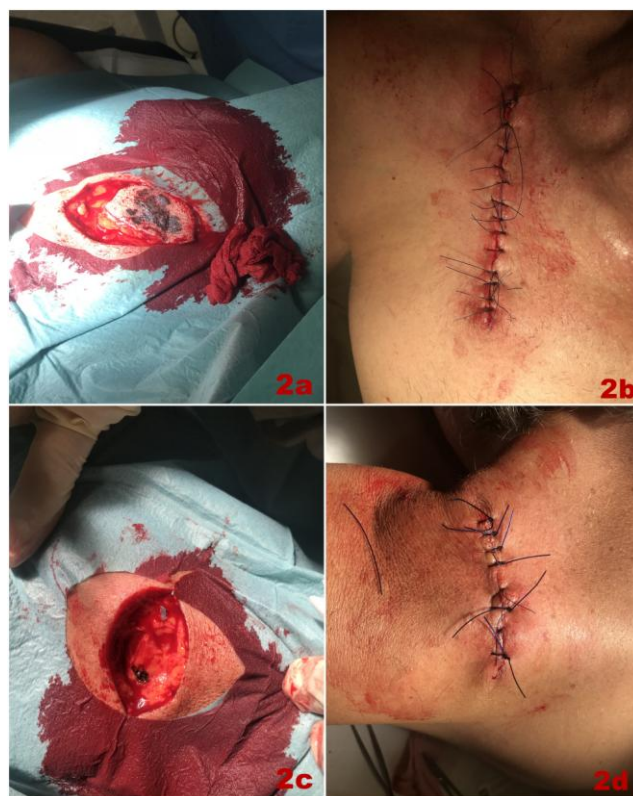

Figure 2: a), c) Intraoperative finding of the two lesions removed by elliptical excision; b), d) Postoperative clinical picture of surgical defects closed by single interrupted sutures

A week later, following the recommendations of the applicable guidelines, a re-excision was performed in the primary excision zones with 1.5 cm surgical safety margin in all directions (Figures 3a-3f). Immediately before the re-excision, the patient was consulted in the Oncology Ward, where the need for parallel removal of draining lymph node during the re-excisions was rejected, based on 1) the lack of explicit evidence of locoregional dissemination of the process, 2) complains that occurred more than 20 years ago, as well as 3) the involucional nature of one of the lesions. Postoperative period – calm, without complications. The patient was referred to the oncology unit for regular ultrasound controls and the introduction of systemic Interferon therapy.

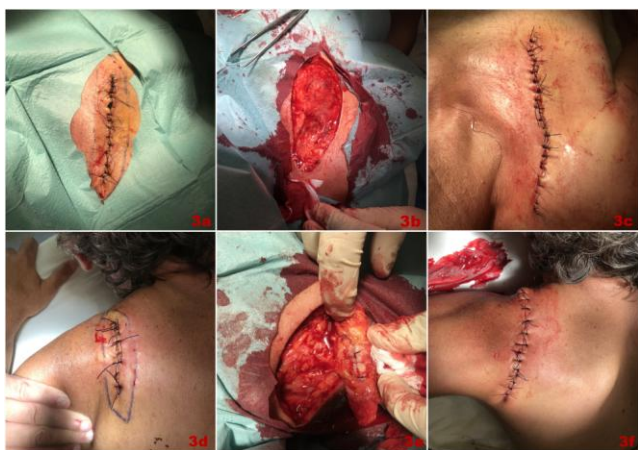


Figure 3: a), d) Preoperative outline of 1.5 cm operational security boundaries in all directions for primary excision sites directly before re-excision; b), e) Intraoperative view of elliptical re-excision; c), f) Postoperative clinical picture of surgical defects closed by single interrupted sutures after re-excision

Discussion

Simultaneous occurrence of multiple primary melanomas (MPM) in the same patient is a rare, however well-recognisable phenomenon with variable incidence, according to the available literature [7], [8] [9], [10]. It is believed that older, male, white, history of melanoma, thin primaries and history of another cancer are risk factors for development MPMs [6], [10]. Also, the identification of Atypical Mole Syndrome carriers (sporadic and familial) is essential, as it is considered the most important phenotypic risk factor for cutaneous melanoma and there are documented cases of MPM within the familial and sporadic syndrome of dysplastic nevi [3].

MPM patients are also at risk of developing subsequent primary melanomas, which most often occurs within the first year [1], [10]. Apart from additional melanoma, the probability of developing nonmelanoma tumours in melanoma patients should be noted as well [11].

It is interesting whether there is a difference in the prognosis between the patients with single and multiple primary melanomas [12]. So far, melanoma thickness, as well as some additional features, such as the presence of ulceration, mitoses and scalp location, has been used as a prognostic factor [12].

Based on the available literature from research, some conclusions have been laid down, without a unanimous opinion:

1. According to some authors, the mean Breslow's thickness of the first melanoma is significantly higher than the mean Breslow's thickness of the second primary melanoma [13].

2. No difference is observed in the presence or absence of mitoses, a marker of tumour proliferation, in SPM (Single primary melanomas) and MPM [14].
3. CDKN2A mutation status and family history of melanoma significantly affect outcomes of MPM patients, and worse outcomes have been noted in patients with multiple primary melanomas (MPMs) than in patients with single primary melanomas [15].
4. Multiple invasive lesions seem more at risk of death than melanoma [16], but according to others:
5. Thicker SPM, however, had higher fatality than thicker MPM [12], and
6. The presence of multiple primary melanomas does not appear to be a negative prognostic factor [17].

However, it is generally accepted that melanoma patients require close follow-up to detect not only metastases but also subsequent primaries in their earliest phases [17].

Spontaneous regression of malignant tumours is extremely rare, but it is still a possible phenomenon [18], [19], [20]. It may be partial or complete [21]. Regression is defined as a much more common phenomenon in cases of malignant melanoma than in other types of tumours [21]. It may typically be observed in patients with no evidence of metastases development, but also the event of metastatic melanomas [18], [20], [22]. While primary non-metastatic melanomas are thought to have a possible spontaneous regression in up to 50% of cases, the percentage of metastases is quite different, and regression is only observed in 0.23% of the cases of metastatic forms [20], [21]. Clinically, the presence of hyper- to hypo-pigmented macules, patches, papules and plaques, measuring from 0.4 to 3.0 cm in diameter, showing enlargement, friability, and bleeding, speaks in favour of emerging regression [5]. In turn, histopathological signs defining the regression as an event include atrophic epidermis, dermal aggregation of many melanophages, lymphocytic infiltrate, reactive vascular proliferation, and surrounding fibrosis [5].

Regarding the factors considered as leading to spontaneous regression, surgical trauma, infection, vaccination (BCG and rabies vaccines), immunological factors, blood transfusion and various endocrine factors are being mentioned [21]. Now there is a widespread perception that specific cell-mediated immunity against melanoma cells are involved in regression mechanisms and that mainly the lymphocytes are responsible for this tumour regression [19]. This has been investigated histologically and by immunofluorescence (direct and indirect) in the cases of Halo nevus, where it is clear

that in addition to T cell-mediated immunity (CD8 + cells outnumbered CD4 + cells), IgM antibodies against nevus cells as well as melanoma cells and cultured melanocytes may be involved in regression [23].

It is not yet clear how spontaneous immune response is induced and why, for example, in specific events of melanoma and congenital melanocytic nevus combination, regression only affects melanoma, while nevus remains undisturbed by the immunological response [24].

According to some authors, patients who develop multiple asynchronous melanomas, namely the first melanoma, produce an immunisation effect with increased immunity against certain antigens expressed by tumour-associated melanocytes [25]. According to other authors, the presence of regression may be considered a favourable prognostic factor in patients with AJCC stage I-II melanoma. However this statement is still controversial [26], [27].

The approach adopted for treatment of malignant melanoma includes surgical resection with adequate excision margins, with or without lymph node biopsy [28]. At this stage, a large proportion of dermatologists follow the recommendations of the American Joint Committee on Cancer, according to which primary melanoma surgery is based on Breslow tumour thickness and includes resection of 0.5 cm for MIS, 1.0 cm for melanomas \leq 1.0 mm thick, 1-2 cm for melanoma thickness of 1.01-2 mm, 2 cm margins for melanoma thickness of 2.01-4 mm, and 2cm margins for melanomas $>$ 4 mm thick [29]. Based on the established guidelines, treatment begins with resection of the melanocytic lesion with a surgical margin of 0.4-0.5 cm in all directions, followed by re-excision (as in our patient) with or without parallel drainage lymph node (depending on the established postoperative tumor thickness), which however is not individualized and often leads to ambiguity and hesitation, and hence to difficulty in choosing a therapeutic approach, as in the patient we described. [30]. The role of SUNN (sentinel lymph node biopsy) continues to be studied, and its use is currently recommended for Stage IB and Stage II melanomas [29]. In some cases, preoperative high-frequency ultrasound diagnosis helps determine the limits of surgical margins, indications for lymph node biopsy, and the need for re-excision [31].

In the event of hesitation, One step melanoma surgery (OSMS) is found to be a very useful approach, since it clearly defines the surgical safety margins in a) melanoma *in situ* resection with 1 cm surgical safety margin, b) tumours 1 to 2 mm thick resection with 1 cm surgical safety margin, and c) thickness of 2 to 4 mm – 2 cm surgical safety margin, where, in the event of b) and c), it is obligatory or highly recommended to perform, simultaneously or in parallel, detection and removal of the draining lymph node (regardless of whether the node is

echographically enlarged); d) tumour thickness above 4 mm – resection with 2 cm in all directions and if there are no enlarged lymph nodes, 2 cm resection is sufficient, together with control/instrumental examinations every two months, but in the presence of enlarged lymph nodes, it is recommended that they will be removed and examined for the BRAF V600mutation, followed by computed tomography scan (CT) with contrast or PET scan. Interestingly, the abovementioned guidelines for One step melanoma surgery do not change and completely overlap with AJCC recommendations (relative to the result or efficiency score), however OSMS is a less traumatic method requiring additional preoperative preparation and judgment [32], [33], [34], [35], [36].

It is believed that in the case of melanomas with a thickness of over 4mm ELND is not of paramount importance as the draining lymph nodes may not be affected [32]. The reasons for this may be different: 1) accessory parallel lymphatic pathways available, on the one hand, and the other; 2) tumour cells may have passed the draining lymph node without stopping there, or there has already been primary haematogenous dissemination without involving the lymph nodes and pathways [32]. However, it should be taken into account that OSMS applies to all melanoma patient groups, which makes it more appropriate therapeutic endpoint [32].

One stage melanoma surgery results in a reduction of the number of steps of the so-called melanoma treatment programs by reducing the number of stages in which an error (or deviation from the guidelines) could occur [35]. Meanwhile, OSMS saves the patients repeated surgical interventions and relieved them emotionally and financially [32], [36], [37].

In conclusion, one step melanoma surgery is an approach with clearly defined surgical safety (in all melanoma patient groups) and behaviour against draining lymph nodes based on the preoperative ultrasound tumour thickness or clinical and dermatoscopic judgement (when the latter are explicitly in favour of thin melanoma diagnosed in certain patients). It is a better therapeutic solution for all cutaneous melanoma patient groups that allows for the best control of the disease within one surgical session. The case is indicative of the errors or omissions resulting from surgical treatment approaches recommended or not fully defined by AJCC. Or, if we need to be even more precise, this case is indicative of the risks that arise during a possible two-step or two-stage surgical approach.

In the One step melanoma surgery, these possibilities are virtually non-existent, they are limited to the absolute minimum by the creation of certain algorithms. Optimising surgical approaches is a personal choice for the clinician. When guidelines are not so strict and precise, they provide an unjustified field of freedom for the clinician's actions, and this

may be confusing for the patients themselves. Thus, there is an increased possibility of inadequate and unexplained approaches or solutions (as the case we have described). This is also the reason why some dermatologists in the relevant units are increasingly using the recommendations for OSMS that limit the clinician's freedom of action but also refine his/her actions. Or reduce the possibilities for errors.

References

- Ferrone C, Porat L, Panageas K, Berwick M, Halpern A, Patel A, Coit D. Clinicopathological features of and risk factors for multiple primary melanomas. *JAMA*. 2005; 294(13):1647-54. <https://doi.org/10.1001/jama.294.13.1647> PMID:16204664
- Johnson T, Hamilton T, Lowe L. Multiple primary melanomas. *J Am Acad Dermatol*. 1998; 39(3):422-7. [https://doi.org/10.1016/S0190-9622\(98\)70318-4](https://doi.org/10.1016/S0190-9622(98)70318-4)
- Tchernev G, Ananiev J, Cardoso J, Chokoeva A, Philipov S, Penev P, Lotti T, Wollina U. Multiple primary cutaneous melanomas in patients with FAMMM syndrome and sporadic atypical mole syndrome (AMS): what's worse? *Wien Med Wochenschr*. 2014; 164(15-16):302-7. <https://doi.org/10.1007/s10354-014-0295-8> PMID:25096163
- Fölster-Holst R, Schubert C, Christophers E. [Multiple melanoma in xeroderma pigmentosum]. *Hautarzt*. 1994; 45(8):554-61. <https://doi.org/10.1007/s001050050126> PMID:7960757
- Yamada S, Nawata A, Yoshioka M, Hiraki T, Higashi M, Hatanaka K, Tanimoto A. Complete regression of primary cutaneous malignant melanoma associated with distant lymph node metastasis: a teaching case mimicking blue nevus. *BMC Res Notes*. 2016; 9:366. <https://doi.org/10.1186/s13104-016-2174-4> PMID:27456492 PMCID:PMC4960676
- Slingluff C, Vollmer R, Seigler H. Multiple primary melanoma: incidence and risk factors in 283 patients. *Surgery*. 1993; 113(3):330-9. PMID:8441968
- Cheng S, Nambi R. Simultaneous occurrence of five primary melanomas and six melanomas in situ in a patient. *Clin Exp Dermatol*. 2012; 37(2):210-1. <https://doi.org/10.1111/j.1365-2230.2011.04171.x> PMID:22340700
- Remy W, Bockendahl H. [Simultaneous occurrence of two primary melanomas in a patient]. *Hautarzt*. 1975; 26(6):327-9. PMID:1165196
- Savoia P, Quaglino P, Verrone A, Bernengo M. Multiple primary melanomas: analysis of 49 cases. *Melanoma Res*. 1998; 8(4):361-6. <https://doi.org/10.1097/00008390-199808000-00010> PMID:9764812
- Moore M, Geller A, Warton E, Schwalbe J, Asgari M. Multiple primary melanomas among 16,570 patients with melanoma diagnosed at Kaiser Permanente Northern California, 1996 to 2011. *J Am Acad Dermatol*. 2015; 73(4):630-6. <https://doi.org/10.1016/j.jaad.2015.06.059> PMID:26298295
- Bower M, Scoggins C, Martin R, Mays M, Edwards M, Reintgen D, Ross M, Urist M, Noyes R, Sussman J, Hagendoorn L, Stromberg A, McMasters K. Second primary melanomas: incidence and outcome. *Am Surg*. 2010; 76(7):675-81. PMID:20698369
- Kricker A, Armstrong B, Goumas C, Thomas N, From L, Busam K, Kanetsky P, Gallagher R, Marrett L, Groben P, Gruber S, Anton-Culver H, Rosso S, Dwyer T, Berwick M; GEM Study Group. Survival for patients with single and multiple primary melanomas: the genes, environment, and melanoma study. *JAMA Dermatol*. 2013; 149(8):921-7. <https://doi.org/10.1001/jamadermatol.2013.4581> PMID:23784017 PMCID:PMC3815536
- Buljan M, Situm M, Bolanca Z, Zivković MV, Mihić L. Multiple primary melanoma: epidemiological and prognostic implications; analysis of 36 cases. *Coll Antropol*. 2010; 34(Suppl 2):131-4. PMID:21302712
- Hwa C, Price L, Belitskaya-Levy I, Ma M, Shapiro R, Berman R, Kamino H, Darvishian F, Osman I, Stein J. Single versus multiple primary melanomas: old questions and new answers. *Cancer*. 2012; 118(17):4184-92. <https://doi.org/10.1002/cncr.27407> PMID:22246969
- Helgadottir H, Tuominen R, Olsson H, Hansson J, Höiom V. Cancer risks and survival in patients with multiple primary melanomas: Association with family history of melanoma and germline CDKN2A mutation status. *J Am Acad Dermatol*. 2017; 77(5):893-901. <https://doi.org/10.1016/j.jaad.2017.05.050> PMID:28818438
- Rowe C, Law M, Palmer J, MacGregor S, Hayward N, Khosrotehrani K. Survival outcomes in patients with multiple primary melanomas. *J Eur Acad Dermatol Venerol*. 2015; 29(11):2120-7. <https://doi.org/10.1111/jdv.13144> PMID:25864459
- Savoia P, Quaglino P, Verrone A, Bernengo M. Multiple primary melanomas: analysis of 49 cases. *Melanoma Res*. 1998; 8(4):361-6. <https://doi.org/10.1097/00008390-199808000-00010> PMID:9764812
- Martín J, Pinazo I, Monteagudo C, Markovic J, Allende A, Jordá E. Spontaneous regression of multiple melanocytic nevi after melanoma: report of 3 cases. *Am J Dermatopathol*. 2014; 36(11):e183-8. <https://doi.org/10.1097/DAD.0000000000000033> PMID:25343215
- Micksche M, Cerni C, Gebhart W, Kokoschka E. [Halo Nevus (Morbus Sutton): model of an immunological tumor regression]. *Osterr Z Onkol*. 1975; 2(2-3):73-81. PMID:1243163
- Schlabe J, Shah KA, Sheerin F, Payne MJ, Fasanmade AA. Complete spontaneous regression of a metastatic melanoma of the mandible: a case report and follow-up recommendations. *International journal of oral and maxillofacial surgery*. 2018; 47(12):1519-22. <https://doi.org/10.1016/j.ijom.2018.06.007> PMID:29970290
- Cervinkova M, Kucerova P, Cizkova J. Spontaneous regression of malignant melanoma - is it based on the interplay between host immune system and melanoma antigens?. *Anticancer Drugs*. 2017; 28(8):819-830. <https://doi.org/10.1097/CAD.0000000000000526> PMID:28609309
- Kappauf H, Esser G. Metachronous Spontaneous Remission of Melanoma Lung Metastasis and Mediastinal Lymph Node Metastases. *Oncol Res Treat*. 2018; 41(3):135-138. <https://doi.org/10.1159/000485626> PMID:29485417
- Tokura Y, Yamanaka K, Wakita H, Kurokawa S, Horiguchi D, Usui A, Sayama S, Takigawa M. Halo congenital nevus undergoing spontaneous regression. Involvement of T-cell immunity in involution and presence of circulating anti-nevus cell IgM antibodies. *Arch Dermatol*. 1994; 130(8):1036-41. <https://doi.org/10.1001/archderm.1994.01690080102015> PMID:8053701
- Mărgăritescu I, Chiriță A, Vasilescu F. Completely regressed primary cutaneous melanoma - difficulties in diagnosis and classification. *Rom J Morphol Embryol*. 2014; 55(2 Suppl):635-42. PMID:25178337
- Martín J, Pinazo I, Mateo J, Escandell I, Jordá E, Monteagudo C. Assessment of regression in successive primary melanomas. *Actas Dermosifiliogr*. 2014; 105(8):768-73. <https://doi.org/10.1016/j.ad.2014.01.006> PMID:24880710
- Ribero S, Osella-Abate S, Sanlorenzo M, Savoia P, Astrua C, Cavaliere G, Tomasini C, Senetta R, Macripò G, Bernengo M, Quaglino P. Favourable prognostic role of regression of primary melanoma in AJCC stage I-II patients. *Br J Dermatol*. 2013; 169(6):1240-5. <https://doi.org/10.1111/bjd.12586> PMID:23952011
- Fontaine D, Parkhill W, Greer W, Walsh N. Partial regression of primary cutaneous melanoma: is there an association with sub-clinical sentinel lymph node metastasis?. *Am J Dermatopathol*. 2003; 25(5):371-6. <https://doi.org/10.1097/0000372-200310000->

00002 PMID:14501285

28. Dabek R, Baletic N, McUmber H, Nahed B, Haynes A, Eberlin K, Bojovica B. Development of a primary melanoma in situ within a full-thickness skin graft overlying a free muscle flap: a case report. *Case Reports Plast Surg Hand Surg.* 2018; 5(1):23–26.

<https://doi.org/10.1080/23320885.2018.1452615> PMID:29707609
PMCID:PMC5917313

29. Leilabadi S, Chen A, Tsai S, Soundararajan V, Silberman H, Wong A. Update and Review on the Surgical Management of Primary Cutaneous Melanoma. *Healthcare (Basel).* 2014; 2(2):234-49. <https://doi.org/10.3390/healthcare2020234> PMID:27429273

PMCID:PMC4934469

30. Tchernev G, Chernin S, Lozev I, Lotti T, Stavrov K, Temelkova I, Pidakev I. Innovative One Step Melanoma Surgical Approach (OSMS): Not a Myth-It's a Reality! Case Related Analysis of a Patient with a Perfect Clinical Outcome Reported from the Bulgarian Society for Dermatologic Surgery (BULSDS)! *Open Access Maced J Med Sci.* 2018; 6(4):673-674.

<https://doi.org/10.3889/oamjms.2018.194> PMID:29731939
PMCID:PMC5927502

31. Fernández I, de Troya M, Fúnez R, Rivas F, Blanco G, Blázquez N. Preoperative 15-MHz ultrasound assessment of tumor thickness in malignant melanoma. *Actas Dermosifiliogr.* 2013; 104(3):227-31. <https://doi.org/10.1016/j.adengl.2012.06.025>

32. Tchernev G, Temelkova I, Stavrov K. One Step Melanoma Surgery (OSMS) Without Using Ultrasonography for Preoperative Tumour Thickness Measurement? - "A Question that Sometimes Drives Me Hazy: Am I or Are the Others Crazy!" *Open Access Maced J Med Sci.* 2018; 6(6):1085-1090.

<https://doi.org/10.3889/oamjms.2018.236> PMID:29983807

PMCID:PMC6026427

33. Balch M, Urist M, Karakousis P, Smith J, Temple J, Drzewiecki K, Jewell R, Bartolucci A, Mihm Jr, Barnhill R. Efficacy of 2-cm surgical margins for intermediate-thickness melanomas (1 to 4 mm). Results of a multi-institutional randomized surgical trial. *Ann Surg.* 1993; 218(3):262-7. <https://doi.org/10.1097/0000658-199309000-00005> PMID:8373269

PMCID:PMC1242959

34. Balch M, Soong J, Bartolucci A, Urist M, Karakousis P, Smith J, Temple J, Ross I, Jewell R, Mihm C, Barnhill L, Wanebo J. Efficacy of an elective regional lymph node dissection of 1 to 4 mm thick melanomas for patients 60 years of age and younger. *Ann Surg.* 1996; 224(3):255-63. <https://doi.org/10.1097/0000658-199609000-00002> PMID:8813254

PMCID:PMC1235362

35. Tchernev G. One Step Melanoma Surgery for Patient with Thick Primary Melanomas: "To Break the Rules, You Must First Master Them!" *Open Access Maced J Med Sci.* 2018; 6(2):367–371. <https://doi.org/10.3889/oamjms.2018.084> PMID:29531606

PMCID:PMC5839450

36. Tchernev G. One Step Surgery for Cutaneous Melanoma: "We Cannot Solve Our Problems with the Same Thinking We Used When We Created Them?" *Open Access Maced J Med Sci.* 2017; 5(6):774–776. <https://doi.org/10.3889/oamjms.2017.168>

37. Tchernev G, Chokoeva A. New Safety Margins for Melanoma Surgery: Nice Possibility for Drinking of "Just That Cup of Coffee?" *Open Access Maced J Med Sci.* 2017; 5(3):352-358.

<https://doi.org/10.3889/oamjms.2017.068>