

Three-Dimensional Prospective Evaluation of Piezocision-Assisted and Conventional Rapid Maxillary Expansion: A Controlled Clinical Trial

Ahmed I. Abdul-Aziz^{1*}, Wael M. Refai²

¹Department of Orthodontics and Dentofacial Orthopedics, Faculty of Dentistry, Assiut University, Assiut 71515, Egypt;

²Department of Orthodontics and Dentofacial Orthopedics, Faculty of Dentistry, Minia University, Minia, Egypt

Abstract

Citation: Abdul-Aziz AI, Refai WM. Three-Dimensional Prospective Evaluation of Piezocision-Assisted and Conventional Rapid Maxillary Expansion: A Controlled Clinical Trial. Open Access Maced J Med Sci. 2019 Jan 15; 7(1):127-133.
https://doi.org/10.3889/oamjms.2019.021

Keywords: Piezocision; Rapid maxillary expansion; Skeletal; Dental; CBCT; Controlled study

***Correspondence:** Ahmed I Abdul-Aziz. Department of Orthodontics and Dentofacial Orthopedics, Faculty of Dentistry, Assiut University, Assiut 71515, Egypt. E-mail: ahmed_abdul-aziz@aun.edu.eg

Received: 21-Oct-2018; **Revised:** 29-Nov-2018; **Accepted:** 30-Nov-2018; **Online first:** 05-Jan-2019

Copyright: © 2019 Ahmed I. Abdul-Aziz, Wael M. Refai. This is an open-access article distributed under the terms of the Creative Commons Attribution-NonCommercial 4.0 International License (CC BY-NC 4.0)

Funding: This research did not receive any financial support

Competing Interests: The authors have declared that no competing interests exist

BACKGROUND: Piezocision-assisted orthodontics (PAO) is considered one of the modern techniques aiming at reducing the treatment time and overcoming some limitations of orthodontic treatment. The use of piezocision as an adjunct in the treatment of posterior crossbite is limited, so additional research in this area is required.

AIM: To three-dimensionally compare the skeletal and dental effects produced by piezocision-assisted rapid maxillary expansion (PARME) and conventional rapid maxillary expansion (RME) using cone beam computed tomography (CBCT).

MATERIALS AND METHODS: This prospective controlled study comprised 14 consecutive non-syndromic patients with posterior crossbite. In 7 patients (mean age = 16.1 ± 0.3 years), PARME was used to correct the crossbite; whereas in the remaining 7 (mean age = 15.9 ± 0.5 years), RME was done. Cone beam computed tomography (CBCT) scans were performed before expansion (T1) and 3 months later after expansion (T2) to compare the skeletal and dental effects produced by the two expansion techniques. Transverse skeletal, dentoliner, and dentoangular variables at the level of maxillary first and second premolars and maxillary first molars were measured and compared within and between groups using the appropriate statistical test.

RESULTS: For the transverse skeletal variables, PARME showed a non-significant increase; whereas, RME showed a significant increase. Regarding the dentoliner measurements, a significant increase in coronal widths and an insignificant increase in apical widths was seen in PARME, whereas, the RME showed a non-significant increase for both coronal and apical widths. Non-significant decreases (protrusion of teeth) in the dentoangular measurements were seen in both groups. Between-group comparisons showed a non-significant difference except for the dentoliner coronal widths.

CONCLUSION: PARME is effective in treating posterior crossbite. Because of the more dental expansion produced by PARME as compared to the conventional RME, PARME should be limited only to mild or moderate not severe forms of palatal constriction. The available evidence regarding the effectiveness of corticotomy- and/or piezocision-assisted maxillary expansion for correction of posterior crossbite is limited and inadequate.

Introduction

Maxillary transverse deficiency (MTD) is a type of malocclusion commonly seen in daily orthodontic practice. Narrow maxilla and palatal vault; crossbite, unilateral or bilateral; and dental crowding are clinical signs that could be the result of maxillary deficiency [1]. The aetiology of MTD can be due to both genetic and environmental factors: soft tissue influences, cleft palate, and habits [2].

MTD can be treated by expanding the maxilla

through several approaches including slow maxillary expansion (SME), rapid maxillary expansion (RME), and surgically assisted rapid palatal expansion (SARPE); however, the choice of the suitable approach is dependent upon the amount of expansion needed [3], the skeletal age of the patient [4], and the presence of vertical or sagittal problem in addition to the transverse discrepancy [5].

Widening the dental arch by opening the midpalatal suture is the goal of RME. The concept of RME was given in 1860 by E. H. Angell, and because of the efforts done by Hass, RME has become a routine [6] [7], [8], [9]. The ideal age for expansion

with RME is before 13 to 15 years of age. The more the age increases, the more the midpalatal suture becomes tightly interdigitated; however, in most individuals, it is possible to obtain considerable amounts in maxillary width up to age 15 to 18 [10], [11].

The use of corticotomy in orthodontics was first reported in orthodontics by Köle in 1959 [12] and then followed by Converse and Horowitz in 1969 [13]. Also, maxillary expansion accompanied by corticotomy was reported by Lines in 1975 [14]. In 2001, the concept was reintroduced by Wilcko et al., and was named "accelerated osteogenic orthodontics" (AOO); also, it is called "periodontally accelerated osteogenic orthodontics" (PAOO) [15].

In 2006, Park introduced the corticision technique to eliminate the need for flaps using a blade and a surgical hammer to make incisions through the gingiva [16]. On the other hand, Vercellotti reported a technique using a piezosurgical micro-saw in 2007 [17]. In this technique, the elevation of a flap before the corticotomy was maintained, and only vestibular incisions were performed. To overcome the disadvantages and combine the advantages of the previous corticotomy techniques, the Piezocision was introduced [18].

According to a previous systematic review [19], no studies were published on the effects of corticotomy on the transverse expansion; also, only, few case reports [20], [21], [22] addressed the corticotomy- or Piezocision-assisted maxillary expansion (PAME). These case reports had some shortcomings including the absence of the control group and the small sample size.

Therefore, the aim of this controlled clinical trial was to three-dimensionally compare the skeletal and dental effects produced by piezocision-assisted rapid maxillary expansion (PARME) and conventional rapid maxillary expansion (RME) using cone beam computed tomography (CBCT).

Material and Methods

We designed this study as a two-group controlled study that included fourteen consecutive non-syndromic patients (8 males, 6 females) who were prospectively included at the Department of Orthodontics and Dentofacial Orthopedics of the Faculty of Dentistry, Minia University, Egypt. Sex and age distributions for the two groups are shown in Table 1. Inclusion criteria were a maxillary transverse deficiency (MTD) with posterior crossbite, no severe gingival inflammation or active periodontal disease and free from any systemic disease. Exclusion criteria were a history of any previous orthodontic or

orthopaedic treatment, the presence of congenital or developmental deformity, or absence of more than four teeth in the posterior maxillary arch. The study protocol was approved by the Ethical Committee of the Faculty of Dentistry, Minia University, Minia, Egypt. All patients and/or parents consented to the treatment procedures.

Table 1: Sex and age distribution of the groups

	PARME (n = 7)	RME (n = 7)	P value
Gender			
Male	3 (43%)	5 (71%)	0.592
Female	4 (57%)	2 (29%)	
Age (years)			
Range	15.3 – 16.9	15.8 – 16.6	0.329
Mean \pm SD	16.1 \pm 0.3	15.9 \pm 0.5	

SD = standard deviation.

The piezocision surgery was performed by the first author (A.I.) under local anaesthesia without any flaps or sutures. Gingival vertical incisions were made interproximally only on the buccal aspect of the alveolar bone distal to canines, first premolars, second premolars, and first molars below the interdental papilla and kept as much as possible in the attached gingiva using a number 15 blade. These incisions must cross the periosteum allowing the blade to come into contact with the alveolar bone. Ultrasonic instrumentation (US2 piezoelectric tip, ULTRASURGERY, Woodpecker, Guilin, Guangxi, China) was then used to perform corticotomy cuts through the gingival micro-incisions to a depth of 3 mm (Figure 1). Antibiotics, nonsteroidal anti-inflammatory drugs and mouthwashes containing chlorhexidine were prescribed for the patients after the surgery. The patients were instructed to avoid the surgical sites while brushing during the first postoperative week to allow harmonious gingival healing.

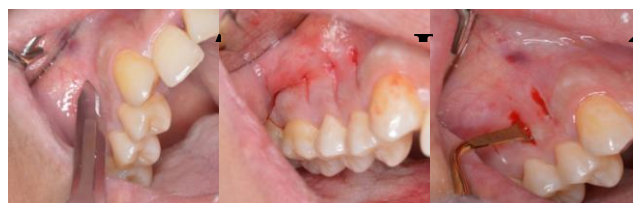

Figure 1: Piezocision surgery; A) scalpel blade No. 15 before making the vertical gingival incisions; B) after making the vertical gingival incisions; C) US2 piezoelectric tip inserted 3 mm into bone

Immediately after the surgery, a bonded tooth-borne hyrax (Leone, Sesto Fiorentino, Firenze, Italy) was cemented, and the activation of the appliance was started the day after the surgery (Figure 2). The expander was activated at a rate of 0.5 mm/day (two quarter turns daily) for eleven days to achieve an expansion of 5.5 mm to standardise the amount of expansion. The patients were reassured about the appearance of the midline diastema with the expansion. The patients were observed after two days from the beginning of the hyrax activation then every 3 days until completion of the expansion to assess the following: subject's compliance in keeping proper oral

hygiene, compliance in activation of the expander, and observation of proper seating and sealing of the appliance. Once the activation of the appliance was completed, the Hyrax was left to act as a retainer for three months. After completion of the activation, the patients were seen after one week and then every month to ensure proper plaque control and reinforce necessary hygiene techniques. The 5.5 mm expansion was enough to achieve over correction of the posterior crossbite in all patients.

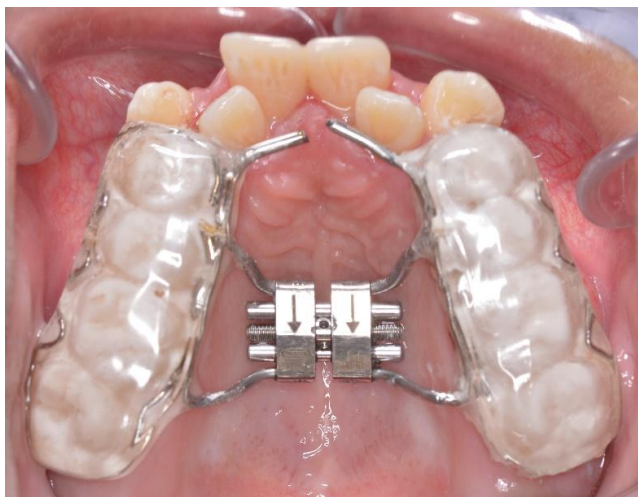

Figure 2: Cemented bonded Hyrax appliance before activation

As with PARME, the same protocol of Hyrax activation was followed in RME (0.5 mm/day for eleven days to achieve 5.5 mm expansion), but without performing the piezocision surgery. After activation, the expander was retained in place for three months before the CBCT scans can be taken. The 5.5 mm of expansion was sufficient to achieve overcorrection of the posterior crossbite in all patients.

The CBCT scans were taken before the expansion (T1) and after expansion (T2) (three months from completion of expansion) with the expander removed. Both before and after CBCT images were taken with a Scanora 3D machine (Soredex, Tuusula, Finland).

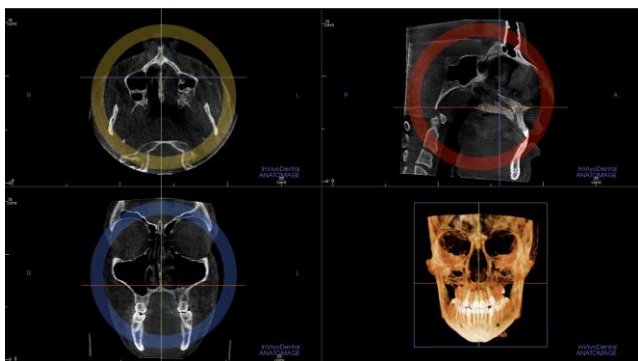


Figure 3: Reorientation of the patient position in all 3 axes (Axial, sagittal and coronal)

Intra-oral splint with a thickness of 2 mm

fabricated for each patient was worn before the CBCT scan to allow for measurements in the axial plane. Image reconstruction was performed with Anatomage software (Invivo version 5.2; Anatomage Dental, San Jose, Calif) to obtain the 3D data.

Before 3D analysis, reorientation of the patient views was performed in all 3 axes (axial, coronal, and sagittal) (Figure 3). Landmark identification for all measurements was made by the first author (A.I.). With the help of the "slice locator" which allowed each point to be seen in the three planes, fine adjustment of the position of the points was performed (Figure 4). Once the points were digitised, the measurements were recorded by the software and then compared to assess intra-observer agreement.

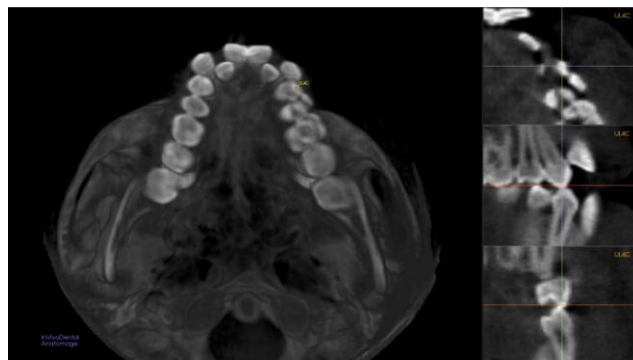


Figure 4: Fine adjustment of the position of the point on the slice locator in the axial, coronal and sagittal views

The 3D analysis was obtained by identifying the 3D reference landmarks, lines, and planes to evaluate transverse skeletal (Figure 5A), dentolinar (Figure 5B), and dentoangular measurements in relation to the maxillary plane (Figure 5C).

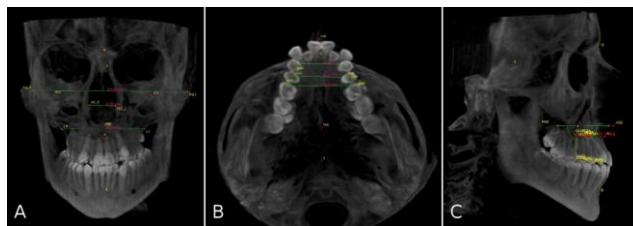


Figure 5: A) Skeletal transverse measurements: facial width (Zyg_R - Zyg_L), nasal width (NC_R - NC_L), and Maxillary width (J_R - J_L); B) Dentolinar measurements: coronal first premolar (UR4-UL4 coronal), coronal second premolar (UR5-UL5 coronal), coronal molar (UR6-UL6 coronal), apical first premolar (UR4-UL4 apical), apical second premolar (UR5-UL5 apical), and apical molar widths (UR6-UL6 apical); C) Dentoangular measurements: external buccopalatal inclination angle of the maxillary right and left first premolars (UR4 BP incl, UL4 BP incl), the maxillary right and left second premolars (UR5 BP incl, UL5 BP incl), and the maxillary right and left first permanent molars (UR6 BP incl, UL6 BP incl) in relation to the maxillary plane. The arrow indicates the external buccopalatal inclination angle of the upper right first premolar

Statistical analysis was performed using SPSS for Windows, version 22 (SPSS Inc., Chicago, Illinois, USA). Shapiro-Wilk test was used to

determine whether the variables were normally distributed or not, while Levene's test was used to assess the homogeneity of variances. Data were shown as mean \pm standard deviation (SD). While the differences between pre- and post-treatment measurements for normally distributed parameters were analysed by the paired-samples t-test, Wilcoxon signed-rank test was used for not normally distributed parameters (U5 apical width, UR4 inclination, and UL5 inclination). The mean differences between the two groups for normally distributed parameters were compared by the independent t-test, and Mann-Whitney test was used for not normally distributed data. A *P* value less than 0.05 was considered statistically significant. To calculate the error of measurements, the measurements were repeated 2 weeks later by the same clinician. Cronbach's alpha was calculated for evaluation of intra-observer reliability.

Results

No difference was observed between the two groups regarding the baseline characteristics (age and gender) (Table 1). No dropouts were reported in the two groups. Loosening of the appliance occurred in two patients in the RME group and one patient in the PARME group.

Table 2: Descriptive statistics and dentoskeletal changes for PARME and RME

	PARME			RME		
	T1 Mean \pm SD	T2 Mean \pm SD	<i>P</i> value	T1 Mean \pm SD	T2 Mean \pm SD	<i>P</i> value
Skeletal linear measurements (mm)						
Facial width	116.72 \pm 4.75	117.91 \pm 5.44	0.107	114.18 \pm 1.36	115.84 \pm 1.44	0.001*
Nasal width	22.56 \pm 2.86	23.70 \pm 2.90	0.127	23.36 \pm 3.31	25.54 \pm 3.60	0.032*
Maxillary width	60.48 \pm 1.08	63.15 \pm 2.34	0.173	60.96 \pm 8.57	64.77 \pm 8.01	0.018*
Dentoliner measurements (mm)						
UR6-UL6 coronal	45.46 \pm 5.24	51.41 \pm 5.49	0.002*	46.17 \pm 4.06	47.68 \pm 3.71	0.159
UR6-UL6 apical	45.21 \pm 6.97	47.15 \pm 7.54	0.058	45.25 \pm 3.25	45.93 \pm 2.74	0.377
UR5-UL5 coronal	41.26 \pm 4.41	46.92 \pm 4.23	0.012*	40.99 \pm 4.53	42.76 \pm 4.14	0.096
UR5-UL5 apical	36.19 \pm 5.88	38.57 \pm 6.88	0.158	38.17 \pm 5.45	36.58 \pm 2.31	1.000
UR4-UL4 coronal	38.01 \pm 4.45	43.69 \pm 4.16	0.009*	36.93 \pm 3.11	38.71 \pm 3.84	0.096
UR4-UL4 apical	35.39 \pm 4.49	37.60 \pm 5.51	0.075	33.75 \pm 3.69	33.43 \pm 6.38	0.860
Dentoangular measurements (°)						
UR6 BP incl	81.07 \pm 3.76	76.06 \pm 7.28	0.135	80.96 \pm 6.40	79.64 \pm 5.57	0.321
UL6 BP incl	82.03 \pm 2.42	78.66 \pm 2.75	0.023*	81.72 \pm 1.60	80.97 \pm 0.38	0.497
UR5 BP incl	83.88 \pm 3.26	78.96 \pm 7.31	0.174	78.73 \pm 3.96	77.96 \pm 4.48	0.158
UL5 BP incl	78.38 \pm 1.26	73.91 \pm 3.26	0.061	78.89 \pm 4.14	76.92 \pm 3.42	0.109
UR4 BP incl	78.49 \pm 3.66	73.00 \pm 2.03	0.039*	78.26 \pm 2.91	74.61 \pm 2.04	0.067
UL4 BP incl	83.65 \pm 3.68	79.58 \pm 2.93	0.353	81.28 \pm 6.01	79.45 \pm 4.10	0.242

U = Maxillary; R = right; L = left; 6 = first molar; 5 = second premolar; 4 = first premolar; BP = buccopalatal; incl = inclination; *Significant at *P* < 0.05.

We started the expansion again after returning the loosened Hyrax to the pre-activation state and after performing a second piezocision surgery in PARME group to assure the effect of the regional acceleratory phenomenon (RAP). Cronbach's alphas were found to be between 0.765 and 0.987; thus, there was a good to very good intra-observer agreement regarding all measurements.

For the skeletal linear measurements, PARME had non-significant increases, but RME demonstrated statistically significant increases for all transverse skeletal variables (Table 2). In comparison, no statistically significant differences were found (Table 3).

Regarding the dentoliner measurements, the intercoronal widths increased significantly in PARME, while the interapical widths increased insignificantly. In RME, non-significant changes were detected for all dentoliner widths (Table 2). Comparing the two groups, PARME had a greater significant increase for the intercoronal widths and a greater non-significant increase for the interapical widths than RME (Table 3).

Table 3: Comparison of skeletal and dental mean changes between the PARME and RME groups

	PARME		RME		<i>P</i> value
	Mean	SD	Mean	SD	
Skeletal linear measurements (mm)					
Facial width	1.19	0.73	1.65	0.09	0.388
Nasal width	1.14	0.78	2.18	0.69	0.156
Maxillary width	2.67	2.22	3.81	0.91	0.459
Dentoliner measurements (mm)					
UR6-UL6 coronal	5.95	0.50	1.51	1.19	0.004*
UR6-UL6 apical	1.95	0.85	0.68	1.04	0.177
UR5-UL5 coronal	5.67	1.07	1.77	1.03	0.011*
UR5-UL5 apical	2.38	1.87	-1.59	4.32	0.200
UR4-UL4 coronal	5.69	0.96	1.78	1.03	0.009*
UR4-UL4 apical	2.21	1.12	-0.31	2.71	0.209
Dentoangular measurements (°)					
UR6 BP incl	-5.02	3.57	-1.32	1.75	0.182
UL6 BP incl	-3.37	0.90	-0.75	1.58	0.067
UR5 BP incl	-4.91	4.11	-0.77	0.61	0.159
UL5 BP incl	-4.46	2.01	-1.97	3.05	0.400
UR4 BP incl	-5.49	1.94	-3.65	1.73	0.400
UL4 BP incl	-4.07	5.88	-1.83	1.93	0.564

U = Maxillary; R = right; L = left; 6 = first molar; 5 = second premolar; 4 = first premolar; BP = buccopalatal; incl = inclination; *Significant at *P* < 0.05.

Concerning the dentoangular measurements, no statistically significant decrease was seen for the external buccopalatal inclination angle of all teeth in both groups except for the upper left maxillary first molar and upper right first premolar in PARME which showed a significant decrease (Table 2). After comparing the two groups, no statistical significance was detected (Table 3).

Discussion

To the best of our knowledge, this is the first prospective controlled clinical study to address the effects of piezocision on rapid maxillary expansion. All previous studies on this topic were case reports [20], [21], [22].

Although one of these articles [21] reported that the expansion done was rapid, the activation was performed to achieve 1 mm of expansion per week which is considered slow expansion. In addition to the rate of expansion, this report was different from our study in that a fixed appliance was worn during the expansion, banded not bonded expander was used,

and buccal flaps were done to perform the corticotomy on the buccal aspect.

The other two case reports [22] described the correction of a unilateral cross bite by corticotomy-assisted rapid maxillary expansion. One report [20] used fixed orthodontic appliance and quad-helix with the expansion assisted with piezocision on the buccal side, while in the other report, [22] fixed orthodontic appliance with heavy labial arch wire in one case and quad-helix in the second case were used to achieve the expansion which was assisted with corticotomies performed on the buccal and palatal sides after reflection of flaps. Therefore, all previous case reports used slow, not rapid maxillary expansion.

Because piezocision-assisted expansion requires periodontal surgery, it is considered an invasive procedure when compared to the conventional expansion. On the other hand, when piezocision is compared with conventional corticotomy, it is believed to produce less patient discomfort and trauma with the same clinical outcome [18], [23].

With the piezocision surgery, bone remodelling increases at the surgical site which is proportional to the surgical trauma. The activity of osteoblasts and osteoclasts increases which results in a decrease in bone density and an increase in bone turnover. This process facilitates the tooth movement and is called "regional acceleratory phenomenon" (RAP) [24]. The duration of the RAP can last for about four months based on the results two studies, one in humans [25] and the other in dogs [26].

Although the four-months duration is sufficient to perform the expansion in our study, we were very careful to gain the full advantage of the RAP. Therefore, the expansion was started immediately on the day following the surgery.

It can be difficult for the patients to brush around the teeth and the Hyrax; also, the gingival index can change because of the periodontal incisions of the piezocision. Because of this, plaque accumulation can increase around the expander with an increased tendency to develop periodontal problems. Therefore, the patients were informed and educated about oral hygiene.

To standardise the amount of expansion in the two groups, the Hyrax was activated by opening it twice daily (0.5 mm/day) for eleven days to achieve 5.5 mm expansion which is enough to achieve over correction in all patients.

During taking the CBCT scans, the patients were instructed to wear 2 mm thickness intra-oral splint to separate the two jaws and allow for measurements to be made in the axial plane.

In the present study, the period between the two CBCT scans was 3 months which is not enough for the growth changes to be combined with treatment

effects; therefore, the growth was not a confounding factor.

For the skeletal linear (transverse) changes, RME showed significant increases in the mean facial, nasal, and maxillary widths. On the other hand, PARME showed a non-significant increase with no significant difference between the two groups. These changes might be attributed to lateral rotation of the two maxillary halves around the estimated centre of rotation located in the area of the frontonasal suture and the rear mid-palatal suture as a result of the lateral displacement and the stress distribution that occurred along the sutures of the circummaxillary structures [27], [28]. Also, these results may support the theory that maxillary expansion increases the airflow and improves nasal breathing [6], [29].

Regarding the facial width, our results were in agreement with Perillo et al., 2014 [30] for PARME and in disagreement for RME. Concerning the nasal and maxillary widths, Chung and Font, 2004 [31]; Gungor et al., 2012 [32]; Gopalakrishnan and Sridhar, 2017 [33]; Baratieri et al., 2014 [34]; Altug, Karasu, and Aytac, 2006 [35]; Perillo et al., 2014 [30]; Corekci and Goyenc., 2013 [36]; and Cordasco et al., 2012 [37] showed results consistent to ours for RME and inconsistent for PARME.

Regarding the dental transverse changes, PARME showed a significant increase in the coronal widths, and RME showed a non-significant increase for all teeth. By comparing the two groups, there was a significant difference. These results indicated that PARME produced more dental expansion than did RME.

The increased dental expansion in PARME as compared to RME conforms to the biological mechanism of RAP, which is characterised by transient bone demineralisation and increased bone metabolism.

The results of Baratieri et al., 2014 [34]; Perillo et al., 2014 [30]; Grassia et al., 2015 [38]; Corekci and Goyenc, 2013 [36]; Weissheimer et al., 2011 [39]; and Gunyuz, Germec-Cakan, and Tozlu, 2015 [40] agreed with our results for PARME but disagreed for RME.

On the other hand, our study showed a non-significant increase in the apical widths of studied teeth in the two groups. Also, there was no significant change between the two groups.

The insignificant increase in the apical width of most teeth found in our study was in disagreement with the significant increase found in Weissheimer et al., 2011 [39] and Gunyuz, Germec-Cakan, and Tozlu, 2015 [40].

The increase in the coronal widths was more than the increase in the apical widths in the two groups. These results demonstrated the controlled tipping of those teeth and the pyramidal nature of the

expansion with the base of the pyramid located at the oral side of the bone [41].

Concerning the buccolingual inclination of the expanded teeth, the two groups showed a statistically non-significant decrease (of the external angle) of the expanded teeth. This decrease could be attributed to buccal tipping of the expanded teeth, bending of the alveolar bone [42] and outward rotational movement of the two maxillary halves [10].

The insignificant increase in Bucco-palatal inclination found in this study agreed with that of Gunyuz, Germec-Cakan, and Tozlu, 2015 [40], but disagreed with the significant increase reported in Baratieri et al., 2014 [34]; Weissheimer et al., 2011 [39]; Kilic, Kiki, and Oktay, 2008 [43]; and Christie, Boucher, and Chung, 2010 [44].

In conclusion, PARME is effective in treating posterior crossbite. PARME produced significantly more coronal dental expansion than did RME. Non-significant difference was found for the skeletal transverse, dentoliner apical, and dentoangular variables between the two groups. Because of the more dental expansion produced by PARME as compared to the conventional RME, PARME should be limited only to mild or moderate not severe forms of palatal constriction. The available evidence regarding the effectiveness of corticotomy- and/or piezocision-assisted maxillary expansion for correction of posterior crossbite is limited and inadequate.

References

- McNamara JA. Maxillary transverse deficiency. *American journal of orthodontics and dentofacial orthopedics*. 2000; 117(5):567-70. [https://doi.org/10.1016/S0889-5406\(00\)70202-2](https://doi.org/10.1016/S0889-5406(00)70202-2)
- Malandris M, Mahoney EK. Aetiology, diagnosis and treatment of posterior cross-bites in the primary dentition. *International journal of paediatric dentistry*. 2004; 14(3):155-66. <https://doi.org/10.1111/j.1365-263X.2004.00546.x> PMID:15139950
- Betts NJ, Vanarsdall RL, Barber HD, Higgins-Barber K, Fonseca RJ. Diagnosis and treatment of transverse maxillary deficiency. *The International journal of adult orthodontics and orthognathic surgery*. 1995; 10(2):75-96. PMID:9082002
- Baccetti T, Franchi L, Cameron CG, McNamara JA, Jr. Treatment timing for rapid maxillary expansion. *The Angle orthodontist*. 2001; 71(5):343-50. PMID:11605867
- Suri L, Taneja P. Surgically assisted rapid palatal expansion: a literature review. *American journal of orthodontics and dentofacial orthopedics*. 2008; 133(2):290-302. <https://doi.org/10.1016/j.ajodo.2007.01.021> PMID:18249297
- Haas AJ. Rapid expansion of the maxillary dental arch and nasal cavity by opening the midpalatal suture. *The Angle orthodontist*. 1961; 31(2):73-90.
- Haas AJ. The treatment of maxillary deficiency by opening the midpalatal suture. *The Angle orthodontist*. 1965; 35:200-17. PMID:14331020
- Haas AJ. Palatal expansion: just the beginning of dentofacial orthopedics. *American journal of orthodontics*. 1970; 57(3):219-55. [https://doi.org/10.1016/0002-9416\(70\)90241-1](https://doi.org/10.1016/0002-9416(70)90241-1)
- Haas AJ. Long-term posttreatment evaluation of rapid palatal expansion. *The Angle orthodontist*. 1980; 50(3):189-217. PMID:6996533
- Bishara SE, Staley RN. Maxillary expansion: clinical implications. *American journal of orthodontics and dentofacial orthopedics*. 1987; 91(1):3-14. [https://doi.org/10.1016/0889-5406\(87\)90202-2](https://doi.org/10.1016/0889-5406(87)90202-2)
- Proffit WR, Fields HW, Sarver DM, Ackerman JL. *Contemporary Orthodontics*. 5th ed, 2013.
- Kole H. Surgical operations on the alveolar ridge to correct occlusal abnormalities. *Oral Surgery, Oral Medicine, Oral Pathology, and Oral Radiology*. 1959; 12(5):515-29. [https://doi.org/10.1016/0030-4220\(59\)90153-7](https://doi.org/10.1016/0030-4220(59)90153-7)
- Converse JM, Horowitz SL. The surgical-orthodontic approach to the treatment of dentofacial deformities. *American journal of orthodontics*. 1969; 55(3):217-43. [https://doi.org/10.1016/0002-9416\(69\)90104-3](https://doi.org/10.1016/0002-9416(69)90104-3)
- Lines PA. Adult rapid maxillary expansion with corticotomy. *American journal of orthodontics*. 1975; 67(1):44-56. [https://doi.org/10.1016/0002-9416\(75\)90128-1](https://doi.org/10.1016/0002-9416(75)90128-1)
- Wilcko WM, Wilcko T, Bouquet JE, Ferguson DJ. Rapid orthodontics with alveolar reshaping: two case reports of decrowding. *The International journal of periodontics & restorative dentistry*. 2001; 21(1):9-19.
- Park YG, Kang SG, Kim SJ. Accelerated tooth movement by corticision as an osseous orthodontic paradigm. *Kinki Tokai Kyosei Shika Gakkai Gakujuyutsu Taikai, Sokai*. 2006; 48:6.
- Vercellotti T, Podesta A. Orthodontic microsurgery: a new surgically guided technique for dental movement. *The International journal of periodontics & restorative dentistry*. 2007; 27(4):325-31.
- Dibart S, Sebaoun JD, Surmenian J. Piezocision: a minimally invasive, periodontally accelerated orthodontic tooth movement procedure. *Compendium of continuing education in dentistry (Jamesburg, NJ: 1995)*. 2009; 30(6):342-4.
- Hassan AH, Al-Saeed SH, Al-Maghlouth BA, Bahammam MA, Linjawi AI, El-Bialy TH. Corticotomy-assisted orthodontic treatment. A systematic review of the biological basis and clinical effectiveness. *Saudi medical journal*. 2015; 36(7):794-801. <https://doi.org/10.15537/smj.2015.7.12437> PMID:26108582 PMID:PMC4503897
- Bakathir MA, Hassan AH, Bahammam MA. Piezocision as an adjunct to orthodontic treatment of unilateral posterior crossbite. *Saudi medical journal*. 2017; 38(4):425-30. <https://doi.org/10.15537/smj.2017.4.16390> PMID:28397951 PMID:PMC5447197
- Echchadi ME, Benchikh B, Bellamine M, Kim SH. Corticotomy-assisted rapid maxillary expansion: A novel approach with a 3-year follow-up. *American journal of orthodontics and dentofacial orthopedics*. 2015; 148(1):138-53. <https://doi.org/10.1016/j.ajodo.2014.08.023> PMID:26124037
- Hassan AH, AlGhamdi AT, Al-Fraidi AA, Al-Hubail A, Hajrassy MK. Unilateral cross bite treated by corticotomy-assisted expansion: two case reports. *Head & face medicine*. 2010; 6(1):6. <https://doi.org/10.1186/1746-160X-6-6> PMID:20482859 PMID:PMC2893126
- Sebaoun JD, Surmenian J, Dibart S. Accelerated orthodontic treatment with piezocision: a mini-invasive alternative to conventional corticotomies. *L'Orthodontie francaise*. 2011; 82(4):311-9. <https://doi.org/10.1051/orthodfr/2011142> PMID:22105680
- Dibart S, Keser E, Nelson D. Piezocision™-assisted orthodontics: Past, present, and future. *Seminars in Orthodontics*. 2015; 21(3):170-5. <https://doi.org/10.1053/j.sodo.2015.06.003>
- Aboul-Ela SM, El-Beialy AR, El-Sayed KM, Selim EM, El-Mangoury NH, Mostafa YA. Miniscrew implant-supported maxillary canine retraction with and without corticotomy-facilitated

- orthodontics. American journal of orthodontics and dentofacial orthopedics. 2011; 139(2):252-9. <https://doi.org/10.1016/j.ajodo.2009.04.028> PMID:21300255
26. Sanjideh PA, Rossouw PE, Campbell PM, Opperman LA, Buschang PH. Tooth movements in foxhounds after one or two alveolar corticotomies. European journal of orthodontics. 2010; 32(1):106-13. <https://doi.org/10.1093/ejo/cjp070> PMID:19736219
27. Asanza S, Cisneros GJ, Nieberg LG. Comparison of Hyrax and bonded expansion appliances. The Angle orthodontist. 1997; 67(1):15-22. PMID:9046395
28. Akkaya S, Lorenzon S, Ucem TT. Comparison of dental arch and arch perimeter changes between bonded rapid and slow maxillary expansion procedures. European journal of orthodontics. 1998; 20(3):255-61. <https://doi.org/10.1093/ejo/20.3.255> PMID:9699403
29. Basciftci FA, Mutlu N, Karaman AI, Malkoc S, Kucukkolbasi H. Does the timing and method of rapid maxillary expansion have an effect on the changes in nasal dimensions? The Angle orthodontist. 2002; 72(2):118-23. PMID:1199934
30. Perillo L, De Rosa A, Iaselli F, d'Apuzzo F, Grassia V, Cappabianca S. Comparison between rapid and mixed maxillary expansion through an assessment of dento-skeletal effects on posteroanterior cephalometry. Progress in orthodontics. 2014; 15:46. <https://doi.org/10.1186/s40510-014-0046-9> PMID:25139110 PMID:PMC4138550
31. Chung CH, Font B. Skeletal and dental changes in the sagittal, vertical, and transverse dimensions after rapid palatal expansion. American journal of orthodontics and dentofacial orthopedics. 2004; 126(5):569-75. <https://doi.org/10.1016/j.ajodo.2003.10.035>
32. Gungor AY, Turkkahraman H, Baykul T, Alkis H. Comparison of the effects of rapid maxillary expansion and surgically assisted rapid maxillary expansion in the sagittal, vertical, and transverse planes. Medicina Oral Patologia Oral y Cirugia Bucal. 2012; 17(2):e311-9. <https://doi.org/10.4317/medoral.17389> PMID:22143686 PMID:PMC3448316
33. Gopalakrishnan U, Sridhar P. Assessment of the dental and skeletal effects of fan-type rapid maxillary expansion screw and Hyrax screw on craniofacial structures. Contemporary clinical dentistry. 2017; 8(1):64-70. <https://doi.org/10.4103/0976-237X.205066> PMID:28566854 PMID:PMC5426169
34. Baratieri Cda L, Alves M, Jr., Mattos CT, Lau GW, Nojima LI, de Souza MM. Transverse effects on the nasomaxillary complex one year after rapid maxillary expansion as the only intervention: a controlled study. Dental press journal of orthodontics. 2014; 19(5):79-87. <https://doi.org/10.1590/2176-9451.19.5.079-087.oar> PMID:25715720 PMID:PMC4296650
35. Altug Atac AT, Karasu HA, Aytac D. Surgically assisted rapid maxillary expansion compared with orthopedic rapid maxillary expansion. The Angle orthodontist. 2006; 76(3):353-9. PMID:16637711
36. Corekci B, Goyenc YB. Dentofacial changes from fan-type rapid maxillary expansion vs traditional rapid maxillary expansion in early mixed dentition. The Angle orthodontist. 2013; 83(5):842-50. <https://doi.org/10.2319/103112-837.1> PMID:23387338
37. Cordasco G, Nucera R, Fastuca R, Matarese G, Lindauer SJ, Leone P, et al. Effects of orthopedic maxillary expansion on nasal cavity size in growing subjects: a low dose computer tomography clinical trial. International journal of pediatric otorhinolaryngology. 2012; 76(11):1547-51. <https://doi.org/10.1016/j.ijporl.2012.07.008> PMID:22840779
38. Grassia V, d'Apuzzo F, Jamilian A, Femiano F, Favero L, Perillo L. Comparison between rapid and mixed maxillary expansion through an assessment of arch changes on dental casts. Progress in orthodontics. 2015; 16:20. <https://doi.org/10.1186/s40510-015-0089-6> PMID:26122076 PMID:PMC4484519
39. Weissheimer A, de Menezes LM, Mezomo M, Dias DM, de Lima EM, Rizzato SM. Immediate effects of rapid maxillary expansion with Haas-type and hyrax-type expanders: a randomized clinical trial. American journal of orthodontics and dentofacial orthopedics. 2011; 140(3):366-76. <https://doi.org/10.1016/j.ajodo.2010.07.025> PMID:21889081
40. Gunyuz Toklu M, Germec-Cakan D, Tozlu M. Periodontal, dentoalveolar, and skeletal effects of tooth-borne and tooth-bone-borne expansion appliances. American journal of orthodontics and dentofacial orthopedics. 2015; 148(1):97-109. <https://doi.org/10.1016/j.ajodo.2015.02.022> PMID:26124033
41. Ladner PT, Muhl ZF. Changes concurrent with orthodontic treatment when maxillary expansion is a primary goal. American journal of orthodontics and dentofacial orthopedics. 1995; 108(2):184-93. [https://doi.org/10.1016/S0889-5406\(95\)70082-X](https://doi.org/10.1016/S0889-5406(95)70082-X)
42. Garrett BJ, Caruso JM, Rungcharassaeng K, Farrage JR, Kim JS, Taylor GD. Skeletal effects to the maxilla after rapid maxillary expansion assessed with cone-beam computed tomography. American journal of orthodontics and dentofacial orthopedics. 2008; 134(1):8-9. <https://doi.org/10.1016/j.ajodo.2008.06.004> PMID:18617096
43. Kilic N, Kiki A, Oktay H. A comparison of dentoalveolar inclination treated by two palatal expanders. European journal of orthodontics. 2008; 30(1):67-72. <https://doi.org/10.1093/ejo/cjm099> PMID:18276928
44. Christie KF, Boucher N, Chung CH. Effects of bonded rapid palatal expansion on the transverse dimensions of the maxilla: a cone-beam computed tomography study. American journal of orthodontics and dentofacial orthopedics. 2010; 137(4 Suppl):S79-85. <https://doi.org/10.1016/j.ajodo.2008.11.024> PMID:20381765