

Retrieval of Intravascular Fractured Fragment of Tunnelled Double Lumen Catheter in Hemodialysis Patient

I Nyoman Semadi¹, Heru Sutanto Koerniawan², Hendry Irawan^{2*}

¹Thorax and Cardiovascular Surgery Division, Surgery Department, Faculty of Medicine, Udayana University, Sanglah General Hospital, Denpasar, Indonesia; ²Surgery Department, Faculty of Medicine, Udayana University, Sanglah General Hospital, Denpasar, Indonesia

Abstract

Citation: Semadi IN, Koerniawan HS, Irawan H. Retrieval of Intravascular Fractured Fragment of Tunnelled Double Lumen Catheter in Hemodialysis Patient. Open Access Maced J Med Sci. <https://doi.org/10.3889/oamjms.2019.025>

Keywords: Double lumen catheter; Intravascular fractured fragment; Retrieval; Surgical venous cut-down

***Correspondence:** Hendry Irawan, Surgery Department, Faculty of Medicine, Udayana University, Sanglah General Hospital, Denpasar, Indonesia. E-mail: hendry_irawan@rocketmail.com

Received: 28-Oct-2018; **Revised:** 04-Dec-2018; **Accepted:** 05-Dec-2018; **Online first:** 11-Jan-2019

Copyright: © 2019 I Nyoman Semadi, Heru Sutanto Koerniawan, Hendry Irawan. This is an open-access article distributed under the terms of the Creative Commons Attribution-NonCommercial 4.0 International License (CC BY-NC 4.0)

Funding: This research did not receive any financial support

Competing Interests: The authors have declared that no competing interests exist

BACKGROUND: Intravascular fractured fragment of double lumen catheter with embolisation is a serious and rare complication. Another serious complication includes infection, thrombosis, arrhythmias, and pulmonary embolism. We report a successful surgical venous cut-down technique in the retrieval of an intravascular fractured fragment of tunnelled double lumen catheter in a hemodialysis patient.

CASE REPORT: A 51-year-old female underwent hemodialysis through a tunnelled double lumen catheter and had her arterio-venous graft matured. During retrieval of tunnelled double lumen catheter procedure, the distal part of the catheter was fractured and slipped into the internal jugular vein. Chest radiograph revealed intravascular double lumen catheter extending from the distal part of the right internal jugular vein to right atrium. The procedure of foreign body retrieval was done the next day under general anaesthesia and C-Arm guidance using right internal jugular venous cut-down approach. A right-angle clamp was used to retrieve the fragment without any post-procedure complications.

CONCLUSION: Intravascular fractured fragment of double lumen catheter is a dangerous situation as are all the intravascular foreign bodies. The choices of the technique for retrieval of the fractured fragment are varied. It depends on the type and site of a fractured fragment as well as the surgeon experiences.

Introduction

Central venous catheter (CVC) is used for the administration of drugs, hemodialysis, hemodynamic measurement, as well as cardiac pacing. The complication of foreign bodies is closely associated with the development of the intravascular catheter technique in 1945 by Meyers. In some case especially in trauma, CVC can be used using large bore to deliver fluid resuscitation. In the United States, more than 5 million of the central venous catheter are inserted every year, and the device drop behind is due to loss of wire or fractured fragment due to inexperience [1]. Various studies have been

performed and suggest that one of the causes of CVC fracture is huge traction force needed to retrieve CVC due to fibrin sheath formation around the CVC [1]. Complications of CVC are a fractured catheter, thrombosis, or even vein perforation (though it is rare). The danger of intravascular foreign bodies was formally recognised by the Federal Drug Administration in a 2008 public health announcement [2]. The authors report a case of an intravascular fractured fragment of tunnelled double lumen catheter in a hemodialysis patient. It was successful retrieval under C-Arm guidance using surgical venous cut-down of the right internal jugular vein.

Case Report

A 51-year-old female was admitted due to complaints of weakness as well as planning to have brachytherapy for her cervical cancer treatment. She was diagnosed with cervical cancer stage III-b with chronic kidney diseases caused by obstructive nephropathy because of the malignancy infiltration of primary cervical cancer. After underwent arterio-venous graft 10 weeks before, a tunnelled double lumen catheter for hemodialysis was accidentally fractured during its retrieval from the skin. The patient was asymptomatic. However, chest radiograph demonstrated of a long radio-opaque double lumen hemodialysis catheter fragment from the end of right internal jugular vein at the junction to the superior vena cava and lodge in this site (Figure 1). The distal tip was at the right atrium.

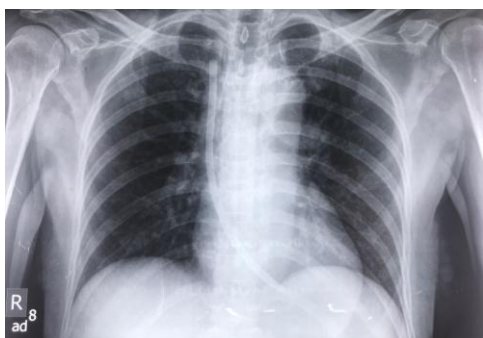


Figure 1: Chest radiograph before surgery

The patient then was planned for retrieval of the catheter. The patient and her husband, as well as her daughter, were discussed, and a small open trans-jugular retrieval technique via the right internal jugular vein was chosen. Informed consent was obtained from her daughter as well as verbal consent from her husband (due to distance and location of the husband).

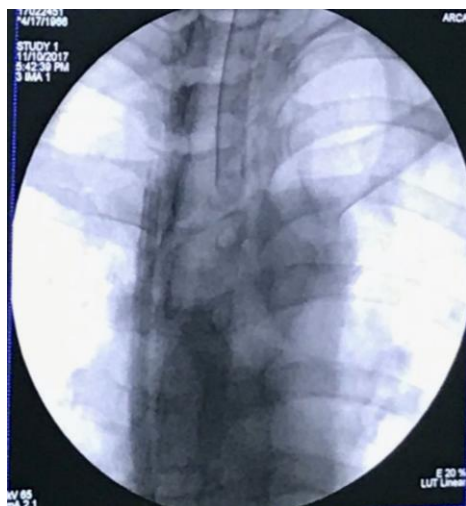


Figure 2: Radiology image shows the location of a fractured fragment of double lumen catheter in the clavicular level of the right internal jugular vein

The procedure was performed under general anaesthesia and C-Arm guidance. Intravenous antibiotic (cefazolin 2 gram) was administered during the procedure and first 24 hours after surgery. About 7 cm Golf stick incision was made at the right Sedillot's triangle. The incision was done until the internal jugular vein was exposed. Purse string was made around prior incision with 4-0 non-absorbable monofilament suture. Under C-arm guidance (Figure 2), a mixer right angle clamp was inserted to retrieve the distal tip of dislodging double lumen catheter. The fractured fragment of the catheter can be retrieved smoothly (Figure 3). The purse sting then tightened. The extravasation from vein was evaluated. The total procedure time was 35 minutes and C-arm time was 5 minutes.

After the procedure, the patient was monitored, electrocardiogram and examination were normal. There were not any major or minor complications such as arrhythmia, bleeding, vascular or cardiac perforation or local hematoma were observed during or after the procedure.

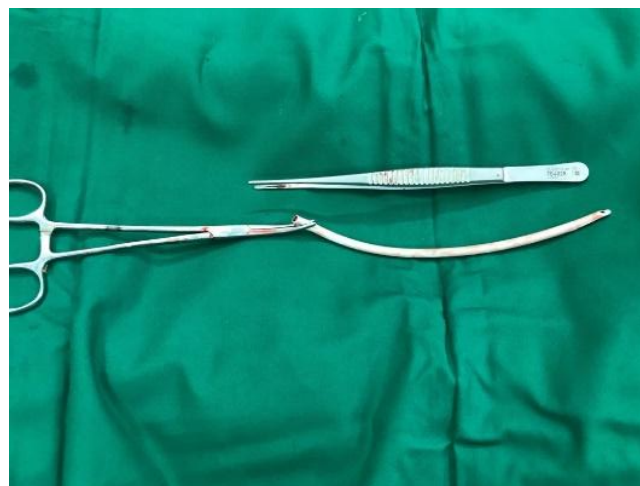

Figure 3: Foreign body of a fractured fragment of double lumen catheter after retrieval

Discussion

We report a case of a patient with a fractured fragment of double lumen catheter for hemodialysis in the right internal jugular vein, which was successfully retrieved using open jugular approach retrieval technique. The main complication of any vein catheter insertion was bloodstream infection and venous thrombosis, and mechanical (such as arterial puncture, nerve injury, air embolism, and hemothorax or pneumothorax between 5% and 19%) [3], [4]. Fractured fragment of the catheter with or without embolisation was a serious but rare complication in a patient [3], [4], [5]. There a few cases of cardiac

tamponade following a fractured fragment of a catheter. Although it was seldom occurred, a fractured intravascular catheter might cause thrombosis in the right atrium [2], [6]. The complication also included cardiac perforation [7].

Improper procedure handling was the most common cause of fractured fragment of a catheter [3]. The previous study suggested that the silicone catheter could be a risk factor for fractured and migration of the catheter [7]. Some mechanisms played a role in the pathogenesis of catheter embolism. According to the literature, the pinch-off syndrome was a frequent cause of catheter injury with an incident 1.1%. The port separation of a catheter from chamber or cuff or disconnection was another mechanism of catheter embolism with incident estimated to be in the range from 0.2 to 1.7% [5]. Incorrect locking of the catheter connection has also been suspected as a cause [5].

Significant complications had formerly reported include fractured of a catheter in the central vein, metal guide wires, pacemaker electrodes port-A fragment, and vascular stents. Retrieval of a fractured fragment of the catheter from the central vein as quickly as possible was needed because the complications might be potentially life-threatening. Complication such as sepsis, Pulmonary embolism, and abscess formation was reported [7], [8], [9]. If a fractured fragment of the catheter was free floating intravascular, a percutaneous retrieval technique is the method of choice. Percutaneous intravascular foreign body retrieval was a safe and effective method of retrieval embolized fragments from venous access devices even in children [7].

If the fractured fragment was remained at the point of skin entry or stay in the vein that can be accessed superficially, a surgical cut-down technique might be preferred as a first approach [6]. The decision of retrieval of the intravascular fractured fragment was often based on the shape, size, and location. The smooth-edged intracardiac foreign body can be treated non-operatively. Sometimes the retained shaped-edged foreign body can remain asymptomatic for a long time, and suggest complete fixation of the metallic foreign body to the cavity wall and further retrieval may not be needed [10], [11]. However, when an intravascular foreign body is identified, endovascular retrieval should be attempted due to its high success rate and minimal morbidity [1].

In our case, a chest radiograph revealed that the catheter fragment stays in the right internal jugular vein near the junction with superior vena cava. We decided to choose the venous cut-down technique. The catheter fragment was able to be retrieved easily under C-Arm guidance successfully without any complications.

In conclusion, an intravascular fractured

fragment of double lumen catheter is a dangerous situation as are all intravascular foreign bodies. They should be managed at the earliest by knowing the exact site of the foreign body using chest radiograph. Intravascular catheter fragment with or without embolisation might cause fatal complication (though it was rare), and they should be retrieved in most instance. There were many methods to retrieve an intravascular fractured fragment of the catheter, including venous cut-down, percutaneous transcatheter retrieval with loop snare, or even thoracotomy or sternotomy. The choices of the technique for retrieval of the fractured fragment are varied. It depends on the type and site of a fractured fragment as well as the surgeon experiences.

References

- Carroll MI, Ahanchi SS, Kim JH, Panneton JM. Endovascular foreign body retrieval. *J Vasc Surg.* 2013; 57:459-63. <https://doi.org/10.1016/j.jvs.2012.01.092> PMID:23069073
- Fischer RA. Danger: Beware of unretrieved device fragments. *Nursing.* 2007; 37:17. <https://doi.org/10.1097/01.NURSE.0000298180.71588.13> PMID:17968245
- Ghaderian M, Sabri MR, Ahmadi AR. Percutaneous retrieval of an intracardiac central venous port fragment using snare with triple loops. *J Res Med Sci.* 2015; 20:97-9. PMID:25767529 PMID:PMC4354073
- Hu CC, Lin SC, Huang PH, Tseng SS, Tarng DC. A lady with a broken hemodialysis catheter fragment. *Nephrol Dial Transplant.* 2002; 17:1126-8. <https://doi.org/10.1093/ndt/17.6.1126>
- Surov A, Buerke M, John E, Kösling S, Spielmann RP, Behrmann C. Intravenous Port Catheter Embolization: Mechanism, Clinical Features, and Management. *Angiology.* 2008; 59:90-7. <https://doi.org/10.1177/0003319707303883> PMID:18319228
- Park SK, Yi IK, Lee JH, Kim DH, Lee SY. Fracture of J-tipped guidewire during central venous catheterization and its successful removal under fluoroscopic guidance -A case report-. *Korean J Anesthesiol.* 2012; 63:457-60. <https://doi.org/10.4097/kjae.2012.63.5.457> PMID:23198042 PMID:PMC3506858
- Cahill AM, Ballah D, Hernandez P, Fontalvo L. Percutaneous retrieval of intravascular venous foreign bodies in children. *Pediatr Radiol.* 2012; 42:24-31. <https://doi.org/10.1007/s00247-011-2150-z> PMID:22179682
- Singh A, Kaur A, Singh M, Kaur S. CT Guided Removal of Iatrogenic Foreign Body: A Broken Intravenous Cannula. *J Clin Diagn Res.* 2015; 9:PD28-9. <https://doi.org/10.7860/JCDR/2015/14344.6549>
- Cheung E, Baerlocher MO, Asch M, Myers A. Venous access: a practical review for 2009. *Can Fam Physician.* 2009; 55:494-6. PMID:19439704 PMID:PMC2682308
- Liu H, Juan Y-H, Wang Q, Lin Y-C, Liang C, Zhang X, et al. Foreign body venous transmigration to the heart. *QJM.* 2014; 107:743-5. <https://doi.org/10.1093/qjmed/hcu052> PMID:24623859
- Agarwal A, Quraishi MB, Mufti OI. Retained Nail in the Heart. *J Am Coll Cardiol.* 2012; 60:75. <https://doi.org/10.1016/j.jacc.2011.11.075> PMID:22742404