

Efficacy of Oral Isotretinoin in Combination with Desloratadine in the Treatment of Common Vulgaris Acne in Vietnamese Patients

Thuong Nguyen Van^{1,2}, Lan Duong Thi¹, Hao Nguyen Trong³, Tro Chau Van⁴, Trang Trinh Minh¹, Phuong Pham Thi Minh¹, Nghi Dinh Huu^{1,2}, Van Tran Cam¹, My Le Huyen¹, Khang Tran Hau^{1,2}, Marco Gandolfi⁵, Francesca Satolli⁵, Claudio Feliciani⁵, Michael Tirant^{6,7}, Aleksandra Vojvodic⁸, Torello Lotti⁶

¹National Hospital of Dermatology and Venereology, Hanoi, Vietnam; ²Hanoi Medical University, Vietnam; ³Dermatology and Venereology Hospital of Ho Chi Minh City, Ho Chi Minh City, Vietnam; ⁴Pham Ngoc Thach Medical University of Ho Chi Minh City, Ho Chi Minh City, Vietnam; ⁵Unit of Dermatology, University of Parma, Parma, Italy; ⁶University of Rome G. Marconi, Rome, Italy; ⁷Psoriasis Eczema Clinic, Melbourne, Australia; ⁸Department of Dermatology and Venereology, Military Medical Academy of Belgrade, Belgrade, Serbia

Abstract

Citation: Van TN, Duong Thi L, Nguyen Trong H, Chau Van T, Trinh Minh T, Thi Minh PP, Dinh Huu N, Tran Cam V, Le Huyen M, Tran Hau K, Gandolfi M, Satolli F, Feliciani C, Tirant M, Vojvodic A, Lotti T. Efficacy of Oral Isotretinoin in Combination with Desloratadine in the Treatment of Common Vulgaris Acne in Vietnamese Patients. Open Access Maced J Med Sci. 2019 Jan 30; 7(2):217-220. <https://doi.org/10.3889/oamjms.2019.054>

Keywords: Common acne; Isotretinoin; Desloratadine

***Correspondence:** Marco Gandolfi, Unit of Dermatology, University of Parma, Parma, Italy. E-mail: marco.gandolfi5@gmail.com

Received: 02-Jan-2019; **Revised:** 16-Jan-2019; **Accepted:** 17-Jan-2019; **Online first:** 25-Jan-2019

Copyright: © 2019 Thuong Nguyen Van, Lan Duong Thi, Hao Nguyen Trong, Tro Chau Van, Trang Trinh Minh, Phuong Pham Thi Minh, Nghi Dinh Huu, Van Tran Cam, My Le Huyen, Khang Tran Hau, Marco Gandolfi, Francesca Satolli, Claudio Feliciani, Michael Tirant, Aleksandra Vojvodic, Torello Lotti. This is an open-access article distributed under the terms of the Creative Commons Attribution-NonCommercial 4.0 International License (CC BY-NC 4.0)

Funding: This research did not receive any financial support

Competing Interests: The authors have declared that no competing interests exist

AIM: To evaluate the efficacy of oral isotretinoin used alone and in combination with desloratadine in the treatment of moderate acne vulgaris.

METHODS: A comparative clinical trial was undertaken to evaluate the efficacy of oral isotretinoin alone and in combination with desloratadine in the treatment of 62 moderate acne vulgaris patients. Patients were randomised into two groups with 31 patients in each group. Each studied group's patient took 20 mg isotretinoin and 5 mg desloratadine per day. In the control group, patients took only 20 mg isotretinoin per day. The treatment time was 16 weeks. The evaluation and follow-up were done at week 2, 4, 8, 12 and 16 of the treatment.

RESULTS: The studied group had a better curative rate than the control group (45.2% versus 22.6%). The average number of inflammatory lesions in the studied group was significantly lower than the control group (0.19 versus 0.94). The mean GAGS score of the studied group was significantly lower than the control group (3.71 versus 6.52). Acne outbreaks rate of the studied group was lower than the control group (in week 2: 22.6% versus 45.2% and in week 4: 16.1% versus 38.7%, respectively). The rate of itchy was lower in the studied group.

CONCLUSION: In the treatment of moderate acne vulgaris, oral isotretinoin in combination with desloratadine is more effective and has fewer side effects than using isotretinoin alone.

Introduction

Acne is a common skin disease, affecting approximately 85% of adults. The increased secretion of sebum, the follicular hyperkeratosis, the presence of *Propionibacterium acnes* and inflammatory response are the four major factors in the acne pathogenesis [1]. Currently, isotretinoin is the only drug that targets all the causative factors of acne. This medicament is also effective in acne cases unsuccessfully treated with other therapeutic agents.

However, isotretinoin results in some side effects including dry skin cracked lips, erythema and rashes.

Antihistamines H1 have been used for a long time to treat pruritus and allergic conditions. Recently, they have also been used in acne treatment because of their ability to reduce sebum and side effects created by isotretinoin [2]. Some studies also mention the effect of antihistamines in reducing inflammation and preventing acne scars.

In Vietnam, there has been no evaluation study done on the use of antihistamines in acne

treatment.

This study aimed to evaluate the efficacy of oral isotretinoin used alone and in combination with desloratadine in the treatment of moderate acne vulgaris.

Methods

A comparative clinical trial on 62 moderate acne vulgaris patients was conducted at the National Hospital of Dermatology and Venereology, from August 2017 to August 2018.

A group of 62 patients were randomised into 2 equal groups: studied group and control group.

Both groups were treated with isotretinoin 20mg per day in 16 weeks. The combined treatment was 5mg desloratadine daily in 16 weeks for the studied group.

For the evaluation, we counted the number of acne lesions, scoring GAGS (Global Acne Grading System), recording unwanted effects after 2, 4, 8, 12 and 16 weeks of treatment.

Evaluation of acne outbreak during treatment was based on the appearance of new nodules at each re-examination. We used a scale of no outbreak (no new lesion), mild outbreak (< 5 nodules), moderate outbreak (5-10 nodules) and severe outbreak (≥ 10 nodules).

The evaluation of clinical efficacy after 16 weeks of treatment was scaled of:

- Excellent: no inflammation and non-inflammation lesions.
- Good: reduced by $\geq 90\%$ of the number of lesions.
- Fair: reduced by $\geq 75-90\%$ of the number of lesions.
- Moderate: reduced by $\geq 50-75\%$ of the number of lesions.
- Poor: reduced by $<50\%$ of the number of lesions.

Results

General characteristics of the included objects

At the initiation time of treatment, the two groups had similar characteristics regarding patient gender, age, average illness duration, number of

lesions, illness severity and isotretinoin dose, as presented in Table 1.

Table 1: Characteristics of patients in both groups before treatment

Indicator	Studied group (n = 31)	Control group (n = 31)	p
Sex			
Male (n)	11	12	
Female (n)	20	19	p = 0,074
Mean age (years)	21,90 \pm 4,1	22,06 \pm 4,20	p = 0,88
Mean duration of disease (months)	38,74 \pm 34,44	43,16 \pm 26,62	p = 0,55
Mean weight (kg)	52,32 \pm 8,56	57,61 \pm 9,90	p = 0,186
The number of inflammatory lesion	20,29 \pm 1,94	19,58 \pm 8,60	p = 0,172
The number of non-inflammatory lesion	48,90 \pm 29,36	47,87 \pm 25,44	p = 0,345
Total no of lesions	68,87 \pm 35,86	68,45 \pm 28,95	P = 0,182
Mean GAGS score	22,90 \pm 3,11	22,77 \pm 3,03	p = 0,869

Treatment results

Change in the number of inflammatory lesions

In the studied group, the number of inflammatory lesions was significantly lower than that in the control group, with $p < 0.025$ as shown in Figure 1.

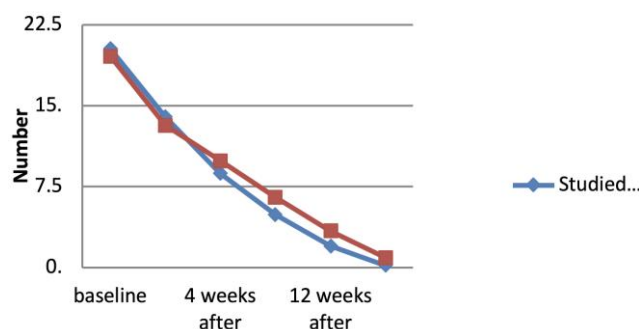


Figure 1: The numbers of inflammatory lesions

Change in the illness severity score

An illness severity score of the studied group was significantly lower than that in the control group from week 4 onwards with $p < 0.05$ as shown in Table 2.

Table 2: Change in the illness severity score

Time	Studied group	Control group	p
Week 0	22.9 \pm 3.11	22.77 \pm 3.03	0.869
Week 2	20.5 \pm 4.22	21.45 \pm 4.31	0.388
Week 4	17.11 \pm 4.22	19.35 \pm 4.70	0.06
Week 8	13.78 \pm 5.48	15.03 \pm 4.11	0.025
Week 12	8.44 \pm 5.40	12.03 \pm 4.27	0.007
Week 16	3.71 \pm 3.81	6.52 \pm 4.35	0.015

Treatment efficacy after 16 weeks

The studied group had 45.2% of acne resolved, higher than that in the control group: 22.6%, with $p < 0.05$ as shown in Figure 2.

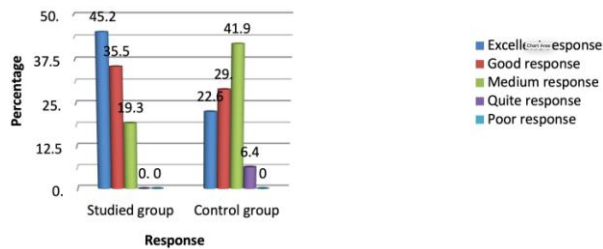


Figure 2: Treatment efficacy after 16 weeks

Unwanted effects

Acne outbreak

The studied group had a significantly lower outbreak rate than that in the control group with $p < 0.05$ at week 2 and 4. At week 16, both groups had no outbreaks.

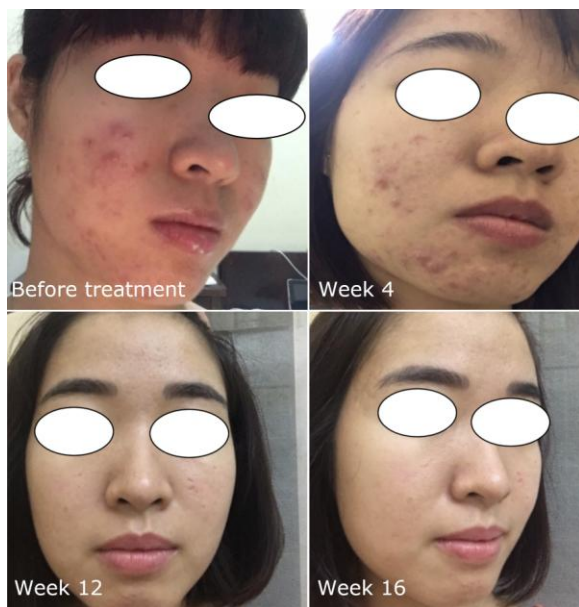

Figure 3: 26 years old female from the studied group (Isotretinoin + Desloratadine)

Other unwanted effects

At the time of follow-up, both groups experienced side effects such as dried skin, dried lips, itching. In the studied group, the rate of itching was significantly lower than the control group (week 2: 12.9%; week 4: 6.2% versus 64.5% in week 2 and 71% in week 4). There was no difference between the two groups regarding side effects such as dried lips, dried skin, flaking and blushing.

Discussion

Studies have shown that inflammation in acne starts very early, even before the appearance of the

lesion and continues at all stages of acne lesion development [3]. Acne inflammation response is due to the release of inflammatory mediators such as histamine and leukotrienes. Therefore, the use of antihistamines can effectively prevent the formation of new acne lesions and have a significant impact on resolving the old acne lesions. In our study, the average number of inflammatory lesions in the studied group was significantly lower than that in the group using only isotretinoin. The reason probably is the combination of anti-inflammatory effects of both retinoids and antihistamines. However, we did not find any difference in the reduction of non-inflammatory lesions between the two groups.

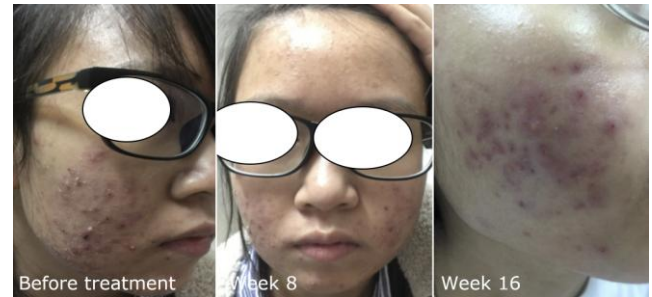


Figure 4: 24 years-old female from the control group (Isotretinoin)

After 16 weeks, the mean GAGS score in the studied group was lower than in the control group (3.71 ± 3.81 vs 6.52 ± 4.35), with $p = 0.015$. In Lee's study, the reduction of GAGS scores in the studied group was seen from week 2. However, the significant difference was just from week 4 onwards [2]. Yosef's study showed similar results [4].

After 16 weeks of treatment, both groups had good outputs: the studied group achieved 45.2% excellent, 35.5% good, and remaining 19.3% fair; the results in the control group were 22.6%, 29%, and 49.1% average response, respectively. However, our results showed that the desloratadine group was better ($p < 0.05$). Experimental studies have shown that desloratadine inhibits inflammatory mediators including IL-4, IL-6, IL-8, IL-13, prostaglandins, leukotriene, tryptase and histamine [5]. Thus, desloratadine acts as an anti-inflammatory role. Also, desloratadine also reduces the formation of squalene, an important component of the sebum [6], [7]. In Lee's study, the studied group had 40% of cases clear, 50% improvement while the control group had 20% of patients clear, 40% improvement [2]. Studies by Dhaher SA and Jasim ZM showed the same results of 50% excellent result, 39.5% good results in the studied group while control group were 31.6% excellent, 34.2% good, 26.3% average and 7.9% poor [8].

Acne outbreaks are common side effects after starting treatment with isotretinoin for 2-4 weeks. The mechanism of the outbreak is unclear, but it is related to the release of *P. acnes* and sebaceous gland antigens, enhancing the inflammatory response [9]. In

our study, the anti-inflammatory effect of antihistamines may have resulted in mild outbreak rate of the studied group: 22.6% at week 2, 16.1 % at week 4, that were lower than those in control group (45.2% and 38.7%, respectively). Similar results were seen in Lee's study [2].

In our study, the itching was less common in the studied group, attributed to the effects of desloratadine.

In conclusion, treating moderate acne vulgaris with oral isotretinoin in combination with antihistamines enhances the curative effectiveness and reduces side effects of itching and acne outbreaks, that is linked with oral isotretinoin intake.

References

1. Knutsen-Larson S, Dawson AL, Dunnick CA, Dellavalle RP. Acne vulgaris: pathogenesis, treatment, and needs assessment. *Dermatologic Clinics*. 2012; 30(1):99-106. <https://doi.org/10.1016/j.det.2011.09.001>
2. Lee HE, Chang IK, Lee Y, Kim CD, Seo YJ, Lee JH, Im M. Effect of antihistamine as an adjuvant treatment of isotretinoin in acne: a randomized, controlled comparative study. *Journal of the European Academy of Dermatology and Venereology*. 2014; 28(12):1654-60. <https://doi.org/10.1111/jdv.12403>
3. Tanghetti EA. The role of inflammation in the pathology of acne. *The Journal of clinical and aesthetic dermatology*. 2013; 6(9):27. PMID:PMC3780801
4. Yosef A, Dawoud NM, Gharib K. Preliminary evaluation of the clinical efficacy of antihistamines as an adjuvant treatment to isotretinoin for acne vulgaris. *Journal of the Egyptian Women's Dermatologic Society*. 2017;14(1):49-55. <https://doi.org/10.1097/01.EWX.0000503398.22746.59>
5. Schroeder JT, Schleimer RP, Lichtenstein LM, Kreutner W. Inhibition of cytokine generation and mediator release by human basophils treated with desloratadine. *Clinical & Experimental Allergy*. 2001; 31(9):1369-77. <https://doi.org/10.1046/j.1365-2222.2001.01130.x>
6. Pelle E, McCarthy J, Seltmann H, Huang X, Mammone T, Zouboulis CC, Maes D. Identification of histamine receptors and reduction of squalene levels by an antihistamine in sebocytes. *Journal of Investigative Dermatology*. 2008; 128(5):1280-5. <https://doi.org/10.1038/sj.jid.5701160>
7. Zouboulis CC, Korge B, Akamatsu H, Xia L, Schiller S, Gollnick H, Orfanos CE. Effects of 13-cis-retinoic acid, all-trans-retinoic acid, and acitretin on the proliferation, lipid synthesis and keratin expression of cultured human sebocytes in vitro. *Journal of investigative dermatology*. 1991; 96(5):792-7. <https://doi.org/10.1111/1523-1747.ep12471782>
8. Dhaher SA, Jasim ZM. The adjunctive effect of desloratadine on the combined azithromycin and isotretinoin in the treatment of severe acne: Randomized clinical trial. *Journal of Dermatology and Dermatologic Surgery*. 2018; 22(1):21-25. https://doi.org/10.4103/jdds.jdds_7_18
9. Clark SM, Cunliffe WJ. Acne flare and isotretinoin-incidence and treatment. *British Journal of Dermatology-Supplement-*. 1995; 133:26.