

# The Efficacy and Safety of Hyaluronic Acid Microinjection for Skin Rejuvenation in Vietnam

Hao Nguyen Trong<sup>1,2</sup>, Thao Vu Thi Phuong<sup>1</sup>, Thuong Nguyen Van<sup>3</sup>, Ha Vu Thai<sup>3</sup>, Nghi Dinh Huu<sup>3</sup>, Minh Vu Nguyet<sup>3</sup>, Khang Tran Hau<sup>3</sup>, Marco Gandolfi<sup>4</sup>, Francesca Satolli<sup>4</sup>, Claudio Feliciani<sup>4</sup>, Michael Tirant<sup>5,6</sup>, Aleksandra Vojvodic<sup>7</sup>, Torello Lotti<sup>5</sup>

<sup>1</sup>HCMS Hospital of Dermato-Venereology, Ho Chi Minh City, Vietnam; <sup>2</sup>Departments of Dermatology, University of Medicine and Pharmacy, Ho Chi Minh City, Vietnam; <sup>3</sup>National Hospital of Dermatology and Venereology, Vietnam; <sup>4</sup>Unit of Dermatology, University of Parma, Parma, Italy; <sup>5</sup>University of Rome G. Marconi, Rome, Italy; <sup>6</sup>Psoriasis Eczema Clinic, Melbourne, Australia; <sup>7</sup>Department of Dermatology and Venereology, Military Medical Academy of Belgrade, Belgrade, Serbia

## Abstract

**Citation:** Nguyen Trong H, Thi Phuong TV, Nguyen Van T, Thai HV, Dinh Huu N, Nguyet MV, Tran Hau K, Gandolfi M, Satolli F, Feliciani C, Tirant M, Vojvodic A, Lotti T. The Efficacy and Safety of Hyaluronic Acid Microinjection for Skin Rejuvenation in Vietnam. Open Access Maced J Med Sci. 2019 Jan 30; 7(2):234-236. <https://doi.org/10.3889/oamjms.2019.059>

**Keywords:** Hyaluronic acid; Microinjection; Skin rejuvenation

**\*Correspondence:** Marco Gandolfi, Unit of Dermatology, University of Parma, Parma, Italy. E-mail: [marco.gandolfi5@gmail.com](mailto:marco.gandolfi5@gmail.com)

**Received:** 02-Jan-2019; **Revised:** 16-Jan-2019; **Accepted:** 17-Jan-2019; **Online first:** 26-Jan-2019

**Copyright:** © 2019 Hao Nguyen Trong, Thao Vu Thi Phuong, Thuong Nguyen Van, Ha Vu Thai, Nghi Dinh Huu, Minh Vu Nguyet, Khang Tran Hau, Marco Gandolfi, Francesca Satolli, Claudio Feliciani, Michael Tirant, Aleksandra Vojvodic, Torello Lotti. This is an open-access article distributed under the terms of the Creative Commons Attribution-NonCommercial 4.0 International License (CC BY-NC 4.0)

**Funding:** This research did not receive any financial support

**Competing Interests:** The authors have declared that no competing interests exist

**BACKGROUND:** Aging is an increasing concern of modern society, particularly facial ageing. In recent years, the microinjection technique has increasingly been emphasised as a skin rejuvenation strategy. Hyaluronic acid (HA) plays an important role in the hydration of the extracellular space and can thus improve skin hydration, firmness and viscoelastic properties.

**AIM:** To evaluate the efficacy and safety of HA microinjection in skin rejuvenation.

**METHODS:** We enrolled thirty participants underwent three sessions of HA microinjection involving multiple injections in the face or back of the hands at 2-week intervals. The aesthetic outcomes were assessed at baseline and after 2, 4 and 8 weeks. Clinical evaluation was based on the Global Aesthetic Improvement Scale (GAIS) and the Wrinkle Severity Rating Scale (WSRS).

**RESULTS:** Evaluation of photographs from 2, 4 and 8 weeks revealed significant clinical improvement in the brightness, texture and wrinkling of the skin. Analysis of the GAIS and WSRS scores revealed statistically significant results after 2 months.

**CONCLUSION:** Most of the participants felt satisfied with the treatment (93.3%).

## Introduction

Ageing is an increasing concern of modern society, particularly facial ageing. This complex process involves two important factors: volume loss in the face and repetitive muscle movements resulting in wrinkles and folds. In recent years, the technique of intradermal microinjection with pharmacologic substances has been emphasised in skin rejuvenation.

This technique aims to restore or maintain youthful and healthy skin structures. The desired effect is firm, bright and moisturised skin via injection of appropriate, completely biocompatible and easily absorbable products into the superficial dermis.

Among the skin rejuvenation microinjection products, hyaluronic acid (HA) plays an important role in hydration of the extracellular space due to its ability to attract water molecules, and HA is thought to give physiological conditions conducive to extracellular matrix production [1], [2].

Some clinical experiments have shown that HA microinjection can stimulate fibroblasts to express collagen type 1 (Col-1), matrix metalloproteinase-1 (MMP-1), and tissue inhibitor of matrix metalloproteinase-1 (TIMP) [2], [3], [4]. This technique is safe when conducted by well-trained dermatologists. However, there have been few clinical studies on HA microinjection in Vietnam. We conducted this study to evaluate the safety and efficacy of HA microinjection in skin rejuvenation.

## Subjects and Methods

This open clinical study was carried out at the HCMC Hospital of Dermato-Venereology. Thirty participants were enrolled in the study from October 2014 to October 2015. The inclusion criteria were as follows: healthy participants who presented with mild/moderate to severe photoaging and were not using any other treatments. Exclusion criteria included previous use of other medical-aesthetical treatments; any cutaneous pathology of infectious, inflammatory, viral and vascular type affecting the face; history of coagulation disorders; wound healing disorders; history of allergy to HA or any ingredient of the test product; and women who were pregnant or breastfeeding. All participants gave informed consent for enrollment in the clinical study.

All participants underwent three sessions of mesotherapy involving multiple microinjections with a 30 G/4 mm needle in the face or back of the hand at 2-week intervals. The study was conducted for 2 months. The photographic evaluation was performed at each treatment and 1 month later after the last session. The results were defined with a score derived from the Global Aesthetic Improvement Scale (GAIS), which was used as a reference parameter (Table 1).

**Table 1: Global Aesthetic Improvement Scale (GAIS)**

Degree	Description
1	Exceptional improvement The excellent corrective result after a session with the VISIA device
2	Very improved patient Marked improvement in appearance, but not completely optimal. A touch-up would slightly improve the result
3	Improved patient Improvement in appearance to better than the initial condition, but a touch-up is advised
4	Unaltered patient The appearance remains substantially the same as the original condition
5	Worsened patient The appearance has become worse than the original condition

Moreover, the Wrinkle Severity Rating Scale (WSRS) was used to evaluate the condition of the wrinkles and, therefore, the degree of ageing (Table 2). The participants were also asked for self-assessment of improvement.

**Table 2: Wrinkle Severity Rating Scale (WSRS)**

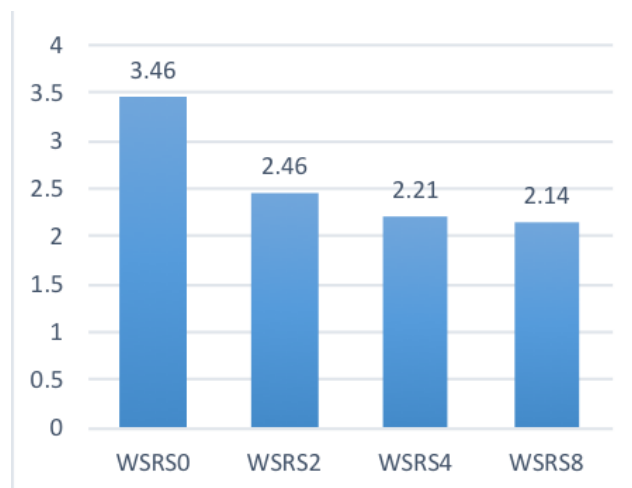
Score	Description
1	Absent
2	Slight
3	Moderate
4	Severe
5	Extreme

## Results

A total of 30 women aged 30-65 years (mean age 46 years) were included in the study. Two participants were lost to follow-up after the first treatment. We had fourteen participants aged 41-50 years (46.7%), which was the most common age group seeking treatment. Most of the participants had

significant improvement after the first treatment (50%), and the improvement continued to increase after the second (70%) and third treatments (83.3%), as indicated by the GAIS evaluation.

The difference between the GAIS scores at weeks 4 and 2 was not clinically significant. However, the improvement between week 8 and week 2 was clinically significant ( $p < 0.05$ ). At all evaluation time points, the participants showed a significant improvement in their skin status compared with that at baseline ( $p < 0.01$ ) as shown in Figure 1.



**Figure 1: Wrinkle Severity Rating Scale (WSRS) before (WSRS0), after 2 weeks (WSRS2), 4 weeks (WSRS4) and 8 weeks (WSRS8). \* Comparisons of WSRS2, WSRS4 and WSRS8 to WSRS0 indicated statistically significant differences ( $p < 0.01$ )**

Adverse effects were generally of mild or moderate intensity and expected (pain, oedema, petechia, hematoma or dark eye circle). The most common expected adverse event was a pain (53.3%), followed by oedema (40%) and petechia (26.7%).

Among 30 participants, 23 (76.6%) felt satisfied with the result. Moreover, 5 (16.7%) felt very satisfied with the treatment.

## Discussion

This clinical, open study with 30 participants demonstrated the efficacy of HA microinjection in skin rejuvenation. Most of the participants were aged 41-50 years, which is consistent with the studies conducted by Adele Sparavigna in 2015 (64 patients aged 37-60 years) [3], and Antonella in 2013 (50 patients) [4]. From 30 years of age, skin renewal decreases, so the very first signs of ageing become visible, such as uneven skin tone, wrinkles, unhealthy skin and elastin degeneration, resulting in decreased skin firmness. Therefore, this is the age when patients start to seek skin rejuvenation procedures.

Most of the participants had significant improvement after the first treatment and continued to improve after every subsequent session. In our study, this significant effect of HA mesotherapy on skin elastic properties and wrinkles was coupled to a sustained improvement after the last session. This finding is consistent with the study of Antonella conducted in Italy. To investigate the molecular effects on the skin caused by HA treatment, the authors analysed the expression levels of IL-6, IL-1b, MMP-1, and Col-1 at the beginning and end of the treatment using immunohistochemistry. The authors observed a decrease in IL-1 $\beta$ , IL-6 and MMP-1 levels and an increase in Col-1 levels. These results were statistically analysed and showed that treatment resulted in significant and long-lasting rejuvenation effects. These data were confirmed both subjectively and objectively by GAIS and WSRS score analysis (50 patients) [4].

Furthermore, HA microinjection can improve skin hydration, firmness and viscoelastic properties. These benefits were proven by Martine Baspeyras et al. when the authors conducted a study to evaluate the effect of microinjection of HA by histology and electron microscopy examination of skin biopsies. The results showed significant improvement after treatment with  $p < 0.01$  [2].

Adele Sparavigna et al. reported a statistically significant improvement in profilometric parameters, skin brightness, pigmentation, and deep skin hydration when treating skin ageing and photoaging with HA microinjection in clinics ( $p < 0.05$ ) [3].

Intradermal HA injection will stimulate fibroblasts, increase the collagen, elastin and HA synthesis in the treatment area, and promote extracellular matrix production and epithelial regeneration, resulting in skin rejuvenation [5].

WSRS2, WSRS4, and WSRS8 exhibited statistically significant differences compared with WSRS0. The improvement in wrinkles was observed after the first treatment and increased after every session. The efficacy of revitalization in skin rejuvenation was confirmed by the study of Adela Sparavigna et al. [3]. This study demonstrated the improvement in at least one grade of crow's feet, and the efficacy was found not only on the face but also on the décolletage and hand skin surface [3].

The new minimally invasive mesotherapy technique with HA can improve the clinical appearance of the skin in different age groups, as reported in a study conducted by Antonella et al. in Italy. This study demonstrated a significant and long-lasting effect on the brightness, texture, and firmness of the skin [4]. More interesting, HA microinjection also resulted in skin hydration, not only at the superficial level but also in the deep layers of the skin. This study showed that HA could have acted as a water content modulator in the skin layers, thus improving the epidermal barrier function, which is

often affected by the ageing mechanism [3].

The most common side effects included pain, oedema, petechia, and hematoma. However, those side effects lasted for only three to four days and were completely tolerable by the participants. Martine Baspeyras et al. also showed some common adverse events, including hematoma, oedema, papule and erythema. All expected adverse events disappeared within a mean time of 5.9 days [2], [7].

Most of the participants felt satisfied or very satisfied with the treatment (93.3%). These data indicate that this technique is efficacious and safe and can be well tolerated by customers.

In conclusion, this study objectively demonstrated the efficacy and safety of HA microinjection for skin rejuvenation. In particular, we showed that intradermal HA mesotherapy might be of value to decrease the wrinkles and increase the suppleness of ageing skin when conducted by a trained physician. The improvement started from the first treatment and continued to increase after every session. Most of the participants felt satisfied or very satisfied with the treatment (93.3%). Adverse events included pain, oedema, petechia, and hematoma, but these effects lasted for three to four days only and were completely tolerable.

## References

- Romagnoli M, Belmontesi M. Hyaluronic acid-based fillers: theory and practice. *Clinics in dermatology*. 2008; 26(2):123-59. <https://doi.org/10.1016/j.clindermatol.2007.09.001> PMID:18472056
- Baspeyras M, Rouvrais C, Liégard L, Delalleau A, Letellier S, Bacle I, Courrech L, Murat P, Mengeaud V, Schmitt AM. Clinical and biometrological efficacy of a hyaluronic acid-based mesotherapy product: a randomised controlled study. *Archives of dermatological research*. 2013; 305(8):673-82. <https://doi.org/10.1007/s00403-013-1360-7> PMID:23715889 PMID:PMC3778226
- Sparavigna A, Tenconi B, De Ponti I. Antiaging, photoprotective, and brightening activity in revitalization: a new solution for ageing skin. *Clinical, cosmetic and investigational dermatology*. 2015; 8:57. <https://doi.org/10.2147/CCID.S77742> PMID:25709488 PMID:PMC4330006
- Savoia A, Landi S, Baldi A. A new minimally invasive mesotherapy technique for facial rejuvenation. *Dermatology and therapy*. 2013; 3(1):83-93. <https://doi.org/10.1007/s13555-012-0018-2> PMID:2388258 PMID:PMC3680640
- Price RD, Berry MG, Navsaria HA. Hyaluronic acid: the scientific and clinical evidence. *Journal of Plastic, Reconstructive & Aesthetic Surgery*. 2007; 60(10):1110-9. <https://doi.org/10.1016/j.bjps.2007.03.005> PMID:17466613
- Zerbinati N, Lotti T, Monticelli D, et al. In Vitro Evaluation of the Sensitivity of a Hyaluronic Acid PEG Cross-Linked to Bovine Testes Hyaluronidase. *Open Access Maced J Med Sci*. 2018;6(1):20-24. <https://doi.org/10.3889/oamjms.2018.046> PMID:29483972 PMID:PMC5816299