

The Effectiveness of Oral Mini-Pulse Methylprednisolone in - the Treatment of Alopecia Areata in Vietnam

Phuong Trinh Thi¹, Anh Tran Lan¹, Phuong Tran Thu Ha¹, Thuong Nguyen Van¹, Phuong Pham Thi Minh¹, Hao Nguyen Trong², Tro Chau Van³, Nghi Dinh Huu¹, Van Tran Cam¹, My Le Huyen¹, Khang Tran Hau¹, Marco Gandolfi^{4*}, Francesca Satolli⁴, Claudio Feliciani⁴, Michael Tirant^{5,6}, Aleksandra Vojvodic⁷, Torello Lotti⁵

¹National Hospital of Dermatology and Venereology, Hanoi, Vietnam; ²HCMC Hospital of Dermato-Venereology, Ho Chi Minh City, Vietnam; ³Department of Dermatology, Pham Ngoc Thach University of Medicine, Ho Chi Minh City, Vietnam; ⁴Unit of Dermatology, University of Parma, Parma, Italy; ⁵University of Rome G. Marconi, Rome, Italy; ⁶Psoriasis Eczema Clinic, Melbourne, Australia; ⁷Department of Dermatology and Venereology, Military Medical Academy of Belgrade, Belgrade, Serbia

Abstract

BACKGROUND: Systemic corticosteroid is used to treat alopecia areata, but it is associated with side effects. Mini-pulse therapy is thought to be effective but able to reduce side effects.

AIM: The study aimed to evaluate the effectiveness of oral mini-pulse methylprednisolone in the treatment of alopecia areata.

METHODS: Patients received methylprednisolone 16 mg orally for 2 consecutive days every week.

RESULTS: After 3 months, among patients, 40% recovered well, and 55.6% recovered fairly. After 6 months, 82.2% recovered well, 17.8% recovered fairly. No adverse events were detected, and the recurrence rate was low (2.2%).

CONCLUSION: Oral mini-pulse methylprednisolone therapy is an effective and safe therapeutic option for alopecia areata without side effects, and the time of the treatment is short.

Citation: Trinh Thi P, Tran Lan A, Thu Ha PT, Van TN, Thi Minh PP, Nguyen Trong H, Chau Van T, Dinh Huu N, Tran Cam V, Le Huyen M, Tran Hau K, Gandolfi M, Satolli F, Feliciani C, Tirant M, Vojvodic A, Lotti T. The Effectiveness of Oral Mini-Pulse Methylprednisolone in - the Treatment of Alopecia Areata in Vietnam. Open Access Maced J Med Sci. <https://doi.org/10.3889/oamjms.2019.097>

Keywords: Prednisolone; alopecia areata

***Correspondence:** Marco Gandolfi, Unit of Dermatology, University of Parma, Parma, Italy. E-mail: marco.gandolfi5@gmail.com

Received: 02-Jan-2019; **Revised:** 16-Jan-2019; **Accepted:** 17-Jan-2019; **Online first:** 29-Jan-2019

Copyright: © 2019 Phuong Trinh Thi, Anh Tran Lan, Phuong Tran Thu Ha, Thuong Nguyen Van, Phuong Pham Thi Minh, Hao Nguyen Trong, Tro Chau Van, Nghi Dinh Huu, Van Tran Cam, My Le Huyen, Khang Tran Hau, Marco Gandolfi, Francesca Satolli, Claudio Feliciani, Michael Tirant, Aleksandra Vojvodic, Torello Lotti. This is an open-access article distributed under the terms of the Creative Commons Attribution-NonCommercial 4.0 International License (CC BY-NC 4.0)

Funding: This research did not receive any financial support

Competing Interests: The authors have declared that no competing interests exist

Introduction

Alopecia areata is an autoimmune disease, affecting 0.2% of the world population, in both genders and all age groups but primarily in young people (aged 15-45), with an unclear aetiology [1]. The most characteristic symptom is hair loss in one or several small rounds or elliptical patches, without pain or itchy. Also, alopecia areata could also cause loss of pubic hair, beard, eyebrows and eyelashes [2].

Systemic corticosteroid therapy has been used to therapy. Though it has beneficial effects, long-term use leads to multiple and note side effects. Pulse and mini-pulse therapy have been introduced to treat

several conditions, including alopecia areata, which have been shown to minimise the side effects of corticosteroids. The effectiveness of oral mini-pulse corticosteroids in treating alopecia areata has not been studied in Vietnam.

The study aimed to evaluate the effectiveness of oral mini-pulse methylprednisolone in the treatment of alopecia areata.

Methods

We recruited a total of 45 patients with diagnosed alopecia areata by clinical symptoms,

including hair loss in round or elliptic patches with no pain, itching, or scaling, age ≥ 15 years and with an indication to oral corticosteroids. The mini-pulse regimen was methylprednisolone 16 mg/day for two consecutive days every week for 6 months. All patients adhered to the study procedure and none dropped out.

Results

After 1 month, there were 5 patients (11.1%) recovered fairly. After 3 months, 40% recovered well (18 cases), and 55.6% recovered fairly (25 cases). After 6 months, 82.2% recovered well (35 cases), 17.8% (8 cases) recovered fairly, and all these patients got better hair regrowth days every week as shown in Figure 1.

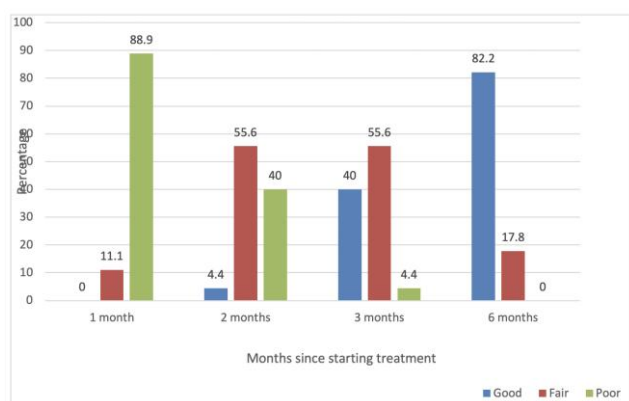


Figure 1: Overall treatment outcome

Severity and gender groups as shown in Table 1 and Table 2.

Table 1: Outcome by severity

Severity	Outcome				p
	Good		Fair		
	n	%	n	%	
Mild	35	85.4	6	14.6	P > 0.05
Moderate	2	50	2	50	

After six months, no side effects were recorded. We had two patients developing new hair loss patches during study participation (one during the therapeutic stage and one during the follow-up stage). This rate was much lower than in patients treated with injected triamcinolone (9.9%).

Table 2: Outcome by gender

Gender	Outcome				p
	Good		Fair		
	n	(%)	n	(%)	
Male	21	77.8	6	22.2	P > 0.05
Female	16	88.9	2	11.1	

Discussion

In comparison with Doulat Rai Bajai's [3] pulse prednisolone therapy concluding 30 mg per day within 3 days every week, and this treatment lasted for 6 months. After Bajai's treatment, among patients, 85.6% recovered well, which is approximately equivalent with our result. Jea Won Jang and partners' [4] pulse betamethasone therapy consisted in treatment in which patients took 5mg per day within two consecutive days every week. After a one-month treatment, 67.4% of patients got better. Pankaj [5] used pulse betamethasone (5 mg/day within two conservative days every week). After 6 months, 73.3% of the patients recovered well. In another group, patients took 40 mg betamethasone once per month in 6 consecutive months, and 42.9% of the patients recovered well [6].

In conclusion, oral mini-pulse methylprednisolone was effective, simple, with short-term use of medication, and had no side effects.

References

- Unal M. Use of adapalene in alopecia areata: Efficacy and safety of mometasone furoate 0.1% cream versus a combination of mometasone furoate 0.1% cream and adapalene 0.1% gel in alopecia areata. *Dermatologic therapy*. 2018; 31(1):e12574. <https://doi.org/10.1111/dth.12574> PMID:29193637
- Craiglow BG. Topical tofacitinib solution for the treatment of alopecia areata affecting eyelashes. *JAAD case reports*. 2018; 4(10):988. <https://doi.org/10.1016/j.jidcr.2018.07.018> PMID:30417059 PMCID:PMC6218694
- Bajaj DR, Devrajani BR, Shah SZ, Ghauri RA, Matlani BL. Treatment of extensive alopecia areata with oral prednisolone mini-pulse regimen. *Journal of Pakistan Association of Dermatology*. 2016; 18(4):226-31.
- Won Jang J, et al. Oral mini-pulse therapy with betamethasone in Treatment of Alopecia Areata. Department of Dermatology, Kyungpook, National University Scholl of Medicine, Taegu, Korea, 2001.
- Chaturvedi P, et al. Comparative Efficacy an Safety of Twice weekly Oral Betamethasone Mini Pulse and Monthly Oral Betamethasone Pulse in Multifocal Alopecia Areata. *Dermacon, India*, 2010:P173.
- Gianfaldoni S, Tchernev G, Wollina U, Lotti T. A Case of Alopecia Areata in a Patient with Turner Syndrome. *Open Access Maced J Med Sci*. 2017; 5(4):493-496. <https://doi.org/10.3889/oamjms.2017.127> PMID:28785342 PMCID:PMC5535667

