

Suboccipital Muscles Injection for Management of Post-Dural Puncture Headache After Cesarean Delivery: A Randomized-Controlled Trial

Mhamed Abdelraouf, Maged Salah, Mohsen Waheb, Ahmed Elshall*

Cairo University, Cairo, Egypt

Abstract

Citation: Abdelraouf M, Salah M, Waheb M, Elshall A. Suboccipital Muscles Injection for Management of Post-Dural Puncture Headache After Cesarean Delivery: A Randomized-Controlled Trial. Open Access Maced J Med Sci. <https://doi.org/10.3889/oamjms.2019.105>

Keywords: Suboccipital muscles injection for management of post-dural puncture headache

***Correspondence:** Ahmed Elshall, Cairo University, Cairo, Egypt. E-mail: dr.ahmedelshall@gmail.com

Received: 08-Dec-2018; **Revised:** 18-Jan-2019; **Accepted:** 19-Jan-2019; **Online first:** 19-Feb-2019

Copyright: © 2019 Mhamed Abdelraouf, Maged Salah, Mohsen Waheb, Ahmed Elshall. This is an open-access article distributed under the terms of the Creative Commons Attribution-NonCommercial 4.0 International License (CC BY-NC 4.0)

Funding: This research did not receive any financial support

Competing Interests: The authors have declared that no competing interests exist

INTRODUCTION: Post-dural puncture headache (PDPH) is a common complication following neuraxial anaesthesia that increases the duration of hospital stay.

AIM: This study aims to evaluate the effectiveness of injection of the dexamethasone-lidocaine mixture in suboccipital muscles treatment of PDPH after cesarean section.

PATIENT AND METHODS: A group of 90 females with PDPH following cesarean section under spinal anaesthesia were randomly allocated into two equal groups: study group (Group S) and control group (group C). All patients received bilateral intramuscular (in the suboccipital muscle) (Group S) (n = 45) patients received lidocaine 40 mg (2 mL of 2% solution) and dexamethasone 8mg in a total volume of 4 mL; whilst, patients in the control group (group C) (n = 45) received 4 mL normal saline. The primary outcome is the Visual Analogue Score for a headache at 24 hours after injection.

RESULTS: Demographic data and the baseline, headache score, neck muscle spasm, and nausea were comparable in both groups. Group S showed lower headache score compared to group C at all the post-injection time points. All patients in group S showed resolution of nausea after the intervention; while none of the control group showed any improvement. All patients of group C needed rescue analgesia; while only 6 (13.3%) patients in group S asked for an analgesic. Time to the first analgesic request was longer in group S compared to group C (10.17 ± 7.96 hours versus 1.00 ± 0.00 hours, P < 0.001).

CONCLUSION: Ultrasound-guided injection of the dexamethasone-lidocaine mixture in suboccipital muscles is effective management of PDPH after CS.

Introduction

Post-dural puncture headache (PDPH) is a common complication following neuraxial anaesthesia that increases the duration of hospital stay [1], [2], and is considered a significant cause of increased anaesthetic workload and often interferes with maternal-infant interaction [3].

The incidence of PDPH after cesarean delivery has been reported to be high up to 38% [4].

Conservative therapy, pharmacotherapy and

interventional procedures have been used in the management of PDPH. Conservative measures such as hydration and bed rest [5] Pharmacotherapy such as gabapentin [6], hydrocortisone [7], cosyntropin (ACTH) [8], sumatriptan [9] and caffeine [10].

An epidural blood patch is an effective intervention for management of PDPH; however, it is relatively invasive [11]. Till now, a standard, evidence-based protocol for management PDPH is still lacking.

The exact cause of PDPH is not clearly understood, however, CSF leakage through dural puncture appears to be the most accepted explanation of PDPH [12].

PDPH is commonly associated with neck stiffness and muscle spasm. Presence of myodural bands a connective tissue band between the spinal dura mater and suboccipital muscles) in the back of neck might play a role in PDPH [13].

Local anaesthetic injection in neck muscles has been reported to relieve some types of chronic headache [14], [15], [16], [17], [18], but to our knowledge, no one has tried to use this technique in the treatment of PDPH.

Intramuscular (neck muscles) injection of local anaesthetic- steroid combination may improve both neck muscles spasm and subsequently PDPH.

This study aims to evaluate the effectiveness of injection of the dexamethasone-lidocaine mixture in suboccipital muscles treatment of PDPH after cesarean section.

Patient and Methods

A prospective double-blinded randomised controlled trial was conducted from January to June 2018 at Cairo University hospital after approval of the Research Ethics Committee. Written informed consent was obtained from all participants before enrollment. Randomisation was achieved using a computer-generated sequence of numbers. Opaque sealed envelopes were used for concealment.

The study 90 female, ASA I&II patients, aged between 18 and 40 years, with PDPH following cesarean section under spinal anaesthesia. Patients with pre-spinal chronic headache or migraine, hypertensive patients, patients who cannot comply with Visual Analogue Score (VAS) were excluded from the study.

Patients were randomly allocated into two equal groups: study group (Group S) and control group (group C). All patients received bilateral intramuscular (in the suboccipital muscle) injection of either local anaesthetic-steroid mixture or saline (according to the group allocation).

(Group S) (n = 45) patients received lidocaine 40 mg (2 mL of 2% solution) and dexamethasone 8 mg in a total volume of 4 mL; whilst, patients in the control group (group C) (n = 45) received 4 mL normal saline.

Details of the technique

The drug was prepared by a research assistant, and the syringe was delivered to another anesthesiologist who was blinded to the study group. Suboccipital muscle injection was performed blindly while the patient is sitting on chair and neck maximally

flexed on the edge of a bed. Patient follow-up was performed by a research assistant who was also blinded to the study group. Mention what are the other routes of management.

Outcomes

Primary outcome

Visual Analogue Score (VAS) for headache: VAS assessed at 24 hours after injection.

Secondary outcomes:

1. Visual Analogue Score (VAS) for headache: VAS was assessed at the baseline before injection, 1 hour, 6 hours, and 12 hours, after injection during rest.

2. The need for rescue analgesia (the frequency of patients who requested additional analgesic). In patients with VAS more than 3, rescue analgesic in the form of ketorolac 30 mg was taken intramuscular up to 120 mg max per day.

3. Time to 1st rescue analgesia.

4. Nausea pre and post injection

Sample size calculation

In a pilot study on 8 patients, we reported a postoperative headache score of 4.2 ± 1.3 after cesarean delivery. Using MedCalc Software version 14.10.2 (MedCalc Software bvba, Ostend, Belgium), we calculated a conservative sample size that could detect 20% difference in headache score (i.e. 0.84) between the two study groups. A minimum number of 78 patients (39 patients per group) was calculated to have a study power of 80% and an alpha error of 0.05. The number was increased to 90 patients (45 patients per group) to compensate for possible drop-outs.

Statistical analysis

Data were presented in terms of mean \pm standard deviation (\pm SD), median and range, or frequencies (number of cases) and percentages when appropriate. Comparison of numerical variables between the study groups was made using Student t-test for independent samples or Mann Whitney test as appropriate. For comparing categorical data, Chi-square (χ^2) test was performed. The exact test was used instead when the expected frequency is less than 5. p values less than 0.05 was considered statistically significant. Repeated measures were compared using two-way Analysis of Variance (ANOVA) test with Post Hoc Bonferroni test. All statistical calculations were done using computer program SPSS (Statistical Package for the Social Science; SPSS Inc., Chicago, IL, USA) release 15 for Microsoft Windows (2006).

Results

One hundred and four patients with PDPH were assessed for legibility. Ten patients were excluded as they did not meet inclusion criteria; four patients refused to sign the consent, and 90 patients received the intervention, and all of them completed the study and were available for final analysis (Figure 1).

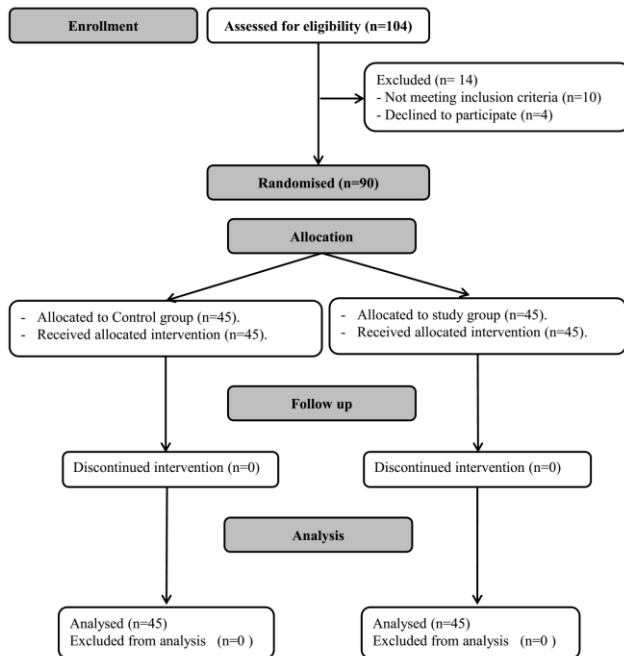


Figure 1: Consort flow diagram

Demographic data were comparable in both groups (Table 1).

Table 1: Demographic data

	Group c (n = 45)	Group s (n = 45)	P value
Age (years)	27.82 ± 3.58	25.87 ± 5.20	
BMI (kg/m ²)	29 ± 3	29 ± 4	0.8

Data expressed as mean ± SD; *Denotes significance between both groups.

At the baseline, both groups were comparable about headache score, neck muscle spasm, and nausea (Table 2, and 3).

Group S showed lower headache score compared to group C at all the post-injection time points (Table 2).

Table 2: Headache score

	Group c (n = 45)	Group s (n = 45)	P value
Baseline	6.40 ± 1.42	6.51 ± 1.82	0.75
Post intervention 1st hour	5.82 ± 1.11	1.69 ± 0.49	0.00*
Post intervention 6th hour	2.20 ± 1.06	1.69 ± 1.10	0.03*
Post intervention 12th hour.	2.87 ± 1.69	1.67 ± 1.24	0.00*
Post intervention 24th hour	3.22 ± 2.14	1.69 ± 1.10	0.00*

Data expressed as mean ± (SD); *Denotes significance between both groups.

All patients in group S showed resolution of nausea after the intervention; while none of the control

group showed any improvement. All patients of group C needed rescue analgesia; while, only 6 (13.3%) patients in group S asked for analgesic (Table 3).

Table 3: Neck spasm, Nausea, The need for rescue analgesia

	Group c (n = 45)	Group s (n = 45)	P value
Neck spasm	36/45 (80%)	36/45 (80%)	1.00
Nausea			
Before intervention	12/45 (26.7%)	12/45 (26.7%)	1.00
After intervention	12/45 (26.7%)	0/45 (0%)	0.00*
The need of rescue analgesia	45/45 (100%)	6/45 (13.3%)	0.00*

Data expressed as count and per cent; *Denotes significance between both groups.

Time to the first analgesic request was longer in group S compared to group C (10.17 ± 7.96 hours versus 1.00 ± 0.00 hours, P < 0.001) (Table 4).

Table 4: Time to first rescue analgesia

	Group c (n = 45)	Group s (n = 45)	P value
Time to first rescue analgesia (hours)	1.00 ± 0.00	10.17 ± 7.96	0.00*

Data expressed as mean ± (SD); *Denotes significance between both groups.

Discussion

We reported that suboccipital (neck) muscles injection successfully improved PDPH after cesarean delivery. To our knowledge, this is the first study to evaluate the efficacy of this intervention in PDPH.

PDPH is characteristically distributed over the frontal and the occipital region radiating to the neck and shoulders. The headache may be associated with other symptoms such as nausea, vomiting, hearing loss. Neck stiffness and muscle spasm are one of the most important characteristics of PDPH following spinal anaesthesia [12].

Although it remains speculative, traction on connective tissue link (myodural band) between the spinal dura mater and suboccipital muscles in the back of the neck may aggravate or even cause the headache [13].

Neck muscles injection with local anaesthetic has been used effectively for the treatment of various types of chronic headaches [14], [15], [16], [17], [18]; thus, we hypothesised that it could be effective in the management of PDPH.

The close characteristics of PDPH and cervicogenic headache could explain the similar response of both types of headache to neck muscle injection [17].

Myodural Bridge might have a role in headache production. This assumption was supported by the relief of chronic headache after surgical separation of the Myodural Bridge from suboccipital musculature [19]. Neck injection of local anaesthetic result in relaxation of suboccipital muscles; and thus, it could improve the tension on the dura by myodural

band.

Our findings provide new insights in the management of PDPH. Our intervention is simple, cost-effective, and less invasive compared to the traditional methods for management of PDPH such as epidural blood patch.

Other types of injections were used effectively for the treatment of PDPH such as greater occipital nerve block and sphenopalatine ganglion block [20], [21].

Future comparison between these blocks could be made and evaluation of suboccipital muscle injection using ultrasound might help select particular muscle for injection (rectus capitis posterior major, rectus capitis posterior minor and the capital inferior) where in all these muscles myo-dural bands were identified.

Our study had some limitations: 1) It is a single centre study. 2) We evaluated the intervention in special population post-cesarean delivery. Future studies are needed for confirming our findings in PDPH after other operations. 3) We used a single dose of the local anaesthetic-steroid mixture; thus, dose-finding studies are warranted.

In conclusion, ultrasound-guided injection of the dexamethasone-lidocaine mixture in suboccipital muscles is effective management of PDPH after CS.

References

- López Correa T, Garzón Sánchez JC, Sánchez Montero FJ, Muriel Villoria C. Postdural puncture headache in obstetrics. *Rev Esp Anestesiol Reanim.* 2011; 58(9):563-573. [https://doi.org/10.1016/S0034-9356\(11\)70141-4](https://doi.org/10.1016/S0034-9356(11)70141-4)
- Thew M, Paech MJ. Management of postdural puncture headache in the obstetric patient. *Curr Opin Anaesthesiol.* 2008; 21(3):288-292. <https://doi.org/10.1097/ACO.0b013e3282f8e21a>
- Evans R. Complications of lumbar puncture. *Neurol Clin.* 1998; 16:83-105. [https://doi.org/10.1016/S0733-8619\(05\)70368-6](https://doi.org/10.1016/S0733-8619(05)70368-6)
- Spencer HC. Postdural puncture headache: what matters in technique. *Reg Anesth Pain Med.* 1998; 23:374-379. <https://doi.org/10.1097/00115550-199823040-00010>
- Carbaat PA, van Crevel H. Lumbar puncture headache: Controlled study on the preventive effect of 24 hours' bed rest. *Lancet.* 1981; 2:1133-1135. [https://doi.org/10.1016/S0140-6736\(81\)90586-9](https://doi.org/10.1016/S0140-6736(81)90586-9)
- Alireza Mahoori, Heydar Noroozinia, Ebrahim Hasani, and Hadi Saghaleini. Comparing the effect of pregabalin, gabapentin, and acetaminophen post-dural puncture headache. *Saudi J Anaesth.* 2014; 8(3):374-377. <https://doi.org/10.4103/1658-354X.136436> PMID:25191190 PMCID:PMC4141388
- Alam MR, Rahman MA, and Ershad R. Role of very short-term intravenous hydrocortisone in reducing postdural puncture headache. *J Anaesthesiol Clin Pharmacol.* 2012; 28(2):190-193. <https://doi.org/10.4103/0970-9185.94840> PMID:22557741 PMCID:PMC3339723
- Basurto Ona X, Osorio D, Bonfill Cosp X. Drug therapy for treating post-dural puncture headache. *Cochrane Database Syst Rev.* 2015; 15:(7). <https://doi.org/10.1002/14651858.CD007887.pub3>
- Hodgson C, Roitberg-Henry A. The use of sumatriptan in the treatment of postdural puncture headache. *Anaesthesia* 1997; 52:808. PMID:9291788
- Camann WR, Murray RS, Mushlin PS, Lambert DH. Effects of oral caffeine on postdural puncture headache. A double-blind, placebo-controlled trial. *Anesthesia and analgesia.* 1990; 70(2):181-4. <https://doi.org/10.1213/00000539-199002000-00009> PMID:2405733
- Malhotra S. All patients with a postdural puncture headache should receive an epidural blood patch. *Int J Obstet Anesth.* 2014; 23(2):168-170. <https://doi.org/10.1016/j.ijoa.2014.01.001> PMID:24656528
- Vilming ST, Titus F. Low cerebrospinal fluid pressure In: Oleson J, T Felt- Hansen P, Wetch K, (eds). *The headaches.* New York, NY: Raven, 1993:687-695.
- KahkeshaniK, and Ward PJ. Connection between the spinal dura mater and suboccipital musculature: evidence for the myodural bridge and a route for its dissection--a review. *Clin Anat.* 2012; 25(4):415-422. <https://doi.org/10.1002/ca.21261> PMID:22488993
- Karadaş Ö, Gül HL, Inan LE. Lidocaine injection of pericranial myofascial trigger points in the treatment of frequent episodic tension-type headache. *J Headache Pain.* 2013; 14:44. <https://doi.org/10.1186/1129-2377-14-44> PMID:23698019 PMCID:PMC3671170
- Venâncio Rde A, Alencar FG, Zamperini C. Different substances and dry-needling injections in patients with myofascial pain and headaches. *Cranio.* 2008; 26(2):96-103. <https://doi.org/10.1179/crn.2008.014> PMID:18468269
- Venancio Rde A, Alencar FG Jr, Zamperini C. Botulinum toxin, lidocaine, and dry-needling injections in patients with myofascial pain and headaches. *Cranio.* 2009; 27(1):46-53. <https://doi.org/10.1179/crn.2009.008> PMID:19241799
- David M. Biondi, DO. Cervicogenic Headache: A Review of Diagnostic and Treatment Strategies. 2005; 105(4):16S-22S.
- Mellick LB, McIlrath ST, Mellick GA. Treatment of headaches in the ED with lower cervical intramuscular bupivacaine injections: a 1-year retrospective review of 417 patients. *Headache.* 2006; 46(9):1441-1449. <https://doi.org/10.1111/j.1526-4610.2006.00586.x> PMID:17040341
- Cohen-Gadol AA, Mokri B, Piepgras DG, Meyer FB, Atkinson JL. Surgical anatomy of dural defects in spontaneous spinal cerebrospinal fluid leaks. *Neurosurgery.* 2006; 58(4):238-245. <https://doi.org/10.1227/01.NEU.0000204712.16099.FB>
- Matute E, Bonilla S, Girones A. Bilateral greater occipital nerve block for post-dural puncture headache. *Anaesthesia.* 2008; 63:551-560. <https://doi.org/10.1111/j.1365-2044.2008.05531.x> PMID:18412667
- Naja ZM, AL-Tannir MA, EL-Rajab M, Ziad FM, Baraka A. Nerve stimulator-guided occipital nerve blockade for postdural puncture headache. *Pain Pract.* 2009; 9:51-58. <https://doi.org/10.1111/j.1533-2500.2008.00238.x> PMID:19019052