

Assessments of Bone Height Loss in Telescopic Mandibular Implant-Retained Overdentures Retained by Two and Four End - Osseous Implants: A Randomized Clinical Trial

Nesma Mohamed Awaad^{*}, Noha Mohamed Eladl, Nadia Ahmed Abbass

Department of Prosthodontics, Faculty of Dentistry, Cairo University, Cairo, Egypt

Abstract

Citation: Awaad NM, Eladl NM, Abbass NA. Assessments of Bone Height Loss in Telescopic Mandibular Implant-Retained Overdentures Retained by Two and Four End - Osseous Implants: A Randomized Clinical Trial. Open Access Maced J Med Sci. <https://doi.org/10.3889/oamjms.2019.108>

Keywords: Bone loss; Bone height; Telescopic attachments; Over-dentures; Cad/cam

***Correspondence:** Nesma Mohamed Awaad, Department of Prosthodontics, Faculty of Dentistry, Cairo University, Cairo, Egypt. E-mail: dr.nesmaawaad@yahoo.com

Received: 01-Dec-2018; **Revised:** 07-Jan-2019; **Accepted:** 09-Jan-2019; **Online first:** 22-Feb-2019

Copyright: © 2019 Nesma Mohamed Awaad, Noha Mohamed Eladl, Nadia Ahmed Abbass. This is an open-access article distributed under the terms of the Creative Commons Attribution-NonCommercial 4.0 International License (CC BY-NC 4.0)

Funding: This research did not receive any financial support

Competing Interests: The authors have declared that no competing interests exist

AIM: This randomized clinical study aimed to assess bone height loss when using mandibular implant overdentures retained by two and four endosseous implants using the telescopic attachments.

METHODS: Twelve completely edentulous patients were randomly allocated so that six patients were treated by telescopic implant overdenture retained by two implants (group A) and six patients were treated with overdentures retained by four implants (group B). Digital radiographic evaluation of bone height using Digora was made starting at the functional loading day followed by time intervals of 12 months.

RESULTS: No implant loss during the healing period or after functional loading. Radiographic evaluation revealed a statistically significant difference was found between (Group A) and (Group B) were ($p < 0.001$).

CONCLUSION: For bone loss, widely distributed four intraforaminal implants revealed more bone preservation than only two implants when using the telescopic attachments to support and retain an over dentures taking in consideration the type of the attachment will be used.

Introduction

Complete dentures wearer usually exhibit problems with their mandibular dentures due to lack of stability and retention as a result of the smaller denture bearing areas which affects the chewing ability [1]. The utilisation of dental implants, as a means for improving retention, has become a common and effective procedure in the last decades. Various authors have presented data on overdentures supported by 1–8 implants. Several attempts were made in recent years to find an answer to the question of how many implants should be used to retain/support an overdenture [2]. The advent of osseointegrated dental implants has offered additional treatment options for completely and partially edentulous patients. Implant prostheses can be classified as fixed or removable and as full-arch or partial-arch, similar to the principles of conventional prosthodontics [3]. The implant-supported prosthesis

usually utilizes four or more implants to totally support an overdenture, obtaining its support totally from implants where the mucosa does not share in any load [4]. While implant -tissue supported prosthesis depends on sharing the load between implants used and the mucosa of the distal extension part, utilizing fewer number of implants usually, two-interforaminal implants [3], [4]. Removable implant-retained restorations might be considered a better treatment option to fixed in patients with excessive ridge resorption which has led to the loss of facial support of the lips and soft tissues of the face as a result of severe residual ridge resorption and when inadequate accessibility to maintain good oral hygiene [5]. There are different attachment systems can be used, the most used connection systems between implants and overdentures are bars, balls with metal clips, locators, magnets, and telescopes depending in their selections on the anatomic, clinical situation, amount of retention needed, cost, implants position and parallelism [6]. Since 1989 non-rigid telescopic attachment have been

used to support a removable overdenture for the treatment of completely edentulous patients [7]. So, it has been over years of good clinical experience.

This study was conducted to evaluate the radiographic changes in bone height when using the telescopic attachment on two or four end-osseous implants supporting and retaining a mandibular overdenture.

Methods

Twelve patients with the eligibility criteria were recruited in the study from the Outpatient Clinic of the Prosthodontics Department, Faculty of Oral and Dental Medicine, Cairo University. The participants received oral and written information about the study and written informed consent was obtained before their recruitment. They were selected with completely edentulous maxillary and mandibular arches with class I maxilla-mandibular relationship, sufficient restorative space not less than 15 mm and adequate buccolingual width of keratinised mucosa equal to or greater than 5mm over the crest of the lower ridge. All Patient were selected with the good physical and psychological condition to tolerate conventional implant surgical protocol. A panoramic radiograph was taken for each patient to assess bone height and location of the nearby vital structure in the areas planned to receive implants. Complete maxillary and mandibular dentures were constructed with proper tissue fitness and ideal teeth setting to allow for prosthetic driven implant placement. When the patient already had a denture, it was checked for proper extension, mucosal fitness, esthetic and occlusion and then it was used to prepare the scan prosthesis. A preoperative CBCT scan was taken for the patient's mandibular arch with the scan appliance with PLANMECA Pro max 3D mid CBCT machine. After CBCT scan, the DICOM images were then imported in Blue Bio sky software (Blue sky Bio, LLC. planning software). For the patients receiving two implants the virtual planning was done to the area at the two canines, but for the patients receiving 4 implants, planning was made in the inter- foraminal area. Virtual implant models 3.5 × 10 mm and 3.5 × 11.5 mm were used for posterior and anterior implants respectively. Implants were placed inadequate bone locations guided by the radiolucent channels in the scan appliance at the place of canines and second premolars. The implants were planned parallel to each other as possible putting in consideration the nearby vital structure.

The surgical stent was inserted in the patient's mouth; then bleeding points were made through the stent by using the periodontal probe opposing the proposed implants sites. The mid crestal incision was made slightly behind the location of

implant placement with buccal releasing incisions for easier releasing of the flap without laceration. Complete flap retraction was made by using mucoperiosteal elevator. Root form tapered implants (Neo Biotech Co. Ltd, Seoul, Korea) were placed using the submerged two-stage technique.

After the healing period of 3 months, the surgical stents were used again to relocate the position of the inserted implants. Infiltration anaesthesia was given to the patient, and crestal incision was made opposing to the site of each implant, healing abutments were screwed with collar height 5 mm to allow for proper gingival healing around the implants prior making the impression.




Figure 1: Milling surveyor

The impression was made with an open tray splinted implant level impression technique was used. Then, telescopic attachments were fabricated through the use of UCLA Ti-based plastic abutments (New Biotech ISUCH400, Korea) to fabricate the primary screw-retained abutments, adjusted the taper by the use of the milling surveyor (Figure 1), which was transferred from their laboratory position to the oral cavity through the use of an abutment jig (Figure 2).

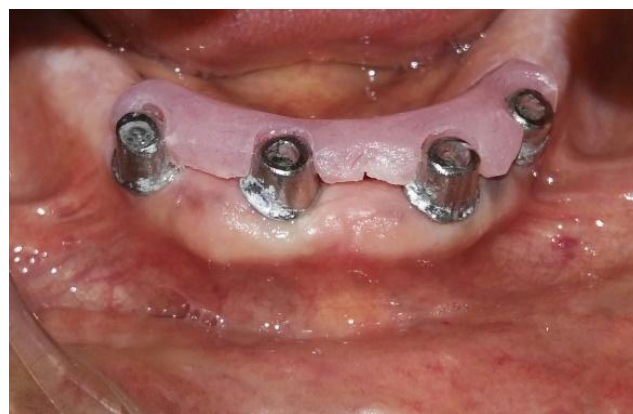

Figure 2: Acrylic jig

For the fabrication of the secondary coping, finished primary coping was scanned to design and fabricate the wax pattern of the secondary coping

using the CAD/CAM (Shera Echo-scan 7 Dental Wings Inc.2251,AvLetourneux Montreal H1V2N9 Canada), secondary coping was designed having two projected wings parallel to the ridge and properly fitted to the primary coping.

The casting of the resulted wax pattern was made, after finishing and polishing, secondary coping was checked on to the primary coping, together were placed on the cast and scanned to design and fabricate the framework using CAD/CAM) (Figure 3). Jaw relation registration was made, try in and then denture insertion and delivery to the patient with final occlusion adjustment.

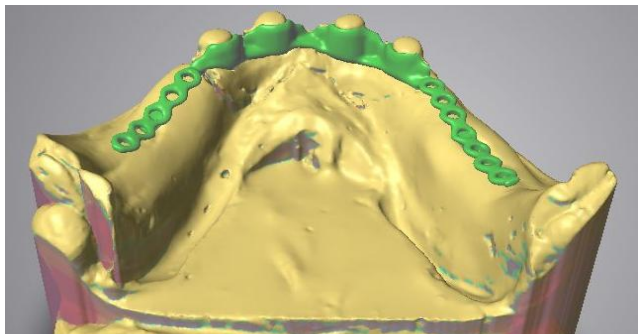


Figure: 3 Cad/cam designing of Framework

Radiographic assessment for the bone loss during the follow-up period:

Bone height was measured using Digora digital radiograph (Digora Computerized system, Helsinki, Finland) radiographs were taken at the following intervals at the day of loading of the final prosthesis and after twelve months of delivery.

The long cone parallel technique was used for making reproducible and standardised images during the follow-ups. At the time of the exposure, the lower denture was removed to allow for proper film alignment in front of the target abutments. Rubber base index (Figure 4) was made to allow for film stabilisation against the upper denture to stabilise the film during exposure. Then, the film was removed from film holder and placed inside Digora scanner opening. The images for each patient were saved in separate files with the patient's name until the end of the follow-up periods for interpretation.



Figure 4: Putty Index for

Measurement of the amount of bone loss

The digital images saved were analysed to detect the amount of bone loss mesial and distal to the implant. To obtain actual images, the calibration option was used to detect the actual length of the implant by comparing the screen length of the implant to the known actual implant length. The reference point was taken at the junction between the implant platform and the abutment base, from which the loss of bone will be calculated by measuring the distance from the reference point to the first implant-bone contact. For each implant, bone height was measured at the mesial and distal surfaces in mm (Figure 5).

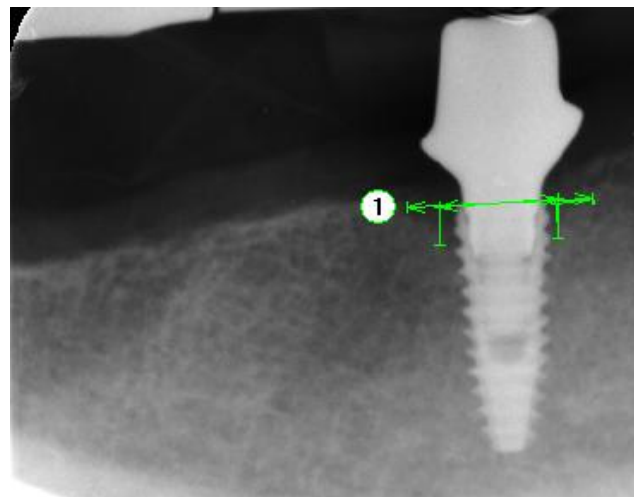


Figure 5: Digora measurements

Results

The mean and standard deviation values were calculated for each group in each test. Data were explored for normality using Kolmogorov-Smirnov and Shapiro-Wilk tests; data showed non-parametric (not-normal) distribution. Wilcoxon was used to comparing between two groups in related samples. Mann Whitney test was used to compare between two groups in non-related samples. The significance level was set at $P \leq 0.05$. Statistical analysis was performed with IBM® SPSS® Statistics Version 20 for Windows.

Table 1: The mean, standard deviation (SD) of bone height loss in different groups

Variables	Bone height loss				p-value
	At loading		After year		
	Mean	SD	Mean	SD	
Group A (2implants)	0.29	0.12	1.9	0.09	< 0.001*
Group B (4implants)	0.44	0.31	1.61	0.23	< 0.001*

*; significant (p < 0.05) ns; non-significant (p > 0.05).

Bone height loss results: Effect of time in each group as shown in Table 1 and Figure 6.

a) Group A (2 implants): A statistically significant difference was found between (At loading) and (After year) where ($p < 0.001$).

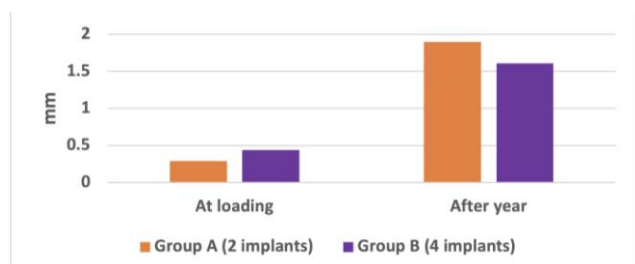


Figure 6: Bar chart representing a bone loss for each group

b) Group B (4 implants): A statistically significant difference was found between (At loading) and (After year) where ($p < 0.001$). Effect of time between groups: As shown in Table 2, and Figure 7.

Table 2: The mean, standard deviation (SD) of bone loss difference in different groups

Variables	Bone loss difference	
	Mean	SD
Group A (2implants)	1.51	0.23
Group B (4implants)	1.08	0.37
p-value	< 0.001*	

*: significant ($p < 0.05$) ns: non-significant ($p > 0.05$).

At loading: No statistically significant difference was found between (Group A) and (Group B) where ($p = 0.051$). After a year: A statistically significant difference was found between (Group A) and (Group B) were ($p < 0.001$).

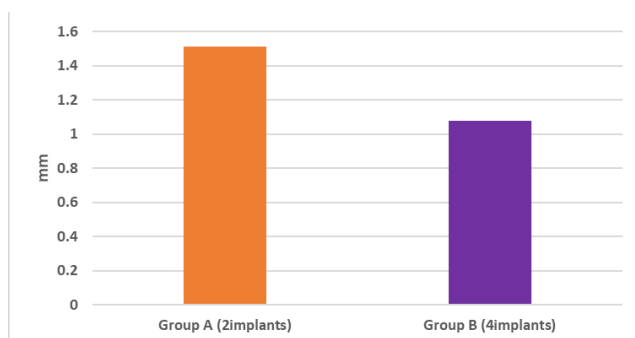


Figure 7: Bar chart representing bone loss difference for different groups

Discussion

Bone height measurement revealed a significant difference between the two groups where Group A showed a statistically significantly higher mean amount of bone loss than Group B.

Data was not much available due to the low number of studies comparing a different number of

implants with telescopic attachments. There was a monthiversary within the studies addressing this topic; where some studies showed a non-significant difference between two and four implants, others showed a significant difference in the bone loss; where bone loss was more with the use of four implants. Other studies concluded that there is a need for more research for the long term effect of the use of different implants number. Although the results of this study were against the results of the following studies found in literature, those studies differed in study design, sample size, and also may be attributed to the different type of attachment used, where the studies comparing the bone loss between two and four implants were not addressing the telescopic attachments, where telescopic attachment should be fabricated with sufficient height to achieve the needed frictional retention; where this vertical height leads to more lateral forces than other attachments.

The height of the telescopic attachments in implant overdentures had a marked effect on the lateral force on implants and denture displacement. To protect implants supporting an overdenture and to prevent bone resorption, the height of the attachment should be carefully considered [8]. Wismeijer et al., 1997 evaluated over 100 patients with overdentures supported by two implants and four implants, no significant differences were found between the two modalities in 16 months; concluding the sufficiency of two implants to support an over-denture [9]. However; these results were against most of the literature which stated that there is a non-significant difference among two and four implants; this may be attributed to the differences in the attachment used and loading of the prosthesis.

Batenburg et al., 1998 studied 60 mandibular implant overdenture patients who were divided into 2 groups, one group treated with two endosteal implants and the other with four endosteal implants. They found no significant differences about peri-implant health. The authors suggested that additional study is necessary [10] in 2005; Visser presented 5-year results of a previous study made by Batenburget al., 1998, There was no difference in the clinical and radiographical state of patients treated with an Overdentures on two or four implants [11].

Meijer et al., in 2009 reported a 10-year data of the previously published paper of Batenburg et al., (1998) concluding that there was no statistically significant difference between patients treated with a two or four implant mandibular Over-denture retained by bars concerning radiographic bone loss and prosthetic aftercare. For reasons of cost-effectiveness, a two-implant Over-dentures was advised [12].

Patients with two implants showed less marginal bone loss than those with four implants, suggesting that two implants seem to be preferable for mandibular implant-supported OD. The different

results of this study to be attributed to the loading and type of supra-structure that may influence the marginal bone loss, and that the more implants a patient has, the higher the probability of obtaining an implant with peri-implantitis affecting the bone level [13].

A randomized clinical trial, using a crossover design, by Burns et al., 2011, Thirty subjects received four implants in the anterior mandible, using three different Over-dentures attachment types were fabricated and/or fitted to the implants: 4-implant bar attachment, 2 implant bar attachment, and two ball attachments, the one-year data revealed that the risk of implant loss does not vary substantially by the number of implants [14].

In 2012, Rocuzzo et al., did a systematic review to assess the optimal number of implants for removable reconstructions. For the mandible, it cannot be concluded that bone loss, patient satisfaction, or a number of complications is significantly related to the number of implants supporting the overdenture. The author concluded that there is a need for a well-conducted research is needed to identify the prognostic factors for long-term success [15].

In conclusion, for bone loss, widely distributed four intraforaminal implants revealed more bone preservation than only two implants when using the telescopic attachments to support and retain an over dentures taking in consideration the type of the attachment will be used.

References

1. Visser A, Raghoobar GM, Meijer HJA, Batenburg RHK, Vissink A. Mandibular overdentures supported by two or four end osseous implants. A 5 years prospective study. *Clin Oral Imp Res.* 2005; 16:19-35. <https://doi.org/10.1111/j.1600-0501.2004.01085.x> PMID:15642027
2. Rocuzzo M, Bonino F, Gaudio L, Zwahlen M, Meijer HJA. What is the optimal number of implants for removable reconstructions? A systematic review on implant-supported overdentures. *Clin Oral Implants Res.* 2012; 23:229–237. <https://doi.org/10.1111/j.1600-0501.2012.02544.x> PMID:23062145
3. Simon H, Yanase RT. Terminology for implant prostheses. *International Journal of Oral & Maxillofacial Implants.* 2003; 18(4). PMID:12939005
4. Raghoobar GM, Meeijer HJ, Slot W, Slater JJ, Vissink A. A systematic review of implant-supported overdentures in the edentulous maxilla, compared to the mandible: how many implants. *Eur J Oral Implant.* 2014; 7: 191-201.
5. Lavery DP, Green D, Morrison D, Addy Land Thomas MBM. Implant retention systems for implant-retained overdentures. *Brit Dent J.* 2017; 222:347-359. <https://doi.org/10.1038/sj.bdj.2017.215> PMID:28281622
6. Preoteasa E, Marin M, Imre M, Lerner H, Preoteasa CT. Patients' satisfaction with conventional dentures and mini implant anchored overdentures. *Rev Med Chir Soc Med Nat Iasi.* 2012; 116:310-316. PMID:23077914
7. Heckmann SM, Schrott A, Graef F, Wichmann MG, Weber HP. Mandibular two-implant telescopic overdentures. *Clin Oral Implants Res.* 2004; 15:560–569. <https://doi.org/10.1111/j.1600-0501.2004.01064.x> PMID:15355398
8. Ziwei Y, Tomoya G, Yoshinobu M, Ying Z, Gonda T, Maeda Y. Influence of Attachment Height and Shape on Lateral Force Transmission in Implant Overdenture Treatment. *Int J Prosthodont.* 2017; 30:586-591. <https://doi.org/10.11607/jip.5400> PMID:29084305
9. Wismeijer D, Van Waas MA, Vermeeren JI, Mulder J, Kalk W. Patient satisfaction with implant-supported mandibular overdentures: a comparison of three treatment strategies with ITI-dental implants. *International journal of oral and maxillofacial surgery.* 1997; 26(4):263-7. [https://doi.org/10.1016/S0901-5027\(97\)80864-8](https://doi.org/10.1016/S0901-5027(97)80864-8)
10. Batenburg RH, Raghoobar GM, Van OT, Heijdenrijk K, Boering G. Mandibular overdentures supported by two or four endosteal implants: A prospective, comparative study. *Int J Oral Maxillofac Implants.* 1998; 27:435–439. [https://doi.org/10.1016/S0901-5027\(98\)80032-5](https://doi.org/10.1016/S0901-5027(98)80032-5)
11. Visser A, Raghoobar GM, Meijer HJ, Batenburg RH, Vissink A. Mandibular overdentures supported by two or four endosseous implants: A 5-year prospective study. *Clinical oral implants research.* 2005; 16(1):19-25. <https://doi.org/10.1111/j.1600-0501.2004.01085.x> PMID:15642027
12. Meijer HJ, Raghoobar GM, Batenburg RH, Visser A, Vissink A. Mandibular overdentures supported by two or four endosseous implants: a 10-year clinical trial. *Clinical Oral Implants Research.* 2009; 20(7):722-8. <https://doi.org/10.1111/j.1600-0501.2009.01710.x> PMID:19489933
13. Stoker G, van Waas R, Wismeijer D. Long-term outcomes of three types of implant-supported mandibular overdentures in smokers. *Clinical oral implants research.* 2012; 23(8):925-9. <https://doi.org/10.1111/j.1600-0501.2011.02237.x> PMID:21722193
14. Burns DR, Unger JW, Coffey JP, Waldrop TC, Elswick Jr RK. Randomized, prospective, clinical evaluation of prosthodontic modalities for mandibular implant overdenture treatment. *The Journal of prosthetic dentistry.* 2011; 106(1):12-22. [https://doi.org/10.1016/S0022-3913\(11\)60088-7](https://doi.org/10.1016/S0022-3913(11)60088-7)
15. Rocuzzo M, Bonino F, Gaudio L, Zwahlen M, Meijer HJA. What is the optimal number of implants for removable reconstructions? A systematic review on implant-supported overdentures. *Clin Oral Implants Res.* 2012; 23:229–237. <https://doi.org/10.1111/j.1600-0501.2012.02544.x> PMID:23062145