

# Angiolymphoid Hyperplasia with Eosinophilia Successfully Treated with Cryotherapy

Nina Caca-Biljanovska, Irina Arsovska-Bezhoska\*

*Clinic of Dermatology, Ss Cyril and Methodius University of Skopje, Skopje, Republic of Macedonia*

## Abstract

**Citation:** Caca-Biljanovska N, Arsovska-Bezhoska I. Angiolymphoid Hyperplasia with Eosinophilia Successfully Treated with Cryotherapy. Open Access Maced J Med Sci. <https://doi.org/10.3889/oamjms.2019.110>

**Keywords:** Angiolymphoid hyperplasia with eosinophilia; Histopathology; Therapeutic approach

**\*Correspondence:** Irina Arsovska Bezhoska. Clinic of Dermatology, Ss Cyril and Methodius University of Skopje, Skopje, Republic of Macedonia. E-mail: [irina.arsovska@yahoo.com](mailto:irina.arsovska@yahoo.com)

**Received:** 27-Feb-2019; **Revised:** 06-Mar-2019; **Accepted:** 07-Mar-2019; **Online first:** 14-Mar-2019

**Copyright:** © 2019 Nina Caca-Biljanovska, Irina Arsovska-Bezhoska. This is an open-access article distributed under the terms of the Creative Commons Attribution-NonCommercial 4.0 International License (CC BY-NC 4.0)

**Funding:** This research did not receive any financial support

**Competing Interests:** The authors have declared that no competing interests exist

**BACKGROUND:** Angiolymphoid hyperplasia with eosinophilia is an uncommon, benign, vasoproliferative cutaneous neoplasm with uncertain origin. It preferably affects middle-aged adults, manifesting as plum-colored pruritic papules, nodules and plaques, which can persist indefinitely, relapsing over time. Different response/resistance to various therapeutic modalities and frequent recurrences impose a great therapeutic dilemma.

**CASE PRESENTATION:** Herein, we present a 77-year-old male patient with a 7-month-history of unrecognized cutaneous manifestations on his left shoulder and flank. Based on the investigations, the diagnosis of angiolymphoid hyperplasia with eosinophilia was established. We applied cryotherapy as a treatment of choice. The complete regression of the skin lesions and three years disease-free period was achieved.

**CONCLUSION:** Although surgery is the standard therapeutic approach, the disease recurs despite multiple surgical attempts. Therefore, we recommend cryotherapy as effective and safe treatment modalities for angiolymphoid hyperplasia with eosinophilia. Knowing the recurring nature of this disease, the patients with angiolymphoid hyperplasia should stay on short-term follow up in order to monitor if new lesions occur.

## Introduction

Angiolymphoid hyperplasia with eosinophilia (ALHE) is a rare, benign vascular disease described for the first time by Wells and Whimster in 1969 [1]. It is characterized with prominent vascular proliferation with lymphocytic and eosinophilic infiltration of the skin [2]. This vascular tumor was also named epithelioid hemangioma (EH) by Weiss and Enzinger in 1982, in order to differentiate the lesion from the malignant vascular tumor, epithelioid hemangioendothelioma [3]. ALHE usually occurs in young to middle aged adults, and it usually affects women [4]. The most frequent involved sites are head and neck (face, ear and periauricular), rarely present in other areas and organs like shoulders, trunk, extremities, hands, breast, liver, spleen, orbit and bone [5]. Oral mucosa, conjunctiva and genital area can also be affected [6].

Clinically, ALHE shows solitary or multiple, dome-shaped, smooth, erythematous/violaceous papules/nodules [7]. There are no systemic symptoms, but sometimes, the lesions may be painful, pruritic or pulsatile due to its vascular nature [8]. Usually, there is no regional lymphadenopathy or peripheral eosinophilia, but approximately 20% of patients with ALHE may show eosinophilia [9]. ALHE grows slowly and can persist indefinitely [10]. Some cases clear up spontaneously, without any treatment, but more often, persistent and recurrent lesions require medical treatment [11].

We report a case of a male patient with a 7-months history of cutaneous lesions and histological characteristics compatible with ALHE. After cryotherapy, the complete healing of skin lesions was achieved. He is three years disease-free, without any recurrence.

## Case Presentation

A 77-year-old man was referred to our clinic due to 7-months history of multiple, pruritic, occasionally painful, erythematous/violaceous papulo/nodular and plaques-like lesions on left shoulder and trunk/flunk (Figure 1). During that period, lesions increased in number and size, without any signs of spontaneous remission. The patient noticed crusting and bleeding from his certain lesions. He has unremarkable medical and family history. No systemic symptoms or palpable regional lymphadenopathy were detected. A laboratory workup was conducted in addition to an excisional biopsy of one skin lesion. All laboratory investigations, including serum IgE level, were within normal range.

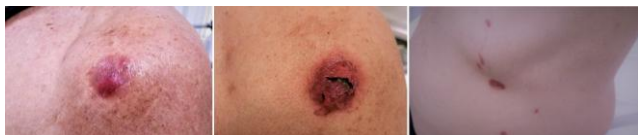

Figure 1: Angiolymphoid hyperplasia with eosinophilia: erythematous/violaceous colored papules, nodules involving the left shoulder and trunk. Superficial crusting and bleeding are observed

Skin biopsy from the lesion showed prominent vascular proliferation, epithelioid-like endothelial cells, with typical presentation of “hobnail” in the lumen of the vessels (Figure 2a and 2b). Polymorphous inflammatory infiltrate composed primarily of histiocytes and eosinophils with secondary lymphoid follicles formation were also noted (Figure 3). Immunohistochemical studies showed positive CD20, reflecting the B-cell nature of the infiltrate (Figure 4). According to these findings, the confident diagnosis of angiolymphoid hyperplasia with eosinophilia was established.

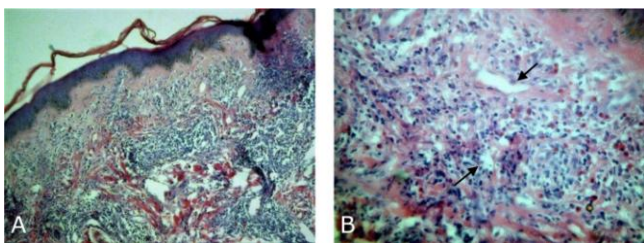


Figure 2: a) Histopathology of the skin lesion (H&E): prominent vascular proliferation; b) Epithelioid-like endothelial cells, with typical presentation of “hobnail” in the lumen of the vessels

Our treatment of choice was open spray techniques of cryotherapy with schedule of one session in every three weeks. Two freeze-thaw cycles with 15-s freezing and 1-min thawing per session. Number of treatment sessions was 3. A complete regression of skin lesions, without any recurrence during three years of follow-up was achieved (Figure 5).

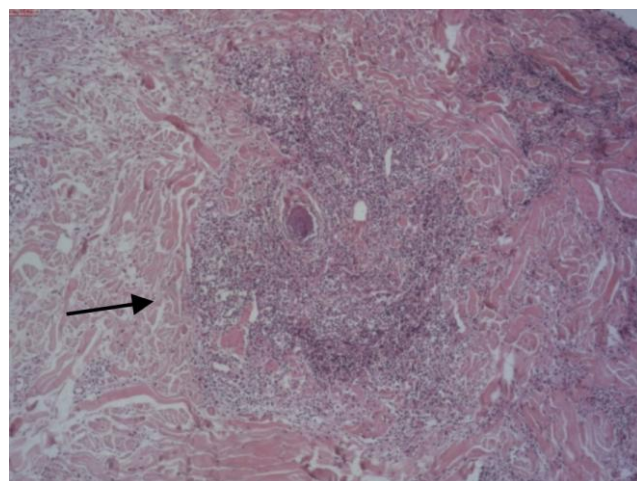


Figure 3: Histopathology of the skin lesion (H&E): polymorphous inflammatory infiltrate composed primarily of histiocytes and eosinophils with secondary lymphoid follicles formation

## Discussion

Angiolymphoid hyperplasia with eosinophilia has been reported worldwide with an undetermined frequency. The pathogenesis of the disease is unclear [5]. Some authors consider ALHE as a benign neoplastic proliferation of endothelial cells [11], [12]. Others proposed a theory of unusual reactive hyperplasia of vascular tissue as a response to insect bite, trauma or infection [2]. Eosinophils could be actively involved in the pathogenesis of inflammatory reaction by production of nitric oxide and eosinophilic cationic protein [13].

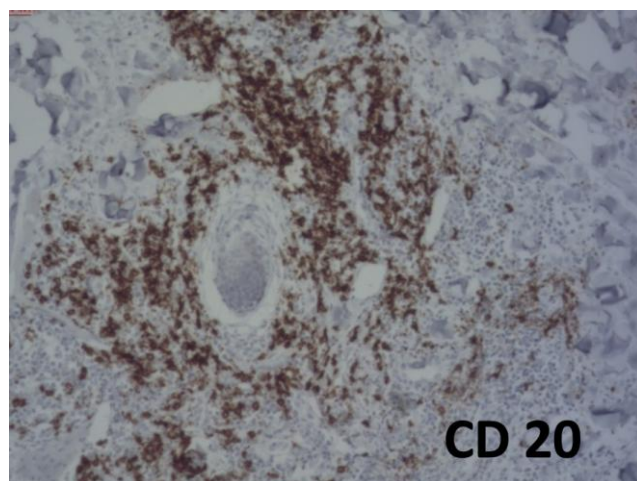


Figure 4: Immunohistochemistry: CD20 positive cells, reflecting the B-cell nature of the inflammatory infiltrate

Additional hypothesis suggest that arteriovenous shunts may play a role in the pathogenesis. In favor of the last theory, most cases of ALHE histologically show damaged and/or tortuous arteries and veins at the base of the lesion [2]. Kempf

et al., presented evidence that ALHE or its subset may represent a T-cell lymphoproliferative disorder of low-grade malignancy [14]. This hypothesis is based on the predominance of T lymphocytes and a rearrangement in TCR receptor in some cases [14]. Therefore, immunohistochemistry could be useful in some cases. Immunohistochemistry in our patient showed CD20+ cells, reflecting the B-cell nature of the inflammatory infiltrate in dermis.

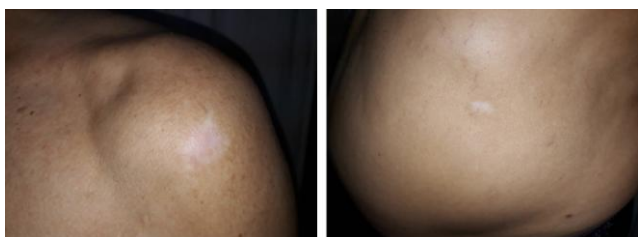


Figure 5: Clinical picture after treatment

Differential diagnosis of ALHE includes Kimura disease, cutaneous lymphoma, Kaposi sarcoma, pyogenic granuloma and cutaneous metastases [5]. Kimura disease clinically presents as large deep nodules covered by normal skin associated with adenomegaly and increased serum eosinophils and IgE [12].

In our case, the immunohistochemistry rules out all other differential diagnosis.

Diagnosis of ALHE is based on clinical, biochemical and unique histopathological findings. All these criteria were fulfilled in the presented case.

ALHE proves a great therapeutic dilemma, because there are a large variety of proposed treatments, yet there is not enough data on most of them. Many therapeutic procedures have been proposed including electrodesiccation, surgical excision, Mohs surgery, cryotherapy, topical or systemic corticosteroids, topical tacrolimus, imiquimod or laser therapy [11]. Surgery may be efficient in limited lesions, but recurrences are observed in 40% of the cases, due to its difficulty to determine the surgical margins [4]. Our patient actually refused surgical procedure and opted for cryotherapy, considering our explanation about the recurring nature of ALHE. However, our therapeutic approach with cryotherapy resulted in a complete regression of the skin lesions without any recurrence in the three years follow-up duration. There is no report available in the literature to date which shows long remission period after successful treatment of ALHE with cryotherapy.

In conclusion, the pathogenesis of ALHE still remains unclear and there is no consensus on the best treatment choice. Although the disease is not life threatening, it usually presents with disfiguring lesions that affect the quality of life. Further research is needed to find an effective cure and standardized

therapeutic approach for this dysmorphic and recurrent condition.

## References

1. Wells GC, Whimster IW. Subcutaneous angiolymphoid hyperplasia with eosinophilia. *Br J Dermatol.* 1969; 81(1):1-14. <https://doi.org/10.1111/j.1365-2133.1969.tb15914.x>
2. Tirumalasetti N. Angiolymphoid hyperplasia with eosinophilia: A rare benign vascular tumor of breast. *Indian J Pathol Microbiol.* 2013; 56:405-7. <https://doi.org/10.4103/0377-4929.125352> PMID:24441232
3. Weiss SW, Enzinger FM. Epithelioid hemangioendothelioma: a vascular tumor often mistaken for a carcinoma. *Cancer.* 1982; 50(5):970-81. [https://doi.org/10.1002/1097-0142\(19820901\)50:5<970::AID-CNCR2820500527>3.0.CO;2-Z](https://doi.org/10.1002/1097-0142(19820901)50:5<970::AID-CNCR2820500527>3.0.CO;2-Z)
4. Gupta M. Angiolymphoid hyperplasia with eosinophilia: A report of three cases. *Our Dermatol Online.* 2018; 9 (2):167-9. <https://doi.org/10.7241/ourdo.2018.16>
5. Guo R, Gavino AC. Angiolymphoid Hyperplasia with Eosinophilia: *Arch Pathol Lab Med.* 2015; 139:683-6. <https://doi.org/10.5858/arpa.2013-0334-RS> PMID:25927152
6. Dewan P, Francis ND, Lear JT, Bunker CB. Angiolymphoid hyperplasia with eosinophilia affecting the penis. *Br J Dermatol.* 2008; 159(3):755-7. <https://doi.org/10.1111/j.1365-2133.2008.08733.x> PMID:18627371
7. Olsen TG, Helwig EB. Angiolymphoid hyperplasia with eosinophilia: a clinicopathologic study of 116 patients. *Journal of the American Academy of Dermatology.* 1985; 12(5):781-96. [https://doi.org/10.1016/S0190-9622\(85\)70098-9](https://doi.org/10.1016/S0190-9622(85)70098-9)
8. Esteves P, Barbalho M, Lima T, Quintella L, Niemeyer-Corbellini JP, Ramos-E-Silva M et al. Angiolymphoid Hyperplasia with Eosinophilia: A Case Report. *Case Rep Dermatol.* 2015; 7:113-6. <https://doi.org/10.1159/000381843> PMID:26120306 PMID:PMC4478319
9. Leiferman KM, Peters MS. Angiolymphoid hyperplasia with eosinophilia and Kimura disease. *Fitzpatrick's Dermatology in General Medicine.* 2008; 7:313-4.
10. Chun SI, Ji HG. Kimura's disease and angiolymphoid hyperplasia with eosinophilia: clinical and histopathologic differences. *J Am Acad Dermatol.* 1992; 27:954-8. [https://doi.org/10.1016/0190-9622\(92\)70293-O](https://doi.org/10.1016/0190-9622(92)70293-O)
11. Youssef A, Hasan AR, Youssef Y, Al-Soufi L, Elshimali Y, Alshehbi Z. Angiolymphoid hyperplasia with eosinophilia: a case report. *J Med Case Rep.* 2018; 12:89. <https://doi.org/10.1186/s13256-018-1599-x> PMID:29606120 PMID:PMC5879596
12. Budimir I, Demirovic A, Ivekovic R, Pazanin L. Epithelioid hemangioma of the orbit. *Acta Clin Croat.* 2015; 54:92-5. PMID:26058249
13. Andrae J, Galle C, Magdorf K, Staab D, Meyer L, Goldman M, Querfeld U. Severe atherosclerosis of the aorta and development of peripheral T-cell lymphoma in an adolescent with angiolymphoid hyperplasia with eosinophilia. *Br J Dermatol.* 2005; 152:1033-8. <https://doi.org/10.1111/j.1365-2133.2005.06421.x> PMID:15888166
14. Kempf W, Haefner AC, Zepter K, Sander CA, Flaig MJ, Panizzon RG, et al. Angiolymphoid hyperplasia with eosinophilia: Evidence for a T-cell lymphoproliferative origin. *Hum Pathol.* 2002; 33:1023-9. <https://doi.org/10.1053/hupa.2002.128247> PMID:12395376