

Pulmonary Embolism Masquerading as Severe Pneumonia: A Case Report

Alvin Oliver Payus^{1*}, Rathika Rajah², Dayang Corieza Febrany¹, Norlaila Mustafa²

¹Faculty of Medicine and Health Science, Universiti Malaysia Sabah (UMS), Jalan UMS, 88400 Kota Kinabalu, Sabah, Malaysia; ²Department of Internal Medicine, Universiti Kebangsaan Malaysia Medical Centre (UKMMC), Jalan Yaacob Latif, 56000 Cheras, Kuala Lumpur, Malaysia

Abstract

Citation: Payus AO, Rajah R, Febrany DC, Mustafa N. Pulmonary Embolism Masquerading as Severe Pneumonia: A Case Report. Open Access Maced J Med Sci. <https://doi.org/10.3889/oamjms.2019.114>

Keywords: De novo pulmonary embolism; Deep vein thrombosis; Severe pneumonia; Computed tomography of pulmonary angiography

***Correspondence:** Alvin Oliver Payus, Faculty of Medicine and Health Science, Universiti Malaysia Sabah (UMS), Jalan UMS, 88400 Kota Kinabalu, Sabah, Malaysia. E-mail: dralvinpayus@ums.edu.my

Received: 25-Dec-2018; **Revised:** 18-Jan-2019; **Accepted:** 20-Jan-2019; **Online first:** 10-Feb-2019

Copyright: © 2019 Alvin Oliver Payus, Rathika Rajah, Dayang Corieza Febrany, Norlaila Mustafa. This is an open-access article distributed under the terms of the Creative Commons Attribution-NonCommercial 4.0 International License (CC BY-NC 4.0)

Funding: This research did not receive any financial support

Competing Interests: The authors have declared that no competing interests exist

BACKGROUND: De novo pulmonary embolism (DNPE) is a term used when pulmonary embolism (PE) occur in the absence of deep vein thrombosis (DVT). Most DNPE cases occur in a patient who had a recent injury to the chest.

CASE PRESENTATION: However, here we report a case of DNPE with a slightly different presentation where there is no preceding trauma and has symptoms that mimic severe pneumonia. He presented with high fever, dyspnoea and pleuritic chest pain. Despite on 10 L of oxygen supplementation via high flow mask and already given bolus intravenous antibiotic, the patient still tachypnoeic and was persistently in type I respiratory failure. His chest X-ray showed consolidative changes. Upon further investigation revealed no evidence of DVT on Doppler ultrasound and normal D-dimer level. Due to the high index of suspicion by the attending physician, PE was suspected and later confirmed with computed tomography pulmonary angiography scan. He was successfully treated with anticoagulation therapy. The objective of this case report is to share the difficult experience of diagnosing PE when the presentation highly atypical and mimics severe pneumonia.

CONCLUSION: And with such a masquerading presentation, one can easily miss the diagnosis. To the best of our knowledge, there are very few similar cases reported.

Introduction

Pulmonary embolism (PE) is a serious medical condition that occurs when a clot usually from the deep vein thrombosis (DVT) dislodged and occluded the pulmonary circulation. It is clinically manifested as shortness of breath, pleuritic chest pain, coughing, orthopnoea, haemoptysis and much other less common presentation [1]. If the PE is massive, the patient can even present with circulatory collapse. When an established PE occurs without any evidence of DVT, the condition is deemed to be called de novo pulmonary embolism (DNPE). A recent study showed that DNPE is not uncommon, and it is associated with a patient who has a history of recent trauma or accident, especially to the chest. However,

here we present a patient who developed PE but has no history of recent trauma. Subsequent investigations noted that the patient has no evidence of DVT and any intracardiac clots or vegetations from echocardiography. Therefore, it is deemed suitable for this patient to be labelled as DNPE and will be the centre of the discussion of this case report.

Case Report

A 70-year old man with underlying hypertension, diabetes mellitus, dyslipidaemia and ischemic heart disease who had undergone multiple percutaneous coronary interventions between the

year 2009 to 2012, was referred from another tertiary hospital after being admitted there for eight days for degenerative spinal disease and prolapse intervertebral disc involving the L3/L4, L4/L5 and L5/S1. He has no history of recent trauma, fall or accident before that admission. In that hospital, he was managed conservatively with only physiotherapy and analgesia. The patient went back home for a few days before current admission, and he was partially bed bound where he spent most of his time in bed and did not ambulate much due to the severe back pain. Upon arrival at the emergency department, he was febrile with a temperature of 38.7°C and breathless with the oxygen saturation of 90% on air. His pulse rate was 114 beats per minute, irregularly irregular rhythm and has good volume. His blood pressure was 130/80 mmHg unsupported.

Further history from the family member noted that the patient has been having a fever and feeling unwell for the past 2 days. On examination, the patient was obese and tachypnoeic. There was reduced breath sound, and coarse crackles heard over the right lower zone. Examination of the cardiovascular system was unremarkable; his abdomen was mildly distended but otherwise soft, not tender and no palpable organomegaly. The muscle power of his lower limbs was reduced to 2/5 from the hip downward. Electrocardiogram (ECG) showed atrial fibrillation with normal ventricular response Q-wave over the inferior lead and no acute ischemic changes. Preliminary blood investigations were done (as shown in Table 1).

Table 1: Initial blood investigation taken upon arrival to the emergency department showed marked leucocytosis and mild renal impairment. Otherwise, no elevated liver enzyme, coagulation profile was normal, no elevated cardiac enzyme, and the D-dimer was not raised

TEST	VALUE	NORMAL RANGE
Haemoglobin	11.8 g/dL	12 – 18 g/dL
Haematocrit	37.1%	35 – 48%
White cell count	27.1 x 10 ⁹ /L	4.0 – 11.0 x 10 ⁹ /L
Platelet	415 x 10 ⁹ /L	150 – 400 x 10 ⁹ /L
Urea	15.7 mmol/L	1.7 – 8.0 mmol/L
Creatinine	103.9 umol/L	60 – 120 umol/L
Sodium	133 mmol/L	135 – 150 mmol/L
Potassium	4.3 mmol/L	3.5 – 5.0 mmol/L
ALT	32 u/L	5 – 35 u/L
ALP	38 u/L	30 – 100 u/L
PT	14.2 second	11.8 – 14.5 second
aPTT	44.3 second	30.0 – 44.5 second
INR	1.09	< 1.1
D-dimer	0.35 mg/L	< 0.5 mg/L

ALT = Alanine aminotransferase ALP = Alkaline phosphatase; PT = Prothrombin time; aPTT = Activated partial thromboplastin time; INR = International Normalised Ratio.

The initial impression was severe community-acquired pneumonia given the respiratory symptoms associated with high fever and leucocytosis. Intravenous (IV) Ceftriaxone 2 gm once daily was started. However, despite on 10 L oxygen supply via a high flow mask, the patient was still tachypnoeic and oxygen saturation still lingering over the 90%. Repeated arterial blood gas still showed type 1 respiratory failure without any improvement. Chest X-ray showed mild consolidation over the right lower zone (as shown in Figure 1), which coincide with

clinical finding of coarse crackles on that area.

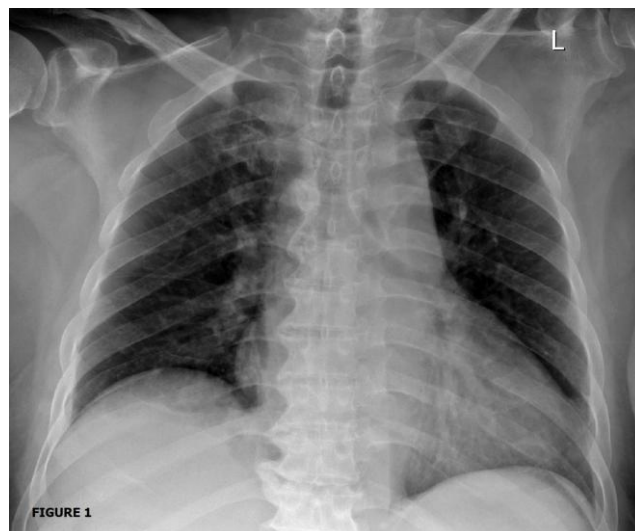


Figure 1: Chest X-ray is taken a few hours after arrival showed minimal consolidation over the right lower zone

Given the atypical presentation of pneumonia and high suspicion of pulmonary embolism, the respiratory physician was referred to review the patient. Although Well's score was only 1.5 which was low, given the risk of partial immobilisation for a few days before referral and also having persistent type 1 respiratory failure despite on oxygen supplementation, he was subjected to Computed Tomographic Pulmonary Angiography scan. The scan showed impaired filling over the secondary branch of the descending right pulmonary artery (as shown in Figure 2a and 2b), in keeping with the diagnosis of pulmonary embolism. There was also right-sided pleural effusion and collapsed consolidation over the ipsilateral posterobasal segment of the lower lobe.

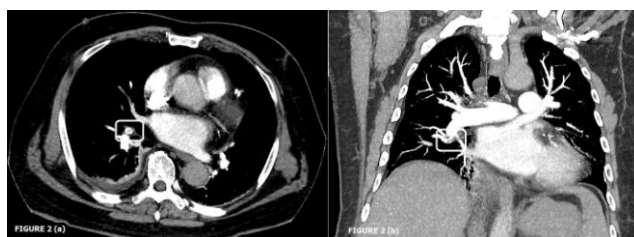

Figure 2: a) Computed Tomography of Pulmonary Angiography (CTPA) Axial view of the thorax showing pulmonary embolus effecting the secondary branch of descending right pulmonary artery. The partial central filling defect surrounded by contrast material produces polo mint sign, in keeping with acute embolus; b) CTPA Coronal view of the thorax shows filling defect of the right basal trunk with no extension into the right lower lobe segmental branch

He was immediately started on subcutaneous Fondaparinux 10 mg once daily and then overlapped with oral warfarin a few days after his condition stabilised. After he achieved his target INR of between 2 to 3, the subcutaneous Fondaparinux was subsequently discontinued. The oral warfarin was

planned to continue for 3 months. The patient has shown great recovery and able to maintain good oxygenation with spontaneous respiration on air. His antibiotic was changed to IV tazobactam 0.5 mg and piperacillin 4mg three times daily given recent hospital admission and was continued for a week. Upon further investigation, Duplex Doppler ultrasonography of the lower limb was done and showed no evidence of deep veins thrombosis. Echocardiograph was also done and show good left ventricular ejection fraction, no abnormal motility of the ventricular wall, no dilated chambers, and no vegetations or clots visible.

Discussion

Pulmonary embolism (PE) is a life-threatening condition that occurs when a dislodged blood clots usually from the deep vein of lower limb occluding the pulmonary vessel. It is clinically manifested as shortness of breath, pleuritic chest pain, coughing, orthopnoea, painful swelling over the calf or thigh, wheezing, haemoptysis and less commonly heart arrhythmia. It can also present with a syncopal attack or more devastatingly as circulatory collapse [1]. The best modality or so-called "gold standard" investigation to diagnose PE is pulmonary angiogram. However, due to the adverse effect and the limited availability of the modality, the best alternative will be Computed Tomography Pulmonary Angiography (CTPA). It has high sensitivity and specificity to diagnose PE which will show filling defect upon contrast enhancement in the pulmonary artery or any of its branches [2]. If CTPA is contraindicated (e.g. patient with a history of contrast allergy, hypotensive, has advanced heart failure, unable to lie flat or morbidly obese and unable to perform CT scan, etc), or when the CTPA finding is inconclusive, and further testing is required, ventilation-perfusion (V/Q) scanning is recommended. V/Q scan has slightly lower sensitivity, and specificity compared to CTPA and will show impaired perfusion with normal ventilation in PE [3]. Other modality to diagnose PE includes echocardiography and also measuring the level of D-dimer in the body. Echocardiography is usually done over the bedside especially in condition when other preferable modalities are not available or when the patient condition is too unstable to transfer, and it will show a nonspecific right ventricle (RV) strain in PE, such as enlarged RV size with reduced functionality, abnormal septal wall movement, and tricuspid regurgitation. Sometimes, RV thrombi can be visualised in echocardiography and usually signify a poor prognosis. The d-dimer level is usually measured when all other modalities are unavailable or in a condition when a patient with high risk but has normal CTPA finding. However, normal D-dimer level does not rule out pulmonary embolism [4], as we see in our patient where the D-dimer level was not elevated.

The management algorithm for PE begins by assessing the severity of the condition [5]. In a hemodynamically unstable patient (systolic blood pressure below 90 mmHg or a drop of more than 40 mmHg from baseline), thrombolysis may be warranted [6]. And if thrombolysis failed or contraindicated, embolectomy sometimes performed. In a hemodynamically stable patient, on the other hand, anticoagulation medication will be started as soon as possible and continued for a certain duration depending on whether the PE is provoked or not. And if the patient developed another episode of PE while on anticoagulation therapy, a longer period of treatment or maybe lifelong maybe indicated. If there is any contraindication for anticoagulation therapy, inferior vena cava (IVC) filter can be inserted in the source of emboli is from deep vein thrombosis (DVT). And once the patient is suitable for anticoagulation medication, it should be started immediately, and the IVC filter should be removed [7].

It is strongly believed that most PE patients have underlying DVT and that the occluding clots in the pulmonary vasculature are dislodged from DVT. Some even claim that PE and DVT are the clinical manifestations of the same entity, which is called venous thromboembolic disease [8]. Until recently, Van Gent JM et al., [2014] reported that PE could occur without DVT especially in a patient who had recent trauma. He also suggested that DNPE most likely occur in response to injury or inflammation [9]. However, there was a slightly different presentation in this case report, whereby our patient who was obese and has a short history of recent partial immobilisation due to severe back pain secondary to degenerative spinal disease and intervertebral prolapse disc, developed PE. Upon further investigation noted that there was no evidence of DVT nor any intracardiac clots or vegetation. And unlike what has been reported by Van Gent JM et al., our patient has no preceding history of trauma. Another peculiar thing about this case was the initial presentation of the patient which was rather not typical and can be easily missed, especially to those who work in the setting with no CTPA or V/Q scan modality.

In conclusion, this case report served only to share the diagnostic challenge in treating a patient with pulmonary embolism (PE) who presented with a clinical manifestation that mimics severe pneumonia. It is by-all-mean not to recommend the reader to treat all patient with a similar presentation as PE, but to keep PE as one of the possible causes in mind whenever treating a patient with a similar presentation.

Consent

Written informed consent was obtained from the patient to publish this case report.

Acknowledgement

The authors would like to thank the patient and his family for their cooperation about the writing of this report. The authors would also like to thank the Director General of Health Malaysia for his permission to publish this article.

References

1. Stein PD, Beemath A, Matta F, et al. Clinical characteristics of patients with acute pulmonary embolism: data from PIOPED II. *Am J Med.* 2007; 120:871. <https://doi.org/10.1016/j.amjmed.2007.03.024> PMID:17904458 PMCID:PMC2071924
2. Remy-Jardin M, Pistolesi M, Goodman LR, et al. Management of suspected acute pulmonary embolism in the era of CT angiography: a statement from the Fleischner Society. *Radiology.* 2007; 245:315. <https://doi.org/10.1148/radiol.2452070397> PMID:17848685
3. Anderson DR, Kahn SR, Rodger MA, et al. Computed tomographic pulmonary angiography vs ventilation-perfusion lung scanning in patients with suspected pulmonary embolism: a randomized controlled trial. *JAMA.* 2007; 298:2743. <https://doi.org/10.1001/jama.298.23.2743> PMID:18165667
4. Gibson NS, Sohne M, Gerdes VE, Nijkeuter M, Buller HR. The importance of clinical probability assessment in interpreting a normal d-dimer in patients with suspected pulmonary embolism. *Chest.* 2008; 134(4):789-93. <https://doi.org/10.1378/chest.08-0344> PMID:18641091
5. Tapson VF, Hockberger RS. Treatment, prognosis, and follow-up of acute pulmonary embolism in adults. UpToDate, Waltham, MA (consultado 20-02-2017).
6. Kearon C, Akl EA, Comerota AJ, et al. Antithrombotic therapy for VTE disease: Antithrombotic Therapy and Prevention of Thrombosis, 9th ed: American College of Chest Physicians Evidence-Based Clinical Practice Guidelines. *Chest.* 2012; 141:e419S.
7. Chow FC, Chan YC, Cheung GC, Cheng SW. Mid- and long-term outcome of patients with permanent inferior vena cava filters: a single center review. *Ann Vasc Surg.* 2015; 29:985. <https://doi.org/10.1016/j.avsg.2015.01.009> PMID:25757994
8. Lucena J, Rico A, Vázquez R, et al. Pulmonary embolism and sudden—unexpected death: Prospective study on 2477 forensic autopsies performed at the Institute of Legal Medicine in Seville. *Journal of forensic and legal medicine.* 2009; 16(4):196-201. <https://doi.org/10.1016/j.jflm.2008.08.015> PMID:19329075
9. Van Gent JM, Zander AL, Olson EJ, et al. Pulmonary embolism without deep venous thrombosis: De novo or missed deep venous thrombosis? *Journal of Trauma and Acute Care Surgery.* 2014; 76(5):1270-4. <https://doi.org/10.1097/TA.0000000000000233> PMID:24747459