

Successful Endovascular Treatment of a Giant Hepatic Artery Aneurysm with Dual Layer Stents Placement as Flow-Diverting Option: Case Report

Aleksandar Gjoreski^{1*}, Filip Risteski¹, Gjorgji Damjanoski²

¹Department for Diagnostic and Interventional Radiology, General City Hospital 8th September, Skopje, Republic of Macedonia; ²Private Radiological Health Organization, Megamed, Skopje, Republic of Macedonia

Abstract

Citation: Gjoreski A, Risteski F, Damjanoski G. Successful Endovascular Treatment of a Giant Hepatic Artery Aneurysm With Dual Layer Stents Placement as Flow-Diverting Option: Case Report. Open Access Maced J Med Sci. <https://doi.org/10.3889/oamjms.2019.120>

Keywords: Visceral artery aneurysms; hepatic artery aneurysm (HAA); case report

***Correspondence:** Aleksandar Gjoreski, Department for Diagnostic and Interventional Radiology, General City Hospital 8th September, Skopje, Republic of Macedonia. E-mail: acegoreski@yahoo.com

Received: 10-Dec-2018; **Revised:** 30-Jan-2019; **Accepted:** 01-Feb-2019; **Online first:** 14-Feb-2019

Copyright: © 2019 Aleksandar Gjoreski, Filip Risteski, Gjorgji Damjanoski. This is an open-access article distributed under the terms of the Creative Commons Attribution-NonCommercial 4.0 International License (CC BY-NC 4.0)

Funding: This research did not receive any financial support

Competing Interests: The authors have declared that no competing interests exist

BACKGROUND: Visceral artery aneurysms are rare conditions. The incidence of hepatic artery aneurysm (HAA) accounts for approximately 20% of all splanchnic aneurysms. HAA can become a life-threatening situation because there is a great risk of rupture when it grows more than 2 cm in diameter.

CASE PRESENTATION: In this article, we describe a case of a 54-year-old female patient with large hepatic artery aneurysm which was incidentally founded. From symptoms, she had abdominal discomfort slightly worsening after meals, frequent pain in mesogastrium and reported some unexplained weight loss in the last few months. The lesion was detected by CT examination of the abdomen and pelvis.

CONCLUSION: The aneurysm was successfully treated at our department with the endovascular approach, by covering the aneurysmal sac with two stents, one closed cell and one double-layer micromesh new generation stent as a flow diverting option.

Introduction

Visceral artery aneurysms (VAAs) and pseudoaneurysms (VAPAs) are rare lesions among other vascular diseases with an incidence from 0.01-2%, although the real percentage is not known because of their asymptomatic nature [1]. The incidence of hepatic artery aneurysm (HAA) is a relatively rare condition, accounting for approximately 20% of all splanchnic aneurysms. Within all splanchnic aneurysms, HAAs are not uncommon, being on the second place just after splenic aneurysms [2], [3].

True aneurysms and pseudoaneurysms of the hepatic artery can become life-threatening situation because of their increased risk of rupture [4], [5]. In the majority of the cases patients remain asymptomatic. Thus HAAs are often detected

incidentally by routine computed tomography (CT), magnetic resonance (MR) or abdominal ultrasonography (US) examinations. When the diameter of the aneurysm increases, patients tend to present with nonspecific symptoms such as upper abdominal pain, back pain or unexplained discomfort. Rupture of HAA can cause abdominal bleeding, jaundice, hypotensive shock, biliary tract bleeding and sometimes gastroduodenal bleeding. The mortality rate at the time of rupture is reported to be as high as 20%, so if an HAA is detected incidentally an early treatment is desirable. Before the era of endovascular techniques, open surgical aneurysmectomy with or without reconstruction was the conventional treatment for HAA [4]. In recent years, with the advances of new tools and embolisation materials, endovascular treatment, a minimally invasive and safe method has been applied by interventional radiologists to treat HAAs, giving satisfactory results [4], [5].

In this article, we present a case of a giant hepatic artery aneurysm that was successfully treated with 2 stents, one closed cell and one double-layer micromesh stent as a flow diverting option.

Case Presentation

During routine abdominal US examination due to unexplained abdominal discomfort and loss of weight a hypervascular mass in the upper abdomen was found. The lesion was located at the hilum of the liver, between the left and right lobes described as a possible pancreatic mass in the region of the head of the pancreas with consecutive stenosis of the main trunk of portal vein at this level.

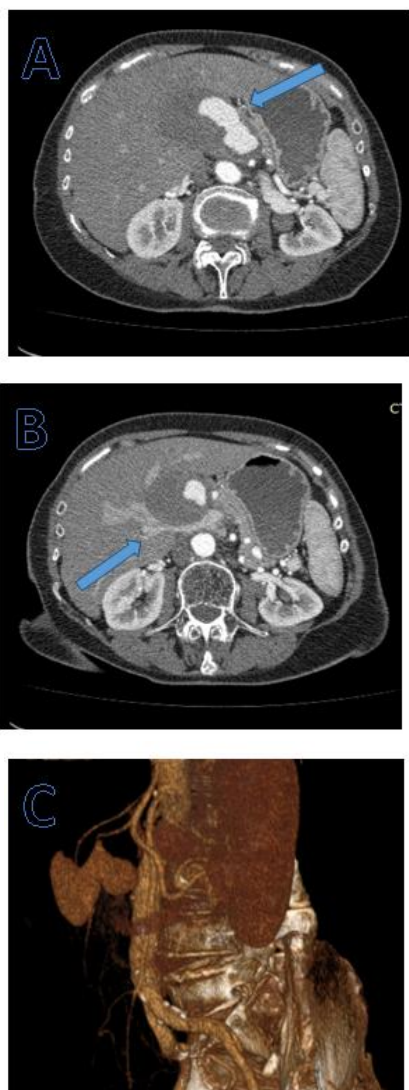


Figure 1: Computed tomography CT findings. A) and B) Enhanced axial abdominal CT scans show large, irregular pseudoaneurysm of common hepatic artery with partially thrombosed wall and compression of the portal vein (arrows); C) 3-dimensional VR angiography shows the aneurysm with wide neck arising from vertically oriented CHA

The patient had neither history of previous abdominal trauma nor a family history of the aneurysmal disease. The only fact that she gave was a severe peritoneal infection after childbirth more than 20 years ago. Standard multiphase multidetector computed tomography- MDCT of the upper abdomen was performed, and large aneurysm of the common hepatic artery was detected. Common hepatic artery was with an extremely vertical course and proper hepatic artery, and gastroduodenal arteries were patent.

The aneurysm was approximately 70 mm in its largest diameter with the very big active portion of 50 mm, mural thrombosis and ill-defined borders which can be a radiological sign of pseudoaneurysm. Also, the neck of the aneurysm was very wide.

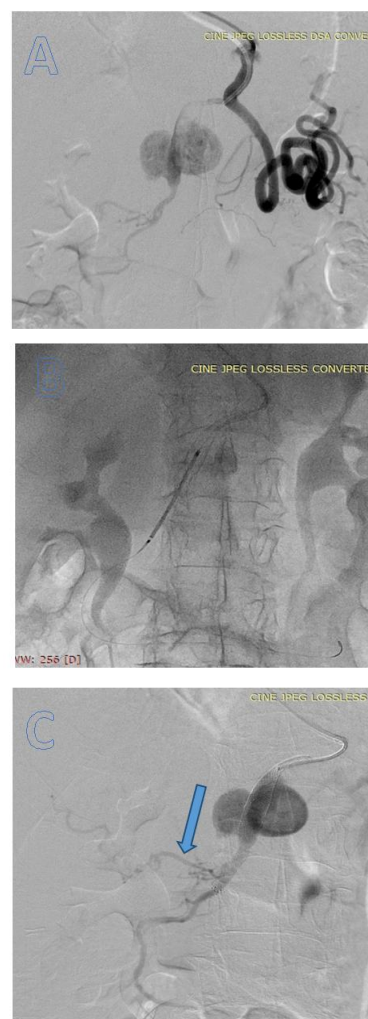

Figure 2: Angiographic findings and treatment. A) Celiac trunk arteriography in 30° left anterior oblique projection shows the aneurysm at the distal site of common hepatic artery; B) Guidewire placed deeply in GDA and 2 carotid stents placed along the neck with complete overstenting; C) Poststenting angiography shows patency of both stents and reduced flow in the aneurysmal sac, patent proper hepatic artery with distal origin (arrow)

There was compression of the main trunk of the portal vein with consecutive stenosis (Figure 1 A, B, C). Our treatment strategy was to go with an

endovascular approach first with stent placement as a flow diverting option because coiling alone seemed to be impossible due to its irregular wide neck.

Because of the vertical origin of the celiac trunk (Figure 1, C), we decided that a brachial approach was more suitable than femoral in this case. A 90 cm long, MP shaped, 6F guiding sheath (Destination, Terumo) was placed in the celiac trunk through left brachial approach. Manipulation with catheters through a brachial approach was not very easy in this particular case because of high tortuosity of the thoracoabdominal aorta. Dynamic angiography of the celiac trunk was performed which showed the common hepatic artery aneurysm with very turbulent flow in the sac (Figure 2 A).

Proper hepatic artery origin was unusually distal, and both left and right hepatic arteries were gracile. The gastroduodenal artery was with a normal calliper. The wide aneurysm neck was successfully crossed with a guidewire (260 cm Advantage, Terumo, 0.014") and then the wire was placed deeply into the gastroduodenal artery. After that followed placement of 2 closed cell stents across the sac (7 x 40 mm Wallstent, Boston Scientific and 7 x 30 mm, Roadsaver, Terumo), both primarily carotid stents (Figure 2 B, C).

The final angiography showed good stent position and an immediate decrease of flow in the aneurysmal sac which led us to think that overstating the aneurysm could be a definite treatment option. All branches of the hepatic and gastroduodenal artery were preserved.

At this point, we decided to stop the procedure and follow the patient after 1-2 months with CT angiography. Hemostasis was achieved by manual compression.

Standard dual antiplatelet therapy was administered; post-stenting, with 100 mg Aspirin and 75 mg Clopidogrel per day for 3 months. The patient was discharged from the hospital the next day without any early complications and with normal laboratory liver function tests. We scheduled her for an abdominal CT angiography after one month. The control CT scan which was performed almost 40 days after the procedure showed complete thrombosis of the aneurysm with patent common hepatic artery and both stents. Good flow in the left and right hepatic arteries and GDA (Figure 3, A and B).

Patient symptoms decreased dramatically since the procedure.

After 3 months we performed DSA of the visceral arteries via right femoral approach as a final invasive control study. 5F SIM 2 catheter was used to cannulate the celiac trunk and angiography performed.

Angiography confirmed the same findings as last CT scan with excellent perfusion in the hepatic

artery, complete thrombosis and shrinkage of the aneurysm without signs of residual filling (Figure 3, C).

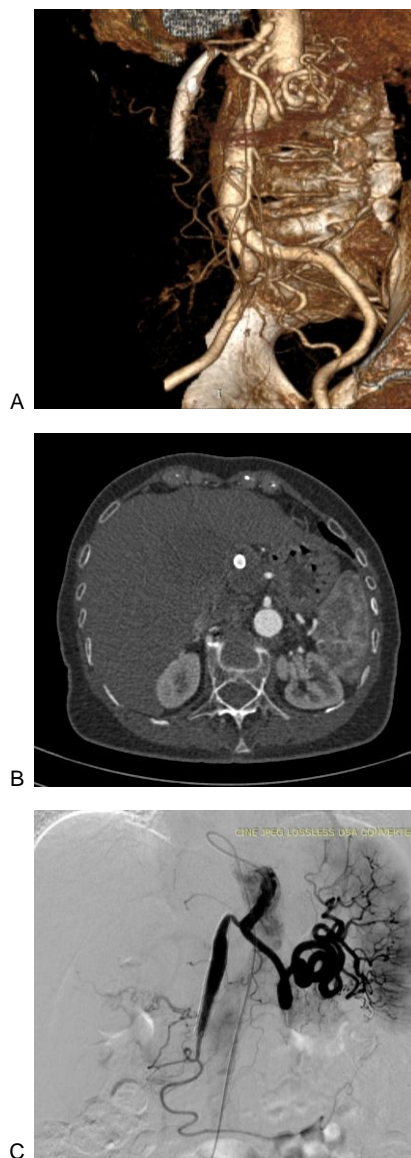


Figure 3: CT and angiographic findings post-treatment. A) and B) 3D VR angiography and axial contrast-enhanced CT 40 days post-treatment both shows good position of stents and patent CHA, complete thrombosis of the aneurysm; C) DSA three months after procedure performed via right femoral approach SIM 2 catheter used to cannulate celiac trunk, clearly confirms stents patency, no residual aneurysmal sac filling and good flow in hepatic and splenic arteries

Discussion

The incidence of hepatic artery aneurysm (HAA) is rare, accounting for approximately 20% of all splanchnic aneurysms, being in second place after splenic artery aneurysms [6], [7]. Aetiology of HAAs varies and includes abdominal trauma, infection, atherosclerosis, pancreatitis, necrotising vasculitis and other [1]. HAAs are

generally asymptomatic and usually found incidentally by CT or ultrasonography examinations. Most common symptoms are abdominal pain, obstructive jaundice, intra-abdominal or gastrointestinal haemorrhage.

HAA can become a life-threatening situation when in ruptures with mortality rates according to some reports > 25%. Treatment for HAAs is always needed and recommended when the diameter surpasses 2 cm. High mortality rates up to 50%, made the surgical repair no more preferred treatment, but the endovascular one. In this case, we chose brachial approach due to the vertical origin of the celiac trunk, and we placed two stents (Wallstent and Roadsaver) over the aneurysmal sac to simulate a covered stent and to divert the blood flow, a technique which is already established in the treatment of cerebral aneurysms. Of course, there are dedicated stents-flow diverters for this purpose in the neurovascular field. The Roadsaver stent is characterised by an external self-expanding nitinol layer and an internal micromesh layer, and Wallstent is a traditionally closed cell stent.

Reviewing the literature, we found that Akkan et al. in 2018 [8] reported the use of double-layer micromesh stent (Roadsaver, Terumo) for the treatment of 5 aneurysms (common carotid, vertebral, mesenteric and renal artery) and achieved successful embolisation in all cases only by the stent. Akasaka J. et al. 2018 [9], reported treatment of hepatic artery aneurysm with balloon occlusion technique and coils. In 2013 Sugihara et al. reported a case of proper hepatic artery embolisation with balloon-assisted occlusion of the left, right and proper hepatic artery without liver dysfunction [10]. Stent-assisted coiling, a technique that is already established in the treatment of intracranial aneurysms can also be performed for visceral aneurysms sometimes. There is no similar case in the literature like this particular one with the use of non-covered stents for treatment of HAA. Due to an immediate decrease in flow within the aneurysmal sac, we decided not to proceed with coiling in our case.

After the procedure, there were no signs of liver dysfunction or infarction. The patient was placed on dual antiplatelet therapy with 100 mg Aspirin and 75 mg of Clopidogrel per day for 3 months. Forty days after intervention CT angiography showed complete thrombosis of the aneurysmal sac with both stents completely patent and normal flow in hepatic and gastroduodenal arteries. DSA performed 3 months after embolisation confirmed successful treatment. In conclusion, we can say that embolisation with dual-layer stents alone or together with other closed cell design stent, used as “flow diverters” can be used in

the treatment of HAA in selected cases. Of course, this is an off- label use, but potentially it can be an option for some cases. The hypothesis of preserving side branches that arise from the aneurysm or close to it may be an additional potential advantage of dual layer stents over traditional stent-grafts. Of course, this is a case report only and further studies with larger cohorts are needed in future with longer follows of patients.

References

1. Chiesa R, Astore D, Guzzo G, Frigerio S, Tshomba Y, Castellano R, et al. Visceral artery aneurysms. *Ann Vasc Surg*. 2005; 19(1):42–8. <https://doi.org/10.1007/s10016-004-0150-2> PMID:15714366
2. Rothbarth LJ, Redmond PL, Kumpe DA. Percutaneous transhepatic treatment of a large intrahepatic aneurysm. *AJR Am J Roentgenol*. 1989; 153(5):1077–8. <https://doi.org/10.2214/ajr.153.5.1077> PMID:2801426
3. Venturini M, Angeli E, Salvioni M, De Cobelli F, Trentin C, Carlucci M, et al. Hemorrhage from a right hepatic artery pseudoaneurysm: endovascular treatment with a coronary stent-graft. *J Endovasc Ther*. 2002; 9(2):221–4. <https://doi.org/10.1177/152660280200900215>
4. Marone EM, Mascia D, Kahlberg A, Brioschi C, Tshomba Y, Chiesa R. Is open repair still the gold standard in visceral artery aneurysm management?. *Annals of vascular surgery*. 2011; 25(7):936-46. <https://doi.org/10.1016/j.avsg.2011.03.006> PMID:21620671
5. Tulsyan N, Kashyap VS, Greenberg RK, Sarac TP, Clair DG, Pierce G, Ouriel K. The endovascular management of visceral artery aneurysms and pseudoaneurysms. *Journal of Vascular Surgery*. 2007; 45(2):276-83. <https://doi.org/10.1016/j.jvs.2006.10.049> PMID:17264002
6. Jesinger RA, Thoreson AA, Lamba R. Abdominal and pelvic aneurysms and pseudoaneurysms: imaging review with clinical, radiologic, and treatment correlation. *Radiographics*. 2013; 33(3):E71-96. <https://doi.org/10.1148/rg.333115036> PMID:23674782
7. Hemmati H, Karimian M, Moradi H, Marandi KF, Haghdoost A. Endovascular treatment of a huge hepatic artery aneurysm by coil embolization method: a case report. *Iranian Journal of Radiology*. 2015; 12(3). <https://doi.org/10.5812/iranradiol.5200>
8. Akkan K, Ilgit E, Onal B, Cindil E, Solak EP, Oncu F, Geylan DE. Endovascular Treatment for Near Occlusion of the Internal Carotid Artery. *Clinical neuroradiology*. 2018; 28(2):245-52. <https://doi.org/10.1007/s00062-016-0546-8> PMID:27783127
9. Akasaka J, Sagushi T, Kennoki N, Shindo S. Coil Embolisation for Endovascular Treatment of Proper Hepatic Artery Aneurysm Using the Ballon Occlusion Technoqe . 2018; 41:1–4.
10. Sugihara F, Murata S, Uchiyama F, Watari J, Abe Y, Kumita S. Successful management of a proper hepatic artery aneurysm by embolization without liver dysfunction. *J Radiol Radiat Ther*. 2013; 1(2):1007.