

Primary Seminoma Localized in Mediastinum: Case Report

Deva Petrova^{*}, Slavica Krалеva, Liliјana Muratovska, Bilјana Crcareva

Acibadem Sistina Hospital, Skopje, Republic of Macedonia

Abstract

Citation: Petrova D, Krалеva S, Muratovska L, Crcareva B. Primary Seminoma Localized in Mediastinum: Case Report. Open Access Maced J Med Sci. <https://doi.org/10.3889/oamjms.2019.122>

Keywords: Mediastinum; Seminoma; Chemotherapy; Radiotherapy

***Correspondence:** Deva Petrova, Acibadem Sistina Hospital, Skopje, Republic of Macedonia. E-mail: deva.petrova@acibademсистина.mk

Received: 14-Dec-2018; **Revised:** 12-Jan-2019;
Accepted: 19-Jan-2019; **Online first:** 25-Jan-2019

Copyright: © 2019 Deva Petrova, Slavica Krалеva, Liliјana Muratovska, Bilјana Crcareva. This is an open-access article distributed under the terms of the Creative Commons Attribution-NonCommercial 4.0 International License (CC BY-NC 4.0)

Funding: This research did not receive any financial support

Competing Interests: The authors have declared that no competing interests exist

BACKGROUND: Primary mediastinal seminomas most commonly occur in young men, and they are localised in the anterior mediastinum.

CASE PRESENTATION: The presented study is a case report of a 34-year-old man suffering from a mediastinal tumour in size of 19 cm, with pleural and pericardial effusion. The patient complains of cough, difficulty breathing, weight loss, and pronounced tiredness. CT of lungs and biopsy of the mediastinal change was performed. The histopathological analysis was in favour of a primary mediastinal seminoma. The patient initially had pronouncedly increased levels of LDH and β -hCG tumour marker. Pericardiocentesis was realised due to threatening tamponade of the heart, followed by 4 cycles of chemotherapy by BEP protocol. Following 2 cycles of chemotherapy, normalisation of LDH and β -HCG levels and significantly improved the clinical condition in the patient was found. Upon completion of 4 chemotherapy cycles by BEP protocol, the patient performed an FDG-PET scan with partial response and reduced dimension of a primary tumour in the mediastinum. Radiotherapy of residual tumour mass up to a total dose of 40Gy in 20 fractions was realised. Control FDG-PET scan had a finding of complete response to a tumour and absence of FDG uptake. The last follow-up examination was performed in October 2018, and the patient was disease-free for 54 months.

CONCLUSION: Multimodality treatment approach of chemotherapy followed by radiation consolidation ensured long-term survival in primary advanced mediastinal seminoma.

Introduction

Primary extragonadal germ cell tumours occur rarely, and they include 1-5% of all germ cell malignancies [1]. The most common extragonadal localisations are mediastinum and retroperitoneum. Primary mediastinal germ cell tumours are rare lesions accounting for only 10-15% of mediastinal masses. Most of these tumours are benign lesions; however, up to one-third of them could be malignant, and seminoma is the most common histologic subtype. The primary mediastinal seminoma is a rare tumour. In general terms, mediastinal seminomas are bulky tumours, and they tend to infiltrate into adjacent structures early in the growth process. Pure seminoma is sensitive to chemotherapy and radiotherapy, and the prognosis is good [2]. These tumours typically occur in men from the second to the fourth decade of life and could be present as asymptomatic, incidentally discovered lesions in 20-30% of patients.

Case Presentation

A 34-year-old patient was diagnosed with chest pain lasting for 2-3 months. Due to pain progression, the occurrence of pronounced fatigue, cough and body weight loss (more than 15 kg), X-ray of lungs was performed with a finding of mediastinal tumour mass, and consequently, CT of lungs was performed by intravenous application of contrast. CT finding of lungs was in favour of a large expansive process in the mediastinum, with irregular form and lobular contours and dimensions of 190 x 100 x 175 mm.

The substrate compressed and displaced the vascular structures in the mediastinum, primarily the aortic arch and its arterial branches toward the dorsal region. Pulmonary arteries were also suppressed. V.cava superior was suppressed as well towards the lateral region to the right, while its lumen was partially reduced. Pleural effusion was present bilaterally, more pronounced to the left side. Enlarged lymph nodes

were detected along the substrate in the proximal segment of the mediastinum. Enlarged lymph nodes were also detected bilaterally to the neck; the largest one was located to the right at the thyroid gland level, behind the right jugular vein (Figure 1).

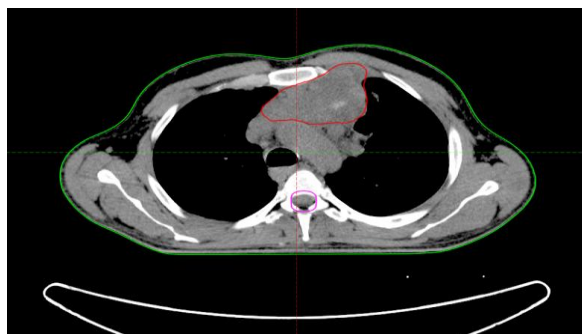


Figure 1: Computed tomography chest showing primary mediastinal seminoma with the involvement of major vessels

Fine needle biopsy and core biopsy were performed on three occasions, whereby the results were obtained in two laboratories; one of the results had undefined histology, and it was in favour of lymphoma or a tumour of neural origin, while the histopathological finding by the second laboratory was in favour of a thymoma. A third opinion indicated a finding in favour of an extragonadal seminoma. Biochemical analyses were performed resulting in pronouncedly increased levels of LDH 1482 U/L (normal range of 0-225), alkaline phosphatase level of 511 U/L (normal range of 40-129). Blood tests for germ cell tumour markers AFP were realised as well, with a normal level of 1.5 kiU/L and β -hCG with a pronouncedly increased level of 420.5 mIU/ml (normal range of 0-2.6).

Considering the increased β -hCG level in correlation with the histopathological finding for extragonadal seminoma, examination of testicles was performed to detect an occult primary testicular tumour. Normal ultrasound finding was obtained. Before the treatment initiation due to worsening of the general condition and occurrence of pronounced fatigue and suffocating, the patient performed an ultrasound examination of the heart with a finding of pericardial effusion and threatening tamponade of the heart. Pericardiocentesis was performed, and 500 ml of haemorrhagic pericardial effusion were evacuated. The patient started chemotherapy by BEP protocol, and 4 cycles of chemotherapy were realised. Following 4 cycles of chemotherapy by BEP protocol, the patient normalised the levels of LDH and alkaline phosphatase, and β -hCG level as well; clinical condition of the patient was significantly improved and following the chemotherapy he did not have symptoms of the disease.

After 4 weeks of the last chemotherapy cycle, the patient performed FDG-PET-CT scan; the result was in favour of partial response and presence of a pathologic metabolically active tumour substrate in the

mediastinum. Radiotherapy for the residual tumour mass using IMRT technique was realised; a total dose of 40 Gy was achieved in the course of 20 fractions. The treatment was performed on LINAC by using X-ray of 6 MV energy (Figure 2). The patient had no side effects related to the treatment during its realisation.

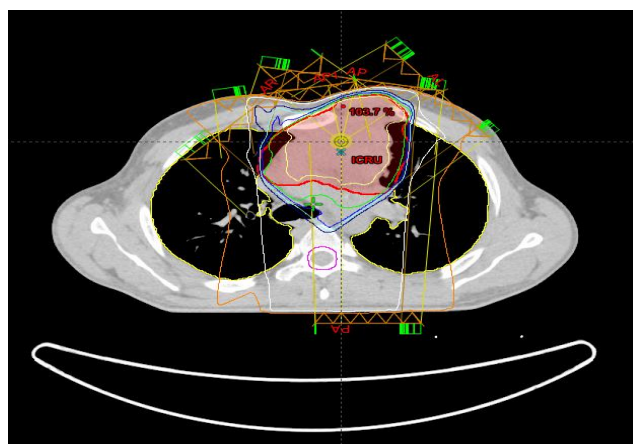


Figure 2: Radiotherapy for the residual tumour mass is realised using IMRT technique; a total dose of 40 Gy

Control FDG-PET-CT scan was performed 6 weeks after the radiation therapy, and a finding of complete response to the treatment and absence of pathologic metabolically active tumour mass in the mediastinum was obtained (Figure 3).

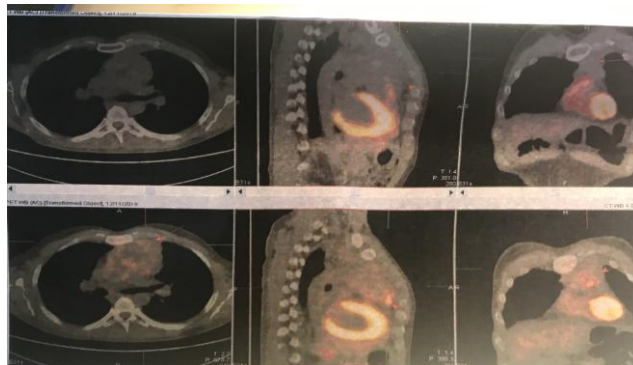


Figure 3: Comparative images from PET-CT before and after radiotherapy (upper part of a picture is PET-CT showing results after radiotherapy)

The patient continued the regular follow-up examinations, and he was disease-free for 54 months since the initial diagnosis. The last follow-up examination performed in October 2018, had a normal finding and the patient was disease-free.

Discussion

Extragonadal germ cell tumours (GCTs) typically are located along the median line of the body,

including the mediastinal and retroperitoneal spaces. Mediastinal seminomas usually affect the anterior mediastinum involving the thymus; more rarely the tumour could be presented in the middle and the posterior mediastinum. In some cases, large tumours could expand from the anterior to the medium mediastinum and lead to difficulty in distinguishing the primary tumour localisation [3].

These extragonadal tumours are considered to develop from germ cell precursors trapped during the embryonic migration and survived on ectopic localisation. Approximately 90% of primary malignant mediastinal germ cell tumours develop in male in the third decade of life. Metastatic disease occurs in less than half the cases; in case of occurrence, it is usually spread to adjacent lymph node groups in the neck, the mediastinum, or the abdomen. Hematogenous metastases are unusual but can be detected in the lungs, bones, liver, spleen, thyroid gland and brain.

Primary mediastinal seminomas are manifested by non-specific symptoms. Symptoms are closely related to tumour localisation and dimensions. The most commonly reported symptoms include chest pain, dyspnea, cough, and weight loss [4]. The prognosis for pure seminomas in the mediastinum is excellent, with a 5-year survival rate in more than 90% using appropriate therapy.

When a tumour mass in the mediastinum develops, it could be a metastatic or primary benign or malignant mediastinal tumour. Most common differentially diagnostic cases could be lymphoma, a tumour of neurogenic origin such as schwannoma; in case of the anterior mediastinum it could be a thymoma; if there are packages of lymph nodes, they could be metastatic deposits of primary lung carcinoma, or an extragonadal mediastinal seminoma or a non-seminoma tumour [5].

Considering the difficult radiology distinction of these tumours, histopathological analysis of the biopsy material is necessary for definitive diagnosis. Another complicated step in the diagnosis of these tumours is the localisation, hardly accessible for biopsy. A biopsy can be done within the mediastinoscopy, or it could be CT-guided biopsy as in the case of our patient. There is significant morphological overlapping when it comes to embryonic carcinoma or seminoma, poorly differentiated carcinomas (such as pulmonary or thymus carcinoma, and metastatic carcinomas as well). Immunohistochemical analysis by a pathologist is of particular importance to specify the diagnosis by individual elimination of these entities. During the diagnosis of a germ cell tumour, a sample of blood may be collected to test for levels of serum tumour markers. High levels of any one of three tumour markers, called alpha-fetoprotein (AFP), beta human chorionic gonadotropin (β -hCG), and lactate dehydrogenase (LDH), may indicate a germ cell tumour. High AFP levels can also help identify the

type of germ cell tumour, by showing whether it is a pure seminoma or mixed with non-seminoma, since AFP is not made by seminomas. However,

β -hCG and LDH can be higher if a man has a seminoma, non-seminoma, or mixed tumour. The diagnosis in our case was based on the histopathological finding, as well as the biochemical analysis in favour of pronouncedly increased LDH and β -HCG levels. Monitoring of serum tumour markers is significantly important for the diagnosis and prognostic evaluation of patients with mediastinal seminoma.

According to the 2010 American Society of Clinical Oncology clinical guidelines, in rare male patients presenting with testicular, retroperitoneal, or anterior mediastinal primary tumor and whose disease burden has resulted in an urgent need to start treatment, substantially elevated serum AFP and/or β -hCG may be considered sufficient for the diagnosis of GCT [6].

Patients at an early stage of mediastinal seminoma could be cured by surgical treatment and postoperative radiotherapy. Patients suffering from an advanced disease should be treated by chemotherapy and radiotherapy to achieve a good treatment result [7]. Seminoma is a highly radiosensitive tumour among mediastinal tumours, and therefore radiotherapy is considered an important treatment that increases the long-term survival rate of patients by 60-80% [8]. Clinical trials have demonstrated excellent results when multimodality chemotherapy is combined with radiation for large, localised mediastinal seminomas or extensive residual disease [9].

In conclusion, multimodality treatment approach of chemotherapy followed by radiation consolidation ensured long-term survival in primary advanced mediastinal seminoma.

References

- Hainsworth JD, Greco FA. Germ cell neoplasms and other malignancies of the mediastinum. *Cancer Treat Res*. 2001; 105:303–325. https://doi.org/10.1007/978-1-4615-1589-0_12
- Bokemeyer C, Nichols CR, Droz JP, et al Extragonadal germ cell tumors of the mediastinum and retroperitoneum: results from an international analysis. *J Clin Oncol*. 2002; 20:1864–73. <https://doi.org/10.1200/JCO.2002.07.062> PMID:11919246
- Takeda S, Miyoshi S, Ohta M, Minami M, Masaoka A, Matsuda H. Primary germ cell tumors in the mediastinum: a 50-year experience at a single Japanese institution. *Cancer*. 2003; 97:367–376. <https://doi.org/10.1002/cncr.11068> PMID:12518361
- Busch J, Seidel C, Zengerling F Male extragonadal germ cell tumors of the adult. *Oncol Res Treat*. 2016; 39:140–4. <https://doi.org/10.1159/000444271> PMID:27032104
- McKenney JK, Heerema-McKenney A, Rouse RV. Extragonadal germ cell tumors: A review with emphasis on pathologic features, clinical prognostic variables, and differential diagnostic considerations. *Adv Anat Pathol*. 2007; 14:69–92.

<https://doi.org/10.1097/PAP.0b013e31803240e6> PMID:17471115

6. Gilligan TD, Hayes DF, Seidenfeld J, Temin S. ASCO clinical practice guideline on uses of serum tumor markers in adult males with germ cell tumors. *Journal of oncology practice*. 2010; 6(4):199-202. <https://doi.org/10.1200/JOP.777010> PMID:21037873
PMCID:PMC2900872

7. Liu TZ, Zhang DS, Liang Y, Zhou NN, Gao HF, Liu KJ, Wu HY. Treatment strategies and prognostic factors of patients with primary germ cell tumors in the mediastinum. *Journal of cancer research and clinical oncology*. 2011; 137(11):1607. <https://doi.org/10.1007/s00432-011-1028-7> PMID:21850383
PMCID:PMC3193517

8. Feldman DR, Patil S, Trinos MJ, Carouso M, Ginsberg MS,

Sheinfeld J, Bajorin DF, Bosl GJ and Motzer RJ: Progression-free and overall survival in patients with relapsed/refractory germ cell tumors treated with single-agent chemotherapy: Endpoints for clinical trial design. *Cancer*. 2012; 118: 981-986. <https://doi.org/10.1002/cncr.26375> PMID:21792865

9. Huang J, Tan Y, Zhen Z, Lu S, Sun F, Zhu J, et al. Role of post-chemotherapy radiation in the management of children and adolescents with primary advanced malignant mediastinal germ cell tumors. *PLoS One*. 2017; 12(8):e0183219. <https://doi.org/10.1371/journal.pone.0183219> PMID:28813488
PMCID:PMC5558937