

The Effectiveness of Local Surgical Technique in Treatment of Axillary Bromhidrosis

Thuong Nguyen Van¹, Tan Nguyen Manh¹, Phuong Pham Thi Minh¹, Trang Trinh Minh¹, Nghi Dinh Huu¹, Kiem Pham Cao¹, Quang Nguyen Huu¹, Van Tran Cam¹, My Le Huyen¹, Khang Tran Hau¹, Marco Gandolfi², Francesca Satolli², Claudio Feliciani², Michael Tirant^{3,4}, Aleksandra Vojvodic⁵, Torello Lotti³

¹National Hospital of Dermatology and Venereology, Hanoi, Vietnam; ²Unit of Dermatology, University of Parma, Parma, Italy; ³University of Rome G. Marconi, Rome Italy; ⁴Psoriasis Eczema Clinic, Melbourne, Australia; ⁵Department of Dermatology and Venereology, Military Medical Academy of Belgrade, Belgrade, Serbia

Abstract

Citation: Nguyen Van T, Nguyen Manh T, Thi Minh PP, Trinh Minh T, Dinh Huu N, Pham Cao K, Nguyen Huu Q, Tran Cam V, Le Huyen M, Tran Hau K, Gandolfi M, Satolli F, Feliciani C, Tirant M, Vojvodic A, Lotti T. The Effectiveness of Local Surgical Technique in Treatment of Axillary Bromhidrosis. Open Access Maced J Med Sci. <https://doi.org/10.3889/oamjms.2019.133>

Keywords: Axillary bromhidrosis; Bromhidrosis

***Correspondence:** Marco Gandolfi. Unit of Dermatology, University of Parma, Parma, Italy. E-mail: marco.gandolfi5@gmail.com

Received: 02-Jan-2019; **Revised:** 16-Jan-2019; **Accepted:** 17-Jan-2019; **Online first:** 29-Jan-2019

Copyright: © 2019 Thuong Nguyen Van, Tan Nguyen Manh, Phuong Pham Thi Minh, Trang Trinh Minh, Nghi Dinh Huu, Kiem Pham Cao, Quang Nguyen Huu, Van Tran Cam, My Le Huyen, Khang Tran Hau, Marco Gandolfi, Francesca Satolli, Claudio Feliciani, Michael Tirant, Aleksandra Vojvodic, Torello Lotti. This is an open-access article distributed under the terms of the Creative Commons Attribution-NonCommercial 4.0 International License (CC BY-NC 4.0)

Funding: This research did not receive any financial support

Competing Interests: The authors have declared that no competing interests exist

BACKGROUND: Up to now, surgical excision of apocrine glands still has been a method that yields high treatment results and low rate of odour recurrent for patients, but many people worry about some serious complications that have been observed postoperatively, such as hematoma and skin necrosis. These prolong wound healing, leading to unsightly scars in the axillary fossae.

AIM: We conducted this research to investigate the effects and complications of our surgical technique for axillary bromhidrosis.

METHODS: Forty-three patients with axillary bromhidrosis were treated. An elliptical incision was made at a central portion of the area marked, with both tips of the ellipse along the axillary crease. The elliptical skin with the subcutaneous tissue was removed en lock. The adjacent skin was undermined to the periphery of the hair-bearing area with straight scissors. The undermined subcutaneous tissue was removed with curved scissors, and the skin was defatted to become a full-thickness skin flap. Any suspected hemorrhagic spots were immediately coagulated electro-surgically. Appropriate drains were placed, and the treated area was covered with thick gauze to each axilla. Arm movement was strictly controlled in the first 3 days post-operatively.

RESULTS: Thirty-one patients have been followed up and evaluated for 6 months. 56 out of 62 axillae (90.3%) showed good to excellent results for malodor elimination. All patients reported a reduction in axillary sweating. There were two axillae of skin necrosis and three axillae of hematoma, with one patient receiving an anticoagulant from a cardiologist after the first day of surgery, to treat heart valve disease. The Dermatology Life Quality Index (DLQI) score decreased significantly, and the quality of life improved after the operation.

CONCLUSION: Our technique is a simple surgical procedure and easy to perform helping to achieve results for high malodor elimination, with almost no serious complications. Patient's life quality improved significantly after the operation.

Introduction

Axillary bromhidrosis is a disease characterised by excessive malodour due to the hyperfunction of apocrine glands. Although this disease is not life-threatening, it can have a serious effect on the patients' quality of life, especially in an Asian society. Various treatment methods have been developed, but the effect of nonsurgical methods such as topical antiperspirants and deodorants, lasers and

botulinum toxin A, is temporary and limited [1], [2]. Systemic medication with anticholinergics cause major side effects, and long-term use is not possible. Thus, surgical treatment seems to be the most logical and effective method available.

Since Skoog and Thyresson introduced the first surgical treatment for axillary hyperhidrosis in 1962 [3], a variety of surgical techniques have been reported in recent years. Minimal invasive procedures, such as superficial liposuction, suction curettage,

allow for short recovery time and leave only minor scars [4]. However, the techniques are unsatisfactory to doctors and patients due to recurrent odour. Up to now, local surgical excision of apocrine glands has been a method that still yields high treatment results and low rate of odour recurrent for patients, although it is often accompanied by wound complications and relatively long recovery period [5], [6], [7], [8].

The purpose of this study is to evaluate the effectiveness and safety of local surgical technique that partially removes skin and subcutaneous cellular tissue in the treatment of axillary osmidrosis.

Methods

Patients

From July 2017 to July 2018, 43 patients were operated on for bilateral axillary bromhidrosis. All operations were carried out in our hospital. The results were assessed by the patients themselves and their family members and/or close friends. The results of malodor elimination were graded by the patients as excellent, good, fair, and poor. Elimination of sweating was evaluated using the Hyperhidrosis Disease Severity Scale (HDSS) [9]. Changes in hair growth and patient satisfaction degree were also evaluated. The quality of life was assessed using the modified Dermatology Life Quality Index [10], which includes a 10 item questionnaire aiming to measure the effects of skin problem on usual life. There were four possible answers for every question: “not at all”, “mild,” “moderate”, or “severe”, with corresponding scores of 0, 1, 2, and 3 respectively. Total scores ranged from 0 to 30, with higher scores indicating a lower quality of life. Post-operative complications were investigated.

Statistic analysis

Statistical analysis was performed using non-parametric testing, with statistical significance at the 95% level. The calculations were performed using the STATA13.0.

Surgical Technique

Patients were placed in the supine position and arms were abducted to about 90. The axillary hair-bearing area was marked before the operation. After regular sterilisation of the area, local anaesthesia was given using 0.5% lidocaine with 1:200,000 epinephrine. An elliptical incision was made at a central portion of the area marked, with both tips of the ellipse along the axillary crease. The widest diameter of the elliptical incision was 1.5 cm. The

elliptical skin with the subcutaneous tissue was removed en block. The adjacent skin was undermined to the periphery of the hair-bearing area with straight scissors. The undermined subcutaneous tissue was removed with curved scissors, and the skin was defatted to become a full-thickness skin flap. Any suspected hemorrhagic spots were meticulously coagulated electro surgically. The incisions were closed in two layers with 5-0 vicryl subcuticularly and 5-0 nylon for the skin. A drain was made of a butterfly needle, and a 20ml syringe placed, which was removed 24 -28 hours postoperatively. The axillary wounds were covered with bulky gauze. Arm movement was strictly controlled in the first 3 days post-operatively. Sutures were removed 10 days after the operation.

Results

The operations were performed in 32 female and 11 male patients, the average age was 29.9 years (ranged 18-63 years), and the female-to-male ratio was 3 : 1. The mean onset of disease was 16.7 years. The mean body-mass-index (BMI) was 20.9 kg/cm². Of 43 cases, 32 cases (74.4%) had family histories of this condition.

Table 1: Postoperative evaluation of 31 patients (62 Axillae) after local excision for Axillary Osidrosis

Variable	N (%)
Malodor elimination	
- Excellent (neither the patient nor close persons were aware of malodor)	15/62 (24.2)
- Good (very marked improvement and minimal malodor sometimes occurs during heavy perspiration)	41/62 (66.1)
- Fair (marked improvement but can be aware of light malodor by her/himself sometimes during daily activity)	6/62 (9.7)
- Poor (limited improvement and both the patient and persons nearby were easily aware of malodor)	0 (0)
Reduced hair growth	
- Significant (>75%)	12/62 (19.4)
- Moderate (50-75%)	28/62 (45.2)
- Mild (25-50%)	18/62 (29)
- No significant (<25%)	4/62 (6.5)
Mean HDSS score	
Before surgery	Before surgery
2.6 ± 0.9	1.3 ± 0.5*
Patients' satisfaction	
- Satisfactory	27/31 (87.1)
- Neutral	4/31 (12.9)
- Regretful	0 (0)
Scar form	
- Flat scar	45/62 (72.6)
- Atropic scar	0 (0)
- Hypertrophic scar	16/62 (25.8)
- Keloid	0 (0)
- Contrative scar	1 (1.6)
Complications	
- Hematoma	3/62 (3.4)
- Seroma	0(0)
- Skin edge necrosis	2/62 (2.3)
- Local infection	0 (0)
- Upper limb oedema	3/62 (3.4)
- Shoulder movement limitation	0 (0)

HDSS: Hyperhidrosis Disease Severity Scale

*p < 0.05

There were 31 patients followed up for a minimum of 6 months, with an average of 8 months (6-12 months). A summary of the results, including malodor elimination, changes in axillary sweating and hair growth, post-operative scar, patient satisfaction degree, and post-operative complications as presented in Table 1.

Of the total of 62 axillae (31 cases), 56 (90.3%) showed good to excellent results; hair growth decreased in 58 (93.6%). The mean HDSS score decreased significantly, 2.6 before the treatment and 1.3 after the surgery ($p < 0.05$). Quality of life was assessed before and 6 months after the operation. The mean DLQI score was 16.1 (ranged from 5 to 28) before the treatment and decreased to 3.3 after the surgery.

All subscores of questions and mean DLQI score significantly decreased after the procedure ($p < 0.05$) as shown in Figure 1. Overall, 27 (87.1%) patients were satisfied, and 4 (12.9%) patients were neutral with the procedure.

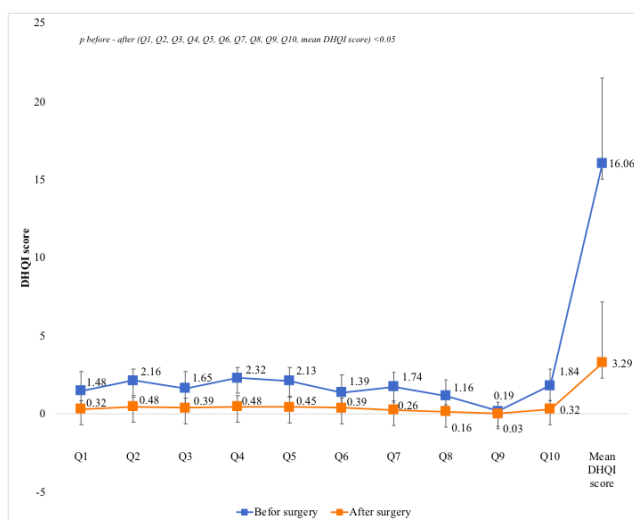


Figure 1: Mean of DQLI score before and six months after surgery

There were three cases of haematoma, two cases of skin edge necroses and three instances of upper limb oedema. For patients with upper limb oedema, oedema disappeared within several days when the arms were maintained in an elevated position. All the skin edge necroses and haematoma occurred on two patients, with one patient receiving an anticoagulant from a cardiologist after the first surgery day, to treat heart valve disease, while the other patient did not strictly control the movement of his arms.

No infection or shoulder movement limitation was observed. There was no keloid or atrophy of scars. Scars were flat in 45 axillae (72.6%) and hypertrophic in 15 axillae (24.2%). There was only one contractive scar.

Discussion

It is believed that the secretion of the apocrine glands and the activity of bacteria create the characteristic malodor of axillary osmidrosis [11]. The apocrine glands are found in connection with hair follicles and located at the junction of the dermis and subcutaneous fat. The surgical pattern designs for bromhidrosis are based on the location of apocrine glands. Therefore, any treatment methods that eliminate subcutaneous tissue are effective in the treatment of axillary bromhidrosis. Up to now, there are many invasive procedures have been proposed. Minimally invasive procedures include mechanical liposuction, curettage, scissors trimming, using small transverse incision, and combined techniques [2], [5], [12]. Many of which results in an inconspicuous scar, but the blind undermining that occurs during the operation increases damage to the skin edge and subdermal vascular plexus and the risk of haematoma and incomplete excision of apocrine glands. Besides, they depend a lot on the surgeon's experience. So an incision with eligible length can achieve full exposure during the operation and control hemostasis meticulously. Our method is a simple surgical procedure, and the glands can be easily excised under direct vision. Therefore, it is not surprising that as high as 90.3% of our patients achieved a good result regarding malodour elimination and 27/31 (87.1%) patient satisfied after treatment.

In our group patients, there was a strong predominance of females, which is similar to previous reports [2], [5], [6]. Most patients have family members who also have bromhidrosis in our study (74.4%). An autosomal dominant inheritance pattern has been proposed. Recently, some studies have found a strong relationship between bromhidrosis and wet ear wax associated with one single nucleotide polymorphism (SNP) 538G > A in exon 4 of the human ABCC11 gene [13], [14].

Axillary osmidrosis is often accompanied by axillary hyperhidrosis. In our study, all patients with a complication of axillary hyperhidrosis reported a reduction in sweating. Beer GM et al. recently reported that most of the eccrine and apocrine glands were found in the subcutaneous tissue near the border to the dermis and not in the dermis [15]. Therefore, our method was also effective in treating axillary hyperhidrosis, although the reduction in axillary sweating was not the primary objects.

Axillary osmidrosis is a distressing problem. Most sufferers limit their social activities because of embarrassment due to offensive axillary odour. The appropriate surgical technique should improve their quality of life. The Dermatology Life Quality Index is a reliable tool for measuring the impact of skin disease on the quality of life of patients and it has been applied to many common skin conditions. In our study, median DLQI score was 16.1 before the operation,

compared with 3.3 postoperatively. The difference is statistically significant ($p < 0.05$).

A haematoma is one of the severe complications after local osmidrosis surgery, the main reasons are uncontrolled bleeding meticulously and active movement of the arm in the early postoperative period. There is two cases of hematoma in our study, careful assessment of the history before the bleeding also revealed that one patient did not abide by the postoperative rest. Thus, doctor's recommendations also have an important role, and immediate evacuation of the large haematoma will lessen the dangers of skin-flap survival.

The ugly scar is also a problem that causes patients' anxiety after surgery. In our group of patients, there was a predominance of flat scars (72.6%), followed by hypertrophic scars (24.2%), with only one axilla with contractive scars (Figure 2). During the followed period, we found a phenomenon that the scars in the right axillary fossa were more conspicuous than those in the left side. This may be attributed to the increased strains in the right side due to relatively more movements. The case of contractive scars occurred on a patient with hematoma, but the contractive degree was slight and acceptable.

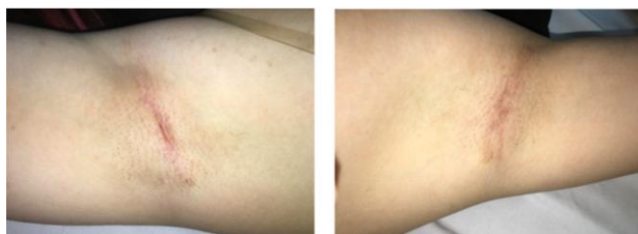

Figure 2: The scar in both side of patient's axillae 6 months postoperatively

In conclusion, our surgical technique for the treatment of axillary bromhidrosis is a simple surgical procedure and easy to perform, with low complications and effective elimination of malodour. The quality of life significantly improved after the operation.

References

- Kunachak S, Wongwaisayawan S, Leelaudomlapi P. Noninvasive treatment of bromhidrosis by frequency-doubled Q-switched Nd: YAG laser. *Aesthetic plastic surgery*. 2000; 24(3):198-201. <https://doi.org/10.1007/s002660010032> PMID:10890947
- He J, Wang T, Dong J. A close positive correlation between malodor and sweating as a marker for the treatment of axillary bromhidrosis with Botulinum toxin A. *Journal of Dermatological Treatment*. 2012; 23(6):461-4. <https://doi.org/10.3109/09546634.2011.594869> PMID:21801111
- Skoog T, Thyresson N. Hyperhidrosis of the axillae. A method of surgical treatment. *Acta chirurgica scandinavica*. 1962; 124:531. PMID:13989093
- Tung TC. Endoscopic shaver with liposuction for treatment of axillary osmidrosis. *Annals of plastic surgery*. 2001; 46(4):400-4. <https://doi.org/10.1097/0000637-200104000-00008> PMID:11324882
- He J, Wang T, Dong J. Excision of apocrine glands and axillary superficial fascia as a single entity for the treatment of axillary bromhidrosis. *Journal of the European Academy of Dermatology and Venereology*. 2012; 26(6):704-9. <https://doi.org/10.1111/j.1468-3083.2011.04149.x> PMID:21689166
- Tung TC, Wei FC. Excision of subcutaneous tissue for the treatment of axillary osmidrosis. *British journal of plastic surgery*. 1997; 50(1):61-6. [https://doi.org/10.1016/S0007-1226\(97\)91285-6](https://doi.org/10.1016/S0007-1226(97)91285-6)
- Wu WH, Ma S, Lin JT, Tang YW, Fang RH, Yeh FL. Surgical treatment of axillary osmidrosis: an analysis of 343 cases. *Plastic and reconstructive surgery*. 1994; 94(2):288-94. <https://doi.org/10.1097/00006534-199408000-00011>
- Qian JG, Wang XJ. Effectiveness and complications of subdermal excision of apocrine glands in 206 cases with axillary osmidrosis. *Journal of Plastic, Reconstructive & Aesthetic Surgery*. 2010; 63(6):1003-7. <https://doi.org/10.1016/j.bjps.2009.05.004> PMID:19505859
- Solish N, Bertucci V, Dansereau A, HONG HC, Lynde C, Lupin M, Smith KC, Storwick G. A comprehensive approach to the recognition, diagnosis, and severity-based treatment of focal hyperhidrosis: recommendations of the Canadian Hyperhidrosis Advisory Committee. *Dermatologic Surgery*. 2007; 33(8):908-23. <https://doi.org/10.1097/00042728-200708000-00003>
- Finlay AY, Khan GK. Dermatology Life Quality Index (DLQI)—a simple practical measure for routine clinical use. *Clinical and experimental dermatology*. 1994; 19(3):210-6. <https://doi.org/10.1111/j.1365-2230.1994.tb01167.x>
- Spielman AI, Sunavala G, Harmony JA, Stuart WD, Leyden JJ, Turner G, Vowels BR, Lam WC, Yang S, Preti G. Identification and immunohistochemical localization of protein precursors to human axillary odors in apocrine glands and secretions. *Archives of dermatology*. 1998; 134(7):813-8. <https://doi.org/10.1001/archderm.134.7.813> PMID:9681344
- Wang R, Yang J, Sun J. A minimally invasive procedure for axillary osmidrosis: subcutaneous curettage combined with trimming through a small incision. *Aesthetic plastic surgery*. 2015; 39(1):106-13. <https://doi.org/10.1007/s00266-014-0431-2> PMID:25476603
- Yoo WM, Pae NS, Lee SJ, Roh TS, Chung S, Tark KC. Endoscopy-assisted ultrasonic surgical aspiration of axillary osmidrosis: a retrospective review of 896 consecutive patients from 1998 to 2004. *Journal of Plastic, Reconstructive & Aesthetic Surgery*. 2006; 59(9):978-82. <https://doi.org/10.1016/j.bjps.2005.12.046> PMID:16920592
- Toyoda Y, Gomi T, Nakagawa H, Nagakura M, Ishikawa T. Diagnosis of human axillary osmidrosis by genotyping of the human ABCC11 gene: clinical practice and basic scientific evidence. *BioMed research international*. 2016; 2016.
- Beer GM, Baumüller S, Zech N, Wyss P, Strasser D, Varga Z, Seifert B, Hafner J, Mihic-Probst D. Immunohistochemical differentiation and localization analysis of sweat glands in the adult human axilla. *Plastic and reconstructive surgery*. 2006; 117(6):2043-9. <https://doi.org/10.1097/01.prs.0000210681.90799.b1> PMID:16651982