

# Uterine Fibroid Embolization via Transradial versus Transfemoral Arterial Access: Technical Results

Aleksandar Gjoreski<sup>1\*</sup>, Josif Gjoreski<sup>2</sup>, Andrea Nancheva<sup>1</sup>

<sup>1</sup>General City Hospital "8th September" – Skopje, Department for Diagnostic and Interventional Radiology, Skopje, Republic of Macedonia; <sup>2</sup>University Clinic for Gynaecology and Obstetrics, Faculty of Medicine, Ss Cyril and Methodius University of Skopje, Skopje, Republic of Macedonia

## Abstract

**Citation:** Gjoreski A, Gjoreski J, Nancheva A. Uterine Fibroid Embolization via Transradial Versus Transfemoral Arterial Access: Technical Results. *Open Access Maced J Med Sci.* 2019 Feb 28; 7(4):579-582. <https://doi.org/10.3889/oamjms.2019.163>

**Keywords:** Transradial; Embolization; Fibroids; Access

**\*Correspondence:** Aleksandar Gjoreski, General City Hospital "8th September" – Skopje, Department for Diagnostic and Interventional Radiology, Skopje, Republic of Macedonia. E-mail: [acegjoreski@yahoo.com](mailto:acegjoreski@yahoo.com)

**Received:** 30-Dec-2018; **Revised:** 07-Feb-2019; **Accepted:** 08-Feb-2019; **Online first:** 25-Feb-2019

**Copyright:** © 2019 Aleksandar Gjoreski, Josif Gjoreski, Andrea Nancheva. This is an open-access article distributed under the terms of the Creative Commons Attribution-NonCommercial 4.0 International License (CC BY-NC 4.0)

**Funding:** This research did not receive any financial support

**Competing Interests:** The authors have declared that no competing interests exist

**AIM:** This study was designed to compare the safety and feasibility of uterine fibroid embolisation (UFE) via transradial access (TRA) and transfemoral access (TFA).

**MATERIAL AND METHODS:** A retrospective analysis was conducted for 2 cohorts: 13 cases with already established TFA (from February 2016 to September 2018) and the first 11 procedures performed via TRA (from October 2017 to October 2018). Indications for embolization included: heavy menstrual bleedings (n = 18), lower urinary tract symptoms (n = 2), pelvic pain (n = 3) and abdominal pain (n = 1). One interventional radiologist and one fellow performed all procedures at one institution. Technical success, procedural time, access site complications as well as feedback from patients were assessed for analysis.

**RESULTS:** Technical success was achieved in 24/24 cases (100%). Unilateral uterine artery embolisation was performed in 7 cases (29.1%) and bilateral in 17 cases (70.8%). Mean procedure time was 72.4 minutes in TFA group, and 60.3 minutes in the TRA group. Mean fluoroscopy time was 25.3 minutes in the TFA group and 21.1 minutes in the TRA group. Access site-related and overall adverse events did not vary significantly among the study cohorts.

**CONCLUSIONS:** TRA represents a safe and feasible approach for UFE with a comparable safety profile to TFA.

## Introduction

Uterine fibroids are the most common gynaecological benign tumours in women and can cause symptoms like severe menstrual bleedings with or without reperfusion of blood account, pelvic or abdominal pain, swelling, urinary tract symptoms, bowel compression etc. Uterine fibroid embolisation (UFE) is a minimally invasive endovascular procedure which is performed for the treatment of fibroids. On the other hand, surgery is the standard treatment of choice for this pathology offered by gynaecologists. Hysterectomy and myomectomy, both in the classical or laparoscopic way are the most common surgical techniques. UFE is an established endovascular interventional technique which includes delivery of embolic agents through the uterine arteries directly in

uterus and fibroids. This intervention is typically offered to women who refuse surgery.

Further it is commonly practiced in women who want to preserve their uterus by any means, who are contraindicated to surgery due to comorbidities, younger women etc. Traditionally, transfemoral access (TFA) has been the standard approach for performing this intervention as well as for other procedures in interventional radiology (IR), proven in a number of studies so far. Transradial access (TRA) is a relatively new approach in interventional radiology (IR) and so far has been used predominantly in interventional cardiology for the past few decades. Due to improved patient comfort, minor access site complications, earlier ambulation and reduced costs, TRA is becoming more popular also in some IR procedures such as: visceral embolizations with predominance of transarterial chemoembolization

(TACE) and radioembolization (TARE), embolization of gastrointestinal bleedings, carotid artery stenting and lately in some centers also for UFE. Reviewing the literature on this particular topic, there are not many papers connecting TRA and UFE. Those few small series published speak for its safety and good feedback from patients. In our hospital, UFE has been practiced from 2015, and from the end of 2017 we started using TRA for this procedure.

In this article, we present our initial experience using TRA for UFE compared to that of TFA regarding the safety profile and the procedural eligibility.

## Material and Methods

Institutional review board approval was obtained for this retrospective study. Retrospective analysis was conducted for twenty-four women with UFE with 29 fibroids in the period from February 2016 to October 2018, reviewing our hospital information system. Thirteen women with TFA and eleven with TRA embolisation of uterine fibroid mean age 39 y. (range 29-47 y.) were analysed. Twenty-one of them (87.5%) have already completed reproduction, with at least one childbirth, with no particular desire for further reproduction. Two of them (8.3%) have no children (in these two myomas/fibroids were considered as one of the possible causes of infertility). One woman (4.1%) with one child, with a desire for another conception in future. All patients were symptomatic and indications for embolization included: heavy menstrual bleedings (n = 18) 75%, lower urinary tract symptoms (n = 2) 8.3%, pelvic pain (n = 3) 12.5% and abdominal pain (n = 1) 4.1%. Demographic patient characteristics between the two groups did not differ significantly (Table 1). Patients were divided into 2 groups: 13 cases with already established TFA (from February 2016 to September 2018) and the first 11 procedures performed via TRA (from October 2017 to October 2018). All procedures were performed by one interventional radiologist with experience of more than 400 visceral embolisations and one fellow in Radiology.

**Table 1: Patient and procedural characteristics**

	TFA group	TRA group
Number of women	13	11
Median age	31-45	29-47
Number of fibroids	16	13
Completed reproduction	10	11
Technical success	100%	100%
Total procedure time(minutes)	72.4	60.3
Fluoroscopy time(minutes)	25.3	21.1
Hospital days per procedure	2	0
Minor complications	1	0
Clinical symptoms improvement	13	9

In the TFA group, standard Seldinger technique was used with 5F introducer in the right common femoral artery (CFA). 5F Cobra 2 catheter was used for catheterisation of left internal iliac artery and Simmons 2 catheter for right internal iliac artery. In all femoral cases, 2,7F 130cm long microcatheter (Program, Terumo, Japan) was used for superselective catheterisation of uterine arteries and consequent embolisation.

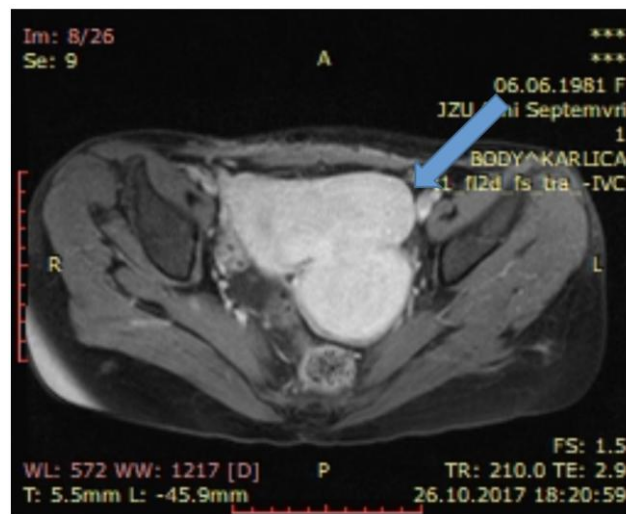


Figure 1: Pelvic MRI; T1 FS contrast-enhanced axial MRI of uterus pre embolisation shows 2 large intramural hypervascular fibroids (arrow) in the left side of uterus body with a displacement of cavum uteri

In the TRA group, the preprocedural US of the radial artery was performed together with Barbeau test for depicting patency of hand vessels. Radial arteries smaller than 2.5 mm in diameter were considered as too small for puncture, and these patients were excluded from radial puncture and converted to femoral access. Micropuncture set for transradial access (5F Slender Glidesheath, Terumo, Japan) was used in all radial cases with 110 cm MP or 125 angled catheter for cannulation of hypogastric artery.

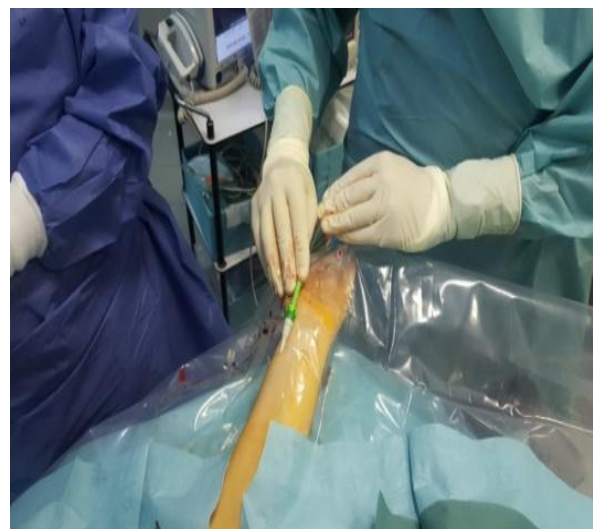

Figure 2: Left transradial access with the insertion of 5F Glidesheath, Slender, Terumo

One 150 cm long 2.8F microcatheter (Program, Terumo, Japan) in combination with GT microwire was chosen for uterine artery super selective catheterisation. Left radial artery was used for all of the eleven TRA cases.

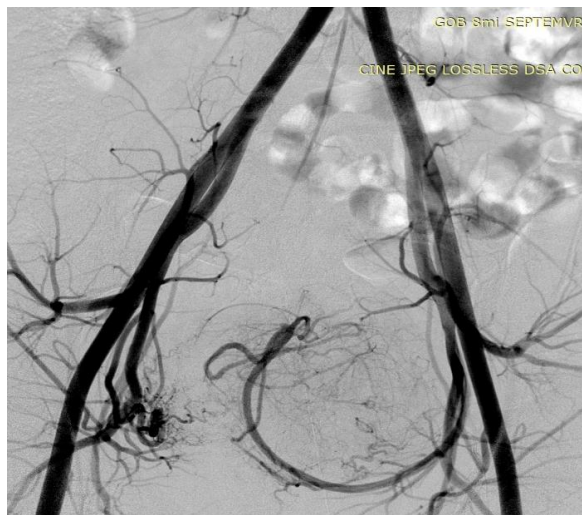


Figure 3: Digital subtraction angiography of pelvic arteries showed large and hypertrophied left uterine artery predominantly supplying the fibroids

Embolisation was performed by using PVA or PEG particles with size from 500-1000 microns. Type and size of particles were selected as per every case on the discretion of the operator.

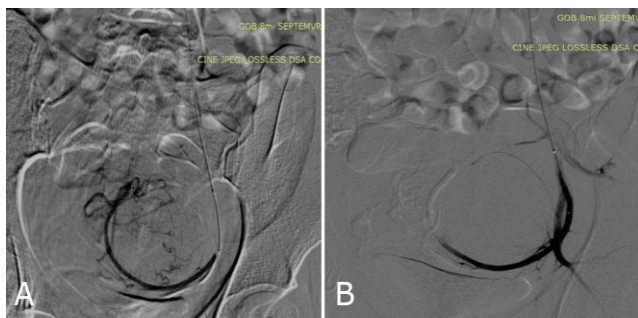


Figure 4: Angiographic findings pre and post-embolization; A) Transradial super selective angiography of left uterine artery pre embolization with 2.8F 150 cm long microcatheter shows large hypervascular fibroid; B) Postembolization angiography in the same patient shows complete embolization of left uterine artery with PVA particles and stasis of contrast at the tip of microcatheter while main uterine artery is still patent

Haemostasis of the femoral artery was achieved with manual compression, and haemostasis of the radial artery was done with TR Band (Terumo Interventional Systems) in all cases.

Pelvic contrast-enhanced MRI and complete blood account tests were assessed before intervention in every case. The degree of achieved necrosis of the fibroids was assessed by control pelvic enhanced MRI 1-2 months after embolisation.

Conversation with the interventional radiologist about improving symptoms and quality of life, complete blood tests and radial artery ultrasound was also part of the postprocedural follow up at 1 month interval.

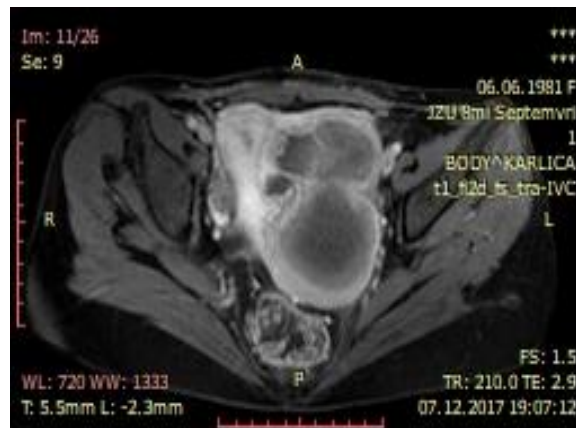


Figure 5: One and a half month post embolisation T1 FS contrast-enhanced axial MRI of the uterus in the same patient shows complete necrosis of both fibroids (arrow) and preservation of uterine body wall with normal enhancement

## Results

Technical success of the procedure was achieved in 24/24 cases (100%). Unilateral uterine artery embolisation was performed in 7 cases (29.1%) and bilateral in 17 cases (70.8%). The decision for unilateral UFE was made by carefully reviewing of the preprocedural US and MRI, and in all these cases fibroids were predominantly vascularized by one uterine artery (> 80%). Mean procedural time was 72.4 minutes in TFA group, and 60.3 minutes in the TRA group. Mean fluoroscopy time was 25.3 minutes in the TFA group and 21.1 minutes in the TRA group. Access site-related and overall adverse events did not vary significantly among the study cohorts. One non-flow-limiting dissection of left internal iliac artery occurred in the TFA group during manipulation with hydrophilic wire which resolved spontaneously at the end of the procedure. In one patient in the TRA group, there was prolonged pain in the left forearm for 14 days which was managed conservatively with use of non-steroidal anti-inflammatory drugs.

Patients in the TRA group left the hospital the same day 3-4 hours after the procedure with a bandage at the left radial artery. In the TFA group patients stayed in the hospital for two nights, one day prior and one day after the procedure. There were no late major complications in both groups. In all TRA cases, radial artery remained patent without signs of thrombosis, which was confirmed with the US on one-month control examination.



## Discussion

Transfemoral approach for uterine artery embolisation is an established technique for the treatment of uterine fibroids. Different catheters and manoeuvres have been described in the literature for cannulation of uterine arteries via transfemoral access. In recent years, transradial approach is gaining more and more popularity in the IR community, especially for some visceral artery interventions. It's proven safety and benefits in interventional cardiology interventions by a number of studies was followed by some small series in interventional radiology as well.

In this retrospective review of procedural safety and efficacy in a small cohort of patients treated with transradial approach, we did not observe any major complications during or after the procedure. Fluoroscopy time was less than that in TFA group without any statistical significance and we found that cannulation of the uterine artery is almost always easier when we used TRA. Main advantage so far is that the procedure can be performed as an outpatient one without patient hospitalisation. This was proven to be of great importance for patients when we were doing the postprocedural questionnaire. According to the results from this study, we can clearly say that TRA is a safe and effective alternative to TFA for UFE in carefully selected patients.

Every woman with the radial artery of 3 mm or greater diameter is a candidate for transradial UFE. Compared to TFA, there is shorter hospital stay and reduced total costs in the TRA procedure.

*Limitations of the study:* This is a small, retrospective study for gaining large and long-term conclusions. Also, it is a single centre so we cannot compare or share the results from other centres as well.

In conclusion, we think that TRA is potentially safe and effective approach for uterine fibroid embolisation. According to our experience so far it appears to be a highly promising treatment option for a woman with symptomatic fibroids. The main advantage of this procedure is early verticalization of the patients and same day discharge from the hospital.

Potential limitations so far are the lack of adequate materials (catheters and microcatheters) that can easily reach the ostium of every uterine artery via radial access. Also, the diameter of radial artery and total body height of the patient is a very important prognostic factor that can influence the success of the procedure.

Further studies with larger numbers of patients with follow-ups on longer intervals are necessary to assess the effectiveness of TRA for uterine fibroid embolization better.

## References

1. Resnick NJ, Kim E, Patel RS, Lookstein RA, Nowakowski FS, Fischman AM. Uterine artery embolization using a transradial approach: initial experience and technique. *Journal of Vascular and Interventional Radiology*. 2014; 25(3):443-7. <https://doi.org/10.1016/j.jvir.2013.11.010> PMID:24581468
2. Spies JB, Pelage JP, editors. *Uterine artery embolization and gynecologic embolotherapy*. Lippincott Williams & Wilkins, 2005.
3. Gonsalves C. Uterine artery embolization for treatment of symptomatic fibroids. *Semin Intervent Radiol*. 2008; 25:369–377. <https://doi.org/10.1055/s-0028-1103001> PMID:21326578 PMID:PMC3036525
4. Ravina JH, Ciraru-Vigneron N, Bouret JM, Herbreteau D, Houdart E, Aymard A, Merland JJ. Arterial embolisation to treat uterine myomata. *The Lancet*. 1995; 346(8976):671-2. [https://doi.org/10.1016/S0140-6736\(95\)92282-2](https://doi.org/10.1016/S0140-6736(95)92282-2)
5. Cooper CJ, El-Shiekh RA, Cohen DJ, Blaesing L, Burket MW, Basu A, Moore JA. Effect of transradial access on quality of life and cost of cardiac catheterization: a randomized comparison. *American heart journal*. 1999; 138(3):430-6. [https://doi.org/10.1016/S0002-8703\(99\)70143-2](https://doi.org/10.1016/S0002-8703(99)70143-2)
6. Feldman DN, Swaminathan RV, Kaltenbach LA, Baklanov DV, Kim LK, Wong SC, Minutello RM, Messenger JC, Moussa I, Garratt KN, Piana RN. Adoption of radial access and comparison of outcomes to femoral access in percutaneous coronary intervention: an updated report from the national cardiovascular data registry (2007–2012). *Circulation*. 2013; 127(23):2295-306. <https://doi.org/10.1161/CIRCULATIONAHA.112.000536> PMID:23753843
7. Kröncke T, David M. Uterine Artery Embolization (UAE) for Fibroid Treatment: Results of the 6th Radiological Gynecological Expert Meeting. 2017; 189(6):511-514.
8. Basile A, Rebonato A, Failla G, Caltabiano G, Boncoraglio A, Gozzo C, Motta A, Foti PV, Palmucci S, García AJ, Garcia-Medina J. Early post-procedural patients compliance and VAS after UAE through transradial versus transfemoral approach: preliminary results. *Radiol Med*. 2018; 123(11):885-889. <https://doi.org/10.1007/s11547-018-0920-5> PMID:30019107
9. Vuurmans T, Hilton D. Brewing the right cocktail for radial intervention. *Indian Heart Journal*. 2010; 62(3):221-5. PMID:21275297
10. Goodwin SC, Bonilla SC, Sacks D, Reed RA, Spies JB, Landow WJ, Worthington-Kirsch RL. Reporting standards for uterine artery embolization for the treatment of uterine leiomyomata. *Journal of vascular and interventional radiology*. 2003; 14(9):S467-76. <https://doi.org/10.1097/01.RVI.0000094620.61428.9c> PMID:14514862
11. Scheurig-Muenkler C, Powerski MJ, Mueller JC, Kroencke TJ. Radiation exposure during uterine artery embolization: effective measures to minimize dose to the patient. *Cardiovascular and interventional radiology*. 2015; 38(3):613-22. <https://doi.org/10.1007/s00270-014-0962-6> PMID:25148920