

Challenging Diagnostics of Biofilm Associated Periprosthetic Infection in Immunocompromised Patient: A Clinical Case

Zinaida S. Naumenko, Tamara A. Silanteva*, Artem M. Ermakov, Natalia V. Godovykh, Nikolay M. Klushin

Russian Ilizarov Scientific Center for Restorative Traumatology and Orthopaedics, Kurgan, Kurgan Oblast, Russia

Abstract

Citation: Naumenko ZS, Silanteva TA, Ermakov AM, Godovykh NV, Klushin NM. Challenging Diagnostics of Biofilm Associated Periprosthetic Infection in Immunocompromised Patient: A Clinical Case. Open Access Maced J Med Sci. <https://doi.org/10.3889/oamjms.2019.180>

Keywords: Biofilms; Periprosthetic infection; Scanning electron microscopy

***Correspondence:** Tamara A. Silanteva. Russian Ilizarov Scientific Center for Restorative Traumatology and Orthopaedics, Kurgan, Kurgan Oblast, Russia. E-mail: tsyl@mail.ru

Received: 14-Jan-2019; **Revised:** 20-Feb-2019; **Accepted:** 21-Feb-2019; **Online first:** 13-Mar-2019

Copyright: © 2019 Zinaida S. Naumenko, Tamara A. Silanteva, Artem M. Ermakov, Natalia V. Godovykh, Nikolay M. Klushin. This is an open-access article distributed under the terms of the Creative Commons Attribution-NonCommercial 4.0 International License (CC BY-NC 4.0)

Funding: This research did not receive any financial support

Competing Interests: The authors have declared that no competing interests exist

BACKGROUND: Periprosthetic joint infection (PJI) is a devastating complication of joint arthroplasty. The identification of microorganisms in biofilm-related PJI is challenging yet significant stage of the treatment process. Medical microbiology methods, such as pure culture isolation, remain the gold standard. However, the error rate of classical methods may vary from 10% to as high as 42% due to the inability to detect bacteria growing within biofilms. Other methods of detection are being explored to improve the management of PJI.

AIM: Accurate identification of PJI contributing microorganisms in a patient with acute postoperative PJI after total hip joint arthroplasty and systemic lupus erythematosus in anamnesis.

METHODS: We used microbial culture methods followed by scanning electron microscopy (SEM).

RESULTS: Perioperative an intraoperative cultural analysis of 8 different culture samples of tissue and prosthetic origin was insufficient for bacterial or fungal detection. Scanning electron microscopy revealed detailed biofilm visualisation on the surface of the prosthetic component. The biofilm exterior was composed of microbial clusters made of 10 or more cells with either pear- or bottle-shaped morphology, 3-6 µm in length and 1.5-3 µm in diameter. Rod-shaped microorganisms of 0.7-1 µm length and up to 0.5 µm in diameter were found adjacent to these clusters.

CONCLUSION: Additional methods for PJI agents' detection are time- and cost-effective in the case of the challenging diagnostics of biofilm-related PJI, particularly in immunocompromised patients. Using combined diagnostic approaches increases the accuracy of detection, justifies treatment strategies and improves clinical outcomes.

Introduction

Periprosthetic joint infection (PJI) is one of the most serious complications following total joint arthroplasty. The accurate identification of microbes contributing to PJI is critical for PJI detection and treatment. However, the identification may pose a significant challenge since the diagnostic tests report both false positive and false negative results. The reference standard for diagnosing of implant-related infections is the isolation of the pathogen in pure cultures and subsequent identification using the combination of tinctorial, physiological, biochemical methods [1].

Gram-positive bacteria contribute to the

development of periprosthetic infection in 88% of cases. Infection by gram-negative bacteria is relatively rare (approximately 7%). The common reasons for gram-negative bacterial infection are empirical antibiotic therapy and prolonged surgical drain stay after endoprosthesis surgery. The widespread gram-negative agents are *Pseudomonas aeruginosa*, *Acinetobacter baumannii*, *Klebsiella pneumoniae*, *Proteus* spp., *Enterobacter* spp., *Escherichia coli* [2], [3], [4]. Despite recent technological advances in cultural methods, an overwhelming 10% to 42% microbial causes of all periprosthetic infections remain unidentified [5], [6].

The standard microbiology approach for microbial identification can be problematic due to the inability of biofilm-forming microorganisms to grow

independently in pure culture [7] along with variability in time and specifics of cultivation methods for different species [8], [9], [10].

Therefore, further studies are needed to improve the management and prevention strategies of PJI.

Scanning electron microscopy (SEM) is one of the effective methods for studying microbial morphology of microorganisms from clinical samples [11], [12]. However, comparative *in situ* studies of biofilm attached to the orthopaedic surfaces and microbial cultures are rare.

We hypothesised that etiologic agents of PJI which remain undetected using standard microbial culture methods could be identified using scanning electron microscopy approach.

Case Presentation

Clinical case: patient D., 44 years old woman, presented with acute postsurgical periprosthetic joint infection (April 2018).

Medical history: In January 2018, the patient underwent cementless total joint arthroplasty of the right hip. The postoperative period has been complicated by a fever of 38°C and purulent drainage of the surgical site. A month later, modular prosthetic components were revised and debrided with subsequent replacement. Following the replacement surgery, the patient has developed a fistula.

Past medical history revealed that the patient had chronic systemic lupus erythematosus, chronic bronchitis, and chronic gastritis in a remission period, genetic thrombophilia and stage 2 hypertonic disease.

The patient presented with the right hip fistula, right hip pain and activity limitations. In the perioperative period we suggested periprosthetic infection based on x-ray findings (Figure 1A, B and C) and cytological and microbiological analysis of the synovial fluid. During the surgery, total removal of prosthetic components followed by the debridement, articulating spacer installation and replacement of the right hip prosthesis with the x-ray control (Figure 1D).

Intraoperative samples of periarticular tissues, bone fragments of the prosthetic base and prosthetic components were obtained for histological and microbiological analyses.

Tissue samples were homogenised and synovial fluid samples were pelleted before inoculation. Blood agar containing 5% defibrinated blood, Baird-Parker egg yolk tellurite medium, Levine eosin methylene blue agar, Sabouraud agar and Columbia agar were used for microbiological cultures.

Inoculated agar plates were incubated at 37° C for 24-48 h. Fungal cultures were incubated at 30° C for 120 h. “Anaerogas” gas generating pack sets and 72-120 h incubation at 3° C were used for anaerobic culture growth. The morphological observation was performed using ordinary staining (Gram) method.

Fragments of the periprosthetic membrane (n=3) and trabecular bone samples (n=3) of periprosthetic host bone were preserved at least 48 h in 4% formalin. Bone samples were decalcified in Richman-Gelfand-Hill solution after fixation. Then samples were dehydrated and embedded in paraffin for microtome sectioning. Slides with tissue sections of 5-7 mcm were stained with hematoxylin and eosin. The visualisation was performed using AxioScope.A1 stereomicroscope. For imaging, we used AxioCam ICc 5 and Zen blue («Carl Zeiss MicroImaging GmbH», Germany) software. For each sample, at least 10 images were obtained.

Metallic endoprosthetic femoral component and periprosthetic tissue samples for scanning electron microscopy was performed using standard patented procedures with authors' modifications [11], [13] After platinum deposition in an IB-6 vacuum ion sprayer (Eiko, Japan), the surface of the implant component was examined with Zeiss EVO MA 18 scanning electron microscope (Carl Zeiss Group, Germany). The limitation was the height of the area in the study region of no more than 145 mm, which was due to the design limitations.

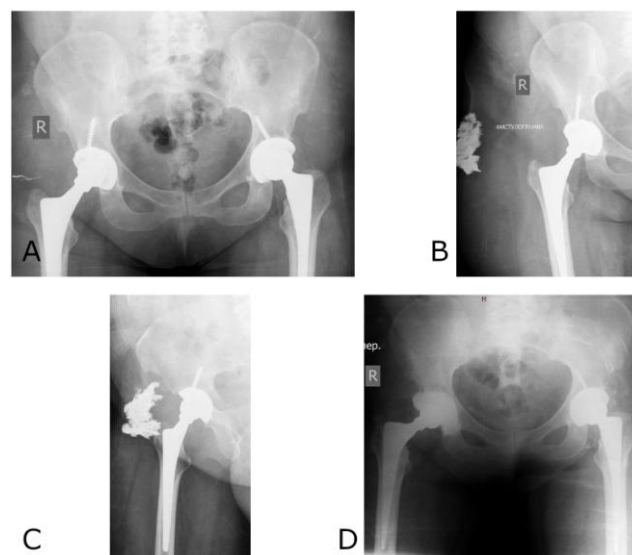


Figure 1: Radiographs of the pelvis: A) AP view before the revision operation; B, C) Fistulograph of the right hip joint before surgery; D) AP view after the intervention

Perioperative culture tests of the punctured material did not reveal bacterial growth. Leucocytosis in the joint fluid was 12.9 cells per microliter, and the rate of neutrophils was 67%.

Microbiological study of intraoperative samples revealed a small number of *Staphylococcus*

saprophyticus cells ($< 10^3$ CFU/ml) in one sample (synovial joint fluid). No bacterial growth has been found after the cultivation of remaining samples. Tests for both fungi and anaerobic bacteria were negative.

Histological analysis of the fragments of periprosthetic membranes was conducted according to the consensus classification of Krenn and Morawitz [14] and revealed some features of conformity to type I, caused by wear particles. In a reactively modified loose fibrous connective tissue with a high density of fibroblast-like cellular elements (Figure 2A), foreign microparticles of an optically transparent material were detected surrounded by giant cells of foreign bodies. In such areas, cell density was reduced; erythrocyte diapedesis and infiltration with monocytes and lymphocytes were noted (Figure 2B). Polymorphonuclear leukocytes were not detected in any of the visual fields.

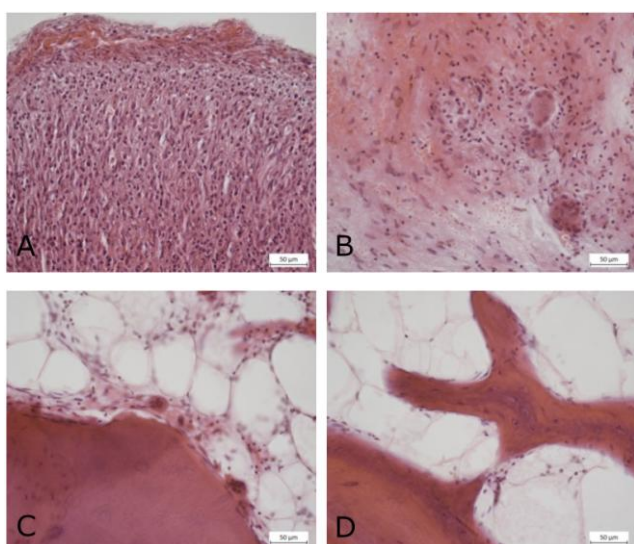


Figure 2: Reactive changes in the periprosthetic membrane: A) high cell density; B) diapedesis, clusters of giant multinuclear cells; C) osteoclastic resorption; D) osteoblastic remodelling of trabeculae in the spongy bone of the periprosthetic bed. Paraffin sections. Stained with hematoxylin and eosin. Magnification: 10 (lens), 40 (eyepiece). Scale bar = 50 microns

Histological study of spongy bone substance fragments revealed signs of remodelling, consisting of moderate osteoclastic (Figure 2C) and osteoblastic (Figure 2D) activity on the surface of bone trabeculae. The intertrabecular spaces contained fatty bone marrow with scattered foci of hematopoiesis; hyperemia and oedema were observed only on the border with the implant.

Scanning microscopy detected clusters of nanoscale globular bodies in the periprosthetic connective tissue (possibly immune complexes) (Figure 3A, and B) and perivascular accumulations of lymphoid cells (Figure 3D), characteristic of systemic lupus erythematosus.

The flat metal surface of the femoral component, free from adherent spongy bone

substance fragments (Figure 4A), was covered with a biofilm shaped as amorphous layers (Figure 4B).

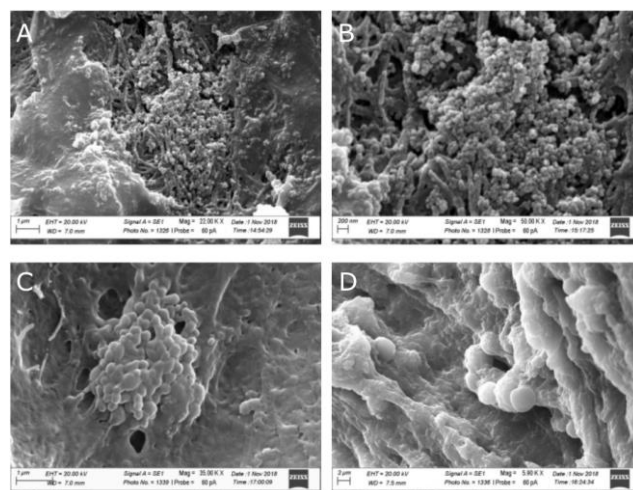


Figure 3: Morphological manifestations of systemic lupus erythematosus in the periprosthetic connective tissue: A, B and C) Deposits of nano-sized globular bodies; D) Perivascular accumulations of lymphoid cells; Electronic scans. Magnification $\times 22,000$ (A), $\times 50,000$ (B), $\times 35,000$ (C), $\times 5,900$ (D)

Microbial cells with different morphological characteristics were detected on its surface. Microorganisms with a length of 3 to 6 microns and a thickness of 1.5 to 3 microns had pear-like or bottle-like elongated shapes (Figure 4C, and D). The wide base of the cells was rounded; at the narrow end of each of them, there was a ring-shaped structure that resembled a "bottleneck". The relief of the cell surface was uneven, poorly folded. Cells that were oriented in various directions were attached to a membranous substance on the component surface.

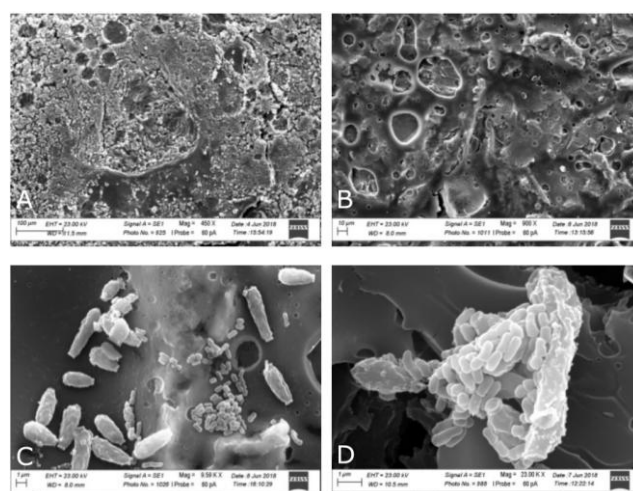


Figure 4: Areas of the metal implant surface with adhered fragments of spongy bone substance of the periprosthetic bed (a) and amorphous filmy substance (b). Biofilm on the surface of the metal implant: large bottle-shaped microorganisms with a characteristic "neck" and small rod-shaped microorganisms adhered on a membranous substrate (c), and a fragment of a structured biofilm (d). Electronic scans. Magnification $\times 450$ (a) $\times 900$ (b) $\times 9590$ (c) $\times 23,000$ (d)

Microorganisms were located in groups of up to 10 or more cells. Rod-shaped and transversely dividing bacteria with a diameter of 0.5 μm and a length of 0.7 to 1 μm had a smooth surface. They formed clusters containing two or more cells that adhered nearby or on the surface of large cells (Figure 4 C, and D).

Discussion

At present, there has been an increase in the incidence of biofilm-related infections caused by saprotrophic or pathogenic fungi along with either Gram-positive or Gram-negative bacteria. The role of biofilm infections in orthopaedic surgery is tremendous due to the high virulence of biofilm-forming microorganisms and the high possibility of biofilm formation on the surfaces of commonly used orthopaedic components [15].

Microbial biofilms can be described as structured, high-functional aggregations of microbial cells belonging to one or most commonly several species, encased into biofilm matrix and adhered to the surface. The eradication of multi-species biofilms associated with implant surfaces can be problematic as a result of poor antibiotic activity against biofilms. Metabolic, structural and functional ties between microorganisms in biofilm do not make allowances for the cultivation of clear cultures in laboratory conditions, leading to false negative test results [16]. To improve the analytical outcome, ordinary microbiology approaches can be enhanced with sophisticated methods for cultivation of each separate microorganism for each case. However, routine use of some techniques is not cost-effective. Thus, ordinary medical microbiology methods are not always effective in PJI diagnosis and should be supported by other methods.

In this clinical case, repeated laboratory tests of diagnostic punctures and intraoperative samples did not reveal etiologic PJI agents despite clinically symptomatic acute inflammatory process. The single-time finding of *S. saprophyticus* in 1 out of 8 perioperative samples could not interpret *S. saprophyticus* as an etiological factor due to the low virulence of this bacteria. Taking into consideration the low number of *S. saprophyticus* cells in a synovial fluid sample, we believe that the contamination of one sample could occasionally occur.

Scanning electron microscopy has proven its effectiveness in the visualization and identification of biofilm-forming microbes [15], [16], [17]. In this clinical case, scanning electron microscopy revealed microbial association adhered to the endoprosthesis surface. Based on morphology, the larger microbial component of the biofilm was identified as yeast and

smaller – as rod-shaped bacteria [18], [19].

Uncommonly, patient anamnesis included systemic lupus erythematosus (SLE). Immunodeficiencies in patients with SLE compromise the immunity so that conditional pathogens (fungal, bacterial, viral) can contribute to the infection development [20], [21]. In this case, additional methods for microbial detection are needed.

Therefore, in immunocompromised patients with periprosthetic infection, the utilization of scanning electron microscopy for accurate identification is advisable. Timely diagnostics is cost-effective and allows for justified, unbiased therapy decisions. The patient voluntarily signed informed consent to a surgical procedure and participation in the study.

Level of evidence: III (limitations due to the lack of patients, single case report)

References

- Petrova NV. Evidence-based diagnosis of implant-associated infection in orthopaedic surgery. *Hir Pozvonoc*. 2012; (1):74–83.
- Berbari EF, Marculescu C, Sia I, Lahr BD, Hanssen AD, Steckelberg JM, Gullerud R, Osmon DR. Culture-negative prosthetic joint infection. *Clin Infect Dis*. 2007; 45(9):1113-9. <https://doi.org/10.1086/522184>
- Gallo J, Smizanský M, Kolár M. A recurrent or a new infection of total hip replacement? A contribution to the discussion on the pathogenesis of prosthetic joint infection. *Acta Chir Orthop Traumatol Cech*. 2009; 76(3):243-6.
- Malekzadeh D, Osmon DR, Lahr BD, Hanssen AD, Berbari EF. Prior use of antimicrobial therapy is a risk factor for culture-negative prosthetic joint infection. *Clin Orthop Relat Res*. 2010; 468(8):2039-45. <https://doi.org/10.1007/s11999-010-1338-0> PMID:PMC2895855
- Jacobs AME, Bénard M, Meis JF, van Hellemond G, Goosen JHM. The unsuspected prosthetic joint infection: incidence and consequences of positive intra-operative cultures in the presumed aseptic knee and hip revisions. *Bone Joint J*. 2017; 99-B(11):1482-1489. <https://doi.org/10.1302/0301-620X.99B11.BJJ-2016-0655.R2>
- Yoon HK, Cho SH, Lee DY, Kang BH, Lee SH, Moon DG, Kim DH, Nam DC, Hwang SC. A review of the literature on culture-negative periprosthetic joint infection: epidemiology, diagnosis and treatment. *Knee Surgery & Related Research*. 2017; 29(3):155-164. <https://doi.org/10.5792/ksrr.16.034> PMID:PMC5596406
- Gbejuade HO, Lovering AM, Webb JC. The role of microbial biofilms in prosthetic joint infections. *Acta Orthopaedica*. 2015; 86(2):147-158. <https://doi.org/10.3109/17453674.2014.966290> PMID:PMC4404764
- Burgo FJ, Mengelle DE, Abraham A, Kremer G, Autorino CM. Periprosthetic fungal infection of a hip caused by *Trichosporon inkin*. *Arthroplasty Today*. 2018; 4(1):24-26. <https://doi.org/10.1016/j.artd.2017.05.005> PMID:PMC5859464
- Meyssonnier V, Zeller V, Malbos S, Heym B, Lhotellier L, Desplaces N et al. Prosthetic joint infections due to *Mycobacterium tuberculosis*: A retrospective study. *Joint Bone Spine*. 2018; 18:30329-4.
- Johansson L, Hailer NP, Rahme H. High incidence of

- periprosthetic joint infection with propionibacterium acnes after the use of a stemless shoulder prosthesis with metaphyseal screw fixation - a retrospective cohort study of 241 patients. *BMC Musculoskelet Disord*. 2017; 18(1):203. <https://doi.org/10.1186/s12891-017-1555-8> PMCID:PMC5438499
11. Naumenko ZS Ocheretina RJu, inventors; Russian Ilizarov Scientific Center for Restorative Traumatology and Orthopaedics, assignee. Method to prepare samples of microorganisms biofilms for survey in scanning electronic microscope. Patent RF 2484446, 2013:6.
12. Prakash D, Nawani NN. A rapid and improved technique for scanning electron microscopy of actinomycetes. *J Microbiol Methods*. 2014; 99:54-7. <https://doi.org/10.1016/j.mimet.2014.02.005>
13. Silant'eva TA, Gorbach EN, Ir'janov JuM, Stupina TA, Vorsegova TN, inventors; Russian Ilizarov Scientific Center for Restorative Traumatology and Orthopaedics, assignee. Method of preparing biological tissue samples for analysis in scanning electron microscope. Patent RF 2397472. 2010:5.
14. Krenn V, Morawietz L, Kienapfel H, Ascherl R, Matziolis G, Hassenpflug J, et al. Revised consensus classification: Histopathological classification of diseases associated with joint endoprostheses. *Z Rheumatol*. 2013; 72(4):383-392. <https://doi.org/10.1007/s00393-012-1099-0>
15. Costa-Orlandi CB, Sardi JCO, Pitangui NS, de Oliveira HC, Scorzoni L, Galeaneet MC, et al. Fungal Biofilms and Polymicrobial Diseases. *J Fungi (Basel)*. 2017; 3(2):22. <https://doi.org/10.3390/jof3020022> PMCID:PMC5715925
16. Gbejuade HO, Lovering AM, Webb JC. The role of microbial biofilms in prosthetic joint infections. *Acta Orthop*. 2015; 86(2):147-58. <https://doi.org/10.3109/17453674.2014.966290> PMID:25238433 PMCID:PMC4404764
17. Yuping R, Kaiwen Z, Wenying H, Jinghong H, Xiaowei F, Shuang C, Jiaoqing T, Xiaoxi X, Daoxian K, Yao L, Ruifeng Z. Observation of Fungi, Bacteria, and Parasites in Clinical Skin Samples Using Scanning Electron Microscopy. In *Modern Electron Microscopy in Physical and Life Sciences*. 2016. <https://doi.org/10.5772/61850>
18. Guarner J, Brandt ME. Histopathologic diagnosis of fungal infections in the 21st century. *Clin Microbiol Rev*. 2011; 24(2):247-80. <https://doi.org/10.1128/CMR.00053-10> PMID:21482725
19. *Bergey's Manual of Systematic Bacteriology*. Second Edition: Volume Three: The Firmicutes. Springer Dordrecht Heidelberg London New York, 2009.
20. Belov BS, Solovyev SK, Klyukvina NG, Tarasova GM, Polyanskaya MV. Comorbid infections in patients with systemic lupus erythematosus & 58; State-of-the-art. *Naučno-Praktičeskaâ Revmatologïa*. 2016; 54(4) :469-77.
21. Wang LR, Barber CE, Johnson AS, Barnabe C. Invasive fungal disease in systemic lupus erythematosus: A systematic review of disease characteristics, risk factors, and prognosis. *Semin Arthritis Rheum*. 2014; 44(3):325-30. <https://doi.org/10.1016/j.semarthrit.2014.06.001>