

# Evaluation of The Bio-Stimulatory Effect of Platelet Rich Fibrin Augmented by Diode LASER Compared to Platelet Rich Fibrin Alone on Dental Implant Replacing Posterior Mandibular Teeth. Randomised Clinical Trial: Split Mouth Study

Sherif Shafik Mohamed El Bahnasy Sleem<sup>1\*</sup>, Mohamed Khalifa Zayet<sup>2</sup>, Tarek Ibrahim El-Ghareeb<sup>2</sup>, Hoda Abd Kader Saleh<sup>2</sup>

<sup>1</sup>Faculty of Dentistry, British University in Egypt, Cairo, Egypt; <sup>2</sup>Faculty of Dentistry, Cairo University, Cairo, Egypt

## Abstract

**Citation:** El Bahnasy Sleem SSM, Zayet MK, El-Ghareeb TI, Saleh HAK. Evaluation of The Bio-Stimulatory Effect of Platelet Rich Fibrin Augmented by Diode LASER Compared to Platelet Rich Fibrin Alone on Dental Implant Replacing Posterior Mandibular Teeth. Randomised Clinical Trial: Split Mouth Study. Open Access Maced J Med Sci. 2019 Mar 15; 7(5):869-875. <https://doi.org/10.3889/oamjms.2019.183>

**Keywords:** Dental Implant; Platelet Rich Fibrin; Diode LASER; Digital Radiography; Implant stability

**\*Correspondence:** Sherif Shafik Mohamed El Bahnasy Sleem, Faculty of Dentistry, British University in Egypt, Cairo, Egypt. E-mail: [sherif.shafik@bue.edu.eg](mailto:sherif.shafik@bue.edu.eg)

**Received:** 30-Dec-2018; **Revised:** 23-Feb-2019; **Accepted:** 24-Feb-2019; **Online first:** 14-Mar-2019

**Copyright:** © 2019 Sherif Shafik Mohamed El Bahnasy Sleem, Mohamed Khalifa Zayet, Tarek Ibrahim El-Ghareeb, Hoda Abd Kader Saleh. This is an open-access article distributed under the terms of the Creative Commons Attribution-NonCommercial 4.0 International License (CC BY-NC 4.0)

**Funding:** This research did not receive any financial support

**Competing Interests:** The authors have declared that no competing interests exist

**BACKGROUND:** Restoring masticatory function and replacing missing teeth with minimal pain and discomfort are the most important issues for the patient and clinician. Nowadays dental implants became the most popular line of treatment to replace missing teeth; offering a comfortable long lasting prosthesis. Osseo-integration reflects the long term success of a dental implant. Many bio-modulators are used aiming to improve the osseointegration and healing around dental implants such as Low-Level Laser treatment (LLLT) and Platelet Rich Fibrin (PRF). PRF has been proven to improve bone repair process around the dental implant. LLLT is considered a noninvasive, safe technique that stimulates osteogenesis and alleviates post-operative pain.

**AIM:** Evaluation of the bio-stimulatory effect of LLLT on a dental implant with PRF compared to PRF alone clinically and radiographically.

**METHODS:** A randomised clinical trial with the split-mouth design was conducted on nine patients with bilaterally missing lower posterior tooth. All patients received one dental implant on each side with PRF. LASER application was performed to one side twice weekly for one month starting on the day of insertion. Post-operative pain was assessed daily through the first week using numerical rating pain scale (NRS) as the primary outcome. Relative peri-implant bone density was measured using direct digital intraoral radiography immediately after insertion, one, four and nine months postoperatively. Implants stability were measured using radio frequency assessment immediately after insertion, four and nine months post-operative as secondary outcomes.

**RESULTS:** The NRS for pain was significantly decreased by the end of the first-week postoperatively in the intervention and control group with a mean of ( $2.22 \pm 1.56$ ) ( $2.11 \pm 1.83$ ) respectively. However, there was no statistically significant difference between the test groups at P-Value (0.892). The relative bone density values were decreased by the end of the ninth month of follow-up in the intervention and control group with a mean of ( $134.42 \pm 16.13$ ) ( $128.77 \pm 33.54$ ) respectively. No statistically significant difference was observed between the two test groups at P-value (0.863). The radiofrequency values for implant stability showed no statically significant difference after nine months of follow up when compared to the initial stability values at the day of insertion in the intervention and control group. The mean radiofrequency values were ( $67.24 \pm 1.79$ ) and ( $66.9 \pm 2.57$ ) respectively, and no statistically significant difference was observed between the two test groups at P-value (0.793)

**CONCLUSION:** There are no statistically significant differences in post-operative pain values, implant stability and bone density between the implant sites treated with PRF augmented by Diode laser compared to implant sites treated by PRF alone.

## Introduction

Osseo-integration of the dental implant is currently considered a key parameter for measuring long-term success of the dental implant. The osseointegration assessment could be achieved either clinical by measuring the implant stability, histological evaluating the quality of bone and bone formation or Radiographic through measuring the peri-implant

bone density. Among the different techniques used in clinical assessment, Radiofrequency analysis with OSSTEL<sup>®</sup> device is a reliable and simple technique reflecting implant stability [1]. Digital intraoral radiographic assessment of relative bone density around the dental implant is another applicable and widely used method reflecting the osseointegration [2].

Studies have been conducted to evaluate different techniques, materials and protocols to

improve osseointegration achieving long-term success of the dental implant. Among these trials, surface treatment to dental implant material, developing enhanced implant designs, the use of different implant placement surgical techniques and the use of Bio-modulators to accelerate healing of tissues around dental implants. PRF as a Bio-modulator is a rich source of growth factors that have been successfully used to enhance bone and soft tissue healing. The Diode LASER or Low-level LASER has been used to accelerate healing through induction of formative cells and angio-neogenesis [3], [4], [5].

The implant Osseo-integration is better achieved through the use of bio-modulators such as Platelet Rich Fibrin (PRF) and Low-Level Laser Treatment (LLLT). Each of these treatments PRF and LLLT, when used alone, is proven to have positive effects on bone and soft tissue healing around the dental implant as reported by many studies [2], [3], [4], [5]. However, these studies focused on the effect of either PRF or LLLT alone, the effect of the combination PRF and LLLT both clinically and radiographically has not been studied yet.

The use of LLLT for therapy was adopted in the late 1960s. This technique was applied to stimulate and improve healing, as well as reducing pain because of its stimulatory effect on different cell types. LLLT in soft tissue has been used clinically to speed up the healing of wounds and to control pain [6].

On the other hand, the use of PRF which is rich in platelet and leukocyte cytokines and growth factors are known for its angiographic, hemostatic and osseous conductive properties, has been proven to improve bone healing around dental implant [7], [8], [9].

## Subjects and Methods

### **Trial design**

This is randomised clinical trial, split-mouth design. Nine patients are suffering from bilaterally missing mandibular posterior teeth in two parallel groups, with allocation ratio 1:1.

### **Participants**

#### *Eligibility criteria*

*Inclusion criteria:* Missing teeth in the posterior mandibular region bilaterally, Absence of any pathological condition in the posterior region (recipient site) at the time of intervention.

*Exclusion criteria:* Systemic disease (metabolic bone disease, uncontrolled diabetes

myelitis, autoimmune diseases, patients treated with corticosteroids at the last three months, infectious diseases, salivary gland diseases, malignancy) or any disease which may affect the peri-implant healing process. Poor oral hygiene, patients with severe chronic periodontitis as well as aggressive periodontitis in the adjacent teeth to the edentulous area pregnant female. Regular smokers, previous head or neck radiation therapy, Patient with an allergy to any material or medication that will be used in the study, severe psychological problems (Para-functional habits and Bruxism), a patient with the thin wiry ridge (2 mm in width).

### **Study setting**

The patients were recruited in consecutive order from the pool of patients of the central clinic, Faculty of Oral and Dental Medicine, Cairo University, until the target population was reached.

### **Intervention**

*Pretreatment measures:* the following steps were done for all enrolled patients: detailed recording history including systemic condition, duration as well as diseases and drug history. Undergoing full clinical examination (extra-oral and intra-oral), Giving oral hygiene instructions (verbally and written), Tacking baseline radiographs and photographs.

You are obtaining signed informed consent after explaining the steps of the study and discussing the treatment plan.

### **Steps for intervention preparation**

PRF preparation protocol: the PRF preparation was done according to Choukroun's Protocol [10].

A) For each patient, venous blood was drawn by the same operator from an antecubital vein with pain-free blood test needles (25 Gauge).

B) About 50 ml (0.05 IU) whole venous blood collected in a sterile vacutainer tube without anticoagulant and the vacutainer tubes were then placed in a centrifugal machine at 3,000 revolutions per minute (rpm) for 10 min.

C) The resultant gelatinous PRF was placed directly on the buccal bone surface after placement of the implant.

### **Surgical Procedures**

1. All surgical procedures were performed according to Misch's Protocol [11].

2. At the edentulous site, a full thickness flap lingual to ridge crest was performed.

3. Standard drills of sequential diameters were used, and the implant was inserted.
4. Implant placement: Insertion of the suitable implant according to the available bone in each site.
5. PRF placement on the buccal bone surface.

### Laser application

Application of LLLT was performed according to Mandić [12]. Patients were briefly informed about the biological effect of Diode Laser and PRF before the operation. The irradiation was performed with a gallium-aluminium-arsenide (GaAlAs) diode low-level laser with continuous emission of 830 nm wavelength. The laser beam power of 100 mW and laser spot size was 0.28 cm<sup>2</sup>, resulting in a calculated energy density of 92.1 J/cm<sup>2</sup> and energy of 0.25 J per point. The irradiation time was 30 second per point; the points of irradiation were buccally and lingually with equal time of irradiation; the total delivered energy was 15 J per irradiation session. The application of Diode Laser was performed in 8 visits twice weekly starting from the day of insertion and end 1 month after insertion.

### Post-operative pain assessment

It was done daily for 1 week starting from day of implant insertion using NRS for each implant site, for implant stability

### Radio Frequency Assessment

Resonance frequency analysis (RFA) was performed using the Osstell™ Mentor instrument. Measurements were recorded immediately after implant insertion and then after four months of insertion then nine months of insertion. A standardised abutment of fixed length was inserted and hand-tightened into each implant. The transducer probe was held so that the probe tip was aimed at the small magnet on top of the Smartpeg™ at a distance of 2-3 mm Figure 1. according to García-Morales et al., 2012.

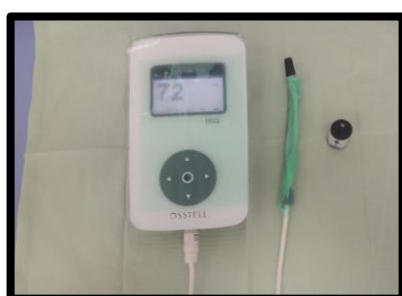

Figure 1: Showing Osstell™ device used in Resonance frequency analysis of implants

Radiographic examination for peri-implant relative bone assessment was done day of the operation, 1 month, 4 months and 9 months using digital intra-oral PSP radiographic assessment (Digora size 2 sensor, Digora Optime UV scanning sensor unit, and X-ray unit Soredex) with exposure parameters 70 kVp, 7 mA and 0.08 Sec ) using radiographic stent for Standardized accurate radiographic image, relative bone density around implant was evaluated on DR software by taking three parallel lines at each side (mesial, distal and apical) with 1mm distance between each line and other then the mean of relative bone density at the three lines in each side was calculated to determine the density at each side (mesial, distal and apical) according to Zaky et al., 2016 examination [16].

## Results

### Demographic data

This study was carried out on nine female patients (split-mouth design) with mean age 45 SD ± 12.5.

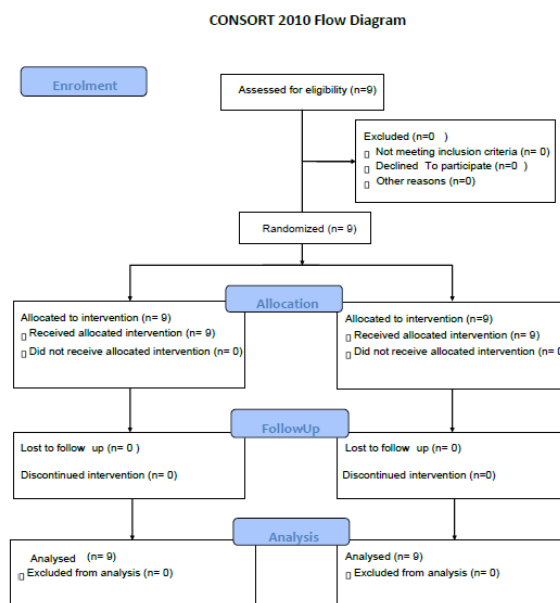


Figure 2: Patients' flow chart

### Post-operative pain in each group in different follow up periods:

1) Control group: There was a statistically significant difference between day 1 and day 7 with a mean difference  $-4.33 \pm 1.252$ ,  $P = 0.0032$  using paired T-test.

2) Intervention group

There was a statistically significant difference

in postoperative pain values between day 1 and day 7 with a mean difference  $-4.66 \pm 1.178$ ,  $P = 0.0011$  using paired T-test.

### Implant stability in each group in different follow up periods

#### Control group

The implant stability values comparison showed no statistically significant difference in implant stability through all test periods.

**Table 1: implant stability values of the intervention group**

Comparatives	Definition	Mean	Mean differences	SD. Deviation	P value	Comment
Pair 1	implant stability at insertion-implant stability at 4m	Insertion 67.13	-1.45556	4.59622	0.370	Non-significant
Pair 2	implant stability at 4m-implant stability at 9 m	4 months 69.16	1.71111	2.12099	0.042	Significant
Pair 3	implant stability at insertion-implant stability at 9 m	9 months 67	0.25556	5.16602	0.886	Non-significant

#### Intervention group

The implant stability values comparison showed no statistically significant difference in implant stability between insertion time and 4 months after insertion.

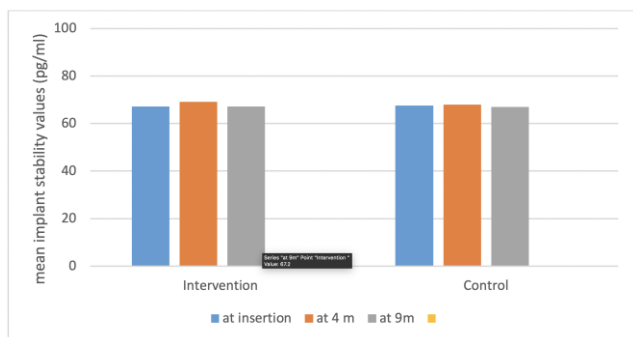


Figure 3: Showing mean implant stability in different follow-up periods

### Bone density in each group in different follow up periods

#### Control group

There were no statistically significant differences between relative bone density values through all periods.

**Table 2: Relative bone density of the control group in different follow-up periods**

Comparatives	Definition	Mean	Mean differences	SD	P value	comment
Pair 1	bone density at insertion-bone density at 1 m	Insertion 130.46	-5.57	26.62	0.547	Non-significant
Pair 2	bone density at 1 m-bone density at 4 m	1 month 135.98	-3.17	20.15	0.649	Non-significant
Pair 3	bone density at 4 m-bone density at 9 m	4 months 139.24	10.44	28.40	0.302	Non-significant
Pair 4	bone density at insertion-bone density at 4 m	9 months 128.77	-8.75	25.04	0.325	Non-significant
Pair 5	bone density at insertion-bone density at 9 m		1.68	32.26	0.879	Non-significant

\*Paired t-test.

#### Intervention group

There were no statistically significant differences between relative bone density values through all periods.

**Table 3: Relative Bone density of the intervention group in different follow-up periods**

Comparatives	Definition	Mean	Mean differences	Std. Deviation	P value	Comment
Pair 1	Bone density at insertion-Bone density at 1 m	Insertion 136.35	-10.62	33.33065	0.367	Non-significant
Pair 2	Bone density at 1 m-Bone density at 4 m	1 month 145.38	2.52	21.52073	0.734	Non-significant
Pair 3	Bone density at 4 m-Bone density at 9 m	4 months 142.86	17.25	28.93117	0.111	Non-significant
Pair 4	Bone density at insertion-Bone density at 4 m	9 months 134.42	-8.10	39.79447	0.558	Non-significant
Pair 5	Bone density at insertion-Bone density at 9 m		9.155	32.63181	0.424	Non-significant

\*Paired t-test.

### Comparison between the two test groups

A- Post-operative pain between the two study groups in different follows up periods.

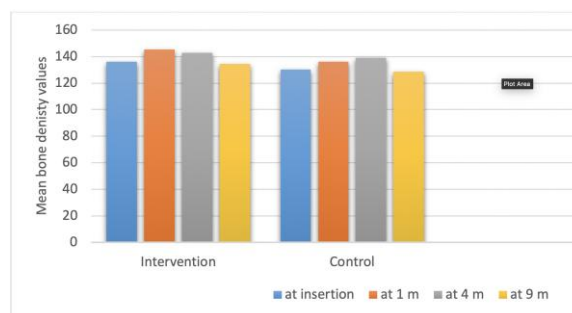


Figure 4: Showing mean density values in different follow-up periods

There were no statistically significant differences in post-operative pain values between both tests groups at all study periods using student t-test  $P$  value  $\leq 0.05$ .

**Table 4: Comparison between postoperative pain of the two study groups in the different follow-up periods**

Comparatives	Intervention	Control	Mean difference	P value	Comments
pain at day 1	6.8	6.4	0.44	0.774	Non-significant
pain at day 2	6.2	4.8	1.33	0.370	Non-significant
pain at day 3	5.2	4.5	0.66	0.554	Non-significant
pain at day 4	4.0	4.2	-0.22	-0.879	Non-significant
pain at day 5	3.2	3.6	-0.44	-0.728	Non-significant
pain at day 6	2.3	2.6	-0.33	-0.728	Non-significant
pain at day 7	2.2	2.1	0.11	0.892	Non-significant

### Implant stability between the two study groups in different follow up periods

There were no statistically significant differences in implant stability values between both groups at all study periods using student T-test, Table 5.

**Table 5: Comparison between implant stability of the two study groups in the different follow-up periods**

Comparatives	Intervention (mean)	Control (mean)	Mean difference	P value	Comment
Implant stability at insertion	67.1	67.5	-0.044	-0.982	Non-significant
Implant stability at 4m	69.1	67.8	1.055	0.281	Non-significant
Implant stability at 9 m	67.2	66.9	0.277	0.793	Non-significant

### **Comparison between Relative Bone density values of the two study groups in different follow up periods**

There was no statistically significant difference in relative bone density values between both test groups at all study periods using Student T-test Table 6.

**Table 6: Relative bone density differences between the two study groups in the different follow up periods**

Comparatives	Intervention (mean)	Control (mean)	Mean difference	P value	Comment
bone density at 1 m	145.3	135.9	9.98889	0.556	Non-significant
bone density at 4m	142.8	139.5	4.28889	0.760	Non-significant
bone density at 9 m	134.4	128.7	-2.52222	0.863	Non-significant

## **Discussion**

Bio-stimulation is an emerging concept in the field of dentistry that has been proven to accelerate the biological process of healing and regeneration. The purpose of the current study is to evaluate the combined effect of two bio-stimulants, Platelet Rich fibrin and Diode Laser compared to PRF alone. A randomised clinical trial was carried out on nine patients with missing bilateral posterior teeth in a split-mouth study. All nine patients received one dental implant on each side with PRF. On one side LLLT was applied to start from the day of insertion twice weekly for one month postoperatively.

Many of the published studies have assessed the effects of either LLLT or PRF on bone healing around dental implants; however and up to our knowledge this is the first study evaluating the effect of the two techniques together on healing and osseointegration around dental implants both clinically and radiographically using digital radiography [7], [9], [22].

Although LLLT had a strong body of evidence supporting its role in the neo-bone formation and increased implant stability, the absence of a unified protocol of LLLT application around dental implant demands more researches on this point to identify a successful protocol [17], [19], [21].

Post-operative pain was assessed as a primary outcome using numerical rating score daily for seven days. The secondary outcomes assessed were implanted stability and relative peri-implant stability.

The results of the present study revealed no significant difference between the two treatments.

Although the results of this study have shown significant pain reduction in each of the test group alone, the comparison revealed no significant differences between the two test groups. In agreement Marenzi et al., in 2015 [4] investigated the influence of PRF on post-extraction healing. Where twenty-six patients were enrolled in their study and a split-mouth design was adopted. Only one side post-extraction sockets received PRF and the other side used as a control. The results were a significant pain reduction in PRF sides.

On the other hand Ozgul et al., 2015 [25] assessed postoperative pain reduction in the presence of PRF compared to non-PRF protocol after third molar extraction in a multicenter randomised clinical trial on fifty-six patient. The study stated no statistically significant differences regarding pain among the groups.

In accordance He et al., in 2014 [3] conducted a systematic review of evidence for LLLT pain reduction capacity post extraction. They pooled the data of 193 patients in a meta-analysis. Despite the authors' comment on the poor quality of the evidence and high risk of bias, their conclusion was a significant pain reduction after laser irradiation post-surgical. Also, Landucci et al., 2016 [24] evaluated postoperative pain in twenty two post extraction patients. The patients were randomly distributed into two groups, one subjected to a single session of laser radiation and the other didn't receive radiation. They reported the same results.

Concerning the implant stability and relative bone density, the present study results have shown no significant differences in each test group starting from the day of insertion till the end study time also no significant difference was found between the two test groups. In agreement, this was in contradiction to the results reported by Jang et al., in 2010 [2]. The study investigated the ability of PRF to fill peri-implant bone defects in rabbit models. They concluded that peri-implant defect could be successfully repaired by the application of Choukroun PRF. This evidence supported the ability of PRF to induce neo-bone formation. However, the study was an animal study, and the neo-bone formation was histologically evaluated.

A significant difference was found in pain in each group from the 1<sup>st</sup> day to the 7<sup>th</sup> day postoperatively in this study. Pain may be reduced as a result of the usage of PRF, finding in agreement of Ozgul et al., 2015 [25] how assessed postoperative pain reduction in the presence of PRF after third molar extraction, and the study of Marenzi et al., in 2015 [4] which investigated the influence of PRF on post-extraction healing. Where twenty-six patients were enrolled in their study and a split-mouth design was adopted. Only one side post-extraction sockets

received PRF and the other side used as a control. The results were a significant pain reduction in PRF sides.

The evaluation of PRF validity in neo-bone formation was evaluated by Jang et al., in 2010 [2] study which detected the ability of PRF to fill peri-implant bone defects in rabbit models. They concluded that peri-implant defect could be successfully repaired by the application of Choukroun PRF. This evidence supported the ability of PRF to induce neo-bone formation.

Zaky et al., in 2016 [16] conducted a prospective randomised controlled trial on 16 patient evaluated the bone healing in maxillary cystic defect reflected by digital radiographic assessment of bone density after single post-operative LLLT session and follow up period for 90 days. The results were a significant increase in bone density in the laser group. This contradiction could be attributed to the nature of the maxillary bone and the different pathological condition. [20], [26], [27].

Castro et al., in 2017 [5] conducted a systematic review of evidence on the ability of L-PRF to induce neo-bone formation in periodontal defects. The results stated that "Favorable effects on hard and soft tissue healing and postoperative discomfort reduction were often reported when L-PRF was used favoured the potential ability of PRF to induce neo-bone formation in periodontal defects". However, the different material used and different protocol, as well as nature of the disease, may justify this contradiction

In conclusion, there are no statistically significant differences in post-operative pain values, implant stability and bone density between the implant sites treated with PRF augmented by Diode laser compared to implant sites treated by PRF alone.

## References

- Perry K. Oral implantology Carranza's Clinical Periodontology. 12th edition St. Louis, Missouri: Elsevier Saunders. part 7 chapter 68, 2015:1019-1030.
- Jang ES, Park JW, Kweon H, Lee KG, Kang SW, Baek DH, Choi JY, Kim SG. Restoration of peri-implant defects in immediate implant installations by Choukroun platelet-rich fibrin and silk fibroin powder combination graft. Oral Surgery, Oral Medicine. Oral Pathology and Oral Radiology. 2010; 109 (6):831-6. <https://doi.org/10.1016/j.tripleo.2009.10.038> PMID:20163973
- He WL, Yu FY, Li CJ, Pan J, Zhuang R, Duan PJ. A systematic review and meta-analysis on the efficacy of low-level laser therapy in the management of complication after mandibular third molar surgery. Lasers in medical science. 2014; 30(6):1779-88. <https://doi.org/10.1007/s10103-014-1634-0> PMID:25098769
- Marenzi G, Riccitiello F, Tia M, di Lauro A, Sammartino G. Influence of leukocyte-and platelet-rich fibrin (L-PRF) in the healing of simple post extraction sockets: a split-mouth study. BioMed research international. 2015; 2015.
- Castro AB, Meschi N, Temmerman A, Pinto N, Lambrechts P, Teughels W, Quirynen M. Regenerative potential of leucocyte-and platelet-rich fibrin. Part B: sinus floor elevation, alveolar ridge preservation and implant therapy. A systematic review. Journal of clinical periodontology. 2017; 44(2):225-34. <https://doi.org/10.1111/jcpe.12658> PMID:27891638 PMCid:PMC5347939
- Nissan J, Assif D, Gross MD, Yaffe A and Binderman I. Effect of low intensity laser irradiation on surgically created bony defects in rats. Journal of Oral Rehabilitation. 2006; 33(8):619-924. <https://doi.org/10.1111/j.1365-2842.2006.01601.x> PMID:16856960
- Borie E, Oliví DG, Orsi IA, Garlet K, Weber B, Beltrán V, Fuentes R. Platelet-rich fibrin application in dentistry: a literature review. International journal of clinical and experimental medicine. 2015; 8(5):7922–7929. PMID:26221349 PMCid:PMC4509294
- Freitas Fulton RM, Susin C, Spin-Neto R, Marcantonio C, Wikesj UME, Pereira LAVD, Marcantonio E. Horizontal Ridge Augmentation of the atrophic anterior maxilla using Rbmp-2/ACS or autogenous bone grafts: A proof of concept randomized clinical trial. Journal of Clinical Periodontology. 2013; 40(10):968-975. <https://doi.org/10.1111/jcpe.12148> PMID:23998375
- Cortese A, Pantaleo G, Borri A, Caggiano M, Amato M. Platelet-rich fibrin (PRF) in implant dentistry in combination with new bone regenerative technique in elderly patients. International Journal of Surgery Case Reports. 2016; 28:52-56. <https://doi.org/10.1016/j.ijscr.2016.09.022> PMID:27689517 PMCid:PMC5043401
- Choukroun J, Diss A, Simonpieri A, Girard MO, Schoeffler C, Dohan SL, Dohan DM. platelet Rich Fibrin (PRF) A second generation platelet concentration. Part IV: Clinical Effect on Tissue Healing. Oral Surgery, Oral Medicine, Oral Pathology, Oral Radiology and Endodontology. 2006; 101(3):56-60. <https://doi.org/10.1016/j.tripleo.2005.07.011> PMID:16504852
- Misch CE. Dental Implant Prosthetics, Churchill Livingstone. Elsevier Mosby, Industrial Drive St. Louis, Missouri. 2014.
- Mandić B, Lazić Z, Marković A, Mandić B, Mandić M, Đinić A, Miličić B. Influence of postoperative low-level laser therapy on the osseointegration of self-tapping implants in the posterior maxilla: A 6-week split-mouth clinical study. Vojnosanitetski pregled. 2015; 72(3):233-40. <https://doi.org/10.2298/VSP131202075M> PMID:25958474
- Breivik H, Borchgrevink PC, Allen SM. Assessment of pain. Br. J. Anaesth. 2008; 101(1):17-24. <https://doi.org/10.1093/bja/aen103> PMID:18487245
- García-Morales JM, Tortamano-Neto P, Todescan FF, de Andrade JC, Marotti J, Zezell DM. Stability of dental implants after irradiation with an 830-nm low-level laser: a double-blind randomized clinical study. Lasers in medical science. 2012; 27(4):703-11. <https://doi.org/10.1007/s10103-011-0948-4> PMID:21732113
- Faul, F., Erdfelder, E., Lang, A-G., & Buchner, A.: G\*Power 3: A flexible statistical power analysis program for the social, behavioral, and biomedical sciences. Behavior Research Methods. 2007; 39:175-191. <https://doi.org/10.3758/BF03193146> PMID:17695343
- Zaky AA, El Shenawy HM, Harhsh TA, Shalash M, Awad NM. Can low level laser therapy benefit bone regeneration in localized maxillary cystic defects?-a prospective randomized control trial. Open access Macedonian journal of medical sciences. 2016; 4(4):720. <https://doi.org/10.3889/oamjms.2016.140> PMID:28028422 PMCid:PMC5175530
- Fávaro-Pípi E, Ribeiro DA, Ribeiro JU, Bossini P, Oliveira P, Parizotto NA, Tim C, de Araújo HS, Renno AC. Low-level laser therapy induces differential expression of osteogenic genes during bone repair in rats. Photomedicine and laser surgery. 2011; 29(5):311-7. <https://doi.org/10.1089/pho.2010.2841> PMID:21306231
- Romanos GE, Gupta B, Yunker M, Romanos EB, Malmstrom H. Lasers use in dental implantology. Implant dentistry. 2013; 22(3):282-8. <https://doi.org/10.1097/ID.0b013e3182885fcc> PMID:23571715

19. Soares LG, Magalhaes Junior EB, Magalhaes CA, Ferreira CF, Marques AM, Pinheiro AL. New bone formation around implants inserted on autologous and xenografts irradiated or not with IR laser light: a histomorphometric study in rabbits. *Brazilian dental journal*. 2013; 24(3):218-23. <https://doi.org/10.1590/0103-6440201302186> PMID:23969909
20. de Almeida AL, Medeiros IL, Cunha MJ, Sbrana MC, de Oliveira PG, Esper LA. The effect of low-level laser on bone healing in critical size defects treated with or without autogenous bone graft: an experimental study in rat calvaria. *Clinical oral implants research*. 2014; 25(10):1131-6. <https://doi.org/10.1111/clr.12239> PMID:23919887
21. Batista JD, Sargenti-Neto S, Dechichi P, Rocha FS, Pagnoncelli RM. Low-level laser therapy on bone repair: is there any effect outside the irradiated field?. *Lasers in medical science*. 2015; 30:245–249. <https://doi.org/10.1007/s10103-015-1752-3> PMID:25975746
22. Barber A, Luger JE, Karpf A, Salame K, Shlomi B, Kogan G, Nissan M, Alon M, Rochkind S. Advances in laser therapy for bone repair. *Laser Therapy*. 2001; 13:80-5. <https://doi.org/10.5978/islsm.13.80>
23. Lim HM, Lew KK, Tay DK. A clinical investigation of the efficacy of low level laser therapy in reducing orthodontic post adjustment pain. *American Journal of Orthodontics and Dentofacial Orthopedics*. 1995; 108(6):614-22. [https://doi.org/10.1016/S0889-5406\(95\)70007-2](https://doi.org/10.1016/S0889-5406(95)70007-2)
24. Landucci A, Wosny AC, Uetanabaro LC, Moro A, Araujo MR. Efficacy of a single dose of low-level laser therapy in reducing pain, swelling, and trismus following third molar extraction surgery. *International journal of oral and maxillofacial surgery*. 2016; 45(3):392-8. <https://doi.org/10.1016/j.ijom.2015.10.023> PMID:26691932
25. Ozgul O, Senses F, Er N, Tekin U, Tuz HH, Alkan A, Kocyigit ID, Atil F. Efficacy of platelet rich fibrin in the reduction of the pain and swelling after impacted third molar surgery: Randomized multicenter split-mouth clinical trial. *Head & face medicine*. 2015; 11(1):37. <https://doi.org/10.1186/s13005-015-0094-5> PMID:26607842 PMCID:PMC4660809
26. Ceclia L, Sallum E, Nociti F, Moreira R: The effect of low-intensity laser therapy on bone healing around titanium implants: A histometric study in rabbits. *Int J Oral Maxillofac Impl*. 2009; 24:47-51.
27. Adel JH, Abdalbar AA, Mohsen AJ, Al-Nawar AH: Effect of LLLT on the acceleration of wound healing in rabbits: *North Am j Med Sci*. 2011; 3:4.