

Arthroscopic Reduction and Percutaneous Osteosynthesis of Tibial Plateau Fractures

Konstantin Mitev^{1,2*}, Gorgi Zafirovski¹, Sasho Mladenovski¹, Ljupcho Nikolov¹

¹Special Hospital for Surgical Disease Zan Mitrev, Skopje, Republic of Macedonia; ²Univesity Goce Delchev, Faculty of Medical Sciences, Shtip, Republic of Macedonia

Abstract

Citation: Mitev K, Zafirovski G, Mladenovski S, Nikolov Lj. Arthroscopic Reduction and Percutaneous Osteosynthesis of Tibial Plateau Fractures. Open Access Maced J Med Sci. <https://doi.org/10.3889/oamjms.2019.197>

Keywords: Tibial plateau fractures; Arthroscopic reduction; Percutaneous osteosynthesis

***Correspondence:** Konstantin Mitev. Special Hospital for Surgical Disease Zan Mitrev, Skopje, Republic of Macedonia; Univesity Goce Delchev, Faculty of Medical Sciences, Shtip, Republic of Macedonia. E-mail: konstantin.mitev@filipvtori.com

Received: 04-Feb-2019; **Revised:** 21-Feb-2019; **Accepted:** 22-Feb-2019; **Online first:** 13-Mar-2019

Copyright: © 2019 Konstantin Mitev, Gorgi Zafirovski, Sasho Mladenovski, Ljupcho Nikolov. This is an open-access article distributed under the terms of the Creative Commons Attribution-NonCommercial 4.0 International License (CC BY-NC 4.0)

Funding: This research did not receive any financial support

Competing Interests: The authors have declared that no competing interests exist

BACKGROUND: Tibial plateau fractures are complex lesions capable of causing severe consequences if not appropriately treated. They are often the result of high-energy trauma and, not rarely, are associated with significant soft-tissue and intra-articular injuries. Different therapeutic options can be managed in the treatment of these lesions. Minimally invasive surgery percutaneous technique-offers several advantages compared to other surgical techniques and allows, with less additional soft tissue damages, good reduction and stable fixation of the fracture.

CASE PRESENTATION: In this study, we assessed the results of the combined arthroscopic and radioscopic assisted reduction and internal fixation of tibial plateau fractures in 7 patients with Schatzker type II and III.

CONCLUSION: According to Hohl's and Rasmussen's grading system, all of the patients scored excellent and good results at 1 year follow up. We experienced no complications due to arthroscopy.

Introduction

Tibial plateau fractures are complex lesions capable of causing severe consequences if not appropriately treated. They are often the result of high-energy trauma and, not rarely, are associated with significant soft-tissue and intra-articular injuries. Different therapeutic options can be managed in the treatment of these lesions. Minimally invasive surgery percutaneous technique-offers several advantages compared to other surgical techniques and allows, with less additional soft tissue damages, good reduction and stable fixation of the fracture [1].

Methods

Between April 2013 and December 2016, seven lateral tibial fractures were treated with arthroscopic assisted osteosynthesis. The patients had a mean age of 42 years (22 – 56 years), male three and four female. The cause of injury was pedestrian hit by a car – three patients, fall from height two of them and two-sport injuries.

According to the Shatzker classification (image 1), four fractures were type II, and three were type III. Surgery was done when the swelling subsided

on the average 4-the day (3-6 d). Mean follow up period = 18 months (12 – 24 months).

Inclusion criteria were a proximal tibial fracture with > 3 mm articular step off. We excluded complex fracture type IV-VI. We obtained informed consent from all patients preoperatively.

We used the t-test for statistical analysis, and we considered a result of $p < 0.05$ statistically significant.

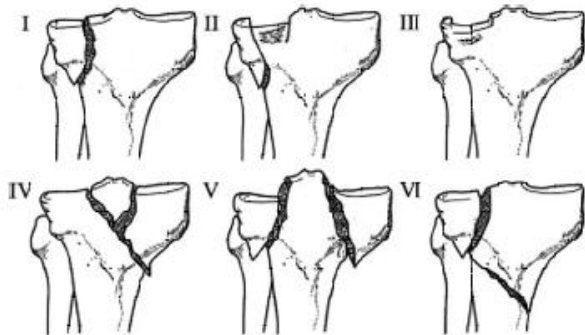


Figure 1: Shatzker classification

Surgical technique

The operating room setup requires positioning of the patient as a standard knee arthroscopy procedure and place for fluoroscopy C-arm monitor. The leg holder is placed more proximal than usual, exsanguinated with esmarch bandage, the contralateral limb is abducted ensuring that is it out of imaging. The standard arthroscopic portals are used. Concomitant pathology as meniscal and cartilage injury are diagnosed and treated.

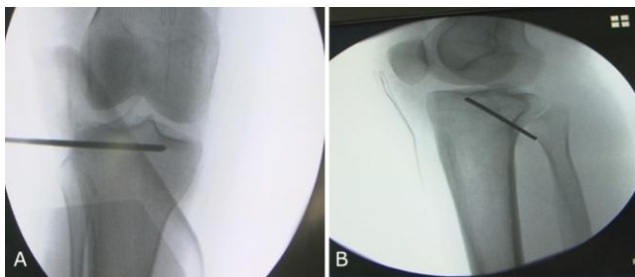


Figure 2: A) and B) k-wire starting position

According to the type of the fracture we placed the k-wire (Figure 2), and with joystick technique, we reduce the fracture, or we put the ACL guide pin percutaneously from the anteromedial tibia and with a cannulated bone tamp elevated the depressed fragment. Once satisfactory reduction under arthroscopic control is achieved (Figure 3) three to four 3, 5 or 4.5 partially or fully threaded screws are drilled and tapped. The bone tunnel was grafted to increase subchondral support.

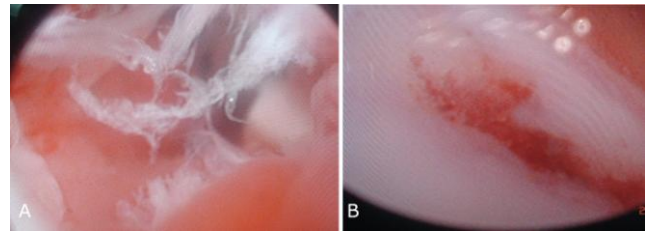


Figure 3: A) and B) Pre- and post-fracture reduction- arthroscopic view

Results

All treated fractures were successfully united, Average length of union 12 weeks (10 – 13 week). Preoperative fracture depression average 7 mm (3 – 10 mm).

At the clinical assessment subjectively all for the patient were satisfied with this technique. According to the Rasmussen criteria. 6 (86 %) were excellent, and one (14%) was good.

Concomitant lesions were noted, four of them had a lateral meniscal lesion, one medial meniscal and partial ACL tear. We partially resected the meniscal lesions, and we treated conservatively ACL partial tear.

We didn't find any statistical difference between the range of motion of injured and noninjured knee -135-140 degree ($p > 0.05$) Figure 4.

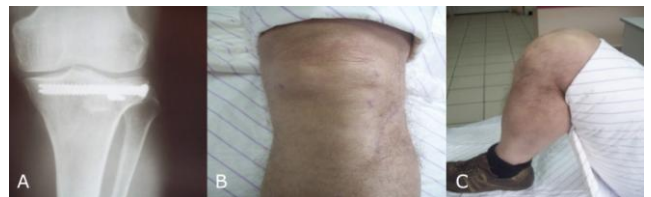

Figure 4: A), B), and C) Three months postoperative results

Discussion

Arthroscopically assisted percutaneous fixation which was first recommended by Caspari [2], and Jennings [3] has gradually become popular during the years. The advantages of this technique are an exact visualisation of the intraarticular fracture, accurate reduction, lower morbidity and immediate treatment of associated soft tissue lesions. Ohdera [4] reported no difference in the duration of surgery, clinical results between two open and arthroscopic technique.

It was reported that not all plateau tibial

fractures are amenable for arthroscopic assisted osteosynthesis. High energy fractures according to Shatzker IV-VI are associated with potential risk of fluid extravasation and compartment syndrome [5], [6], [7]. Torneta et al., [7] insisted in using arthroscopic assisted osteosynthesis only in Shatzker type I, II and III.

According to that all the fractures healed without angular deformity, no complications, infections or compartment syndrome, in conclusion, we can accept arthroscopic assisted osteosynthesis as an effective, minimally invasive, surgical method for the treatment of low energy plateau tibial fractures [8] Shatzker II and III types.

References

1. Gill TJ, Moezzi DM, Oates KM, Sterett WI. Arthroscopic reduction and internal fixation of tibial plateau fractures in skiing. *Clinical Orthopaedics and Related Research*®. 2001; 383:243-9. <https://doi.org/10.1097/00003086-200102000-00028>
2. Caspari RB, Patrick MJ, Hutton TL, et al. The role of arthroscopy in the management of tibial plateau fractures. *Arthroscopy*. 1985; 1:76-82. [https://doi.org/10.1016/S0749-8063\(85\)80035-9](https://doi.org/10.1016/S0749-8063(85)80035-9)
3. Jennings JE. Arthroscopic management of tibial plateau fractures. *Arthroscopy*. 1985; 1:160-8. [https://doi.org/10.1016/S0749-8063\(85\)80003-7](https://doi.org/10.1016/S0749-8063(85)80003-7)
4. Ohdera T, Tokunaga M, Hiroshima S, et al. Arthroscopic management tibial plateau fractures – comparison with open reduction method. *Arch Orthop Trauma Surg*. 2003; 123:489-93. <https://doi.org/10.1007/s00402-003-0510-3> PMID:12720016
5. McClellan RT, Comstock CP. Evaluation and treatment of tibial plateau fractures. *Curr Opin Orthop*. 1999; 10:10-21. <https://doi.org/10.1097/00001433-199902000-00003>
6. Guanche CA, Marman AW. Technical notes. Arthroscopic management of tibial plateau fractures. *Arthroscopy*. 1993; 9:467-71. [https://doi.org/10.1016/S0749-8063\(05\)80324-X](https://doi.org/10.1016/S0749-8063(05)80324-X)
7. Tornetta P. Arthroscopic elevation with grafting. *J Orthop Trauma*. 2002; 16:444-6. <https://doi.org/10.1097/00005131-200207000-00017> PMID:12142839
8. Kayali C. Arthroscopically assisted percutaneous osteosynthesis of lateral tibial plateau fractures. *Can J Surg*. 2008; 51(5):378–382. PMID:18841234 PMCID:PMC2556545