

Clinical Behaviour and Marginal Sealing of Bulk-Fill Resin Composite Restorations Using Light Amplified High-Intensity LEDs Curing: A Randomized Controlled Clinical Trial

Shereen Essameldin Fahim¹, Mostafa Abdelhamid Mostafa², Mohsen Hussein Abi-Elhassan², HebatAllah Mohamed Taher²

¹Conservative Dentistry Department, Faculty of Dentistry, October 6 University, Giza, Egypt; ²Conservative Dentistry Department, Faculty of Dentistry, Cairo University, Cairo, Egypt

Abstract

Citation: Fahim SE, Mostafa MA, Abi-Elhassan MH, Taher HM. Clinical Behaviour and Marginal Sealing of Bulk-Fill Resin Composite Restorations Using Light Amplified High-Intensity LEDs Curing: A Randomized Controlled Clinical Trial. Open Access Maced J Med Sci. <https://doi.org/10.3889/oamjms.2019.216>

Keywords: LAHI LED curing; Bulk-fill; Clinical performance; Marginal sealing

***Correspondence:** Shereen Essameldin Fahim. Conservative dentistry department, Faculty of Dentistry, October 6 University, Giza, Egypt. E-mail: sherenesameldien@gmail.com

Received: 25-Feb-2019; **Revised:** 14-Apr-2019; **Accepted:** 15-Apr-2019; **Online first:** 29-Apr-2019

Copyright: © 2019 Shereen Essameldin Fahim, Mostafa Abdelhamid Mostafa, Mohsen Hussein Abi-Elhassan, HebatAllah Mohamed Taher. This is an open-access article distributed under the terms of the Creative Commons Attribution-NonCommercial 4.0 International License (CC BY-NC 4.0)

Funding: This research did not receive any financial support

Competing Interests: The authors have declared that no competing interests exist

BACKGROUND: Delivering sufficient intensity output of curing lights is mandatory to ensure optimum cure and clinical success of bulk-fill resin composite restorations and to avoid undesirable clinical outcomes.

AIM: To evaluate the effectiveness of using light amplified high intensity LED curing on the clinical performance and marginal sealing of posterior bulk-fill resin composite restorations.

MATERIAL AND METHODS: This study was designed as a randomised, controlled, double-blind, Unicenter, parallel, two arms, superiority trial with 1:1 allocation ratio. Adult patients who required posterior tooth-coloured restorations were asked to participate in this trial. All participants signed written informed consent after being completely aware of the settings of the study. The participants who fulfilled the eligibility criteria were divided into two groups according to the type of light curing mode used. Adhesive compound proximal cavities were prepared. All restorative materials were applied according to the respective manufacturer's instructions. Assessments of the restorations were done at baseline (one week after placement of the restoration), after 6 months and after 12 months using the modified US Public Health Service (USPHS) criteria. For quantitative assessment of the marginal sealing, resin replicas were analysed using scanning electron microscopy. Statistical analysis was done using Chi-square, Mann Whitney, independent t-test and dependent t-tests.

RESULTS: There were no statistical differences between the two groups for the tested clinical parameters along the study periods. For marginal analysis, there were no statistical differences between the intervention and control group at baseline and six months (p -value = 0.347 and 0.516) respectively. At 12 months the control group showed statistically significant higher percentages (p -value = 0.031).

CONCLUSION: Light amplified high-intensity curing units have clinical performance comparable with the conventional LED.

Introduction

The improvements in resin composite formulations and newer generation bonding agents, as well as the increasing demand for esthetics, have made composite resin restoration the optimal choice for restoring posterior teeth. Several efforts have been continuously made to improve its physical and mechanical properties and to simplify its application techniques [1], [2]. Application of resin composite restorations requires a dry field to guarantee effective enamel and dentin etching, priming, and bonding. The application has usually been incremental, with the

maximum incremental thickness of two millimetres, to ensure complete curing of resin composites, in addition to minimisation of the polymerisation shrinkage and associated shrinkage-induced stress [3].

A new resin composite material class has been introduced in the past years relying upon bulk-fill technology. These newly introduced bulk-fill resin composites have additional light penetration and deeper cure depth properties due to both increased translucency and developments in photoinitiator dynamics, so they can be used to fill cavities up to 4-5 mm at once allowing for more convenient procedure and reducing the operatory times required for

restoration of large cavities [4], [5], [6].

Delivering sufficient intensity output of curing lights is mandatory to ensure the longevity of restorations and to avoid undesirable clinical outcomes. Light-emitting diodes (LEDs), which were introduced in the late 1990s, are becoming increasingly popular for curing of resin-based restorations. Although first-generation LEDs had power density ranged from 160 to 400 mW/cm², newer generations LED curing units had higher power intensities, ranging from approximately 500 to 1,400 mW/cm² [7], [8].

Therefore, it is of prime importance to assess the effect of using light amplified high intensity LED curing (1400 mW/cm²) on the clinical performance and marginal sealing of posterior bulk-fill resin composite restorations.

Material and Methods

Trial registration

The trial was designed following the SPIRIT 2013 Statement (Standard Protocol Items: Recommendations for Interventional Trials) and approved from Evidence-Based Dentistry Committee (EBD) – Faculty of Dentistry, Cairo University (Date of approval: 13-7-2015). The trial was registered in the Pan African Clinical Trial Registry (PACTR). The identification number for the registry was PACTR201609001768135 (Date of approval: 22-9-2016). The ethical issues of this trial were reviewed and approved by the Research Ethics Committee (REC) – Faculty of Dentistry, Cairo University (Approval no. 1579/Date of approval: 27-7-2015).

Sample size calculation

Based on a previous study [9], the secondary outcome variable is normally distributed (marginal sealing by μm), and an approximately 0.21 Cohen F effect size was expected which was the standard deviation of the population means divided by their common standard deviation. A total sample size of 38 was required. This number had been increased to a total sample size of 44 (22 per group), to adjust for using a nonparametric test. This sample would be sufficient to detect an effect size of 0.21, a power of 80%, and a significance level of 5%. The sample size was calculated using the G*Power program (University of Düsseldorf, Düsseldorf, Germany).

Participants' recruitment

During the period from 3rd December 2016 to 22nd April 2017, adult patients attending the

conservative dentistry clinic, Faculty of Dentistry – Cairo University who required posterior tooth-coloured restorations were asked to participate in this trial. Medical and dental histories were carefully assessed. Thorough extra- and intra-oral examinations of the volunteers were performed and recorded in the diagnostic chart to identify volunteers fulfilling the eligibility criteria of the trial which were determined from previous studies [10], [11], [12], [13]. The inclusion and exclusion criteria are listed in Table 1.

Table 1: Eligibility criteria of the trial

Inclusion criteria	Exclusion criteria
<u>Patient inclusion:</u>	<u>Patient exclusion:</u>
1-Patients ageing ≥ 18 years.	1-Participants with general/systemic illness.
2-Patients with a high level of oral hygiene.	2-Pregnant or lactating females.
3-Patients have at least 12 posterior teeth in occlusion.	3-Concomitant participation in another research study.
4-Patients with a good likelihood of recall availability.	4-Inability to comply with study procedures.
	5-Heavy bruxism habits.
	6-Last experience with allergic reactions against any components of the used materials.
<u>Tooth inclusion:</u>	7-Patients are receiving orthodontic treatment.
1-Permanent premolars or molars.	<u>Tooth exclusion:</u>
2-Moderate to deep compound class II cavities.	1-Teeth with clinical symptoms of pulpitis such as spontaneous pain or sensitivity to pressure.
3-Primary carious lesions.	2-Non-vital teeth.
4-Vital with the positive reaction to a cold thermal stimulus.	3-Secondary carious lesions.
5-Well-formed and fully-erupted in normal functional occlusion with the natural antagonist and adjacent teeth.	

Participants' grouping

All volunteers who gave their written informed consent for participation and fulfilled the eligibility criteria were randomly assigned using computer-generated randomisation www.random.org to either intervention (Light amplified high intensity (LAHI) LED curing) or control (Low intensity LED curing) groups

Preoperative assessments

The pulp sensibility was assessed with a cold test using (Endo-Frost, Coltène/Whaledent GmbH+ Co. KG; Langenau, Germany). After cold application on the centre of the buccal surface of the examined tooth for 10 seconds, participants were expected to answer positively to this test providing a short and transient pain response.

A digital periapical radiograph was taken before restorative procedures to assess the degree of approximation of carious lesion to a pulp, intactness of lamina dura and/or presence of any periapical radiolucency. A digital bitewing radiograph with 1:1 ratio was further taken. The carious cavities had to be at least 3 mm deep All radiographs were taken using (FONA XDC, FONA SRL; Assago, Italy) and processed by (Sordex DIGORA Optime, KaVo; Charlotte, NC, USA)

Cavity preparation

The operative field was isolated by the

application of medium consistency latex rubber dam sheet (Sanctuary Dental Dam, Sanctuary Health SDN BHD; Malaysia). Local anaesthetic agent; articaine hydrochloride 4% with 1/100 000 epinephrine (Septanest SP, Septodont; Saint-Maur des Fossés, France) was administered before cavity preparation to control patient discomfort during the restorative procedures. The adhesive cavity preparation design was employed according to the principles of minimally invasive dentistry. All cavities were prepared by the same operator (S.E.F). The cavities were prepared using #330 and #245 carbide burs (Komet®, Brasseler; Lemgo, Germany) rotating in high-speed handpiece (COMFORTdrive 200 XD, KaVo Dental; Fruehauf, Germany) with copious amounts of water coolant. Remaining soft caries -if present- were removed using sharp excavator (Maillefer, Dentsply; Switzerland). Control of the depth of the prepared floor was done by visual inspection and confirmed by probing with a sharp explorer to assess the hardness of discoloured underlying dentin. The operator measured the depth of the prepared cavities with a periodontal probe.

Restorative procedures

All restorative materials were applied according to the respective manufacturer’s instructions. The restorative materials used as well as their descriptions, compositions, manufacturers and lot numbers were listed in Table 2.

Table 2: Materials’ specifications, compositions, manufacturers and lot numbers

Material	Specification	Composition	Manufacturer	Lot number
Vococid	Etching gel	Orthophosphoric acid (34.9%).	Voco, Cuxhaven, Germany www.voco.com	132704
Futurabond M [*]	Universal Adhesive	Liquid A: methacrylic phosphorus acid ester and carbonic acid modified methacrylic ester Liquid B: water, ethanol, silicon ph = 1.4	Voco, Cuxhaven, Germany www.voco.com	1612531
X-tra fil	Bulk-fill posterior resin composite	Resins: Bis-GMA ⁽¹⁾ UDMA ⁽²⁾ TEGDMA ⁽³⁾ Bis-EMA ⁽⁴⁾ PEGDMA ⁽⁵⁾ Fillers: (Combination of non-agglomerated/nonaggregate d silica filler, zirconia filler, zirconia/silica cluster filler	Voco, Cuxhaven, Germany www.voco.com	1612219
Ionoseal	Light-curing glass ionomer cement	-Fluoro-aluminosilicate glass -An acrylic acid copolymer containing pendant methacryloxy groups, HEMA	Voco, Cuxhaven, Germany www.voco.com	1645424
Impregum™ Soft	Polyether impression material	Base: -Prepolymer-ethylene amine -Inert filler silica -Plasticiser glycol ether Catalyst: -Ester derivatives of aromatic sulphonic acid - Plasticiser phthalate -Thinner-octyl phthalate -Methyl cellulose	3M ESPE, Neuss, Germany www.3mespe.com	665796

⁽¹⁾ Bis-GMA: Bisphenol A diglycidylmethacrylate; ⁽²⁾ UDMA: Urethane dimethacrylate; ⁽³⁾ TEGDMA: Triethyleneglycoldimethacrylate; ⁽⁴⁾ Bis-EMA: Bisphenol A polyethylene glycol dietherdimethacrylate; ⁽⁵⁾ PEGDMA: Polyethyleneglycoldimethacrylate.

All cavities were restored using sectional matrix system (Palodent® Plus, DENTSPLY Caulk, Milford, DE, USA) to reestablish the interproximal contacts of the teeth. Light-curing glass ionomer cement was applied as a liner in very deep cavities (≥ 5 mm) over the deepest area in the prepared cavity and cured for 20 seconds using Dr’s light AT CL-AT24

light curing system (Good Doctors Co., Ltd., Korea) with a light intensity of 650 mW/cm². The enamel surfaces of each prepared cavity were etched with 34.9% phosphoric acid for 15 seconds. The cavity was then thoroughly rinsed with air-water spray for 15 seconds; the excessive water was then removed, using oil-free air, to avoid dehydrating the dentin. The bonding system was applied once using a micro brush in rubbing motion for 20 seconds, followed by gentle blow of oil-free air for 10 seconds then light cured for 10 seconds with a low light intensity of 650 mW/cm².

The bulk-fill resin composite was available in one semi-translucent universal shade. The material was applied as one increment into the prepared cavity then light-cured in either high-intensity mode (1400 mW/cm² for 5 seconds) or low-intensity mode (650 mW/cm² for 20 seconds). The light was directed perpendicular to the occlusal surface. The light output of the curing unit was monitored with a light meter (Curing Radiometer Model 100; Demetron Corp, USA). The occlusal adjustment was performed with carbon articulating paper (HANEL Articulating Paper, Coltene/Whaledent GmbH + Co. KG; Langenau, Germany) to establish appropriate occlusal morphology and contacts. The quality of interproximal contacts and cervical adaptation was checked using dental floss. Finishing and polishing of all restorations were done under water cooling with fine-grit diamond burs, polishing discs and strips (Sof-Lex, 3 M, St. Paul, MN, US). Abrasive strips were used (3M ESPE, St Paul, MN, USA) on the proximal surfaces.

Clinical evaluation of the restorations

Assessments of the restorations were done at baseline (one week after placement of the restoration), after 6 and 12 months using the modified US Public Health Service (USPHS) criteria [14], [15] for the following parameters; marginal discolouration, marginal adaptation, secondary caries and postoperative sensitivity. The criteria are listed in Table 3.

Table 3: Modified USPHS criteria

Criteria	Test procedure	Score		Criteria
		Accepted	Unaccepted	
Marginal discolouration	Visual inspection with a mirror at 18 inches	0		No discolouration evident
		1	2	Slight staining can be polished away Gross staining cannot be polished away
Marginal adaptation	Visual inspection with explorer and mirror, if needed	0		Continuity between the restoration and the tooth surface. The explorer tip does not engage at the interface
		1	3	The explorer tip does engage at the interface, but no gap is visible Gap at tooth/restoration interface, exposed enamel Gap at tooth/restoration interface exposed dentin
Secondary caries	Visual inspection with explorer and mirror, if needed	0		No caries present adjacent to the restoration margins
		1		Caries present adjacent to the restoration margins
Postoperative sensitivity	Ask patients	0		Not present
		1	2	Sensitive but diminishing in intensity Constant sensitivity, not diminishing in intensity

Two independent assessors (M.A.M & M.H.A) who had no preliminary information about the type of interventions evaluated the restorations.

Disagreements between examiners over assessments were solved by reexamination of the restorations, and a consensus was obtained through discussion between examiners.

Assessment of marginal sealing

For quantitative assessment of the marginal sealing, impressions were taken at the predetermined periods (baseline, after 6 and 12 months) using custom-constructed sectional trays with polyether impression material (impregnate Soft, 3M ESPE) and then poured with epoxy resin (Kemapoxy 150, CMB International; Khofo Gate Hdaek El-Ahram, Giza, Egypt) to obtain epoxy replicas. Scanning electron microscopy (SEM) Model Quanta™ 250 FEG (Field Emission Gun) attached with EDX Unit (Energy Dispersive X-ray Analyses), with accelerating voltage 30 K.V. at a magnification of 200×. The values are expressed as a percentage of the continuous margin over the total margin length for the occlusal margins [16], [17]. The marginal analyses were performed by an evaluator (H.M.T) who was blinded to the interventions.

Statistical methods

For the results of clinical evaluation of the restorations; data showed nonparametric distribution, the Chi-square test was used to compare between groups and follow-up periods. Mann Whitney test was used to compare between tested light curing modes. For the results of the assessment of marginal sealing; data showed parametric distribution, so independent t-test was used to compare between tested groups. A dependent t-test was used to compare between tested follow-up periods in each group ($\alpha = 0.05$). Statistical analysis was performed with IBM® SPSS® (SPSS Inc., IBM Corporation, NY, USA) Statistics Version 25 for Windows.

Results

In this study, a total of 44 restorations were placed in the cavities of 36 patients and re-evaluated for 6 and 12 months. Thirty patients had one restoration while four patients had two restorations and two patients had three restorations. In the first recall after 6 months, 42 restorations in 34 patients were evaluated (one restoration from each group was lost). After 12 months, another evaluation was performed, and two more restorations from the intervention group and one from the control group were lost. The study model employed was illustrated in Figure 1.

Of the 44 restorations that were placed, 45.5% were in the maxilla, 54.5% were in the mandible, 40.9% were in the premolar teeth, and 59.1% were in the molar teeth. Table 4 presents an overview of the distribution of the restorations according to the type of tooth and arch.

Table 4: Distribution and tooth locations of the restorations

	Premolars	Molars	Total
Maxillary	8	12	20
Mandibular	10	14	24
Total	18	26	44

The volunteers who participated in the study comprised 21 females (61.4%, restorations = 27) and 15 males (38.6%, restorations = 17) ranging in age from 19 to 32 years (median age was 21.6 years).

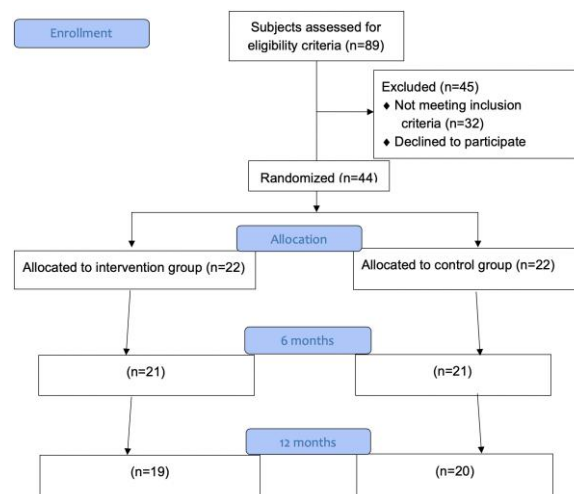


Figure 1: Flowchart of the model under study

Results of clinical evaluation of the restorations (Marginal discolouration)

At baseline, all restorations showed score 0 (100%). After 6 months, 19 restoration of the intervention group (LAHI) representing 90.5% showed score 0 while 2 restorations representing 9.5% showed score 1. However, 20 restorations of the control group (low intensity) representing 95.2% showed score 0 while 1 restoration representing 4.8% showed score 1. No statistical differences did exist between the two groups (p -value = 0.5539).

Table 5: Frequency (N) and percentage (%) for marginal discolouration

Marginal Discoloration		LAHI		Low		p-value
		N	%	N	%	
Baseline	0	22	100.0%	22	100.0%	1.00 NS
	1	0	0.0%	0	0.0%	
	2	0	0.0%	0	0.0%	
6 Months	0	19	90.5%	20	95.2%	0.5539 NS
	1	2	9.5%	1	4.8%	
	2	0	0.0%	0	0.0%	
12 Months	0	17	89.5%	19	95.0%	0.5228 NS
	1	2	10.5%	1	5.0%	
	2	0	0.0%	0	0.0%	
p-value		0.3060 NS		0.5740 NS		

NS = Non-Significant.

After 12 months, 17 restorations of the intervention group (LAHI) representing 89.5% showed score 0 while 2 restorations representing 10.5% showed score 1. However, 19 restorations of the control group (low intensity) representing 95.0% showed score 0 while 1 restoration representing 5.0% showed score 1. No statistical differences did exist between the two groups (p-value = 0.5228). The frequency (N) and percentage (%) of scores of marginal discolourations were presented in Table 5 and Figure 2.

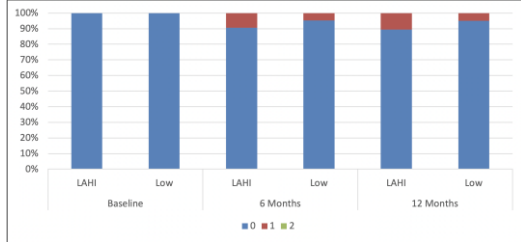


Figure 2: Stacked bar chart showing the marginal discolouration scores

Results of clinical evaluation of the restorations (Marginal adaptation)

For both intervention (LAHI) and control (low intensity) groups, all restorations (100.0%) showed score 0 at different evaluation periods.

Table 6: Frequency (N) and percentage (%) for marginal adaptation

		LAHI		Low		p-value	
		N	%	N	%		
Marginal Adaptation	Baseline	0	22	100.0%	22	100.0%	1.00 NS
		1	0	0.0%	0	0.0%	
		2	0	0.0%	0	0.0%	
	6 Months	0	21	100.0%	21	100.0%	
		1	0	0.0%	0	0.0%	
		2	0	0.0%	0	0.0%	
	12 Months	0	19	100.0%	20	100.0%	
		1	0	0.0%	0	0.0%	
		2	0	0.0%	0	0.0%	
p-value		0.8932 NS		0.9535 NS			

NS = Non-Significant.

No statistical differences did exist between the two groups at baseline (p-value = 1.00), 6 months (p-value = 1.00) and 12 months (p-value = 0.8728). The frequency (N) and percentage (%) of scores of marginal adaptations were presented in Table 6 and Figure 3.

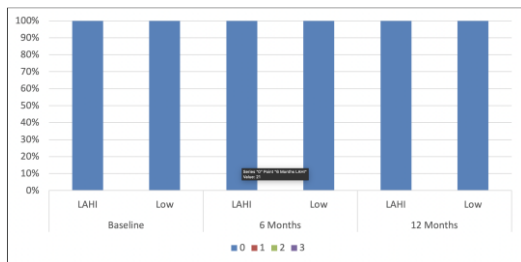


Figure 3: Stacked bar chart showing the marginal adaptation scores

Results of clinical evaluation of the restorations (Secondary caries)

For both intervention (LAHI) and control (low intensity) groups, all restorations (100.0%) showed score 0 at different evaluation periods.

Table 7: Frequency (N) and percentage (%) for secondary caries

		LAHI		Low		p-value	
		N	%	N	%		
Secondary Caries	Baseline	0	22	100.0%	22	100.0%	1.00 NS
		1	0	0.0%	0	0.0%	
	6 Months	0	21	100.0%	21	100.0%	
		1	0	0.0%	0	0.0%	
	12 Months	0	19	100.0%	20	100.0%	
		1	0	0.0%	0	0.0%	
p-value		0.8932 NS		0.9535 NS			

NS = Non-Significant.

No statistical differences did exist between the two groups at baseline (p-value = 1.00), 6 months (p-value = 1.00) and 12 months (p-value = 0.8728). The frequency (N) and percentage (%) of scores of secondary caries were presented in Table 7 and Figure 4.

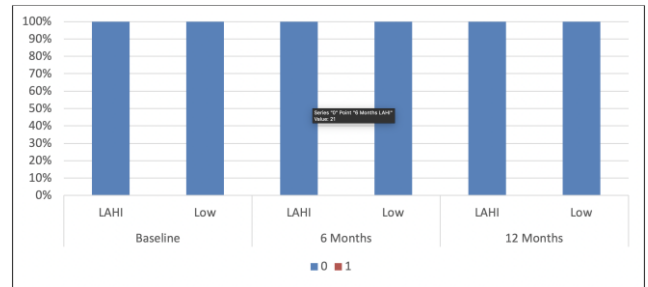


Figure 4: Stacked bar chart showing the secondary caries scores

Results of clinical evaluation of the restorations (Postoperative sensitivity)

At baseline, 19 restorations of the intervention group (LAHI) representing 86.4% showed score 0 while 3 restorations representing 13.6% showed score 1. However, 18 restorations of the control group (low intensity) representing 81.8% showed score 0 while 4 restoration showed score 1 representing 18.2%.

Table 8: Frequency (N) and percentage (%) for postoperative sensitivity

		LAHI		Low		p-value		
		N	%	N	%			
Postoperative sensitivity	Baseline	0	19	86.4%	18	81.8%	0.6837 NS	
		1	3	13.6%	4	18.2%		
		2	0	0.0%	0	0.0%		
	6 Months	0	20	100.0%	20	100.0%		1.00 NS
		1	0	0.0%	0	0.0%		
		2	0	0.0%	0	0.0%		
	12 Months	0	19	100.0%	20	100.0%		0.8728 NS
		1	0	0.0%	0	0.0%		
		2	0	0.0%	0	0.0%		
p-value		0.0569 NS		0.0187*				

Different letters within each column indicate a significant difference; NS = Non-Significant, * significant.

No statistical differences did exist between the two groups (p-value = 0.6837). After 6 and 12 months, all restorations in both groups showed score

0. The frequency (N) and percentage (%) of scores of postoperative sensitivities were presented in Table 8 and Figure 5.

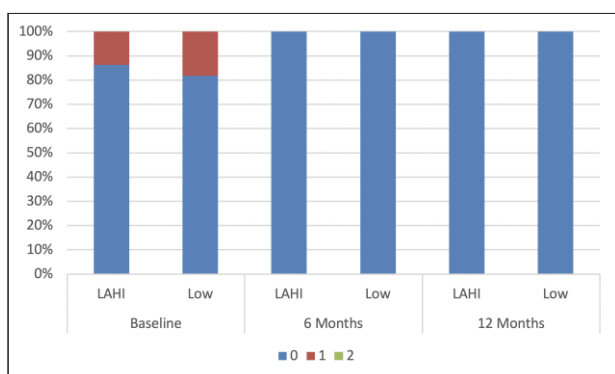


Figure 5: Stacked bar chart showing the postoperative sensitivity scores

Results of the assessment of marginal sealing

The values are expressed as a percentage of the continuous margin over the total margin length for the occlusal margins Figure 6. At baseline, the intervention group showed statistically non-significant lower mean marginal sealing values (93.98 ± 3.58 %) than the control group (94.89 ± 2.77 %) (p -value = 0.347).




Figure 6: Representative SEM 200x image of non-continuous margins (arrows)

After 6 months, the intervention group showed statistically non-significant lower mean marginal sealing values (91.44 ± 3.30 %) than the control group (92.89 ± 2.94 %) (p -value = 0.516).

Table 9: Mean and standard deviation (SD) for a percentage of marginal sealing

		LAHI		Low		p-value
		Mean	SD	Mean	SD	
% of Continuous margins	Baseline	93.98	3.58	94.89	2.77	0.347 NS
	6 Months	91.44	3.30	92.08	2.94	0.516 NS
	12 Months	87.22	3.19	89.39	2.72	0.031*

NS = Non-Significant; * = significant.

After 12 months, the intervention group showed statistically significant lower mean marginal sealing values (87.22 ± 3.19 %) than the control group (89.39 ± 2.72 %) (p -value = 0.031). The mean and standard deviation (SD) for a percentage of marginal sealing were presented in Table 9 and Figure 7.

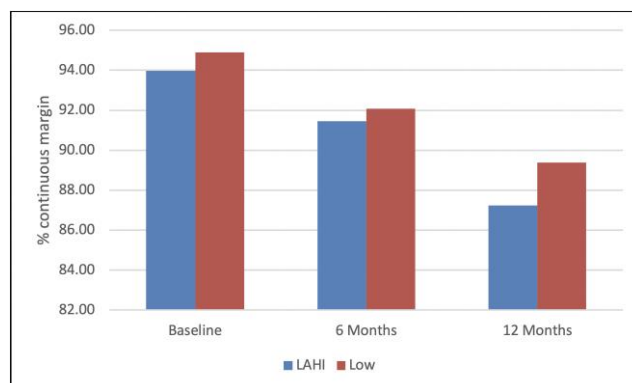


Figure 7: Bar chart showing the percentage of continuous margins for tested groups

Discussion

The use of resin composite as a restorative material for class I and II cavities has become a popular option in daily practice. However, the placement of posterior resin composite restorations has many limitations. Among these limitations are the increased time required for incremental packing in deep cavities and increased incidence of postoperative sensitivity [18]. Although several major developments in resin composite formulations and light curing units have been done to overcome these limitations, there is limited good quality in vitro research regarding the effect of light curing intensity while clinical trials are scarce apart from a few studies [19]. Long term results with some of these newly developed lights curing units are lacking and remain controversial as studies report inconsistent clinical results. There is a paucity of well-conducted clinical trials assessing the clinical effectiveness of different light curing intensities. The present prospective clinical trial was conducted to evaluate the clinical performance and marginal sealing of bulk-fill resin composite restorations using different light curing intensities.

The USPHS criteria had served well for clinical evaluation of different types of dental restorations. However, the sensitivity of these criteria in the short term and medium-term clinical evaluations (< 3-5 years) was questioned. The USPHS system lacks the sensitivity to record small early changes, therefore, in 2007 the FDI published new recommendations, which were updated in 2010, for conducting clinical studies of dental restorative materials with detailed assessment criteria [20], [21].

Despite the increasingly wide use of FDI criteria, USPHS criteria were used in this study because they are still being used in the clinical researches more than FDI criteria [22]. Only outcomes that may be related to polymerisation stress effects on restorations were chosen for clinical evaluation in the current study. These outcomes include marginal discolouration, marginal adaptation, secondary caries, and postoperative sensitivity [23], [24].

Among the 36 volunteers participating in this study, 5 participants did not complete the study. The recall rate was 95.5% at 6 months and 88.6% at 12 months, which are comparable to the rates reported in similar clinical trials [13], [25], [26]. The dropout rate (11.4%) did not increase the risk of attrition bias because the sample size was calculated allowing for losses of around 25%.

The first 6 up to 24 months are considered the critical period for evaluation of deteriorations of resin composite restorations [10]. Although the present study can be criticised that the duration of follow up (12 months) is insufficient to confirm long-term suitability of the tested light curing intensities. However, the obtained clinical findings may provide an initial indication of their clinical performance.

The potentially deleterious effects of polymerisation stress, despite the absence of clear evidence, remain clinically meaningful. Several modifications have been made in the monomer and composite organic matrix of bulk-fill resin composites to allow optimal curing efficiency. These include increased translucency [27]; increased flowability [28]; incorporation of "booster" photoinitiators and polymerisation modulators [8]. These modifications have been reported to reduce polymerisation shrinkage stresses up to 70% [29], [30], [31].

In this study, none of the evaluated restorations over 12 months showed manifestations of clinical failure. All restorations recorded clinically ideal or accepted scores (score 0 and 1). The marginal discolouration is one of the early clinical signs of failure of resin composite restorations. In the current study, the majority of the scores allocated for the marginal discolouration criteria was 0. These results were by the findings of Van Dijken and Pallesen, 2015 [13], Çolak et al., 2017 [26], Yazici et al., 2017 [32]. The slight colour changes observed after 6 and 12 months at the restoration margins were not associated with secondary caries or loss of marginal adaptation. None of the evaluated restorations showed secondary caries at different evaluation periods. This is closely related to the good marginal adaptation of the restorations.

Postoperative hypersensitivity (POH) is one of the common patients' complaints following resin composite restorations [33]. This occurs as a consequence of polymerisation shrinkage stress [34]. In the present study, only spontaneous postoperative sensitivity was measured. This is by a recent

systematic review and meta-analysis [35] that investigated the correlation between the risk and intensity of POH in posterior resin composite restorations and the adhesive strategy. In that review, POH was assessed in approximately 50% of the included studies by asking patients whether they experienced spontaneous POH during a specific time frame. In our study, 3 restorations of the intervention group and 4 of the control group showed score 1 representing 13.6% and 18.2% respectively of the restorations evaluated at baseline. These results were in line with the results obtained by (Costa et al., 2017) who found that overall risk of postoperative sensitivity was 20.3% and typically occurred within 48 hours after the restorative procedure. None of the patients involved in the study reported postoperative sensitivity at 6- and 12-months evaluation point. The lack of long-term sensitivity may be related to the application of resin-modified glass ionomer liner in deep and very deep cavities.

The use of intraoral impressions to fabricate accurate replicas is a challenge. Unless an adjacent tooth is not present, the proximal margins of the restoration can rarely be replicated. Therefore, most studies can only assess the marginal integrity of the occlusal margins of the restoration. However, this is of limited value because caries adjacent to restoration occur more frequently at proximal margins rather than occlusal margins [23]. In the current study, the restorations had marginal deficiencies already at baseline. The percentages increased over time. However, there was no correlation between increasing marginal deficiencies with the clinical performance of this restoration.

Marginal deficiencies may result from excessive polymerisation contraction stresses at tooth-restoration interface [36], [37]. The statistically significant increase in marginal deficiencies over time could also be attributed to slow hydrolysis which causes degradation of the resin/bond interface [38], [39], [40].

In conclusion, the results of the current study revealed no significant differences between the intervention and the control group over different evaluation periods regarding the clinical performance. A significant increase in the percentage of discontinuities at the tooth-restoration interface was observed over the 12-month evaluation period. Based on these findings it could be concluded that light amplified high-intensity curing units have clinical performance comparable with the conventional LED. However, the in vitro assessment of marginal sealing at the tooth-restoration interface has limited clinical relevance. Finally, further well-conducted randomised clinical trials with extended evaluation periods are highly recommended to confirm the findings obtained from the current study.

References

1. Jang J-H, Park S-H, Hwang I-N. Polymerization shrinkage and depth of cure of bulk-fill resin composites and highly filled flowable resin. *Oper. Dent.* 2014; 39(6):215-220.
2. Gupta R, Tomer, AK, Kumari A, Mullick S. Bulkfill flowable composite resins - A review. *Int J Appl Dent Sci.* 2017; 3,38-40.
3. Hamlin NJ, Bailey C, Motyka NC, Vandewalle KS. Effect of tooth-structure thickness on light attenuation and depth of cure. *Oper Dent.* 2016; 41(2):200-207. <https://doi.org/10.2341/15-067-L> PMID:26509234
4. Ilie N, Stark K. Curing behaviour of high-viscosity bulk-fill composites. *J Dent.* 2014; 42(8):977-985. <https://doi.org/10.1016/j.ident.2014.05.012> PMID:24887360
5. Reis A F, Vestphal M, Amaral RCD, Rodrigues JA, Roulet JF, Roscoe MG. Efficiency of polymerization of bulk-fill composite resins: a systematic review. *Braz oral res.* 2017; 31(spp1):37-48. <https://doi.org/10.1590/1807-3107bor-2017.vol31.0059>
6. Palin WM, Leprince JG, Hadis MA. Shining a light on high volume photocurable materials. *Dent Mater.* 2018; 34 (5):695-710. <https://doi.org/10.1016/j.dental.2018.02.009> PMID:29549967
7. Hegde V, Jadhav S, Aher GB. A clinical survey of the output intensity of 200 light curing units in dental offices across Maharashtra. *J Cons Dent.* 2009; 12(3):105-108. <https://doi.org/10.4103/0972-0707.57633> PMID:20543916 PMID:PMC2879716
8. Leprince JG, Leveque P, Nysten B, Gallez B, Jacques Devaux J, Leloup G. New insight into the "depth of cure" of dimethacrylate-based dental composites. *Dent Mater.* 2012; 28(5):512-520. <https://doi.org/10.1016/j.dental.2011.12.004> PMID:22217607
9. Poon ECM, Smales RJ, Kann H-k. Clinical evaluation of packable and conventional hybrid posterior resin-based composites Results at 3.5 years. *JADA.* 2005; 136(11):1533-1540. <https://doi.org/10.14219/jada.archive.2005.0083>
10. Celik C, Arhun N, Yamanel K. Clinical evaluation of resin-based composites in posterior restorations: 12-month results. *Eur J Dent.* 2010; 4 (1): 57-65.
11. Van Dijken JW, Pallesen U. A randomized controlled three year evaluation of "bulk-filled" posterior resin restorations based on stress decreasing resin technology. *Dent Mater.* 2014; 30(9):e245-e251. <https://doi.org/10.1016/j.dental.2014.05.028>
12. Olegário IC, Hesse D, Bönecker M, Imparato JC, Braga MM, Mendes FM, Raggio DP. Effectiveness of conventional treatment using bulk-fill composite resin versus atraumatic restorative treatments in primary and permanent dentition: a pragmatic randomized clinical trial. *BMC Oral Health.* 2015; 17(1):34-41. <https://doi.org/10.1186/s12903-016-0260-6> PMID:27485432 PMID:PMC4970260
13. Van Dijken JW, Pallesen U. Randomized 3-year clinical evaluation of Class I and II posterior resin restorations placed with a bulk-fill resin composite and a one-step self-etching adhesive. *J Adhes Dent.* 2015; 17(1):81-88.
14. Cvar JF, Ryge G. Reprint of criteria for the clinical evaluation of dental restorative materials. *Clin Oral Investig.* 2005; 9:215-232. <https://doi.org/10.1007/s00784-005-0018-z> PMID:16315023
15. Wilson MA, Cowan AJ, Randall RC, Crisp RJ, Wilson NH. A practice-based, randomized, controlled clinical trial of a new resin composite restorative: one-year results. *Oper Dent.* 2002; 27:423-429.
16. Campos EA, Ardu S, Lefever D, Jassé FF, Bortolotto T, Krejci I. Marginal adaptation of class II cavities restored with bulk-fill composites. *J Dent.* 2014; 42(5):575-581. <https://doi.org/10.1016/j.ident.2014.02.007> PMID:24561041
17. Gamarra VSS, Borges GA, Júnior LHB, Spohr AM. Marginal adaptation and microleakage of a bulk-fill composite resin photopolymerized with different techniques. *Odontology.* 2018; 106(1):56-63. <https://doi.org/10.1007/s10266-017-0294-5> PMID:28160094
18. Chesterman J, Jowett A, Gallacher A, Nixon P. Bulk-fill resin-based composite restorative materials : a review. *Br Dent J.* 2017; 222(5):337-344. <https://doi.org/10.1038/sj.bdj.2017.214> PMID:28281590
19. Van Ende A, De Munck J, Lisec DP, Van Meerbeek B. Bulk-fill composites: a review of the current literature. *J Adhes Dent.* 2017; 19:95-109.
20. Hickel R, Roulet JF, Bayne S, Heintze SD, Mjör IA, Peters M, Rousson V, Randall R, Schmalz G, Tyas M, Vanherle G. Recommendations for conducting controlled clinical studies of dental restorative materials. *Clin Oral Invest.* 2007; 11:5-33. <https://doi.org/10.1007/s00784-006-0095-7> PMID:17262225
21. Hickel R, Peschke A, Tyas M, Mjör I, Bayne S, Peters M, Hiller KA, Randall R, Vanherle G, Heintze SD. FDI World Dental Federation-Clinical criteria for the evaluation of direct and indirect restorations. Update and clinical examples. *J Adhes Dent.* 2010; 12(4):259-272. <https://doi.org/10.1007/s00784-010-0432-8>
22. Thomas M, Sophie D, Florence C, Kerstin G, Jean-Christophe M, Pierre M, Matthieu P, Brigitte G, Elisabeth D. The use of FDI criteria in clinical trials on direct dental restorations: A scoping review. *J Dent.* 2017; 68:1-9. <https://doi.org/10.1016/j.ident.2017.10.007>
23. Heintze SD. Clinical relevance of tests on bond strength, microleakage and marginal adaptation. *Dent Mater.* 2013; 29(1):59-84. <https://doi.org/10.1016/j.dental.2012.07.158> PMID:22920539
24. Ferracane, J.L., Hilton, T.J. Polymerization stress-Is it clinically meaningful? *Dent Mater.* 2016; 32(1):1-10. <https://doi.org/10.1016/j.dental.2015.06.020> PMID:26220776
25. Atabek D, Aktaş N, Sakaryalı D, Bani M. Two-year clinical performance of sonic-resin placement system in posterior restorations. *Quintessence Int.* 2017; 48(9):743-751.
26. Çolak H, Tokay U, Uzguur R, Hamidi MM, Ercan E. A prospective, randomized, double-blind clinical trial of one nano-hybrid and one high-viscosity bulk-fill composite restorative systems in class II cavities: 12 months results. *Niger J Clin Pract.* 2017; 20(7):822-831.
27. El-Damanhoury HM, Platt JA. Polymerisation shrinkage stress kinetics and related properties of bulk-fill resin composites. *Oper Dent.* 2014; 39(4):374-382. <https://doi.org/10.2341/13-017-L> PMID:23865582
28. Shah PK, Stansbury JW, Bowman CN. Application of an addition-fragmentation-chain transfer monomer in di(meth)acrylate network formation to reduce polymerisation shrinkage stress. *Polym Chem.* 2017; 8:4339-4351. <https://doi.org/10.1039/C7PY00702G> PMID:29104618 PMID:PMC5665588
29. Miletic V, Pongruksa P, De Munck J, Brooks NR, Van Meerbeek B. Curing characteristics of flowable and sculptable bulk-fill composites. *Clin Oral Invest.* 2017; 21(4):1201-1212. <https://doi.org/10.1007/s00784-016-1894-0> PMID:27383375
30. Garcia D, Yaman P, Dennison J, Neiva GF. Polymerization shrinkage and depth of cure of bulk fill flowable composite resins. *Oper Dent.* (2014); 39(4):441-448. <https://doi.org/10.2341/12-484-L>
31. Meereis CTW, Münchow EA, de Oliveira da Rosa, WL, da Silva AF, Piva E. Polymerization shrinkage stress of resin-based dental materials: a systematic review and meta- analyses of composition strategies. *J Mech Behav Biomed Mater.* 2018; 82:268-281. <https://doi.org/10.1016/j.jmbbm.2018.03.019> PMID:29627738
32. Yazici AR, Antonson SA, Kutuk ZB, Ergin E. Thirty-six-month clinical comparison of bulk fill and nanofill composite restorations. *Oper Dent.* 2017; 42(5):478-485. <https://doi.org/10.2341/16-220-C> PMID:28581919
33. Berkowitz GS, Spielman H, Matthews AG, Vena D, Craig RG, Curro FA, Thompson VP. Postoperative hypersensitivity and its relationship to preparation variables in class I resin-based composite restorations: findings from the practitioners engaged in applied research and learning (PEARL) network. Part 1. *Compend*

- Contin Educ Dent. 2013; 34(3):e44-e52.
<https://doi.org/10.12816/0010811>
34. Kruly PC, Giannini M, Pascotto RC, Tokubo LM, Suga USG, Marques ACR, Terada RSS. Meta-analysis of the clinical behavior of posterior direct resin restorations : low polymerization shrinkage resin in comparison to methacrylate composite resin. PLoS One. 2018; 13(2):1-18. <https://doi.org/10.1371/journal.pone.0191942> PMID:29466366 PMCID:PMC5842874
35. Reis A, Loguercio AD, Schroeder M, Luque-Martinez I, Masterson D, Cople Maia L. Does the adhesive strategy influence the post-operative sensitivity in adult patients with posterior resin composite restorations? A systematic review and meta-analysis. Dent Mater. 2015; 31(9):1052-1067. <https://doi.org/10.1016/j.dental.2015.06.001> PMID:26122377
36. Benetti AR, Havndrup-Pedersen C, Honoré D, Pedersen MK, Pallesen U. Bulk-fill resin composites: polymerization contraction, depth of cure, and gap formation. Oper Dent. 2015; 40(2):190-200. <https://doi.org/10.2341/13-324-L> PMID:25216940
37. Roggendorf MJ, Krämer N, Appelt A, Naumann M, Frankenberger R. Marginal quality of flowable 4-mm base vs. conventionally layered resin composite. J Dent. 2011; 9:643-647. <https://doi.org/10.1016/j.jdent.2011.07.004> PMID:21801799
38. Savadi Oskoe S, Bahari M, Jafari Navimipour E, Ajami AA, Ghiasvand N, Savadi Oskoe A. Factors affecting marginal integrity of class II bulk-fill composite resin restorations. J Dent Res Dent Clin Dent Prospects. 2017; 11(2):101-109. <https://doi.org/10.15171/joddd.2017.019> PMID:28748051 PMCID:PMC5519990
39. Jung JH, Park SH. Comparison of polymerization shrinkage, physical properties, and marginal adaptation of flowable and restorative bulk fill resin-based composites. Oper Dent. 2017; 42(4):375-386. <https://doi.org/10.2341/16-254-L> PMID:28402737
40. Peutzfeldt A, Mühlebach S, Lussi A, Flury S. Marginal gap formation in approximal "bulk fill" resin composite restorations after artificial ageing. Oper Dent. 2018; 43(2):180-189. <https://doi.org/10.2341/17-068-L> PMID:29148914