

# Steroid Induced Cataract in Langerhans Cell Histiocytosis Patient

Wayan Eka Sutyanan<sup>1</sup>, Ida Ayu Putri Widiastuti<sup>1</sup>, Christopher Ryalino<sup>2\*</sup>

<sup>1</sup>Department of Ophthalmology, Faculty of Medicine, Udayana University, Bali, Indonesia; <sup>2</sup>Department of Anesthesiology and Intensive Care, Faculty of Medicine, Udayana University, Bali, Indonesia

## Abstract

**Citation:** Sutyanan WE, Widiastuti IAP, Ryalino C. Steroid Induced Cataract in Langerhans Cell Histiocytosis Patient. Open Access Maced J Med Sci. <https://doi.org/10.3889/oamjms.2019.233>

**Keywords:** Steroid; Cataract; Histiocytosis

**\*Correspondence:** Christopher Ryalino, Department of Anesthesiology and Intensive Care, Faculty of Medicine, Udayana University, Bali, Indonesia. E-mail: [ryalino@gmail.com](mailto:ryalino@gmail.com)

**Received:** 04-Feb-2019; **Revised:** 21-Mar-2019; **Accepted:** 22-Mar-2019; **Online first:** 28-Mar-2019

**Copyright:** © 2019 Wayan Eka Sutyanan, Ida Ayu Putri Widiastuti, Christopher Ryalino. This is an open-access article distributed under the terms of the Creative Commons Attribution-NonCommercial 4.0 International License (CC BY-NC 4.0)

**Funding:** This research did not receive any financial support

**Competing Interests:** The authors have declared that no competing interests exist

**BACKGROUND:** Cataract is an opacification of the lens. Pediatric cataracts can be congenital or acquired. Acquired cataract including the one caused by corticosteroid used. It occurred as bilateral posterior subcapsular cataracts and tended to be progressive. Treatment of choice is lens extraction with or without intraocular lens (IOL).

**CASE PRESENTATION:** We present a case of posterior subcapsular cataract that occurs in a patient with Langerhans cell histiocytosis that was using corticosteroid therapy.

**CONCLUSION:** The routine ophthalmologic examination should be performed in children who received treatment with corticosteroids in the long term so that with early detection it can be given early treatment.

## Introduction

Cataract is the opacification of the lens that can occur as a congenital or acquired disease. Cataracts can affect all ages, including children. Cataracts in children can be a stand-alone disease or as part of a systemic disorder, congenital or acquired, unilateral or bilateral. Epidemiological studies and clinical observations have successfully identified the risk factors responsible for the formation of cataracts including exposure to ultraviolet light, myopia, diabetes and long-term use of corticosteroids. Pathophysiology of cataract formation in corticosteroids usage hasn't certainly known yet, but several mechanisms that alleged to be responsible described in some theories including osmotic theory, the oxidative theory, modification of proteins, and metabolic disorders [1].

Cataracts that are formed in the long-term use

of corticosteroids are usually formed as posterior subcapsular cataracts, which mean the opacity formed on the polar part of the posterior cortex of the posterior lens capsule [1], [2], [3]. This type of cataract usually found on adults rather than children occurs bilaterally, and progressively. Symptoms often complained including reduced visual acuity and disturbingly glary vision [4].

There are 1.5 million children with corrected visual acuity below 20/40 in the world, and 1 million of these children are living in Asia. The prevalence of children with cataracts recorded is 1-15 cases out of 10,000 children in developing countries [2]. It is estimated that 200,000 children are blind due to bilateral cataract [5], [6]. Cataracts in children may cause visual impairment. The number of visual impairments caused by cataracts is more than any other preventable cause of blindness. Children with cataract that affect visual acuity but not treated properly could face a lifetime of blindness, with a

miserable quality of life and socio-economic, they would be a burden for themselves, family, and the environment [7].

Currently, the most effective cataract therapy for children is lens removal surgery. Cataract surgery in children is a complex procedure. The eye's anatomy and physiology aspects in children that are still growing are quite different than in adults. Most times it would also take a long process of post-surgery follow-ups. The timing of the surgery, IOL measurement and installation, surgical techniques, and post-operative care are some things that should be considered carefully [6].

Langerhans cell histiocytosis (LCH) is a proliferation of Langerhans cells, which are the member of the dendritic cell of bone marrow and characterised by abnormal accumulation of dendritic cells, lymphocytes, macrophages and eosinophils in various organ systems [8], [9]. The aetiology and pathogenesis of LCH have yet to be known clearly. Several hypotheses explained the involvement of somatic mutations, chromosomal instability, human herpesvirus-6 (HHV6) infection, dysregulation of cytokine and apoptosis [10], [11].

The prevalence of LCH is 1 in 50,000 children with incidents of 1.08 in 200,000 children per year. LCH can occur in all age groups, but about 50% of LCH cases were diagnosed at the age of 1-15 years and the highest incidence rate found are in the age group of 1-3 years [12], [13], [14]. The clinical manifestations of LCH may involve various organ systems with the most common area affected is skin and bones. The diagnosis is confirmed with histopathology, immunohistochemistry and electron microscopy examination [13].

LCH therapy is implemented based on the course of disease and organ system involvement. Patients with localised skin lesions may not require special treatment with spontaneous resolution in some cases reported. Systemic therapy is given to patients with multi-systemic or extensive LCH, with choices such as vinblastine 6 mg/m<sup>2</sup> intravenous every week for 24 weeks and methylprednisolone 30 mg/kg/day administered intravenously for three days followed by a lowered dose. Another option of regimen includes etoposide 150 mg/m<sup>2</sup>/day intravenously for three days that must be repeated every 3 weeks until a total of 8 cycles of 24 weeks is reached, combined with methylprednisolone 30 mg/kg/day administered intravenously for three days followed by lowered dose.

The evaluation of the treatment will be carried out on the sixth week, in patients that do not respond to the therapy performed, cytostatic replacement is used, with the combination of mercaptopurine and prednisone or methotrexate and prednisone. The prognosis of patients with LCH are quite varied, depending on the response to initial therapy, age at onset of the disease, organs involved, and organ dysfunction involved [8], [9], [10], [13], [14].

We are presenting a case of posterior subcapsular cataract that occurs in a patient with Langerhans cell histiocytosis that was under a corticosteroid therapy.

## Case Illustration

A 7 years-old boy came to the ophthalmology clinic complaining of progressive blurred vision on both eyes since three months ago. The condition was disturbing the patient's activity, especially when he was at school. The patient also complained about glary feeling that felt annoying when he was doing activity outdoors. His birth history and family history were unremarkable.

The patient was diagnosed with LCH since he was 7 months-old. The disease was preceded by a lump in the bottom of his right eye. He was then brought to a hospital where he underwent biopsy examination. Another lump grew on the bottom of his left eye two months later. A paediatrician performed a biopsy of the lump, and he was later diagnosed with juvenile xanthogranuloma. He received chemotherapy for one year but then lumps reappeared on his neck, arms, and legs. Another biopsy revealed LCH, and he was scheduled for chemotherapy.

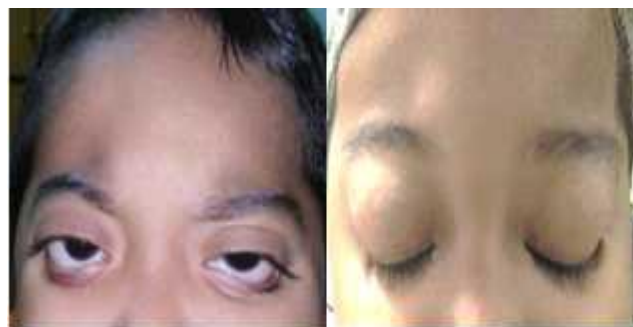

Figure 1: Physical finding when the patient first came to the ophthalmology clinic

Eye examination (Figure 1) revealed the visual acuity is of the right eye (OD) was 4/60 which was unimproved with a pinhole vision. His inferior eyelid retracted because of the biopsy scar. The conjunctiva, anterior chamber, cornea, and iris exams were unremarkable. The lens appeared cloudy at the posterior subcapsular, with a clear vitreous, positive fundus reflex, but difficult to observe the details (Figure 2).

Left eye (OS) examinations showed visual acuity of 1/60 which was also unimproved with pinhole vision. The inferior eyelid was also retracted due to biopsy scar. The conjunctiva, anterior chamber, cornea, and iris exams were unremarkable. The lens appeared cloudy at the posterior subcapsular, with a

clear vitreous, positive fundus reflex, but difficult to observe the details.

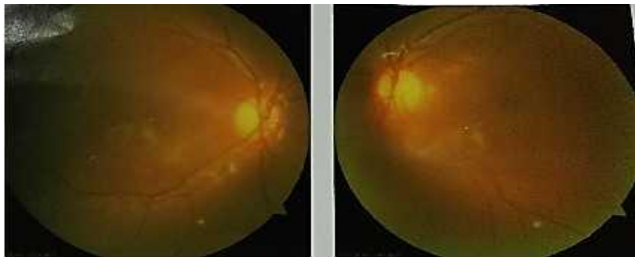


Figure 2: Fundus exam findings

Both eyes could move normally to all directions. Eye pressure was 14,00 mmHg on the right eye and 12.00 mm Hg on the left eye. Exophthalmometer examination using Hertel found a base of 78 with values on the right eye and the left eye were 19-20 mm. Ultrasound examination was performed to determine the length of axial length, which were obtained that the axial length on the right eye and the left eye 23.22 mm and 23.59 mm (Figure 3).

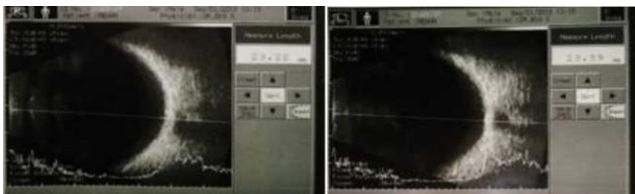

Figure 3: Ultrasound findings

The patient was diagnosed with right and left eye complicated cataract caused by steroid usage. Biometric inspection indicates the size of the lens for the right eye and the left eye were 15.00 and 14.50 diopters, respectively.

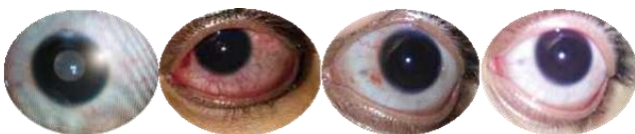


Figure 4: Left eye photos. From left to right: during the surgery, one day after the surgery, one week after the surgery, and one month after the surgery

He underwent surgery for the lens extraction and IOL mounting on the left eye. One day after surgery the left eye showed improved visual acuity of 6/30 with unimproved with a pinhole. Eyelid oedema, conjunctival vascular injection (CVI), pericorneal vascular injection (PCVI), and subconjunctival bleeding (SCB) were present on the left eye. IOL was installed properly in the central, with clear vitreous and positive fundus reflex. He was discharged from the hospital with antibiotic and Lpred eye drops.

Two months later, he underwent a second surgery for cataract extraction and IOL mounting of the right eye. One day after the surgery, examination on the right eye revealed visual acuity was 6/15 (unimproved by pinhole), with the presence of oedema of the eyelid, CVI, PCVI, and SCB. IOL was installed properly in the central, with clear vitreous and positive fundus reflex. At this point, the OS visual acuity was 6/10 with an unimproved with a pinhole. Eye pressure was 12.00 mmHg for both eyes. He was then discharged from the hospital with antibiotic and Lpred eye drops.

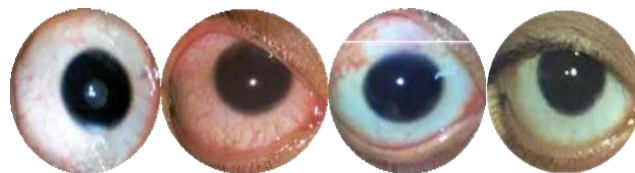


Figure 5: Right eye photos. From left to right: during the surgery, one day after the surgery, one week after the surgery, and one month after the surgery

One month later, eye examination showed visual acuity on the right eye with was 6/10 (improved to 6/7.5 with pinhole), that was corrected with the spherical lens of -1.00 to 6/7.5. The left eye's visual acuity was 6/7.5 (unimproved with pinhole). He was discharged with the provision of eyeglasses with best correction lens.

## Discussion

Cataracts are opacities of the lens. Lens opacities in children can occur congenitally or acquired, and one of the reasons is the use of corticosteroids in the long term. Cataracts in children may be formed unilaterally or bilaterally, stand-alone or as part of a systemic condition, and can be either stable or progressive.

The patient presented in this case came with a sharp decrease in vision in both eyes for three months, which worsen over time. This proved to be very disturbing, especially during the learning process at school. He had a history of suffering from LCH and received chemotherapy for 4 years using a protocol where it included the use of methylprednisolone and prednisone. Patients' family had no history of cataracts in childhood. Ophthalmology examination on the patient showed cloudiness in the polar part of the posterior capsule in both eyes and was advancing rapidly, with a decrease in visual acuity continued to deteriorate in a matter of months.

While the treatment of cataracts in children includes surgery, some important things must be considered beforehand. The younger the child, the sooner surgery is required to prevent amblyopia due

to visual deprivation. In older children, surgery is performed when the vision of children is less than or equal to 20/40. The second thing to consider is the installation of IOL depending on the age of the patient and lateralisation of the cataract, where the IOL implant should be performed on children aged 1-2 years or more, because of the magnitude of change and refractive errors are still possible [6].

Postoperative management with medication of steroid and antibiotics are important, whereas, in children who underwent IOL installation, steroids administration should be more aggressive [6], [7], [8]. This patient received antibiotics, and steroid eye dropped immediately after surgery and continued until 6 weeks postoperatively.

Treatment and prevention of amblyopia in children with cataract should be done immediately after the surgery. Patients with bilateral aphakia should be given corrective lenses a week after surgery. In patients who are older and underwent IOL replacement directly after cataract surgery, refractive correction should be done one month postoperatively [5], [6].

In conclusion, cataracts are opacification of the lens that can occur in children, one of which can be caused by the use of corticosteroids in the long term. Diagnosis and appropriate treatment can save the patient from complications that may occur. Long-term follow-up is necessary given the ongoing development in children. Chemotherapy addition in children to provide the desired effect is not uncommon but also can result in adverse side effects. Routine examination in children who received chemotherapy should be done to detect early adverse effects that may occur. In this case, the routine ophthalmologic examination should be performed in children who received treatment with corticosteroids in the long term so that with early detection it can be given early treatment.

## Acknowledgement

The patient's parent provided us with a written consent for possible future publication regarding this case.

## References

1. Jobling AI, Augusteyn RC. What causes steroid cataracts? A review of steroid-induced posterior subcapsular cataracts. *Clinical and Experimental Optometry*. 2002; 85(2):61-75. <https://doi.org/10.1111/j.1444-0938.2002.tb03011.x>
2. Vasavada AR, Mamidipudi PR, Sharma PS. Morphology of and visual performance with posterior subcapsular cataract. *J Cataract Refract Surg*. 2004; 30(10):2097-104. <https://doi.org/10.1016/j.jcrs.2004.02.076> PMID:15474821
3. Čerim A, Dizdarević A, Pojskić B. Occurrence and morphological characteristics of cataracts in patients treated with general steroid therapy at Cantonal Hospital Zenica. *Med Glas (Zenica)*. 2014; 11(2):295-9.
4. Amaya L, Taylor D, Russell-Eggitt I, Nischal KK, Lengyel D. The Morphology and Natural History of Childhood Cataracts. *Survey of Ophthalmology*. 2003; 48(2):125-144. [https://doi.org/10.1016/S0039-6257\(02\)00462-9](https://doi.org/10.1016/S0039-6257(02)00462-9)
5. Lafolette S. Pediatric Cataract. *Survey of Ophthalmology*. 2000; 45(3 Suppl 1):S150-S168.
6. Ram J. Pediatric cataract. *Indian J Med Res*. 2018; 147(6):621. [https://doi.org/10.4103/ijmr.IJMR\\_58\\_17](https://doi.org/10.4103/ijmr.IJMR_58_17) PMID:PMC6118152
7. Abraham AG, Condon MG, West-Gower E. The new epidemiology of cataract. *Ophthalmol Clin North Am*. 2006; 19(4):415-25. PMID:17067897
8. Donadieu J, Chalard F, Jeziorski E. 2012. Medical management of langerhans cell histiocytosis from diagnosis to treatment. *Expert Opin Pharmacother*. 2012; 13(9):1309-22. <https://doi.org/10.1517/14656566.2012.688028> PMID:22578036
9. Herwig MC, Wojno T, Zhang Q, Grossniklaus HE. Langerhans cell histiocytosis of the orbit: five clinicopathologic cases and review of the literature. *Surv Ophthalmol*. 2013; 58(4):330-40. <https://doi.org/10.1016/j.survophthal.2012.09.004> PMID:23246282 PMID:PMC4100607
10. Jezierska M, Stefanowicz J, Romanowicz G, Kosiak W, Lange M. Langerhans cell histiocytosis in children - a disease with many faces. Recent advances in pathogenesis, diagnostic examinations and treatment. *Postepy Dermatol Alergol*. 2018; 35(1):6-17. <https://doi.org/10.5114/pdia.2017.67095> PMID:29599667 PMID:PMC5872238
11. Nandhini T. Langerhan cell histiocytosis-a review. *Journal of Pharmaceutical Sciences and Research*. 2015; 7:586-589.
12. Kumar YP, Agrawal J, Mohanlakshmi J, Kumar PS. Langerhans cell histiocytosis revisited: Case report with review. *Contemp Clin Dent*. 2015; 6(3):432-6. <https://doi.org/10.4103/0976-237X.161912> PMID:26321851 PMID:PMC4550003
13. Lanzkowsky P. *Manual of Pediatric Hematology and Oncology*. Amsterdam: Elsevier/Academic Press; 2011.
14. Saletta F, Seng MS, Lau LM. Advances in paediatric cancer treatment. *Transl Pediatr*. 2014; 3(2):156-82. PMID:26835334 PMID:PMC4729100