

Arthroscopic Assisted Reduction and Internal Fixation of Tibial Plateau Fractures

Sherif Hamdy Mohamed Zawam^{*}, Ahmed Mahmoud Gad

Faculty of Medicine, Cairo University, Cairo, Egypt

Abstract

Citation: Zawam SHM, Gad AM. Arthroscopic Assisted Reduction and Internal Fixation of Tibial Plateau Fractures. *Open Access Maced J Med Sci*. <https://doi.org/10.3889/oamjms.2019.248>

Keywords: Arthroscopic assisted; Tibial plateau fractures; ORIF; Schatzker

***Correspondence:** Sherif Hamdy Mohamed Zawam. Faculty of Medicine, Cairo University, Cairo, Egypt. E-mail: herifzawam@gmail.com

Received: 07-Feb-2019; **Revised:** 25-Mar-2019; **Accepted:** 26-Mar-2019; **Online first:** 14-Apr-2019

Copyright: © 2019 Sherif Hamdy Mohamed Zawam, Ahmed Mahmoud Gad. This is an open-access article distributed under the terms of the Creative Commons Attribution-NonCommercial 4.0 International License (CC BY-NC 4.0)

Funding: This research did not receive any financial support

Competing Interests: The authors have declared that no competing interests exist

BACKGROUND: Tibial plateau fractures present an important entity in orthopaedic fractures. Arthroscopic-assisted reduction and internal fixation is a good alternative to ORIF as it has the advantage of direct visualisation of the articular surface of the plateau, direct assessment of the reduction of the articular surface, and managing any associated intra-articular pathology.

AIM: Our study aim is to determine the results of arthroscopic assisted reduction and internal fixation of tibial plateau fractures.

METHODS: This study involved 25 patients with tibial plateau fractures presenting to the emergency department of Cairo University Hospitals between the periods of November 2016 and May 2017. The patients were followed up for an average of 14 months (11-18 months). According to Schatzker's classification, five patients had type I, eleven had type II, and nine patients had type III fractures.

RESULTS: The average time to full union in Schatzker type I was 9.1 weeks, in type II was 10.2 weeks, and in type III it was 9.4. The mean clinical Rasmussen score among the 25 patients was 26 (range, 24-30). A group of 19 patients (76%) had excellent results, (4 type I, 8 types II, and 7 types III) 6 patients (24 %) had good results (1 type I, 3 types II, 2 types III). Radiologic results were excellent in (14 cases) 56.0% and good results (11 cases) 44%.

CONCLUSION: Arthroscopic assisted reduction and fixation of tibial plateau fractures have the advantages of checking the adequacy of reduction, avoiding the need for detachment of the meniscus, and allowing for accurate diagnosis and management of associated knee injuries. Therefore, we recommend that arthroscopic assisted reduction and fixation of tibial plateau fractures should be used more often.

Introduction

Tibial plateau fractures present an important entity in orthopaedic fractures. They may be associated with other knee injuries such as meniscal tears, cruciate ligaments injuries and collateral ligaments damage [1], [2].

The role of conservative treatment is limited in the management of fractures of the tibial plateau. Open reduction and internal fixation (ORIF) is the standard treatment option. Several complications may arise from ORIF, such as wound complications and infection [3].

Arthroscopic-assisted reduction, and internal fixation is a good alternative to ORIF as it has the advantage of direct visualisation of the articular surface of the plateau, direct assessment of the

reduction of the articular surface, and managing any associated intra-articular pathology. Several studies have adopted arthroscopic assisted reduction of tibial plateau fractures with good results [4].

Our study aim is to determine the results of arthroscopic assisted reduction and internal fixation of tibial plateau fractures.

Methods

This study involved 25 patients with tibial plateau fractures presenting to Kasr El Ainy Hospitals between the period of November 2016 and May 2017. The patients were followed up for an average of 14 months (11-18 months). Twelve patients sustained

their injuries from road traffic accidents (RTA), eight patients fell from a height, and five patients had sports injuries.

There were 16 males (64%) and 9 females (36%). The age ranged from 19 to 55 years with a mean age of 38.8 years. According to Schatzker's classification, five patients had type I, eleven had type II, and nine patients had type III fractures [5].

Full medical history was obtained from the patients. Then, a detailed physical examination was performed to assess the local skin condition and the neurovascular status of the affected limb. Plain x-rays and CT scan were ordered to assess the type of the fracture, the degree of depression, joint widening, and plan the way of management. Also, the patients were checked for any associated fractures. Operative indications included step-off of the articular surface more than 2-3 mm, widening of the tibial condyles more than 5 mm or varus/valgus instability more than 10 degrees [6].

Patients with open physis, open or pathological fractures were excluded. The patients were put in a back slab initially to stabilise the fracture site and allow the soft tissues to heal. The patients were admitted and given "low molecular weight heparin" to protect them against deep venous thrombosis. When oedema and the skin condition improve, the patients were prepared for surgery.

The procedure was performed under spinal anaesthesia putting the patients in supine position. Pre-operatively, the prophylactic antibiotic was given before tourniquet inflation. Knee ligaments were examined under anaesthesia. The standard anterolateral portal was used for viewing, and the anteromedial portal was used for manipulation. Evacuation of the organised intra-articular hematoma was done first to improve the visibility (Figure 1).

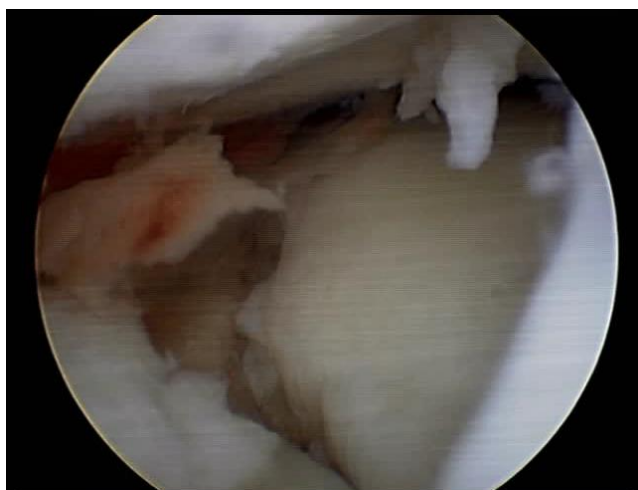


Figure 1: The shape of the fracture before reduction (after removal of the hematoma)

Then, an examination of the intraarticular structures was performed. A "figure of 4 positions"

was used during examination and reduction of lateral plateau fractures as by this we open the joint space and improve the visualisation.

Prolene suture loops or retractors were used to retract the lateral meniscus to expose the lateral tibial plateau and the fracture site. This avoids the detachment of the meniscus that occurs with an open approach.

In Schatzker Type I Fractures, K-wires (Kirschner wires) were used to manipulate the split fragment to be used as joy-stick for reduction. When the fracture was reduced, K-wires for cannulated screws were used to temporarily fix the fracture, until the cannulated screws were inserted. Any other associated pathology was dealt with accordingly.

The reduction of Schatzker Type II Fractures was more difficult than Type I or typed III, as the fracture pattern consists of depressed parts and split parts, especially if the fracture was comminuted.

First, the fracture pattern was studied well using the arthroscopy to identify the number of fragments, the degree of depression, split and depressed parts. Then A.C.L guide was used over the depressed part to pass a guide wire from the medial or lateral side of the knee.

The position of the wire was checked using the arthroscope and the image intensifier. After that, a window was created around the K-wire using the mosaicplasty set (Figure 2).

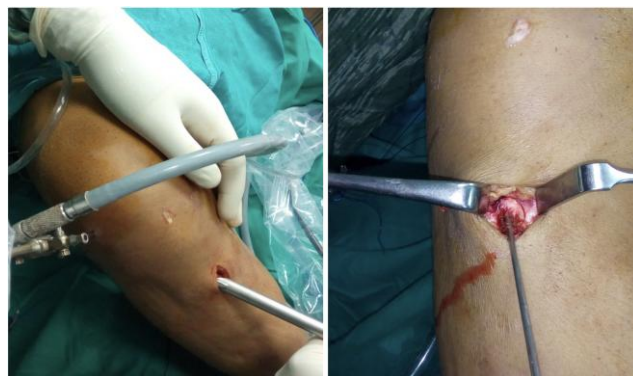

Figure 2: the window was created around the K-wire using the mosaicplasty set

Then, using an impactor, and through the created cortical window, the depressed parts were gently elevated until they reach the level of the surrounding normal plateau. Intra-articular fine-tuning was done to adjust the level of the depressed part. The split parts were manipulated using K-wires.

Then, temporary stabilisation of the fracture was achieved using subchondral K-wires until iliac crest graft was impacted to fill the defects. The accuracy of the reduction was checked both arthroscopically and using the image intensifier (Figure 3).

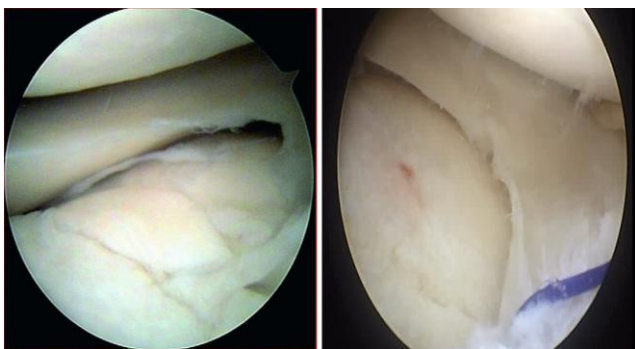


Figure 3: The shape of the articular surface after reduction in 2 patients

Final fixation of the fracture was done in 2 ways. Cannulated screws were used in cases with no comminution or when the fracture pattern was relatively stable after reduction (Figure 4).

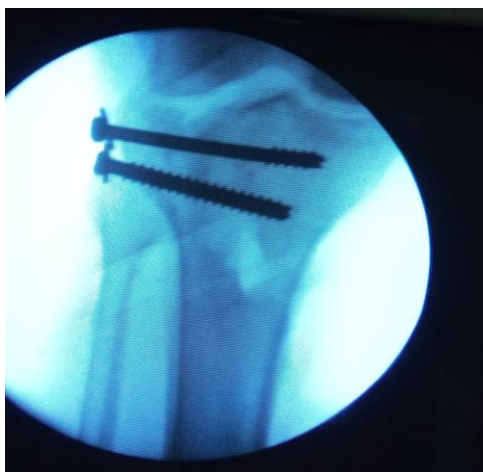

Figure 4: Intraoperative photo from the image intensifier after fracture reduction and fixation by 2 screws

While, in the presence of a comminuted articular surface, or unstable fracture pattern, plate and screws were used for fixation as this added more stability (Figure 5). They were inserted using minimal skin incisions. Iliac crest graft was used in 21 cases.



Figure 5: Intraoperative photo from the image intensifier after fracture reduction and fixation by plate and screws

The way of management of Schatzker type III fractures was similar to that of type II in many ways, but it was easier. As in Schatzker type III fractures, there is an only central depression in the lateral plateau. The A.C.L guide was used, the depressed fragment was elevated, iliac crest bone graft was used, and lastly, the fracture was fixed with two cannulated screws with washers.

The patients received postoperative antibiotic prophylaxis for 4 days. Oral anticoagulation was given and continued until partial weight bearing was allowed. The patients were followed up weekly to check the wound until sutures were removed after 2 weeks. Then, the patients were followed up clinically and radiologically in each monthly visit. Partial weight bearing was allowed after an average of eight weeks. Full weight bearing was allowed after the full union was observed radiologically and clinically.

Results

The patients were followed up for an average of 14 months (11-18 months). The average time to full union in Schatzker type I was 9.1 weeks, in type II it was 10.2 weeks, and in type III it was 9.4.

This was checked both clinically and radiologically. Clinically, the patient was examined for the absence of tenderness at the fracture site and during weight bearing. Radiologically, the x-rays were checked for the continuity of the cortical bone and absence of defects in the fracture site (Figure 6).

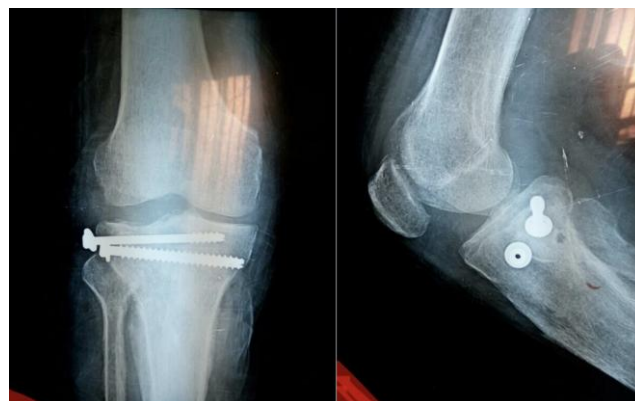

Figure 6: Xrays (anteroposterior and lateral views) after 1 year

The mean clinical Rasmussen score among the 25 patients was 26 (range, 24-30). Nineteen patients (76%) had excellent results, (4 type I, 8 types II, and 7 types III), and 6 patients (24 %) had good results (1 type I, 3 types II, 2 types III). Radiologic results were excellent in (14 cases) 56 % and good in (11 cases) 44%.

Regarding the associated conditions, there

were 8 patients with lateral meniscus lesions, 2 patients with medial meniscus lesions, and 2 patients with partial A.C.L rupture. The torn menisci were sutured using outside in or all-inside techniques, in case of meniscal-capsular separation. In the case of central tears, partial meniscectomy was done. The partial A.C.L injuries were treated conservatively.

Regarding the complications, one patient had a superficial infection, which was treated by antibiotics and repeated dressings. Another case was complicated by articular surface depression (4 mm) due to early weight bearing against the instructions and the patient refused surgical revision.

A group of 20 patients (80%) were satisfied and returned to their previous work before the injury, three reported mild satisfaction, and 2 were dissatisfied.

Discussion

Fractures of the tibial plateau represent 1% of all types of fractures. They should be properly managed. Otherwise, several complications may occur. They may be associated with meniscal tears, cruciate ligaments injuries or collateral ligaments damage [7].

Conservative treatment has a limited role in treating fractures of the tibial plateau. Open reduction and internal fixation is the standard treatment option. Several complications may arise from ORIF, such as wound complications and infection. Ideal management should aim at anatomic reduction and rigid internal fixation. This will allow early mobilisation preventing joint stiffness [8].

Minimally invasive methods include arthroscopic assisted reduction and internal fixation avoiding opening the fracture site, large skin incisions and detachment of the menisci [9].

Fowble et al., performed a retrospective study comparing the results of arthroscopic assisted reduction and fixation to the standard open approach. The group treated with the arthroscopic technique showed superior results compared to the open group [10].

Dall'Oca et al., compared the results of patients treated with arthroscopic assisted reduction and internal fixation to those of patients treated with the open method. The study was conducted on one hundred patients. They were followed up for seventy-three months on average. There were no differences between the results of both groups in patients with Schatzker type I fractures. However, in type II, III and IV the arthroscopic group showed better results when compared to the open group. In fractures with type V

and VI classification, the results of both groups were poor, but the arthroscopic group had fewer infection rates [11].

Our study involved 25 patients with tibial plateau fractures presenting to Kasr El Ainy Hospitals between the period of November 2016 and May 2017.

In our study, we used the arthroscope first to assess intra-articular structures, examine for any associated pathology and study the fracture pattern and components. Using the A.C.L guide, a wire was inserted into the fracture site. A cortical window was created around the wire. Then using an impactor, the depressed segment was elevated and carefully reduced. Iliac crest graft was used and impacted under the fracture site.

Split fragments could be manipulated and reduced using k-wires as Joysticks. The reduction was checked fluoroscopically and arthroscopically and fixed using cannulated screws or plates and screws. This combination between the arthroscope and the image intensifier allows the more precise anatomical reduction, as the fracture was visualised from inside and outside. This minimises the size of the incision and the surgical dissection. Also, this avoids the detachment of the meniscus that occurs with the open approach as prolene suture loops or retractors were used to retract the lateral meniscus to expose the lateral tibial plateau and the fracture site [12].

The average time to full union in Schatzker type I was 9.1 weeks, in type II was 10.2 weeks, and in type III it was 9.4. According to the clinical Rasmussen score, nineteen patients (76%) had excellent results, (4 type I, 8 types II, and 7 types III), and 6 patients (24%) had good results (1 type I, 3 types II, 2 types III). Radiologic results were excellent in 14 cases (56 %) and good in 11 cases (44%). There were no patients who had fair or poor results.

These were considered high compared to the other studies that adopted similar techniques. This may be because our study was conducted only on Schatzker Type I, II, and III only.

Regarding the complications, in the study conducted by Pogliacomini F, et al., two patients (11%) were complicated by joint depression. In Roerdink, et al., 9 patients (30%) was complicated by secondary displacement, but without affecting the outcome. Also, his study was conducted only on patients more than 55 years old. In our study, one patient had a superficial infection, which was treated by antibiotics and repeated dressings. Another case was complicated by articular surface depression (4 mm) due to early weight bearing against the instructions and the patient refused surgical revision.

Our average follow up period was 14 months which is acceptable in comparison to the other studies, as most of the complications appear on the first three to six months. The following table compares our results to other similar studies (Table 1).

Table 1: Comparison between our results and other similar studies

	Pogliacomini et al. [13]	Roerdink et al. [14]	Our study
Number of patients	18 patients	30 patients	25 patients
Average follow up period	12 months	36 months	14 months
Schatzker classification	I-IV	I-VI	I-III
Mean Clinical (Rasmussen Score)	45% excellent 37% good 12% fair 6% poor	40% excellent, 40% good 10% fair 10% poor	76% excellent 24 % good
Mean Radiographic (Rasmussen Score)	29 % excellent 39% good 32% fair 16% were poor	13.3% excellent, 33.3% good, 33.3% were fair 20% poor	56 % excellent 44% good
Post-operative Complications	Two patients (11%)	Nine patients (30%)	Two cases (8%)

In conclusion, arthroscopic assisted reduction and fixation of tibial plateau fractures is not a commonly used technique in management in spite of its benefits. It is not a surgically demanding technique; it requires basic arthroscopic surgical skills and an average learning curve.

Its main advantage is checking the adequacy of reduction, avoiding the need for detachment of the meniscus, and allows for accurate diagnosis and management of associated knee injuries. Therefore, we recommend that Arthroscopic assisted reduction and fixation of tibial plateau fractures should be used more often.

Author Contribution

Sherif Hamdy Mohamed Zawam: literature search, data collection and performing the operative technique, data analysis. Ahmed Mahmoud Gad: Revision, Editing.

References

1. Jennings JE. Arthroscopic management of tibial plateau fractures. *Arthroscopy: The Journal of Arthroscopic & Related Surgery*. 1985; 1(3):160-8. [https://doi.org/10.1016/S0749-8063\(85\)80003-7](https://doi.org/10.1016/S0749-8063(85)80003-7)

2. Caspari RB, Hutton PM, Whipple TL, Meyers JF. The role of arthroscopy in the management of tibial plateau fractures. *Arthroscopy: The Journal of Arthroscopic & Related Surgery*. 1985; 1(2):76-82. [https://doi.org/10.1016/S0749-8063\(85\)80035-9](https://doi.org/10.1016/S0749-8063(85)80035-9)
3. Tilkeridis K, Kiziridis G, Tottas S, Kougioumtzis I, Riziotis G. Arthroscopically Assisted Fixation of the Tibial Plateau Fractures. *J Bone Res*. 2018; 6(188):2. <https://doi.org/10.4172/2572-4916.1000188>
4. Chan YS, Yuan LJ, Hung SS, Wang CJ, Yu SW, Chen CY, Chao EK, Lee MS. Arthroscopic-assisted reduction with bilateral buttress plate fixation of complex tibial plateau fractures. *Arthroscopy: The Journal of Arthroscopic & Related Surgery*. 2003; 19(9):974-84. <https://doi.org/10.1016/j.arthro.2003.09.038> PMID:14608317
5. Burdin G. Arthroscopic management of tibial plateau fractures: surgical technique. *Orthopaedics & Traumatology: Surgery & Research*. 2013; 99(1):S208-18. <https://doi.org/10.1016/j.otsr.2012.11.011> PMID:23347755
6. Honkonen S. Indications for surgical treatment of tibia condylar fractures. *Clin Orthop*. 1994; 302:199-205. PMID:8168301
7. Hohl M. Part I: Fractures of the proximal tibia and fibula. In: Rockwood C, Green D, Bucholz R, eds. *Rockwood and Green's Fractures in Adults*. Vol 2. 3rd ed. Philadelphia, PA: JB Lippincott, 1992:1725-1757.
8. Kampa J, Dunlay R, Sikka R, Swiontkowski M. Arthroscopic-assisted fixation of tibial plateau fractures: patient-reported postoperative activity levels. *Orthopaedics*. 2016; 39(3):e486-91. <https://doi.org/10.3928/01477447-20160427-03> PMID:27135456
9. Hartigan DE, McCarthy MA, Krych AJ, Levy BA. Arthroscopic-assisted reduction and percutaneous fixation of tibial plateau fractures. *Arthroscopy techniques*. 2015; 4(1):e51-5. <https://doi.org/10.1016/j.eats.2014.11.002> PMID:25973374 PMID:PMC4427637
10. The fowble CD, Zimmer JW, Schepsis AA. The role of arthroscopy in the assessment and treatment of tibial plateau fractures. *Arthroscopy: The Journal of Arthroscopic & Related Surgery*. 1993; 9(5):584-90. [https://doi.org/10.1016/S0749-8063\(05\)80410-4](https://doi.org/10.1016/S0749-8063(05)80410-4)
11. Dall'Oca C, Maluta T, Lavini F, Bondi M, Micheloni GM, Bartolozzi P. Tibial plateau fractures: compared outcomes between ARIF and ORIF. *Strategies in Trauma and Limb Reconstruction*. 2012; 7(3):163-75. <https://doi.org/10.1007/s11751-012-0148-1> PMID:23086660 PMID:PMC3482433
12. Siegler J, Galissier B, Marcheix PS, Charissoux JL, Mabit C, Arnaud JP. Percutaneous fixation of tibial plateau fractures under arthroscopy: a medium term perspective. *Orthopaedics & Traumatology: Surgery & Research*. 2011; 97(1):44-50. <https://doi.org/10.1016/j.otsr.2010.08.005>
13. Pogliacomini F, Verdano MA, Frattini M. Combined arthroscopic and radioscopic management of tibial plateau fractures: report of 18 clinical cases. *Acta Bio Medica Atenei Parmensis*. 2005 76(2):107-14. PMID:16350556
14. Roerdink WH, Oskam J, Vierhout PA. Arthroscopically assisted osteosynthesis of tibial plateau fractures in patients older than 55 years. *Arthroscopy: The Journal of Arthroscopic & Related Surgery*. 2001; 17(8):826-31. [https://doi.org/10.1016/S0749-8063\(01\)90005-2](https://doi.org/10.1016/S0749-8063(01)90005-2)