

# Central Nervous System Tuberculoma Complicated with Spinal Arachnoiditis in Immunocompetent Patient

A.A. Ayu Suryapraba<sup>1\*</sup>, Ni Made Susilawathi<sup>2</sup>, I Wayan Nirvana<sup>3</sup>

<sup>1</sup>Neurology Department, Faculty of Medicine, Udayana University, Sanglah Hospital Denpasar, Denpasar, Bali, Indonesia; <sup>2</sup>Neurology Department, Faculty of Medicine, Udayana University, Udayana University Hospital Jimbaran, Jimbaran, Bali, Indonesia; <sup>3</sup>Neurosurgery Departement Faculty of Medicine Udayana University, Sanglah Hospital Denpasar, Bali, Indonesia

## Abstract

**Citation:** Suryapraba AAA, Susilawathi, NM, Nirvana IW. Central Nervous System Tuberculoma Complicated with Spinal Arachnoiditis in Immunocompetent Patient. Open Access Maced J Med Sci. 2019 Jun 30; 7(12):2002-2005. <https://doi.org/10.3889/oamjms.2019.272>

**Keywords:** Tuberculoma; Central nervous system; Arachnoiditis; Immunocompetent

**\*Correspondence:** A.A. Ayu Suryapraba. Neurology Department Faculty of Medicine Udayana University/Sanglah Hospital Denpasar, Denpasar, Bali, Indonesia. E-mail: [ayu.suryapraba@gmail.com](mailto:ayu.suryapraba@gmail.com)

**Received:** 04-Apr-2019; **Revised:** 07-Jun-2019;

**Accepted:** 08-Jun-2019; **Online first:** 30-Jun-2019

**Copyright:** © 2019 A.A. Ayu Surya Prabha, Ni Made Susilawathi, I Wayan Nirvana. This is an open-access article distributed under the terms of the Creative Commons Attribution-NonCommercial 4.0 International License (CC BY-NC 4.0)

**Funding:** This research did not receive any financial support

**Competing Interests:** The authors have declared that no competing interests exist

**BACKGROUND:** Central nervous system (CNS) tuberculosis (TB) can manifest as meningitis, abscess, tuberculoma or other manifestations. CNS TB is a rare TB complication, and its diagnosis remains a challenge since it has clinical and imaging features that resemble other diseases. The antituberculosis treatment has a significant role in determining a patient's outcome and prevent complications and mortality.

**CASE PRESENTATION:** Here, we report a case of CNS TB manifested as tuberculoma in immunocompetent patient complicated with spinal arachnoiditis. Despite a treatment delay, the patient still showed clinical improvement after proper treatment with a combination of antituberculosis drug and corticosteroid.

**CONCLUSION:** Central Nervous System Tuberculoma Complicated with Spinal Arachnoiditis in Immunocompetent Patient CNS tuberculoma is a rare CNS TB manifestation, and its diagnosis remain a challenge since its clinical symptoms and radiological findings could mimic other cases such as malignancy, pyogenic abscess, toxoplasmosis, sarcoidosis, or neurocysticercosis.

## Introduction

Tuberculosis (TB) is a disease caused by *Mycobacterium tuberculosis* and can occur in any organs of the human body. In the central nervous system, TB can manifest as meningitis, abscess, tuberculoma or other manifestations. CNS TB is a condition with neurological morbidity and mortality and still become a major health problem and threat in developing countries especially with the pandemic of the *human immunodeficiency virus* (HIV) [1], [2], [3].

TB Incidence in Asia & Africa developing countries range from 110-165 cases/100.000 populations per year. About 10% of patient with TB could have CNS involvement. Factors associated with an increased risk of CNS TB are young age, HIV co-infection, alcoholism, malignancy, and immunosuppressive agents. Extrapulmonary TB manifests in about 40% of patients with HIV positive [3].

*Mycobacterium tuberculosis* enters the human body through droplet inhalation, followed by bacteria phagocytosis by macrophage, which induces a cascade of inflammation, protective immunity, and formation of primary complex. In a short term of bacteremia, then the *M. tuberculosis* basil spread hematogenously to any organs including meninges or by the formation of an isolated granuloma on meninges, subpial surface and subependymal of the brain or spinal cord is known as "Rich foci" [4]. Rupture or growth of this tuberculosis lesion then develops into various type of CNS TB [4].

With such various type of TB manifestation, appropriate diagnosis and management are essential to achieve favourable outcomes. In this case report, we discuss a case of a non-HIV woman with 2 types of CNS TB manifestation; tuberculoma and spinal arachnoiditis.

## Case Presentation

A 23-year-old female, Balinese from Buleleng regency, came to Sanglah Hospital Denpasar with headache, nausea and vomiting for One month before hospital admission. The symptoms got worse on the last two weeks, accompanied by a fluctuating fever, dizziness, shaking off both arm when raised, and bilateral leg weakness, but she still could walk without assistance and did mild activities. She also complained a bit of dyspnea with a mild cough. The patient had a history of brain tumour (cerebellar mass) and had undergone VP shunt insertion followed by tumour removal about 1.5 years before, with biopsy result considered as granulomatous lesion suspected as tuberculoma (Figure 1). After the surgery, she felt the symptoms resolved and discontinued the medication. On physical examination, there were subfebrile fever, cerebellar symptoms (spontaneous nystagmus to all directions on both eyes, limb ataxia, tremor, loss of physiological reflexes, muscle atrophy especially on both legs and hypotonia).

On laboratory examination, there was normal white blood count ( $10.26 \times 10^9/\mu\text{L}$ ) with neutrophil predominance 88.3%, elevated erythrocyte sedimentation rate (66.4 mm/hour), hyponatremia (127 mmol/L) with positive cerebrospinal fluid PCR TB. CSF culture was found negative for *M. tuberculosis* Rapid test for HIV result was non-reactive.

Head MRI with contrast revealed irregular mass with enhancement, and extensive perifocal oedema sized 4.23 x 4.24 x 3.51 cm suggestive as residual/residing mass.

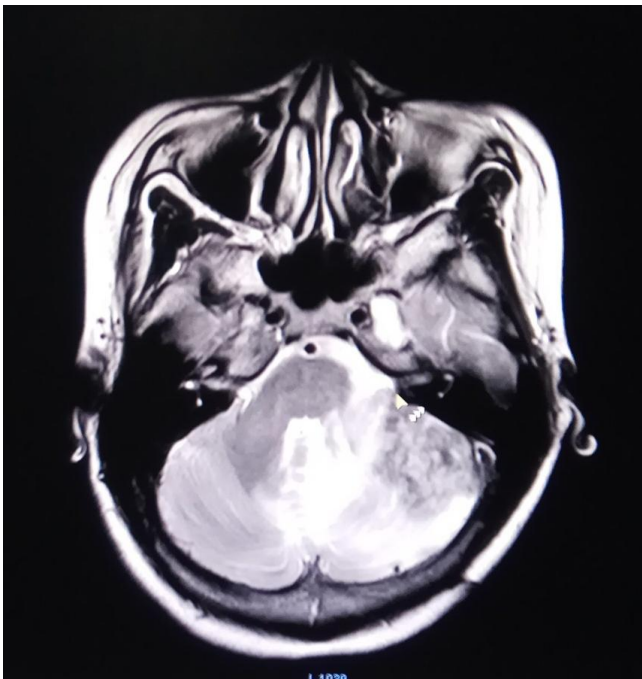


Figure 1: Chest x-ray showed pneumonia with bilateral hilar lymphadenopathy

Category I antituberculosis regimen (oral isoniazid 300 mg, rifampicin 600 mg, pyrazinamide 1500 mg and ethambutol 750 mg) also of 1 g intramuscular injection of streptomycin were given immediately. Intravenous dexamethasone injection with a dose of 5 mg was given in interval 6 hours and was tapered off 1 mg each week. The patient was consulted to the Internal Medicine Department and was assessed as pneumonia, she was given cefoperazone 1 gram/12 hours IV dan levofloxacin, 750 mg/24 hours IV.

On the third day of hospitalisation patient complained a worsening of both leg weakness, she could not lift them. She also felt numbness and tingling sensation from both toes to the navel, accompanied by difficulty in micturition and defecation. On rectal touché examination, the sphincter ani muscle tone was decreased.

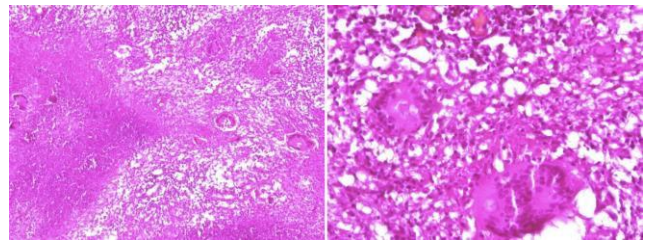


Figure 2: Histopathological result from a cerebellar mass biopsy; Large necrotic foci, some surrounded by histiocytes epithelioid cell that forms granulomas with compact aggregates and multinucleated giant cell Langhans and specific type

The patient underwent thoracolumbar MRI with contrast and showed diffuse leptomeningeal enhancement along cervical, thoracic and lumbar spine with enhancement on cauda equina and nerve root on lumbar level suggestive as arachnoiditis (Fig. 3). Compound Muscle Action Potential (CMAP) test showed loss of response on bilateral peroneus nerve, lengthening of distal latency and decreased of amplitude on bilateral tibialis nerve especially on the left side and somatosensory evoked potential (SSEP) showed lengthening of P37 latency consistent with spinal cord lesion above 12<sup>th</sup> thoracic.

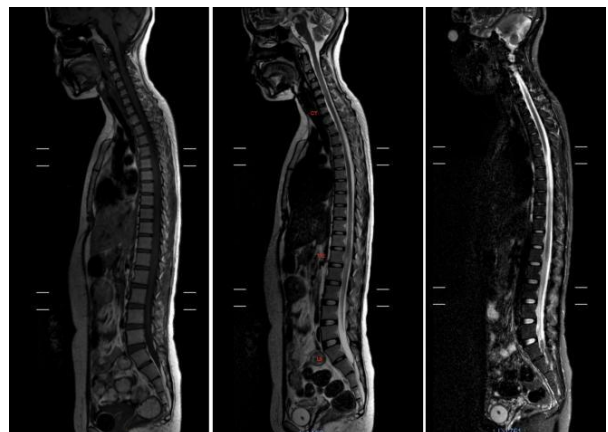


Figure 3: Whole spine vertebral MRI T1, T2, TSE; diffuse leptomeningeal enhancement along cervical, the thoracic and lumbar segment with the enhancement of cauda equine and spinal nerve roots

On the 19<sup>th</sup> day of hospitalisation patient's condition was improved, there was no fever, cerebellar signs were improved (spontaneous nystagmus were diminished, tremor and ataxia were gone), the patient could sit down with help and elevate her right leg. She could defecate without laxantia and micturate without a catheter. The patient was discharged with category I antituberculosis drug and continued streptomycin injection at a health facility near her residence.

After 3 day outpatient care patient came back to the hospital with a distended stomach. Leg weakness and numbness persist as previous time patient was discharged. On plain abdomen and 3 position abdomen x-ray, there was distention of gaster without signs of ileus. The patient was consulted to Digestive Surgery Department, and decompression was done by insertion of a nasogastric tube (NGT), and the antituberculous drug was continued. An evaluation of CSF were performed on day 8 of re-hospitalisation with result yellow colour, pleocytosis (128 cell/  $\mu$ L) with monocyte predominance (90%), total protein elevation (72.9 mg/dL) and hipoglycorachia (CSF glucose was 14 mg/dL, with CSF glucose/serum ratio 0.13). Dexamethasone 10 mg was administered intrathecally after CSF sample collection and was repeated once with a 1-week interval.

The patient then was discharged with the improvement of the condition; abdominal distention was relieved, she could elevate her both legs, sat down by herself, numbness and tingling sensation were diminished. She continued antituberculosis drug medication at the health facility in her hometown.

## Discussion

CNS TB occurs in about 1% of TB patients, especially in young age, immunosuppressed patient, malnutrition, alcoholism, and malignancy. Intracranial tuberculoma is a rare condition, found in 1 % CNS TB [5], [6]. Tuberculoma can cause focal neurologic symptoms without systemic condition, and its radiologic finding can mimic malignancy, pyogenic abscess, toxoplasmosis, sarcoidosis or neurocysticercosis [6], [7], [8].

Focal brain lesion involves the process of hematogenous spread from a primary focus on other organs such as the lung. With low cell-mediated immunity and significant inoculation size, a tubercle focus on brain parenchyma can develop into tuberculoma or abscess [4]. Intracranial tuberculoma is a rare complication and usually occur in immunocompromised patients such as HIV patients and its incidence in patients without TB is not clearly described [9], [10].

A serial case report by Guo et al. 2013 [11] reported 11 cases of infratentorial tuberculoma on immunocompetent patients and most of the cases did not show any evidence of systemic tuberculosis; only 1 subject had pulmonary TB. Infratentorial tuberculoma risks patient's life more than supratentorial tuberculoma and rarely reported. Tuberculoma can occur in any body parts. However, adults tend to have supratentorial tuberculoma while infratentorial tuberculoma occurs more in children [11], [12].

The supporting examination for diagnosis, in this case, was a positive result of CSF PCR for *M. tuberculosis*. The microbial CSF culture for *M. tuberculosis* was negative. Lack of sensitivity on current diagnostic tests for TB still became a problem in supporting early diagnosis of TB. Culture is a gold standard. However, its sensitivity is not quite high, ranging from 25 to 70%. TB diagnosis cannot be excluded from a negative microbial test [13]. PCR can detect *M. tuberculosis* weeks before culture in 80-90% of patients with TB whose TB already confirmed by culture [14].

Our patient had a complication of spinal arachnoiditis, which is considered as a late complication of CNS TB and often causes spinal cord and spinal nerve root disorder. Spinal arachnoiditis can develop into various clinical conditions such as radiculomyelitis, spinal tuberculoma, myelitis, syringomyelia, vertebral TB or spinal TB abscess. There is 3 possible pathomechanisms for TB spinal arachnoiditis; by hematogenous spread to meninges and spinal cord parenchyma; gravitation of tuberculous exudates to the lumbosacral area or via direct spread from vertebral TB [15]. With a diffuse leptomeningeal enhancement along cervical, thoracic and lumbal level accompanied by enhancement of cauda equina and spinal nerve roots on whole spine MRI examination, it is possible that our patient had gravitation of infection from infratentorial to meninges along the spinal cord until the spinal nerve roots.

After received category I antituberculosis drug with adjunction of streptomycin injection, the patient getting improved gradually with diminished of cerebellar symptoms and relieved symptoms of radiculomyelitis (increased of muscle strength, numbness and tingling sensation minimised, micturition and defecation returned to normal). Immediate treatment with an antituberculosis drug with the first-line drug (isoniazid, rifampicin, ethambutol, pyrazinamide and streptomycin) is important. At the first 2 months of intensive phase patient should receive at least 4 regimens (isoniazid, rifampicin, ethambutol and streptomycin or pyrazinamide) followed by a maintenance phase with isoniazid and rifampicin for 7-10 months [16].

The patient also received dexamethasone injection with a dose of 5 mg every 6 hours, which tapered off weekly and 2 times intratechal

dexamethasone with a 1-week interval. Corticosteroid for tuberculoma patient with spinal TB could benefit in improvement of neurological outcome despite its controversy, especially in HIV patients. The recommended dose according to latest study is dexamethasone 0.4 mg/kg/day on first week and tapered down 0.1 mg/kg every week until dose 0.1 mg/kg/day, continued orally 4mg/day and was tapered down 1 mg/kg each week [2], [15], [17]. Intrathecal steroid in TB meningitis (TBM) remains a controversy; even some study does not recommend it. Steroid decreases meningeal inflammation and consequently affect antituberculosis drug penetration [3]. According to a study by Ghosh et al. 1971 [18] in children with TBM, there was no significant difference in the outcome between patients who received oral, intravenous or intrathecal steroid.

In conclusion, CNS tuberculoma is a rare CNS TB manifestation, and its diagnosis remains a challenge since its clinical symptoms and radiological findings could mimic other cases such as malignancy, pyogenic abscess, toxoplasmosis, sarcoidosis, or neurocysticercosis. Spinal arachnoiditis as a late complication of TB infection may occur. Appropriate antituberculosis drug medication is important to prevent complications and mortality and should be highlighted since it requires a lot of drug combination and long treatment duration to achieve a favourable outcome of the patients.

## Acknowledgement

The author obtained permission from the patient and her family to report her case.

## References

1. Rock RB, Olin M, Baker CA, Molitor TW, Peterson PK. Central Nervous System Tuberculosis: Pathogenesis and Clinical Aspects. *Clinical Microbiology Reviews*. 2008;243-261. <https://doi.org/10.1128/CMR.00042-07> PMID:18400795 PMCid:PMC2292571
2. Cherian A, Thomas SV. Central nervous system tuberculosis. *African Health Sciences*. 2011; 11.
3. Chagal KH, Raina AH. Central Nervous System Manifestations of Tuberculosis: A Review Article. *J Mycobac Dis*. 2014; 4:2.
4. Garg RK. Tuberculosis of the central nervous system. *Postgrad Med J*. 1999; 75:133-140. <https://doi.org/10.1136/pgmj.75.881.133> PMID:10448488 PMCid:PMC1741157
5. Pimentel MLV, Alves SMV, Novis SAP, Brandão RZ, Neto EB. Intracranial tuberculomas are developing during treatment of pulmonary tuberculosis: a case report. *Arq Neuropsiquiatri*. 2000; 58(2-B):572. <https://doi.org/10.1590/S0004-282X2000000300028> PMID:10920425
6. Monteiro R, Carneiro JC, Costa C, Duarte R. Cerebral tuberculomas: A clinical challenge. *Respiratory Medicine Case Reports*. 2013; 9:34. 37. <https://doi.org/10.1016/j.rmcr.2013.04.003> PMID:26029627 PMCid:PMC3949551
7. Rock RB, Olin M, Baker CA, Molitor TW, Peterson PK. Central nervous system tuberculosis: pathogenesis and clinical aspects. *Clinical Microbiology Reviews*. 2008; 21(2):243e61. <https://doi.org/10.1128/CMR.00042-07> PMID:18400795 PMCid:PMC2292571
8. Sahai SS, Jones B. Brainstem tuberculoma in the immunocompetent: case report and literature review. *Clinical Neurology and Neurosurgery*. 2008; 110:302e4. <https://doi.org/10.1016/j.clineuro.2007.11.002> PMID:18160211
9. Martinez-Vazquez C, Bordon J, Rodriguez-Gonzalez A, Aguado JD, Sopena B, Gallego-Rivera A, Martinez-Cueto P. Cerebral tuberculoma- a comparative study in patients with and without HIV infection. *Infection*. 1995; 23(3):149-53. <https://doi.org/10.1007/BF01793855> PMID:7499003
10. Zavascki AP, Dias AE, Cruz RP, De Oliveira RL, Duquia RP. Intracranial tuberculomas in an immunocompetent patient mimicking brain metastasis of unknown origin. *Infection*. 2006; 34(3):181-2. <https://doi.org/10.1007/s15010-006-5028-5> PMID:16804665
11. Guo N, Huang F, Chen X, Zheng M, Zhong D, Feng Y. Infratentorial Tuberculoma Mimics Tumor in Immunocompetent Adults: An Analysis of 11 Patients. *Open Journal of Modern Neurosurgery*. 2013; 3:36-40. <https://doi.org/10.4236/ojmn.2013.33008>
12. Dastur HM, Desai AD. A Comparative Study of Brain Tuberculomas and Gliomas Based on 107 Case Records of Each. *Brain*. 1965; 88(2):375-96. <https://doi.org/10.1093/brain/88.2.375> PMID:5828909
13. Heemsker AD, Donovan J, Thu DDA, Marais S, Chaidir L, Dung VTM, Centner CM, Ha VTN, Annisa J, Dian S, Boyijn L, Mai NTH, Phu NH, Chau NVV, Ganiem AR, Van CT, Geskus RB, Thuong NTT, Ruslami R, Meinties G, van Crevel R, Wilkinson RJ, Twaithes GE. Improving the microbiological diagnosis of tuberculous meningitis: A prospective, international, multicentre comparison of conventional and modified Ziehl-Neelsen stain, GeneXpert, and culture of cerebrospinal fluid. *Journal of Infection* 77. 2018; 509-515. <https://doi.org/10.1016/j.jinf.2018.09.003> PMID:30217659 PMCid:PMC6293313
14. Ryu YJ. Diagnosis of Pulmonary Tuberculosis: Recent Advances and Diagnostic Algorithms. *Tuberc Respir Dis*. 2018; 78:64-71. <https://doi.org/10.4046/trd.2015.78.2.64> PMID:25861338 PMCid:PMC4388902
15. Garcia-Monco JC, Pomar V, Domingo P. *CNS Infections*. Springer; 2017. <https://doi.org/10.1007/978-3-319-70296-4>
16. Parekh R, Haftka A, Porter A. A Rare Case of Central Nervous System Tuberculosis. *Case reports in infectious diseases*. 2014; 2014. <https://doi.org/10.1155/2014/186030> PMID:25478256 PMCid:PMC4248556
17. Thwaites GE, Nguyen DB, Nguyen HD, Hoang TQ, Do TT, Nguyen TC. Dexamethasone for the treatment of tuberculous meningitis in adolescents and adults. *N Engl J Med*. 2004; 351(17):1741-51. <https://doi.org/10.1056/NEJMoa040573> PMID:15496623
18. Ghosh S, Seshadri R, Jain KC. Evaluation of Corticosteroids in Treatment of Tuberculous Meningitis. *Archives of Disease in Childhood*. 1971; 46:51. <https://doi.org/10.1136/adc.46.245.51> PMID:21032461 PMCid:PMC1647566