

# Dermal Pleomorphic Sarcoma of the Scalp – Report of Two Cases

Uwe Wollina<sup>1</sup>, Jacqueline Schönlebe<sup>2</sup>, Violetta Bujok<sup>1</sup>, Torello Lotti<sup>3</sup>, Georgi Tchernev<sup>4</sup>, Ivanka Temelkova<sup>4</sup>, Aleksandra Vojvodic<sup>5</sup>

<sup>1</sup>Department of Dermatology and Allergology, Städtisches Klinikum Dresden, Academic Teaching Hospital, Dresden, Germany; <sup>2</sup>Institute of Pathology “Georg Schmorl”, Städtisches Klinikum Dresden, Academic Teaching Hospital, Dresden, Germany; <sup>3</sup>Department of Dermatology, University of Rome “G. Marconi”, Rome, Italy; <sup>4</sup>Onkoderma Policlinic for Dermatology and Dermatologic Surgery, Sofia, Bulgaria; <sup>5</sup>Military Medical Academy of Belgrade, Serbia, and University of Rome Guglielmo Marconi Rome, Italy

## Abstract

**Citation:** Wollina U, Schönlebe J, Bujok V, Lotti T, Tchernev G, Temelkova I, Vojvodic A. Dermal Pleomorphic Sarcoma of the Scalp – Report of Two Cases. *Open Access Maced J Med Sci*. <https://doi.org/10.3889/oamjms.2019.274>

**Keywords:** Cutaneous sarcomas; Atypical fibroxanthoma; Dermal pleomorphic sarcoma; Surgery

**\*Correspondence:** Uwe Wollina, Department of Dermatology and Allergology, Städtisches Klinikum Dresden, Academic Teaching Hospital, Dresden, Germany. E-mail: [Uwe.Wollina@klinikum-dresden.de](mailto:Uwe.Wollina@klinikum-dresden.de)

**Received:** 04-Apr-2019; **Revised:** 18-May-2019; **Accepted:** 19-May-2019; **Online first:** 30-May-2019

**Copyright:** © 2019 Uwe Wollina, Jacqueline Schönlebe, Violetta Bujok, Torello Lotti, Georgi Tchernev, Ivanka Temelkova, Aleksandra Vojvodic. This is an open-access article distributed under the terms of the Creative Commons Attribution-NonCommercial 4.0 International License (CC BY-NC 4.0)

**Funding:** This research did not receive any financial support

**Competing Interests:** The authors have declared that no competing interests exist

**BACKGROUND:** Neoplasias of the UV-exposed head-and-neck area of the elderly include non-melanoma skin cancers of various origin.

**CASE REPORT:** We report two cases of rapid growing exophytic scalp tumors on chronic sun-damaged skin, in one case with a tendency of bleeding. The tumours were removed by wide surgical excision with 3D margin control, and the resulting defect was covered by a meshed split skin graft. Histopathologic examination disclosed a dermal pleomorphic sarcoma in both cases. The staging was unremarkable in both patients.

**CONCLUSIONS:** Sarcomatous tumours of the scalp should be completely excised with a 3D margin control. Dermal pleomorphic sarcoma is a more aggressive variant compared to atypical fibroxanthoma despite some similarities.

## Introduction

Chronic sun-exposed skin predisposed to non-melanoma skin cancer. In the head-and-neck region, basal cell carcinoma, squamous cell carcinoma, Merkel cell carcinoma, and sarcomas have to be considered in elderly patients.

Dermal pleomorphic sarcoma (DPS) is an important differential diagnosis to atypical fibroxanthoma (AFX) [1]. Both tumour entities are predominantly seen on ultraviolet (UV)-radiation exposed head-and-neck skin in elderly patients. They represent rapidly growing pleomorphic spindle-cellular

tumours with numerous mitoses, including atypical ones. These tumours are non-encapsulated. Some authors consider AFX as a superficial variant of DPS [2], [3].

While both tumours are part of a disease spectrum, their differentiation is important in risk stratification. In contrast to AFX, which shows the metastatic spread in up to 5%, DPS develops metastasis in about 10 to 20% with up to 28% local recurrences [4], [5], [6].

## Case Report

**Case 1:** A 71-year old male patient presented with a field cancerization of his bald head. In the occipital area, there was an irregular nodular plaque. A diagnostic biopsy from elsewhere suggested a cutaneous leiomyosarcoma. He was referred for complete tumour excision. His medical records were remarkable for metabolic syndrome with diabetes mellitus type II, hyperlipidemia, hyperuricemia and arterial hypertension. A being prostate hypertrophy was known.

On examination, we observed numerous actinic keratoses on his baldness, cutis rhomboidalis nuchae and elastosis. In the centre of the occipital region, a nodular firm, a painless, skin-coloured, ill-defined plaque was observed with a diameter of approximately 1.5 cm (Figure 1).

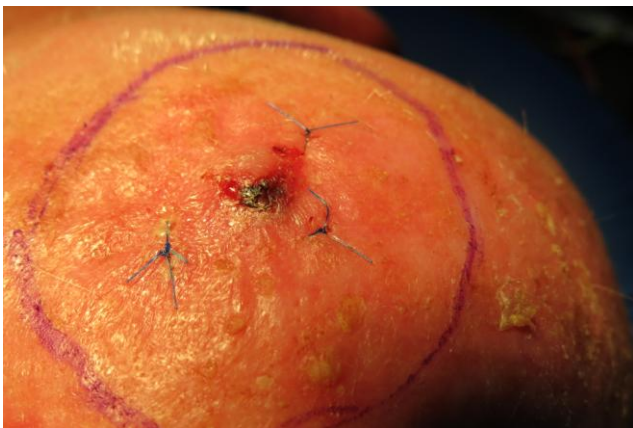

Figure 1: Dermal pleomorphic sarcoma (Case 1)

Due to the previous histological findings, we recommended a wide excision with a lateral safety margin of at least 2 cm and down to the galea in general anaesthesia and three-dimensional histologic margin control. The surgical defect measured 5 cm in diameter, which was closed by meshed graft transplantation. Wound healing was unremarkable.

Histologic examination revealed a spindle cell tumour with well-defined borders but no capsule infiltrating dermis and partially subcutaneous adipose tissue. Tumour cell was arranged in a fascicular or storiform pattern and demonstrated pronounced cellular and nuclear atypia. Locally, numerous mitoses, many atypical, could be identified. Neither lymphovascular or perineural invasion nor necrosis was evident. Tumour cells expressed CD10 and p53 strongly. Ki67 was positive in about 15% of tumour cells; smooth-muscle actin was only weakly expressed. Single cells were positive for CD68. The tumour was completely negative for pan-cytokeratin (CK), desmin and S100. Resection was R0.

The diagnosis of a DPS of the scalp was confirmed.

Tumour staging by lymph node and

abdominal sonography and dual-energy X-ray of the thorax remained unremarkable. Healing was uneventful. There was no relapse within a 2-year follow-up.

**Case 2:** An 84-year-old male patient presented with a rapidly growing, exophytic and painless scalp tumour that was easily bleeding. His medical history was remarkable for hypertensive coronary heart disease with stent implantation, diabetes mellitus type II, lower leg varicosis, gonarthrosis, nodular goitre, and presbycusis.

His facial and neck skin demonstrated signs of extrinsic ageing with cutis rhomboidalis nuchae, facial telangiectasias, multiple actinic keratoses and elastosis. On examination, we observed a partially ulcerated skin tumour in the left parieto-occipital region, measuring 4 x 4 cm (Figure 2).

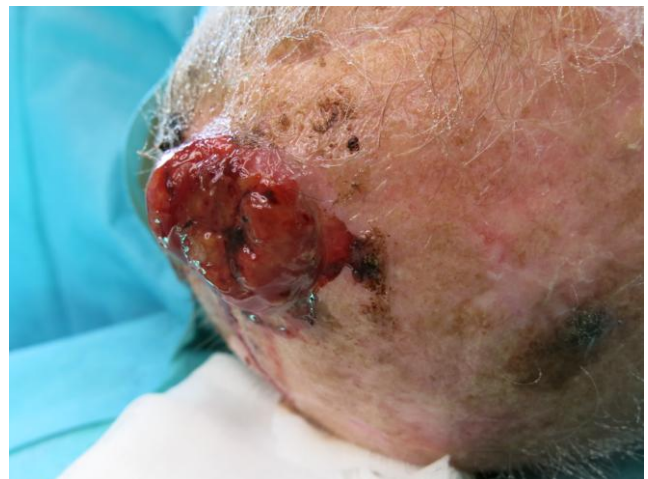

Figure 2: Dermal pleomorphic sarcoma (Case 2)

Our suspicion was either a cutaneous squamous cell carcinoma (SCC) or a Merkel cell carcinoma (MCC). We recommended wide excision with a lateral safety margin of at least 2 cm and down to the galea in general anaesthesia and three-dimensional histologic margin control. The surgical defect measured 9 x 7 cm. It was closed by meshed graft transplantation. Wound healing was unremarkable.

Histologic examination revealed an exophytic spindle cell tumour with well-defined borders but no capsule. Tumour cell was arranged in a storiform pattern and demonstrated moderate cellular and nuclear atypia. Locally, numerous mitoses, some atypical, could be identified. The tumour infiltrated the subcutaneous adipose tissue resulting in a honeycomb-like pattern. Lymphovascular and perineural invasion and tumour necrosis were absent. Tumour stroma was sparse but well vascularized with partially myxoid appearance. Tumour cells strongly expressed vimentin and CD10; a weaker expression of smooth-muscle actin was observed (Figure 3). Some cells were positive for CD68 but negative for

pan-cytokeratin (CK), CK5 and 6, CD34, and S100. Resection was R0.

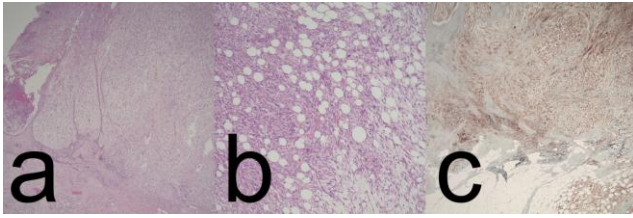


Figure 3: Histopathology of the dermal pleomorphic sarcoma (Case 2); a) Overview (hematoxylin-eosin x 2); b) Deep infiltration in the subcutaneous adipose tissue (hematoxylin-eosin x 4); c) Expression of CD10 (x 2)

The diagnosis of a DPS of the scalp was confirmed. Tumour staging by computerised tomography of the trunk and lymph node sonography did not provide any hints for a metastatic spread. The patient is in a regular follow-up.

## Discussion

AFX and DPS are sarcomatous neoplasias of the head-and-neck region of elderly patients. UV-exposure seems to be an additional risk factor for its development. Despite some similarities in clinical presentation and cell type, growth pattern, mitotic activity, they differ in depth of infiltration, invasiveness in lymphovascular and perineural structures, and prognosis [2], [3].

Comparative genomic hybridisation demonstrated similar mutation profiles in genes like *FAT1*, *NOTCH1* and 2, *CDKN2A*, *TP53* and *TERT* promoter, but activating *RAS* and *PIK3CA* mutations only in a small number of DPS [7], [8].

Risk factors for tumour recurrence are clinical tumour size larger than 5 cm and invasion beyond subcutaneous adipose tissue. Risk factors for mortality include tumour size > 2 cm, age, immunosuppression, and lymphovascular invasion [9]. Our second patient had a tumour larger than 2 cm, an age of 84 years but neither immunosuppression nor lymphovascular or perineural invasion. Treatment was surgical in both cases resulting in an R0-resection status. The staging did not demonstrate any signs of possible metastasis.

Complete excision is the treatment of choice. Whether Mohs surgery is better than wide excision is debatable, the same is true of sentinel lymph node biopsy. Nevertheless, a complete 3D-histologic margin control will reduce the risk of local recurrence. A regular follow-up of these patients is recommended [10].

In conclusion, DPS is a malignant

sarcomatous tumour of elderly patients. It represents an important differential diagnosis to other head-and-neck malignancies such as squamous cell carcinoma, basal cell carcinoma, Merkel cell carcinoma and AFX. Complete surgical excision is the treatment of choice. Tumour staging is necessary, since DPS have a risk of metastatic spread.

## References

- Mentzel T, Requena L, Brenn T. Atypical Fibroxanthoma Revisited. *Surg Pathol Clin*. 2017; 10(2):319-335. <https://doi.org/10.1016/j.path.2017.01.007> PMID:28477883
- Nonaka D, Bishop PW. Sarcoma-like tumor of head and neck skin. *Am J Surg Pathol*. 2014; 38(7):956-65. <https://doi.org/10.1097/PAS.0000000000000210> PMID:24705313
- Brenn T. Pleomorphic dermal neoplasms: a review. *Adv Anat Pathol*. 2014; 21(2):108-30. <https://doi.org/10.1097/PAP.0000000000000009> PMID:24508694
- Miller K, Goodlad JR, Brenn T. Pleomorphic dermal sarcoma: adverse histologic features predict aggressive behavior and allow distinction from atypical fibroxanthoma. *Am J Surg Pathol*. 2012; 36(9):1317-26. <https://doi.org/10.1097/PAS.0b013e31825359e1> PMID:22510760
- Wollina U, Schönlebe J, Ziemer M, Friedling F, Koch A, Haroske G, Kaatz M, Simon JC. Atypical fibroxanthoma: a series of 56 tumors and an unexplained uneven distribution of cases in southeast Germany. *Head Neck*. 2015; 37(6):829-34. <https://doi.org/10.1002/hed.23673> PMID:24946737
- Tardío JC, Pinedo F, Aramburu JA, Suárez-Massa D, Pampín A, Requena L, Santonja C. Pleomorphic dermal sarcoma: a more aggressive neoplasm than previously estimated. *J Cutan Pathol*. 2016; 43(2):101-12. <https://doi.org/10.1111/cup.12603> PMID:26264237
- Helbig D, Quaas A, Mauch C, Merkelbach-Bruse S, Büttner R, Emberger M, Wobser M, Rüsseler V, Pütz K, Binot E, Rehker J, Budczies J, Ihle MA. Copy number variations in atypical fibroxanthomas and pleomorphic dermal sarcomas. *Oncotarget*. 2017; 8(65):109457-109467. <https://doi.org/10.18632/oncotarget.22691> PMID:29312620 PMID:PMC5752533
- Koelsche C, Stichel D, Griewank KG, Schimpf D, Reuss DE, Bewerunge-Hudler M, Vokuhl C, Dinjens WNM, Petersen I, Mittelbronn M, Cuevas-Bourdier A, Buslei R, Pfister SM, Flucke U, Mechttersheimer G, Mentzel T, von Deimling A. Genome-wide methylation profiling and copy number analysis in atypical fibroxanthomas and pleomorphic dermal sarcomas indicate a similar molecular phenotype. *Clin Sarcoma Res*. 2019; 9:2. <https://doi.org/10.1186/s13569-019-0113-6> PMID:30809375 PMID:PMC6375211
- Winchester D, Lehman J, Tello T, Chimato N, Hocker T, Kim S, Chang J, Markey J, Yom SS, Ryan W, Mully T, Hodge D, Otley C, Arron ST. Undifferentiated pleomorphic sarcoma: Factors predictive of adverse outcomes. *J Am Acad Dermatol*. 2018; 79(5):853-859. <https://doi.org/10.1016/j.jaad.2018.05.022> PMID:29787841
- Soleymani T, Tyler Hollmig S. Conception and Management of a Poorly Understood Spectrum of Dermatologic Neoplasms: Atypical Fibroxanthoma, Pleomorphic Dermal Sarcoma, and Undifferentiated Pleomorphic Sarcoma. *Curr Treat Options Oncol*. 2017; 18(8):50. <https://doi.org/10.1007/s11864-017-0489-6> PMID:28762020