

Goldenhar Syndrome: A Case Report

Ruby Kurniawan*, I Kadek Suarca, I Wayan Bikin Suryawan

Department of Child Health, Wangaya General Hospital, Denpasar, Indonesia

Abstract

Citation: Kurniawan R, Suarca IK, Suryawan IWB. Goldenhar Syndrome: A Case Report. Open Access Maced J Med Sci. 2019 Apr 30; 7(8):1342-1345. <https://doi.org/10.3889/oamjms.2019.281>

Keywords: Goldenhar syndrome; Congenital; Deformity
***Correspondence:** Ruby Kurniawan. Department of Child Health, Wangaya General Hospital, Denpasar, Indonesia. E-mail: ruby_kurniawan@gmail.com

Received: 25-Feb-2019; **Revised:** 04-Apr-2019; **Accepted:** 05-Apr-2019; **Online first:** 25-Apr-2019

Copyright: © 2019 Ruby Kurniawan, I Kadek Suarca, I Wayan Bikin Suryawan. This is an open-access article distributed under the terms of the Creative Commons Attribution-NonCommercial 4.0 International License (CC BY-NC 4.0)

Funding: This research did not receive any financial support

Competing Interests: The authors have declared that no competing interests exist

BACKGROUND: Goldenhar syndrome is a multiple congenital disorder with classic characteristics regarding the face, eyes, ears. The incidence of this case is between 1:3.500 to 1:5.600. Early detection and good management can have good outcomes. A newborn with this condition can have a normal life and intelligence.

CASE PRESENTATION: A baby girl was born spontaneously at Wangaya General Hospital with APGAR minutes 1, 5, and 10 scores respectively 3, 5, and 8. Infant birth weight was 2.600 grams, body length was 47 cm, and head circumference was 31 cm with estimated age 32-34 weeks. Clinically showing an asymmetrical face, mouth toward the right side without hypoplasia, the eyelids appear asymmetrical with the right eyelid not open when the left eyelid is open, and the two ears not fully formed and diagnosed as Goldenhar Syndrome. From the physical examination, the ear canal is not formed, intact palate, normal eyeball no abnormalities in the spine and found murmur during the systolic-diastolic phase of the heart. Evaluation of the function of vision and hearing has not been concluded. Abdominal ultrasound showed first-degree picture of bilateral hydronephrosis, and from echocardiography, a PDA was found. TORCH profiles in infant were positive for IgG anti-CMV, IgG anti-rubella, and IgG anti-HSV 1. The prognosis, in this case, is good and periodic evaluation needs to be done in 6 months.

CONCLUSION: Multidisciplinary examination and management, in this case, are needed so that appropriate therapeutic planning can be carried out as well as periodic evaluations in monitoring the child's growth and development.

Introduction

Goldenhar syndrome, known as oculo-auriculo-vertebral (OAV) dysplasia is a multiple congenital disorder with classic characteristics involve the face, eyes, ears [1]. This case was first reported in 1952 [2].

The incidence of this case is between 1: 3.500 to 1:5.600 where the ratio of men: women is 3:2 [3]. The underlying cause is still poorly understood [4]. This syndrome can also affect the heart, lungs, kidneys and nervous system [5]. A newborn with this condition can have a normal life and intelligence.

Case Report

A baby girl was born spontaneously at Wangaya General Hospital and did not immediately cry with APGAR scores at 1, 5 and 10 minutes respectively 3, 5, and 8. Infant birth weight was 2.600 grams, body length 47 cm and head circumference 31 cm. After the examination of the new Ballard score, a score of 22 was obtained with estimates of age 32-34 weeks. Clinically showing an asymmetrical face, mouth toward the right side without hypoplasia, the eyelids appear asymmetrical with the right eyelid not open when the left eyelid is open, and the two ears not fully formed (Figure 1) and diagnosed as Goldenhar Syndrome. Maternal diagnosis is 40 years old, gravida 2, para 1, 32 weeks 4 days gestation age,

premature rupture of membranes (ROM) 12 hours and HBsAg (+). Baby's mother never continued immunisation before pregnancy, no history of illness or perceived fever during pregnancy, no history of miscarriage and only taking vitamin supplementation from the primary health centre. There is no similar history in the family.

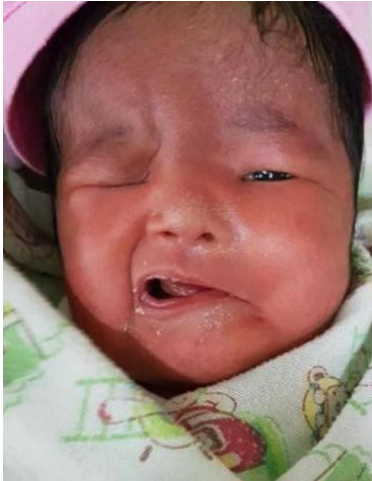

Figure 1: The face is not symmetrical

From the physical examination, the ear canal is not formed (Figure 2), intact palate, normal eyeball, no abnormalities in the spine and found murmur during the systolic-diastolic phase of the heart. Evaluation of the function of vision and hearing has not been concluded. Based on routine blood results, leukocytes 10.610/uL, haemoglobin 19.8 g/dL, platelets 189.000/uL, neutrophils 48%, lymphocytes 33.6%, monocytes 16.6%, so it was concluded that there were no signs of acute infection.




Figure 2: The earlobe and ear canal are not formed

The babygram examination shows the heart is not enlarged, the lungs do not appear infiltrates and normal bronchovascular patterns, the left-right diaphragm is normal, no abnormalities in the projected spine (Figure 3), the contour of the right-left kidney is not clear, psoas line is symmetrical right, the shadow of the liver and spleen do not appear enlarged and the corpus, pedicle, intervertebral spatium are good. From the abdominal ultrasound, first-degree bilateral hydronephrosis was obtained. From echocardiography, a patent ductus arteriosus (PDA) was found. TORCH profiles in infant were positive for IgG anti-cytomegalovirus (CMV), anti-rubella IgG, and

IgG anti-HSV (herpes simplex virus) 1. From the physical examination and supporting data, it was concluded that Goldenhar syndrome.

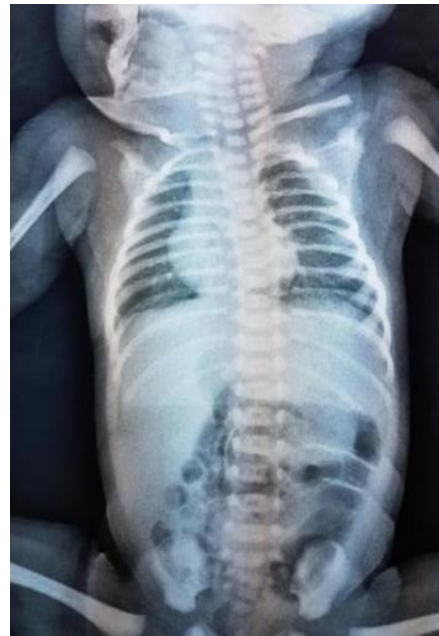

Figure 3: Radiological examination of the anteroposterior spine. No abnormalities were found

Discussion

Goldenhar syndrome is a congenital disorder known as dysplasia/oculo-auricular-vertebral syndrome (OAV) with classic triad syndrome, namely mandibular hypoplasia (facial asymmetry), ear malformation (microtia/anotia and preauricular fistula) and/or eyes (bulbar dermoid cyst, microphthalmia), as well as vertebral anomalies [7]. This case was first reported in 1952 by Maurice Goldenhar [1], [2].

The incidence of this case is between 1:3.500 to 1:5.600 where the ratio of men: women is 3:2 [3]. Approximately 1-2% of people affected have other family members with this condition, which indicates that genes can play a role in some cases [5]. This case cannot be concluded because genetic testing cannot be carried out in Bali because it can only be done at the Eijkman Institute Jakarta and can be a consideration for further examinations. In family history, no or negative abnormalities were found.

The underlying cause of this disorder is still poorly understood, but it is possible that the embryonic vascular supply to the first and second branch arches at 4-8 weeks of conception is abnormal, disturbances in mesoderm migration or several other factors cause the formation of branch arches and a damaged spinal system [6], [8], [9]. The history of pregnancy such as heavy alcohol

consumption, use of drugs such as thalidomide, retinoic acid, tamoxifen, and cocaine may be related as a risk factor to the development of this syndrome. Pregnancy with diabetes, rubella infection and influenza are possible etiological factors [10]. The causative factor in this case probably due to rubella infection during before or early pregnancy is seen from the presence of positive anti-rubella IgG from baby and mother without immunization. It maybe the baby's mother had been infected before. From birth defects are found, we considered to rubella infection.

Facial asymmetry and mandibular hypoplasia are typical features of OAV syndrome [11]. In addition to these abnormalities, Goldenhar syndrome may be associated with other disorders such as mental retardation, hearing loss, cleft palate, abnormal hands or fingers, pulmonary hypoplasia, lymphoma, kidney agenesis, ectopic kidney, ureter duplication, hydronephrosis, hydroureter, and genitourinary system anomalies [7]. Cardiovascular malformations occur in patients with Goldenhar syndrome between 5-58 per cent, the most common being ventricular septal defect and tetralogy of Fallot, PDA [12]. In this case, a small PDA was found and no symptoms during hospitalised. It must be observed because a small PDA may close spontaneously. If a small PDA does not close and no symptoms, it requires medical treatment and possible to surgical repair after 6 months of age.

The diagnosis of Goldenhar syndrome through the identification of abnormalities on physical examination, no genetic examination. The multidisciplinary examination of ophthalmology, otolaryngology, odontology, radiology and neurology contributes to the diagnosis and treatment of this case [13].

Management of this case is by abnormalities and age. In patients with mandibular hypoplasia, reconstruction is performed. Structural abnormalities in the eyes and ears are corrected by plastic surgery. Surgery to repair cleft lip and cleft palate [14].

Early management is very important in this case. By improving hearing function with hearing aids, bone-anchored hearing aids for conductive hearing loss, cochlear implants in cases of severe sensorineural hearing loss, and reconstruction at 4-10 years of age, operating time depends on the severity of the disability and the age of the child [15], [16]. After the Goldenhar syndrome is diagnosed, flexion-extension must be measured every 6 months and must be considered for scoliosis [12]. Evaluations carried out in this case, among others, the examination of vision, hearing, spine, heart in 6 months of monitoring and growth and development. Scan computerized tomography (CT) inspection plans to look for problems that are not seen with babygram.

In conclusion, Goldenhar syndrome patients can have multiple congenital abnormalities and must be thoroughly examined with other multidisciplinary. In

making a diagnosis, must be with the other multidisciplinary so that appropriate therapeutic planning can be carried out and periodic evaluations in monitoring the child's growth and development. The prognosis is determined by the abnormality and severity obtained, and periodic evaluation needs to be done in 6 months to determine its progress. In this case, the prognosis of this baby is good; there are no serious problems in facial malformations and inclusion abnormalities such as abnormalities of the heart and kidneys. Patients reported here have several problems in the eyes, ears and heart. At present, patients are in medical care and observation for other possible problems.

References

1. Goldenhar M. Associations malformatives de l'oeil et l'oreille, en particulier le syndrome dermoide épibulbaire-appendices auriculaires-fistula auris congenita et ses relations avec la dysostose mandibulo-faciale. *J Genet Hum.* 1952; 1:243-82.
2. Reddy MV, Reddy PP, Usha Rani P, Hema Bindu L. Facio-auricular vertebral syndrome-a case report. *Indian J Hum Genet.* 2005; 11:156-8. <https://doi.org/10.4103/0971-6866.19537>
3. Kulkarni VV, Shah MD, Parikh AA. Goldenhar syndrome: A case report. *J Postgrad Med.* 1985; 31:177-9.
4. Seethalakshmi A, Sreenivasan A, Saraswathy GK. Goldenhar Syndrome - Review with Case Series. *Journal of Clinical and Diagnostic Research.* 2014; 8(4):17-19. <https://doi.org/10.7860/JCDR/2014/7926.4260>
5. National Center for Advancing Translation Sciences. Goldenhar disease, 2019. <https://rarediseases.info.nih.gov/diseases/6540/goldenhar-disease> (accessed 10 Januari 2019).
6. Maria Ferreira J, Gonzaga J. Goldenhar syndrome. *Revista Brasileira de Oftalmologia.* 2016; 75(5). <https://doi.org/10.5935/0034-7280.20160081>
7. Kumar Barolia D, Kumar Mehra S, Chaturvedi V, Raipuria G, Pratap Singh A, Kumar Rai A. Goldenhar Syndrome associated with Vestibular Fistula and Esophageal Atresia - A Rare Association. *Journal of Neonatal Surgery.* 2018; 7(8). <https://doi.org/10.21699/jns.v7i1.668>
8. Bijal Mehta, Chitra Nayak, Shankar Savant et al. Goldenhar syndrome with unusual features. *Indian J Venerol Dermatol Leprol.* 2008; 74(3):254-56. <https://doi.org/10.4103/0378-6323.41374>
9. Relhan V, Mittal S, Mahajan K, Kumar Garg V. Goldenhar syndrome with rare clinical features. *Indian Journal of Paediatric Dermatology.* 2017; 18(4). https://doi.org/10.4103/ijpd.IJPD_110_16
10. Ferrari F, D'Orazio F, Patriarca L, Piccorossi A, Di Fabio S, Barile A, et al. A Female Case of Goldenhar Syndrome with Mandibular Hypoplasia and Aural Involvement. *British Journal of Medicine & Medical Research.* 2015; 11(8). <https://doi.org/10.9734/BJMMR/2016/21666>
11. Pinheiro ALB, Araujo LC, Oliveira SB, Sampaio MCC, Freitas AC. Goldenhar's Syndrome - Case Report. *Braz Dent J.* 2003; 14(1). <https://doi.org/10.1590/S0103-64402003000100013>
12. Bayraktar S, Tabanlı Bayraktar S, Ataoglu E, Ayaz A, Elevli M. Case Report Goldenhar's Syndrome Associated with Multiple Congenital Abnormalities. *Oxford University Press.* 2005; 51(6). <https://doi.org/10.1093/tropej/fmi020>
13. Sethi R, Sethi A, Lokwani P, Chalwade M. Case Report

- Goldenhar syndrome. Indraprastha Medical Corporation. 2015; 12. <https://doi.org/10.1016/j.apme.2015.02.011>
14. Goswami M, Bhushan U, Jangra B. Goldenhar Syndrome: A Case Report with Review. International Journal of Clinical Pediatric Dentistry. 2016; 9(3):278-280. <https://doi.org/10.5005/jp-journals-10005-1351>
15. Strömmland K, Miller M, Sjögreen L, Johansson M, Ekman Joelsson B, Billstedt E, et al.. Oculo-Auriculo-Vertebral Spectrum: Associated Anomalies, Functional Deficits and Possible Developmental Risk Factors. American Journal of Medical Genetics. 2007; Part A(143A):1317-1325. <https://doi.org/10.1002/ajmg.a.31769>
16. Division of Birth Defects and Developmental Disabilities Centers for Disease Control and Prevention, 2019. Facts about Anotia/Microtia. <https://www.cdc.gov/ncbddd/birthdefects/anotia-microtia.html> (accessed 30 Januari 2019).