

# Eosinophilic Fasciitis – Report of Three Cases and Review of the Literature

Uwe Wollina<sup>1\*</sup>, Gesina Hansel<sup>1</sup>, Jacqueline Schönlebe<sup>2</sup>, Birgit Heinig<sup>3</sup>, Ivanka Temelkova<sup>4</sup>, Georgi Tchernev<sup>4</sup>, Aleksandra Vojvodic<sup>5</sup>, Torello Lotti<sup>6</sup>

<sup>1</sup>Städtisches Klinikum Dresden, Department of Dermatology and Allergology, Dresden, Germany; <sup>2</sup>Institute of Pathology "Georg Schmorl", Städtisches Klinikum Dresden, Academic Teaching Hospital, Dresden, Germany; <sup>3</sup>Center of Physical and Rehabilitative Medicine, Städtisches Klinikum Dresden, Academic Teaching Hospital, Dresden, Germany; <sup>4</sup>Onkoderma - Clinic for Dermatology, Venereology and Dermatologic Surgery, General Skobelev 26, 1606, Sofia, Bulgaria; <sup>5</sup>Department of Dermatology and Venereology, Military Medical Academy of Belgrade, Belgrade, Serbia; <sup>6</sup>University of Rome Guglielmo Marconi Rome, Italy

## Abstract

**Citation:** Wollina U, Hansel G, Schönlebe J, Heinig B, Temelkova I, Tchernev G, Vojvodic A, Lotti T. Eosinophilic Fasciitis – Report of Three Cases and Review of The Literature. *Open Access Maced J Med Sci.* <https://doi.org/10.3889/oamjms.2019.296>

**Keywords:** Eosinophilic fasciitis; Fibrotic disorders; Scleroderma; Treatment; Corticosteroids; Methotrexate

**\*Correspondence:** Uwe Wollina. Städtisches Klinikum Dresden, Department of Dermatology and Allergology, Dresden, Germany. E-mail: uwollina@gmail.com

**Received:** 05-Apr-2019; **Revised:** 03-May-2019;  
**Accepted:** 04-May-2019; **Online first:** 15-May-2019

**Copyright:** © 2019 Uwe Wollina, Gesina Hansel, Jacqueline Schönlebe, Birgit Heinig, Ivanka Temelkova, Georgi Tchernev, Aleksandra Vojvodic, Torello Lotti. This is an open-access article distributed under the terms of the Creative Commons Attribution-NonCommercial 4.0 International License (CC BY-NC 4.0)

**Funding:** This research did not receive any financial support

**Competing Interests:** The authors have declared that no competing interests exist

**BACKGROUND:** Eosinophilic fasciitis is a rare fibrosing disorder of muscle fascia with rapid onset of erythema, induration, oedema and tenderness affecting extremities bilaterally.

**CASE REPORT:** We report three cases of eosinophilic fasciitis in 3 females aged 64, 65 and 73 years, in two of them in association with morphea. They fulfilled the proposed diagnostic criteria. Associated malignancies could be excluded in all of them. They were treated by systemic corticosteroids. In the two females with associated morphea higher prednisolone dosages and a combination with methotrexate was necessary.

**CONCLUSIONS:** Eosinophilic fasciitis is a differential diagnosis of systemic scleroderma. Response to treatment is often delayed. Systemic corticosteroids are the first line therapy. Patients with associated morphea need combined drug therapy, in our patients with methotrexate. There is no close correlation between laboratory signs of inflammation and clinical response to treatment.

## Introduction

Eosinophilic dermatosis was described first by Shulman in 1975 as diffuse fasciitis with hypergammaglobulinemia and eosinophilia [1], [2]. The disease is now also known as Shulman syndrome. It is characterised by abrupt onset with bilateral oedema on the limbs, peau d'orange appearance of the skin, linear depression along the veins (groove sign), and tenderness.

The induration is progressive and may lead to

joint contractures in about 50% of patients [3]. In Caucasians, women are affected twice as often as men, in Japan, the male to female ratio is 1.5:1 [4]. In about 25% of cases, only the lower legs are involved, but most often all four limbs become affected. Raynaud's phenomenon is typically absent [5]. Although cases with trunk involvement have been reported, the face is always spared [4].

The disease is rare with only 63 patients in the largest series reported so far [5].

## Case reports

**Case 1:** A 65-year-old woman developed plaque-like, erythematous induration on all four extremities with tenderness since March 2017. She reported a feeling of tension on the ankles with limited mobility, muscular pain and weakness, and fatigue. She had already unintended lost 7 kg of her body weight within 3 months.

Her medical history was positive for diabetes mellitus type II (no medications), arterial hypertension, hyperlipoproteinemia, and hyperuricemia. She was a smoker with 10 cigarettes per day.

On examination, we observed symmetric brownish hyperpigmentation on lower legs and lower arms, and the lower trunk. The skin appeared thickened, and it was impossible to crease the skin. The groove sign was positive on the legs (Figure 1). She had no Raynaud's phenomenon.

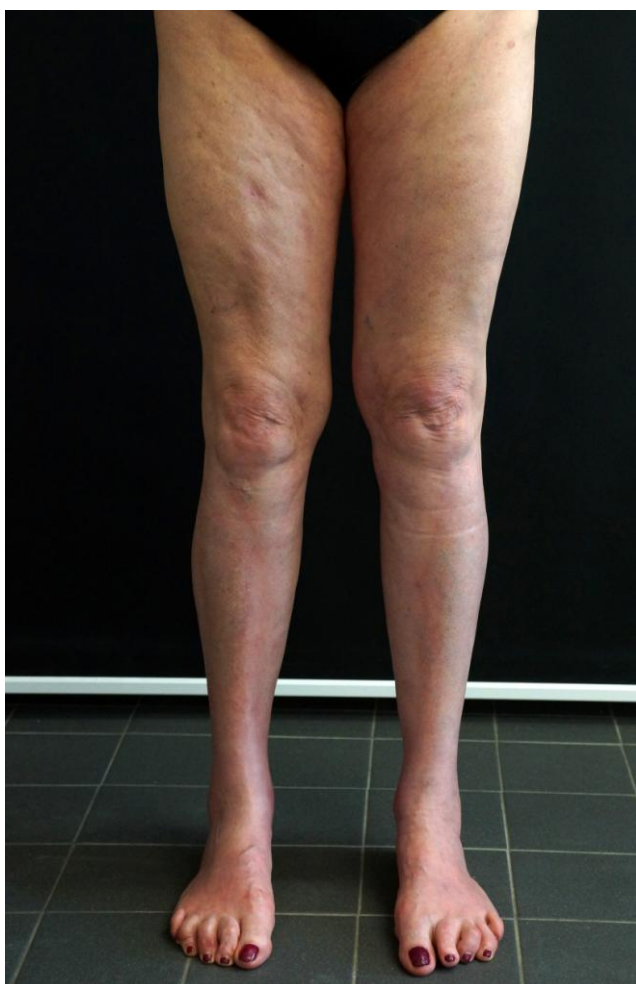

Figure 1: Eosinophilic fasciitis in a 65-year-old woman. Positive groove sign on her leg

We took a skin biopsy from the lower arm that showed epidermal atrophy and band-like melanin pigmentation of the basal layer. Along the border of cutis and subcutis, inflammatory infiltrates composed of lymphocytes and monocytes were visible.

A bone marrow biopsy demonstrated increased production of eosinophils.

Molecular cytogenetic diagnostics excluded an eosinophilic myeloproliferative malignancy.

Laboratory findings: Leukocytosis of 14.3 Gpt/L, erythrocytes 3.6 Tpt/L, eosinophilia of 8%, C-reactive Protein 67.1 mg/L.

Imaging: Computerized tomography (CT) scan of the trunk remained unremarkable. Esophago-duodenoscopy: Helicobacter-associated (HP) pangastritis. Colonoscopy: Benign colon polyps (Biopsy).

Treatment and course: Initially we suspected a malignancy. The pangastritis was eradicated by triple therapy of HP gastritis. The clinical findings with peripheral eosinophilia confirmed the diagnosis of eosinophilic fasciitis. The patients treated initially with 60 mg prednisolone/d with slow tapering down the doses. We started pantoprazole and cholecalciferol therapy to protect the stomach and prevent osteoporosis. She responded well.

**Case 2:** A 64-year-old woman noted a progressive and painful thickening of the soft tissue on her lower arms and legs. She suffered from diffuse pain of muscles and bones. Her medical history was remarkable for allergic asthma. She was treated with mepolizumab for one year. The treatment was withdrawn in March 2018 because of the suspicion of drug-related toxicity. She underwent a corrective nasal surgery because of nasal stenosis in May 2018. She suffered from pollen allergy, glaucoma and liver hemangiomas.

On examination, we observed erythematous lesions with livedo reticularis. The subcutaneous soft tissue was fibrotic and thickened. On her lower arms, plate-like indurations were noted. The affected limbs were painful. Peau d'orange appearance of upper legs was obvious (Figure 2). Hands and feet remained unaffected. There was no Raynaud's phenomenon.

We took a skin biopsy that revealed a superficial and deep perivascular and interstitial dermatitis with the involvement of eosinophils. The subcutaneous adipose tissue presented septal panniculitis.

Laboratory findings: C-reactive protein 24 mg/L, eosinophilia of 32%, lymphocytes 13%,  $\beta$ 2-microglobulin 4.6 mg/L, interleukin-2-receptor 2,380 U/mL. Serology for infections remained negative. Antinuclear antibodies 1:160.

Bone-marrow biopsy: Eosinophilia (31.8%), lymphocytes 14%. Molecular cytogenetics and FISH – no malignancy, no aberrant cell clone in the bone marrow.

Imaging: X-Ray Thorax: Diffuse fibrotic pulmonary changes, mild emphysema. Body plethysmography: Minor alterations of diffusion. MRI abdomen: Steatosis hepatitis, liver hemangioma. MRI

right lower arm: Hyperintense fascial signals. Mammography: Involution. No malignancy.

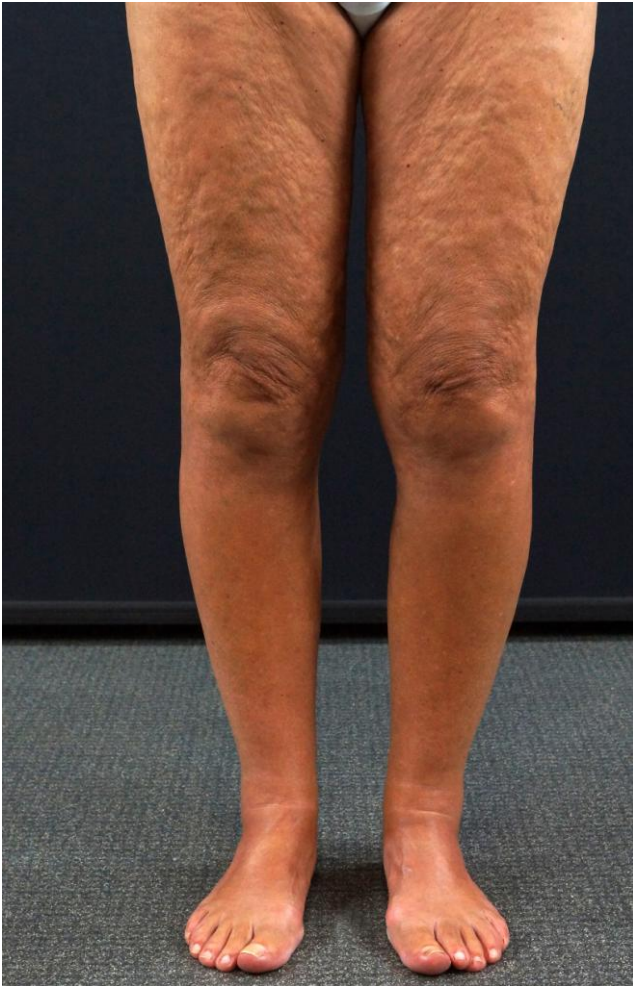

Figure 2: Eosinophilic fasciitis in a 64-year-old woman. Peau d'orange sign

Treatment and course: After confirmation of the diagnosis of eosinophilic fasciitis by clinical finding, MRI and eosinophilia, we started initially with 100 mg prednisolone/d and 20 mg pantoprazole/d. Ten days later, the prednisolone dosage could be reduced to 75 mg/d and methotrexate 15 mg per week plus 5 mg folate on the following day. Pain management was realised using metamizole and hydromorphone. Physical therapy with mobilisation and manual lymph drainage was initiated. Within 10 days, the inflammatory parameters normalised. A very slow dose of tapering was recommended for outpatient treatment.

In October 2018, the patient returned to the hospital with a worsening of her complaints. At that time, she received prednisolone 5 mg/d and methotrexate 10 mg/week. We repeated tumour screening including colonoscopy, esophagogastroscope and CT scans from the head and the trunks that remained inconspicuous. MRI of the right lower arm demonstrated the improvement of her fasciitis. We performed a high-dose pulse therapy with 1000 mg

prednisolone intravenous infusion on 4 consecutive days and increased the methotrexate dosage to 15 mg/week. On the following days, the dosage of prednisolone was 100 mg/d and later 75 mg/d. In January 2019 we repeated the high-dose pulse therapy on 3 consecutive days. We noted an improvement of the thickness of the tissue and tenderness on the extremities. On the trunk, however, she developed symptomless plaque-type morphea.

**Case 3:** A 73-year-old woman developed in April 2018 multiple circumscribed plaques on her trunk diagnosed as morphea. She was treated by a combination of 10 mio U penicillin i.v. And psoralen plus UVA therapy (PUVA) resulting in complete remission. During the following months, she noted relapsing oedema on the extremities with subsequent thickening, fibrosis and tenderness on lower arms and lower legs. Her medical history was positive for hypothyroidism and cataract.

On examination, we observed symmetrical plaque-like subcutaneous indurations on lower arms and lower legs. There was a peau d'orange appearance of her upper legs (Figure 3). Hands and feet remained unaffected. She had no Raynaud's phenomenon.

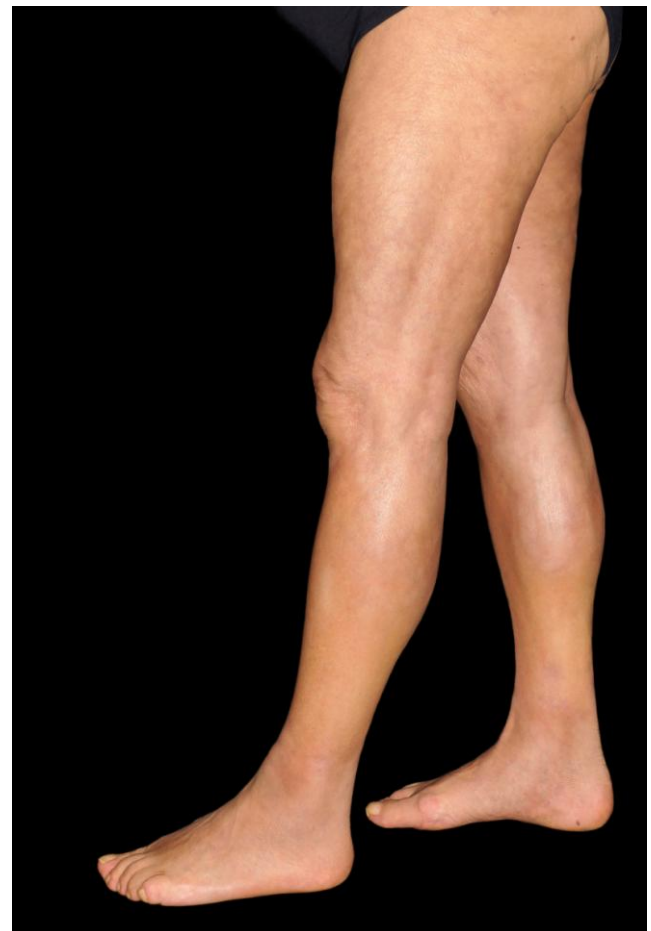

Figure 3: Eosinophilic fasciitis in a 73-year-old woman. Peau d'orange sign

A skin biopsy revealed some inflammatory infiltrate in the reticular dermis. In the deep dermis, it was perivascular, periadnexal and interstitial composed of mononuclear cells and some eosinophils. In the subcutaneous adipose tissue septal tissue became enlarged and presented with interstitial cellular infiltrates. Some foreign-body granulomas were described. Elastic fibres were preserved.

Laboratory findings: Eosinophilia 7.1% and lymphopenia 10%. Gamma-globulins were increased (21.6%), lactate dehydrogenase (4.24  $\mu$ kat/L) and C-reactive protein (7.28 mg/L) were slightly increased.

Imaging: An MRI of the right lower arm demonstrated fibrosis of the proximal ulnar part and generalised enhanced signalling of the fascia.

Treatment and course: After confirmation of eosinophilic fasciitis we performed a high-dose prednisolone pulse therapy with 1000 mg/ on 4 consecutive days with protective pantoprazole medication. Afterwards, we switched to oral treatment with 100 mg prednisolone/d and 15 mg methotrexate/week plus 5 mg folate on the other day after methotrexate.

Pain management was realised with ibuprofen. She was also treated with physical therapy (manual lymph drainage and mobilisation). A control MRI disclosed improvement of the fasciitis and nearly complete remission of the fibrosis. Tissue hardening could be reduced, and pain relief was achieved (Figure 4). The prednisolone dosage could further be tapered down.

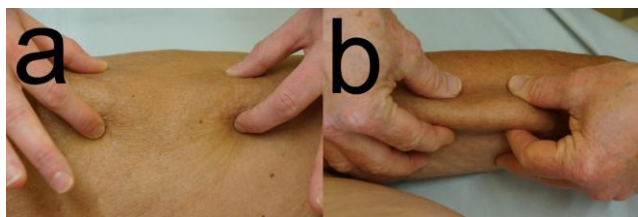


Figure 4: Patient #3 Improvement of soft tissue tenderness (thigh). (a) Before treatment. (b) After high-dose prednisolone pulse therapy

## Discussion

Eosinophilic fasciitis is a rare disease of the fibrous spectrum but distinct from systemic scleroderma. Diagnostic criteria have been proposed by different groups of investigators (Table 1 and 2) [6], [7]. Patients with eosinophilic fasciitis are often initially misdiagnosed leading to delayed treatment. We performed skin biopsies to exclude other dermatoses.

Table 1: Diagnostic criteria for eosinophilic fasciitis [6]

Major criteria	(a) symmetric or asymmetric diffuse or localised swelling, induration and thickening of the skin and subcutaneous tissue (b) Histology showing fascial thickening with an accumulation of lymphocytes and macrophages with or without eosinophils
Minor criteria	(a) Peripheral eosinophilia ( $> 0.5 \times 10^9/L$ ) (b) Hypergammaglobulinemia ( $> 1.5 g/L$ ) (c) Muscular weakness and/or elevated serum aldolase (d) Groove sign and/or peau d'orange appearance of skin (e) T2-weighted MRI showing hyperintense fascia
Exclusion criterion	Diagnosis of systemic scleroderma

The pathogenesis of eosinophilic fasciitis is not completely understood. Autoimmune mechanisms have been suggested, but strenuous exercise or labour may trigger the onset. Dermal fibroblasts are hyperactive overexpressing type I collagen and fibronectin [8].

Table 2: Japanese diagnostic criteria of eosinophilic fasciitis [7]

Major criterion:	Symmetrical plate-like sclerotic lesions are present on the four limbs. However, this condition lacks Raynaud's phenomenon, and systemic sclerosis can be excluded.
Minor criteria 1:	The histology of a skin biopsy that incorporates the fascia shows fibrosis of the subcutaneous connective tissue, with thickening of the fascia and cellular infiltration of eosinophils and monocytes.
Minor criteria 2:	Thickening of the fascia is seen using imaging tests such as magnetic resonance imaging (MRI).

A definitive diagnosis is made when a patient has the major criterion and one of the minor criteria, or the major criterion and two of the minor criteria.

Levels of tissue inhibitor of metalloproteinase-1 (TIMP-1), an inhibitor of the extracellular matrix-degrading enzyme matrix metalloproteinase-1, are also increased, supporting tissue fibrosis [9]. There are reports on altered levels of certain interleukins, interferon-gamma, transforming growth factor- $\beta$ 1 mRNA, and TH17+ cells [4], [5].

Diagnosis is confirmed by fascial biopsy and histopathology demonstrating fascial thickening, fibrosis, and lymphocytic infiltrate [6], [7]. Involvement of muscles and adipose tissue may also be present. Another diagnostic tool is the MRI that shows hyperintense fascia on T2-weighted images [10] (Table 3).

Table 3: Findings of our patients with eosinophilic fasciitis

Criteria	Patient 1	Patient 2	Patient 3
Major criteria			
(a) Clinical findings	+	+	+
(b) Fascial histology	not done	not done	not done
Minor criteria			
(a) Eosinophilia	+	+	+
(b) Hypergammaglobulinemia	-	-	+
(c) Muscular weakness	+	+	+
(d) Groove sign and / or peau d'orange	+	(+)	(+)
(e) MRI hyperintense fascia	-	+	+
	+	+	+

Treatment is not standardised. It is known that concurrent morphea is associated with a 1.4 to 3 times higher risk of resistance to systemic corticosteroid therapy [8], [11]. Our experience with two patients with associated morphea supports this finding. Both did not respond to oral corticosteroids

and needed a combined medication with methotrexate and intravenous high-dose pulse steroids. Medical treatment was supported by pain management and physical therapy. The latter is of importance to prevent joint contractures [5]. Since eosinophilic fasciitis may be a facultative paraneoplastic disorder, exclusion of underlying malignancies is of importance [3], [4], [5]. We performed imaging investigations and bone-marrow biopsies. In all three of our patients, a malignant background could be excluded.

The course of the disease often needs many months to several years of treatment. The keystones of drug therapy are systemic corticosteroids and methotrexate. Other drugs that have been occasionally used are mycophenolate mofetil, cyclosporin A, dapson, azathioprine, tumour necrosis factor-inhibitors, sirolimus, immunoglobulins, and D-penicillamine. Photo(chemo)therapy with either UVA1, PUVA or extracorporeal photochemotherapy has also been reported [12]. There are some case reports about the successful but off-label use of interleukin-6 antagonist tocilizumab [13], anti-CD-antibody rituximab [14], and Janus kinase inhibitor tofacitinib [15]. In some of the cases, these new drugs have been used in combination with either methotrexate or prednisolone. We achieved improvement with systemic corticosteroids with or without methotrexate.

In conclusion, eosinophilic fasciitis is rare but probably underdiagnosed. The disease should not be mistaken for systemic scleroderma since treatment and prognosis are different. Careful clinical investigation, histopathology, eosinophilia in peripheral blood, and MRI allow the confirmation of diagnosis. Keystones of treatment are systemic corticosteroids and methotrexate, although other compounds have also been used occasionally. Physical therapy is essential to prevent joint contractures that develop in half of the patients.

## References

- Shulman LE. Diffuse fasciitis with hypergammaglobulinemia and eosinophilia: a new syndrome? *J Rheumatol.* 1974; 1(1):46.
- Shulman LE. Diffuse fasciitis with eosinophilia: a new syndrome? *Trans Assoc Am Physicians.* 1975; 88:70-86.
- Wright NA, Mazori DR, Patel M, Merola JF, Femia AN, Vleugels RA. Epidemiology and Treatment of Eosinophilic Fasciitis: An Analysis of 63 Patients From 3 Tertiary Care Centers. *JAMA Dermatol.* 2016; 152(1):97-9. <https://doi.org/10.1001/jamadermatol.2015.3648> PMID:26559760
- Ihn H. Eosinophilic fasciitis: From pathophysiology to treatment. *Allergol Int.* 2019; S1323-8930(19)30021-8. <https://doi.org/10.1016/j.alit.2019.03.001> PMID:30910631
- Mazori DR, Femia AN, Vleugels RA. Eosinophilic Fasciitis: an Updated Review on Diagnosis and Treatment. *Curr Rheumatol Rep.* 2017; 19(12):74. <https://doi.org/10.1007/s11926-017-0700-6> PMID:29101481
- Pinal-Fernandez I, Selva-O' Callaghan A, Grau JM. Diagnosis and classification of eosinophilic fasciitis. *Autoimmun Rev.* 2014; 13(4-5):379-82. <https://doi.org/10.1016/j.autrev.2014.01.019> PMID:24424187
- Jinnin M, Yamamoto T, Asano Y, Ishikawa O, Sato S, Takehara K, Hasegawa M, Fujimoto M, Ihn H. Diagnostic criteria, severity classification and guidelines of eosinophilic fasciitis. *J Dermatol.* 2018; 45(8):881-90. <https://doi.org/10.1111/1346-8138.14160> PMID:29235676
- Jinnin M, Ihn H, Yamane K, Asano Y, Yazawa N, Tamaki K. Serum levels of tissue inhibitor of metalloproteinase-1 and 2 in patients with eosinophilic fasciitis. *Br J Dermatol.* 2004; 151(2):407-12. <https://doi.org/10.1111/j.1365-2133.2004.06062.x> PMID:15327548
- Lebeaux D, Francès C, Barete S, Wechsler B, Dubourg O, Renoux J, Maisonobe T, Benveniste O, Gattfossé M, Bourgeois P, Amoura Z, Cacoub P, Piette JC, Sène D. Eosinophilic fasciitis (Shulman disease): new insights into the therapeutic management from a series of 34 patients. *Rheumatology (Oxford).* 2012; 51(3):557-61. <https://doi.org/10.1093/rheumatology/ker366> PMID:22120602
- Kirchgeßner T, Dallaudière B, Omoumi P, Malghem J, Vande Berg B, Lecouvet F, Houssiau F, Galant C, Larbi A. Eosinophilic fasciitis: typical abnormalities, variants and differential diagnosis of fasciae abnormalities using MR imaging. *Diagn Interv Imaging.* 2015; 96(4):341-8. <https://doi.org/10.1016/j.diii.2014.06.018> PMID:25746223
- Endo Y, Tamura A, Matsushima Y, Iwasaki T, Hasegawa M, Nagai Y, Ishikawa O. Eosinophilic fasciitis: report of two cases and a systematic review of the literature dealing with clinical variables that predict the outcome. *Clin Rheumatol.* 2007; 26(9):1445-51. <https://doi.org/10.1007/s10067-006-0525-6> PMID:17345001
- Tull R, Hoover WD 3rd, De Luca JF, Huang WW, Jorizzo JL. Eosinophilic fasciitis: a case series with an emphasis on therapy and induction of remission. *Drugs Context.* 2018; 7:212529. <https://doi.org/10.7573/dic.212529> PMID:30302114 PMID:PMC6172017
- Espinoza F, Jorgensen C, Pers YM. Efficacy of Tocilizumab in the treatment of Eosinophilic fasciitis: Report of one case. *Joint Bone Spine.* 2015; 82(6):460-1. <https://doi.org/10.1016/j.jbspin.2015.02.008> PMID:26162635
- Nahhas AF, Alam M, Lim HW. Rituximab as a therapeutic consideration for refractory eosinophilic fasciitis. *Int J Dermatol.* 2018; 57(5):614-615. <https://doi.org/10.1111/ijd.13940> PMID:29446454
- Kim SR, Charos A, Damsky W, Heald P, Girardi M, King BA. Treatment of generalized deep morphea and eosinophilic fasciitis with the Janus kinase inhibitor tofacitinib. *JAAD Case Rep.* 2018; 4(5):443-445. <https://doi.org/10.1016/j.jdcr.2017.12.003> PMID:29984277 PMID:PMC6031588