

Giant Pelvic Neurofibroma in Patient with Plexiform Sciatic Neurofibroma and Neurofibromatosis Type 1

Ivanka Temelkova^{1,2*}, Georgi Tchernev^{1,2}

¹Medical Institute of Ministry of Interior (MVR), Department of Dermatology, Venereology and Dermatologic Surgery, General Skobelev 79, 1606 Sofia, Bulgaria; ²Onkoderma, Clinic for Dermatology, Venereology and Dermatologic Surgery, General Skobelev 26, 1606 Sofia, Bulgaria

Abstract

Citation: Temelkova I, Tchernev G. Giant Pelvic Neurofibroma In Patient with Plexiform Sciatic Neurofibroma And Neurofibromatosis Type 1. Open Access Maced J Med Sci. 2019 Apr 30; 7(8):1346-1349. <https://doi.org/10.3889/oamjms.2019.304>

Keywords: Neurofibromas; Plexiform neurofibroma; Surgical treatment; Sirolimus; MPNST; Neurofibrosarcoma

***Correspondence:** Ivanka Temelkova. Medical Institute of Ministry of Interior (MVR), Department of Dermatology, Venereology and Dermatologic surgery, General Skobelev 79, 1606 Sofia, Bulgaria; Onkoderma-Clinic for Dermatology, Venereology and Dermatologic Surgery, General Skobelev 26, 1606 Sofia, Bulgaria. E-mail: vanq2991@gmail.com

Received: 10-Mar-2019; **Revised:** 15-Apr-2019; **Accepted:** 16-Apr-2019; **Online first:** 25-Apr-2019

Copyright: © 2019 Ivanka Temelkova, Georgi Tchernev. This is an open-access article distributed under the terms of the Creative Commons Attribution-NonCommercial 4.0 International License (CC BY-NC 4.0)

Funding: This research did not receive any financial support

Competing Interests: The authors have declared that no competing interests exist

BACKGROUND: Neurofibromatosis is a genetic disease with an autosomal dominant type of inheritance. It is a multisystem disease in which, besides skin manifestations, there is a possibility for the involvement of other organs and systems, and an atypical variant of neurofibromatosis type 1 can also be observed- the so-called plexiform neurofibroma. In patients with this inherited disease, mortality is higher due to the existing risk for malignant transformation and development of malignant peripheral nerve sheath tumours (MPNSTs) or neurofibrosarcoma.

CASE REPORT: We present a 25-year-old woman with neurofibromatosis type 1 and a family history of the disease-father and grandmother with NF-1, with fatal outcome in the grandmother as a result of malignant transformation to neurofibrosarcoma. The patient has clinical data for multiple café-au-lait spots on the skin of the trunk, upper and lower limbs, and plexiform tumour formation in the seating area. From the performed imaging diagnostic there are available MRT data for 1) giant pelvic neurofibroma, 2) plexiform giant neurofibroma in the subcutaneous fat on the right thigh and gluteal fat tissue to the right, passing through the midline in the area of the external genitalia, leading to deformation of the front wall of the sacrum with bilateral meningoceles and 3) diffuse involvement of the bladder wall from the process in the area of the trigonum vesicae/felleae/the two urethral ostium, as well as 4) the presence of neurofibromas in the course of the iliac vessels on the right. Surgical removal of the oval pelvic formation, identified as neurofibroma was planned, as well as the initiation of systemic therapy with Sirolimus for the plexiform sciatic formation, infiltrating the bladder.

CONCLUSION: Neurofibromatosis type-1 is a problematic disease due to the parallel systemic involvement of different organs and systems, which can be both limited and diffuse. Limited tumour lesions in the form of neurofibromas with diverse localisation (as in the patient we describe) could be surgically removed without difficulty. On the other hand, the diffuse involvement of internal organs within a giant, network-3spreading plexiform neurofibromas (as in the described patient) makes interdisciplinary interventions impossible, and therefore therapeutic alternatives should be considered.

Introduction

Neurofibromatosis was first described in 1882 by Von Recklinghausen as a genetic neuroectodermal abnormality with systemic and progressive involvement, which mainly affected the skin, nervous system, bones, eyes and possibly other organs [1]. It is estimated that about one million people worldwide are living with NF [1]. Neurofibromatosis type 1 is a multisystem autosomal dominant disease, with cutaneous manifestations such as café-au-lait spots, multiple neurofibromas, ephelides in the skin fold

areas, and hamartomatous lesions in the eyes, bones, glands and the central nervous system [1], [2]. Uncommon variants of NF-1 are the so-called plexiform neurofibromas in which neurofibromas arise from multiple nerves that may also engage connective tissue and skin folds and are clinically described as "bags of worms" [3]. Patients with neurofibromatosis are at risk for malignant transformation, as on the one hand having an increased risk of developing malignant peripheral nerve sheath tumours (MPNSTs), and on the other are threatened by a transformation to neurofibrosarcoma, which should be suspected if the initial lesion grows rapidly and

significantly [4], [5], [6]. We describe a patient with neurofibromatosis type 1, miction disorders and giant pelvic neurofibroma.

Case Report

We present a 25-year-old woman with a family history for neurofibromatosis type 1. According to anamnestic data, father and grandmother suffer from neurofibromatosis type 1, as in the grandmother being observed lethal outcome as a result of the transition from plexiform neurofibroma to neurofibrosarcoma in the neck area. The first symptoms date back to the age of 2-3 when multiple café-au-lait spots were observed all over the body and appearance of tumour formation in the neck and genital area (Figures 1a-1d). At the age of 3 labiaplasties were performed on the pubic lips. By entering puberty, tumour formations in the neck area and genitals begin to increase in size. In 2015, the patient was hospitalised in a plastic-restorative and aesthetic surgery department, where step by step the skin and some parts of the plexiform neurofibromas in the lumbosacral, the sciatic, genital, and upper-medial area of the right thigh have been removed.

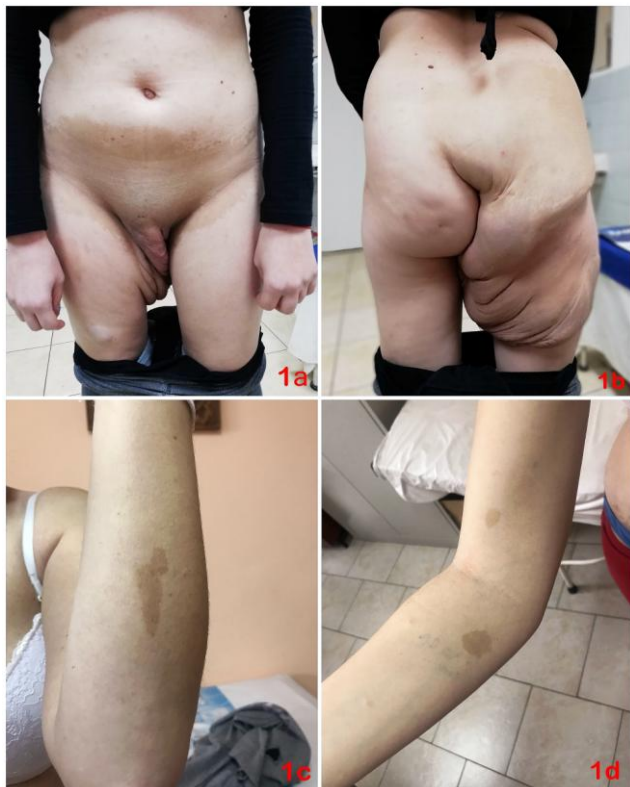

Figure 1: A), B) Clinical examination: in the area of the genitals, the gluteal region and the upper medial part of the right hip, a plexiform tumour-like formation with a darker-skin-colour appearance, which resembles clinically as "worm bag" (Figures 1a and 1b) was observed; C), D): Clinical view of numerous café-au-lait spots on the skin of the upper limbs

In 2016, due to recurrent bladder infections, the patient was directed to a urology department where small pelvis MRI was performed. The results showed an enlarged, hypotonic bladder with multiple diverticula (Figures 2b, 2d). In addition to the right of the bladder and ovary, an 82/50/50 mm formation with sharp and smooth outlines was visualised (Figures 2a-2c). The formation has a characteristic of giant pelvic neurofibroma (Figures 2a-2c).

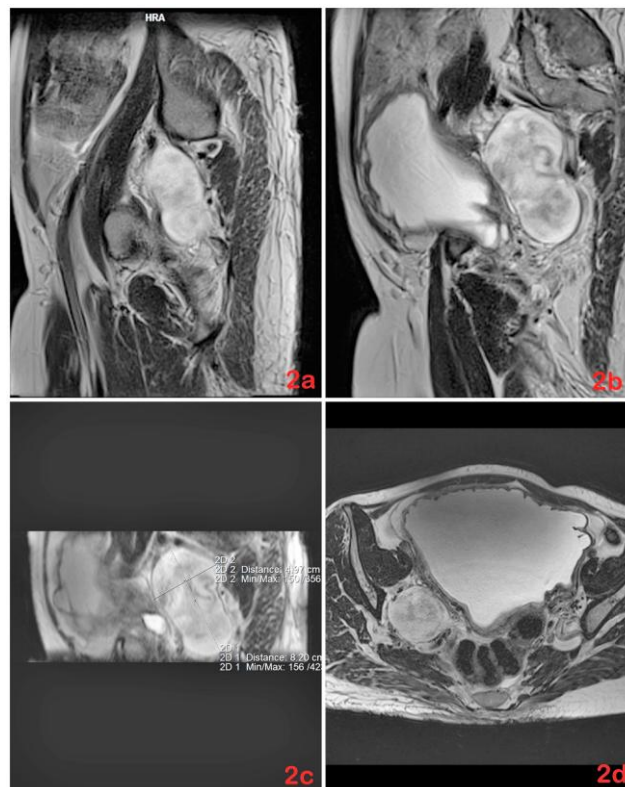


Figure 2: A), B), and C) An MRI images of abdomen, small pelvis, gluteal area and thighs with data for a 9cm mass with irregular shape, lying on the right side of the pelvis and a conclusion about giant pelvic neurofibroma; D) MRI of a small pelvis showing an enlarged, hypotonic bladder with multiple diverticulitis

Within the dermatological examination, a tumour formation was observed in the genital, buttock area and upper-medial part of the right thigh with darker skin colour, resembling clinically as a "worm bag"-plexiform neurofibroma in the sciatic area (Figures 1a-1b). Also, the presence of multiple café-au-lait on the skin of the trunk, upper and lower extremities were found (Figures 1c-1d).

An additional MRI of a small pelvis with contrast revealed data for deformation of the sacrum on the front wall with bilateral meningoceles at Ec1 and Ec2 levels (Figures 3a,3c), as well as the presence of plexiform giant neurofibroma in the subcutaneous fat of the right thigh and gluteal fat on the right, with the changes crossing the midline in the area of the external genitalia (Figure 3a).

The presence of neurofibromas in the course of the iliac vessels on the right, with the larger one measuring 75/49 mm (Figure 3a). Bladder with

irregularly thickened walls and uneven internal outline contours (Figures 3a-3b, 3d). According to the image data, the finding engages the back wall diffusely in the area of the trigonum and the two urethral ostium, and in the trigonum area, the bladder wall is engaged in its entire volume (Figures 3a-3d).

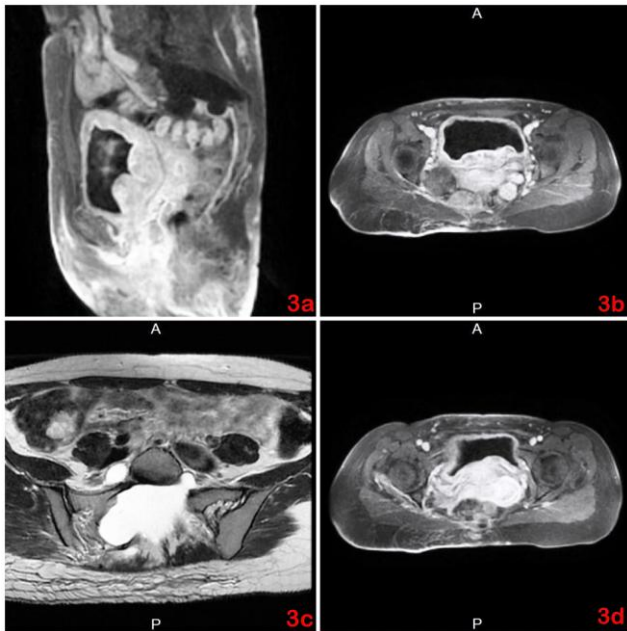


Figure 3: A), B) MRI images showing irregularly thickened walls and uneven internal contours of the bladder wall in the area of the trigonum and the two urethral ostia; C), D) Deformation of the anterior sacral wall with bilateral meningoceles at the Ec1 and Ec2 levels and diffuse engagement of the posterior wall of the bladder in its entire volume

The hospitalisation was planned in a neurosurgical unit for eventual surgical treatment.

Discussion

Data on patients with neurofibromatosis have existed since XIII and XVI centuries, and as early as 1785- Mark Akensidi describes a case about a patient who was nicknamed "wart man" [1]. Subsequently, various descriptions and definitions of the disease arise, and it is currently thought that Neurofibromatosis type 1 (NF-1) or von Recklinghausen's disease is a disease of autosomal dominant transmission that is thought to have mutations in the NF1 gene on the long arm of chromosome 17 (17q11.2), resulting in a decrease in the production of neurofibromin protein, resulting in a lack of control of cell growth and division [2].

Classically, the skin manifestations of NF1 are characterised by the presence of neurofibromas and café au lait spots variably distributed throughout the

skin [7]. In some cases, however, neurofibromas are located along the nerves, in the subcutaneous tissue and follow the nerves affecting large areas and are defined as plexiform neurofibromas [8]. Patients with neurofibromatosis have a higher mortality rate which is mostly related to the possibility of malignant transformation of tumours [1].

Patients are at risk for the transformation of NFs to malignant peripheral nerve sheath tumours (MPNSTs) or neurofibrosarcoma [4], [5], [6]. According to the literature data, particular attention should be paid to four markers (epidermal growth factor receptor, interferon- γ , interleukin-6, and tumour necrosis factor- α) to distinguish between patients with NF-1 and healthy subjects [9].

Even more significant (from a prognostic point of view) should be the determination of two additional markers as potential early risk predictors of developing MPNST (insulin-like growth factor binding protein 1 (IGFBP1)) and regulated upon activation, normal T-cell expressed and secreted (RANTES) in patients with type 1 neurofibromatosis and plexiform neurofibromas [9].

According to the majority of authors' collectives, patients with neurofibromatosis should be closely monitored and, where possible, excision of skin tumours or surgical treatment should be performed [1], [2], [3]. In many cases, however, surgical excision is complicated due to the involvement of the main nervous branches within the plexiform neurofibromas, and then the possibility of relapse after resection depends on the possibility of total or partial resection [4].

We describe an interesting case of a patient with a giant, well-defined neurofibroma behind the bladder, as well as giant network-like sciatic plexiform neurofibroma engaging the genital area of the right, the gluteal region and the upper-medial part of the right thigh. Surgical excision of well-defined neurofibroma in the pelvic region should not be problematic and was planned in a neurosurgical ward at a later stage. Due to evidence of meningoceles in the sacral region, as well as an unfortunate localization of plexiform neurofibroma in the pelvic/genital area, neurosurgeons currently restrain from surgical intervention.

Alternative treatment for patients with type 1 neurofibromatosis could be systemic therapy with Sirolimus (0.8 mg/m² body surface area by mouth for a 28-day course) [10]. Based on the available data, sirolimus treatment is appropriate for patients with progressive NF-1 type, inoperable, and it is not recommended for non-progressive forms of NF-1 [11]. Therapeutic alternatives should be considered.

References

1. Antônio J, Goloni-Bertollo E, Trídico L. Neurofibromatosis: chronological history and current issues. *An Bras Dermatol.* 2013; 88(3):329-43. <https://doi.org/10.1590/abd1806-4841.20132125> PMID:23793209 PMCID:PMC3754363
2. Serafini N, Serafini C, Vinhas A, Godinho M. Moyamoya syndrome associated with neurofibromatosis type 1 in a pediatric patient. *An Bras Dermatol.* 2017; 92(6):870-873. <https://doi.org/10.1590/abd1806-4841.20176829> PMID:29364453 PMCID:PMC5786411
3. Tchernev G, Chokoeva A, Patterson JW, Bakardzhiev I, Wollina U, Tana C. Plexiform Neurofibroma: A Case Report. *Medicine (Baltimore).* 2016; 95(6):e2663. <https://doi.org/10.1097/MD.0000000000002663>
4. Stefano P, Apa S, Lanoël A, María J, Sierre S, Pierini A. Isolated plexiform neurofibroma mimicking a vascular lesion. *An Bras Dermatol.* 2016; 91(2):240-2. <https://doi.org/10.1590/abd1806-4841.20164300> PMID:27192529 PMCID:PMC4861577
5. Nielsen G, Stemmer-Rachamimov A, Ino Y, Moller M, Rosenberg A, Louis D. Malignant transformation of neurofibromas in neurofibromatosis 1 is associated with CDKN2A/p16 inactivation. *Am J Pathol.* 1999; 155(6):1879-84. [https://doi.org/10.1016/S0002-9440\(10\)65507-1](https://doi.org/10.1016/S0002-9440(10)65507-1)
6. McCarron K, Goldblum J. Plexiform neurofibroma with and without associated malignant peripheral nerve sheath tumor: a clinicopathologic and immunohistochemical analysis of 54 cases. *Mod Pathol.* 1998; 11(7):612-7.
7. Tongsgard J. Clinical manifestations and management of neurofibromatosis type 1. *Semin Pediatr Neurol.* 2006; 13:2-7. <https://doi.org/10.1016/j.spen.2006.01.005> PMID:16818170
8. Aloï F, Massobrio R. Solitary plexiform neurofibroma. *Dermatologica.* 1989; 179:84-86. <https://doi.org/10.1159/000248318> PMID:2529151
9. Park S, Sawitzki B, Kluwe L, et al. Serum biomarkers for neurofibromatosis type 1 and early detection of malignant peripheral nerve-sheath tumors. *BMC Med.* 2013; 11:109. <https://doi.org/10.1186/1741-7015-11-109> PMID:23618374 PMCID:PMC3648455
10. Weiss B, Widemann B, Wolters P, Dombi E, Vinks A, Cantor A, Perentesis J, Schorry E, Ullrich N, Gutmann D, Tongsgard J, Viskochil D, Korf B, Packer R, Fisher M. Sirolimus for progressive neurofibromatosis type 1-associated plexiform neurofibromas: a neurofibromatosis Clinical Trials Consortium phase II study. *Neuro Oncol.* 2015; 17(4):596-603. <https://doi.org/10.1093/neuonc/nou235> PMID:25314964 PMCID:PMC4483073
11. Weiss B, Widemann BC, Wolters P, Dombi E, Vinks AA, Cantor A, Korf B, Perentesis J, Gutmann DH, Schorry E, Packer R, Fisher MJ. Sirolimus for non-progressive NF1-associated plexiform neurofibromas: an NF clinical trials consortium phase II study. *Pediatr Blood Cancer.* 2014; 61(6):982-6. <https://doi.org/10.1002/pbc.24873> PMID:24851266