

# Cerebellar Cryptococcal Abscess in HIV-Negative Patient: A Case Report and Literature Review

Ni Putu Sriwidyani<sup>1</sup>, Ni Luh G Sagita Dewi<sup>1</sup>, I Nyoman Golden<sup>2</sup>, I Putu Eka Widyadharna<sup>3\*</sup>

<sup>1</sup>Anatomical Pathology Department, Faculty of Medicine Udayana University, Sanglah General Hospital, Bali, Indonesia; <sup>2</sup>Neurosurgery Department, Faculty of Medicine Udayana University, Sanglah General Hospital, Bali, Indonesia; <sup>3</sup>Neurology Department, Faculty of Medicine Udayana University, Sanglah General Hospital, Bali, Indonesia

## Abstract

**Citation:** Sriwidyani NP, Dewi NLGS, Golden IN, Widyadharna IPE. Cerebellar Cryptococcal Abscess in HIV-Negative Patient: A Case Report and Literature Review. Open Access Maced J Med Sci. <https://doi.org/10.3889/oamjms.2019.320>

**Keywords:** Cryptococcosis; Abscess; Immune-competent; Cerebellum; Fungal

**\*Correspondence:** I Putu Eka Widyadharna. Neurology Department, Faculty of Medicine Udayana University/Sanglah General Hospital, Bali, Indonesia. E-mail: [eka.widyadharna@unud.ac.id](mailto:eka.widyadharna@unud.ac.id)

**Received:** 25-Mar-2019; **Revised:** 20-Apr-2019; **Accepted:** 21-Apr-2019; **Online first:** 29-Apr-2019

**Copyright:** © 2019 Ni Putu Sriwidyani, Ni Luh G Sagita Dewi, I Nyoman Golden, I Putu Eka Widyadharna. This is an open-access article distributed under the terms of the Creative Commons Attribution-NonCommercial 4.0 International License (CC BY-NC 4.0)

**Funding:** This research did not receive any financial support

**Competing Interests:** The authors have declared that no competing interests exist

**BACKGROUND:** Cryptococcus is a common cause of opportunistic infection in HIV-positive patients. While the incidence of this disease has decreased in AIDS-associated cases, cryptococcal infection in immune-competent person has been increased.

**CASE PRESENTATION:** We report a case of cryptococcosis and literature review of pathogenesis and clinical aspects of cryptococcal central nervous system infection. A 64-year-old man, from Flores, complaining of severe headache since a few days before admitted to hospital. Head MRI showed multiple hypointense lesions in the left cerebellar hemisphere, suspected abscess or metastatic process. HIV testing was non-reactive. Surgery was performed, and microscopic evaluation revealed multiple abscesses containing PAS-positive budding yeasts consistent with cryptococcal abscesses.

**CONCLUSION:** Cryptococcosis rarely occur in immunocompetent patients. The clinical manifestation depends on pathogenic factors of pathogen and host factor. Treatment is with the administration of antifungal drugs, and the prognosis mostly depends on the underlying disease.

## Introduction

Cryptococcus is the fourth leading cause of opportunistic infections after Pneumocystis jiroveci, Cytomegalovirus, and Mycobacteria with central nervous system (CNS) manifestations. Manifestations of the CNS are much more frequent than those of other organs. In patients infected with human immunodeficiency virus (HIV) in the United States, the incidence of cryptococcosis is about 2-7 cases per 1000 per year, with 89% of manifestations in the CNS [1]. The incidence in HIV patients has declined recently due to widespread antifungal and antiretroviral use. Meanwhile, the incidence in immune-competent person is increasing. Cryptococcosis is an infection caused by encapsulated fungi, *Cryptococcus neoformans*, and

*Cryptococcus gattii*. In CNS cryptococcosis, the organisms spread through the respiratory tract and infect the CNS hematogenously [2]. Pathogenesis of disease in immune-competent person is not clear; the pathogenic factor of the pathogen and host immune response may involve. Here we report one case of cerebellar cryptococcal abscesses in an immune-competent patient, with a literature review of its pathogenic and clinical aspects.

## Case Presentation

A 62-year-old man from Flores, exposed to poultry, complaining of severe headache since a few days before hospital admission. He was suffered from

intermittent headache previously. Neurologic examination revealed left cranial nerve VII, XII supranuclear paresis, left spastic hemiparesis, negative meningeal sign, and positive left Hoffmann-Tromner reflex. Laboratory examination showed normal complete blood count and non-reactive for HIV testing.

Head MRI examination revealed multiple hypointense lesions in the left cerebellum hemisphere at T1W1, the lesion became hyperintense on T2W1 and restricted to DW1, which was with contrast enhancement. The lesions suppress the IV ventricle. The ventricular system of lateral and III ventricular widen with periventricular hyperintense (Figure 1). The conclusion was multiple hypointense lesions in the left hemisphere of the cerebellum with differential diagnoses of abscesses and metastasis tumour, non-communicating hydrocephalus, and ventriculitis.

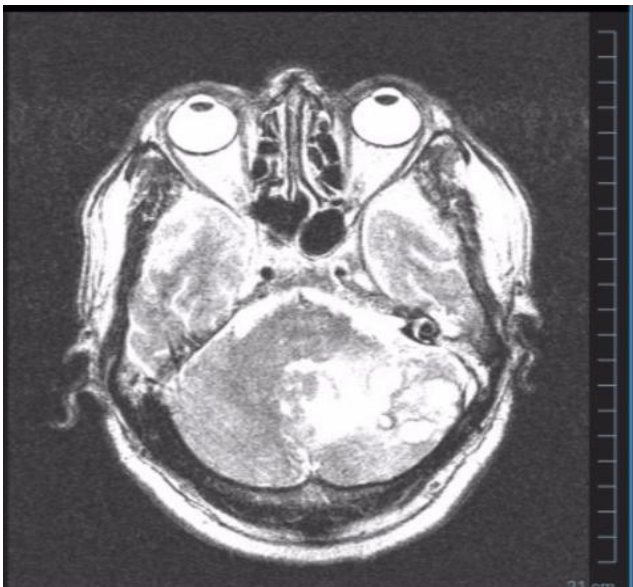


Figure 1: Head MRI. Multiple hypointense lesions in the left cerebellar hemisphere of T1W1, hypertense on T2W1 and restricted to DW1, with contrast enhancement rim. The lesion suppresses the IV ventricle

Based on the results from anamnesis, physical examination and investigation, a working diagnosis on this patient were space-occupying lesions of the cerebellum with differential diagnoses of tumour and abscess. Brain surgery was being performed and based on microscopic examination; there were areas of brain tissue necrosis. The edges of necrosis were surrounded by granulation tissue containing lymphoplasmacytic inflammatory cells. In the necrotic area, there were many unstained ovoid structures. PAS staining examination demonstrated oval-shaped organisms, with bright red double contour wall consistent with cerebellar cryptococcal abscesses (Figure 2). The patient was treated with fluconazole, and the symptoms were improved.

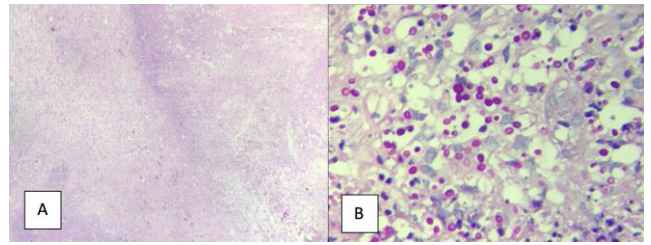


Figure 2: A) Diffuse necrosis with lymphoplasmacytic inflammatory cells. In the necrotic area, there are many unstained ovoid structures; B) PAS staining showed bright red yeast consistent with *Cryptococcus*

## Discussion

Invasive fungal infections are estimated to cause over 1.5 million death per year worldwide — the majority of cases occurring in immunocompromised patients [3]. *Cryptococcus* can be isolated from the environment in many regions of the world. However symptomatic disease after exposure is relatively rare. The defect in cellular immunity is the most commonly found risk factor. Meanwhile, other predisposing factors are tissue transplant, malignancy, sarcoidosis, chronic liver disease, and renal failure [3], [4].

*Cryptococcus neoformans* and *Cryptococcus gattii* are two etiologic agents of cryptococcosis. Brain cryptococcosis more frequently associated with *C. neoformans*. Meanwhile, lung infection more frequently caused by *C. gattii*. They can be distinguished from other pathogenic yeasts by the presence of polysaccharide capsule, melanin formation, and urease activity, which all function as virulence factors of this pathogen. *C. neoformans* primarily reaches the lung after inhalation and disseminates to the brain [5]. Several pieces of evidence showed that *C. neoformans* invades the central nervous system by two mechanisms, direct invasion of endothelial cells lining of brain vasculature and by Trojan horse mechanism whereby the pathogen enters the central nervous system after macrophage ingestion [4], [6].

Neurological cryptococcosis can encompass several different presentations, including meningitis, encephalitis, ventriculitis, increased intracranial pressure, and space-occupying lesion (cerebral abscesses, cyst, and granuloma) [5]. Meningeal infection is one of the most common presentations. Meanwhile, cerebellar infection is rare. Several cases of cerebellar cryptococcosis have been reported [6], [7], [8], [9], [10], [11], [12]. The clinical manifestations of cerebellar cryptococcosis is commonly present with signs of increased intracranial pressure and abnormality of cerebellar functions (ataxia and dysdiadochokinesis). Extension of infection to the surrounding structures can be observed by the presence of cranial nerve functions disorder,

meningeal signs, ventriculitis, and hydrocephalus. The typical imaging appearances of cryptococcal meningoencephalitis include dilated Virchow Robin Space, pseudocysts, abscess, cryptococcoma, leptomeningeal or parenchymal enhancing lesions, and hazy brain base [13]. Cultures of CSF and analysis of soluble cryptococcal polysaccharides are the standard laboratory diagnosis for neurological cryptococcosis [5]. Tissue examination from the space-occupying lesion of brain cryptococcosis may reveal the specific morphologic appearance of this fungi as pathogen proliferation within space surrounded by chronic inflammation or with the granulomatous formation. The fungi which appeared as unstained ovoid structures in H-E staining will be looked like bright red encapsulated ovoid yeast when it is highlighted with PAS staining [14]. Most of the CNS cryptococcosis are successfully treated with fluconazole. A severe case can be treated with amphotericin B and flucytosine combination. A study by Pappas *et al.* showed significant factors that contributed to mortality included late age, hematologic malignancy, and the presence of organ failure [15].

In conclusion, cryptococcosis is an infection caused by fungi and rarely occurs in immunocompetent patients. The clinical manifestation depends on pathogenic factors of pathogen and host factor. Treatment is with the administration of antifungal drugs. The prognosis of this disease mostly depends on the underlying disease.

## References

1. Frosch MP, Anthony DC, Girolami UD. The Central Nervous System. In: Kumar, Abbas, Aster, editor. Robbins and Cotran Pathologic Basis of Disease. 9th ed. Philadelphia: Elsevier Saunders, 2015:1279-1285. <https://doi.org/10.1016/B978-1-4377-0792-2.50033-X>
2. Colombo AC and Rodrigues ML. Fungal colonization of the brain: anatomopathological aspects of neurological cryptococcosis. An Acad Bras Cienc. 2015; 87:1293-1309. <https://doi.org/10.1590/0001-3765201520140704> PMID:26247147
3. Esher SK, Zaragoza O, Alspaugh JA. Cryptococcal pathogenic mechanisms: a dangerous trip from the environment to the brain. Mem Inst Oswaldo Cruz. 2018; 113(7): 1-15. <https://doi.org/10.1590/0073-0008-2018-0000> PMID:29668825  
PMCID:PMC5909089
4. Maziarz EK, Perfect JR. Cryptococcosis. Infect Dis Clin North Am. 2016; 30(1):179-206. <https://doi.org/10.1016/j.idc.2015.10.006> PMID:26897067 PMCID:PMC5808417
5. Kwon-Chung KJ, Fraser JA, Doering TL, Wang ZA, Janbon G, Idrum A, Bahn Y. Cryptococcus neoformans and Cryptococcus gattii, the etiologic agents of cryptococcosis. Cold Spring Harb Perspect. 2014; 4:1-27. <https://doi.org/10.1101/cshperspect.a019760>
6. Li Q, Yu C, Liu Q and Liu Y. Central nervous system cryptococcoma in immunocompetent patients: a short review illustrated by a new case. Acta neurochirurgica. 2010; 152(1):129-36. <https://doi.org/10.1007/s00701-009-0311-8> PMID:19404577
7. Lasso FA, Zamora-Bastidas TO, Potosí-García JA, Díaz-Idrobo B. Cryptococcal cerebellitis in no-VIH patient. Colombia Médica. 2017; 48(2): 94-7.
8. Nakwan N, Songjamrat A, Tungsinmonkong K and Nakwan N. Cerebellar cryptococcoma in an immunocompetent adult patient. Southeast Asian J Trop Med Public Health. 2009; 40(5):1034-1037.
9. Jiang YG, Xiang B, Peng Y, Koussougbo KS. Cerebellar Cryptococcoma in Immunocompetent Patients. Neurosurgery Quarterly. 2012; 22(4):266-270. <https://doi.org/10.1097/WVNO.0b013e318256925b>
10. Zheng LX, De-Zhi K. Multiple cerebellar abscess and pneumonia caused by Cryptococcus in an immunocompetent adult patient. Pakistan Journal of Medical Sciences. 2011; 27(2).
11. Liu BX, Dai XJ, Liu H, Gong HH, Wang YXJ and Zhang LL. Cerebellar cryptococcosis characterized by a space-occupying lesion in an immunocompetent non-HIV patient. Neuropsychiatric disease and treatment. 2015; 11:21. <https://doi.org/10.2147/NDT.S75432>
12. Mukhopadhyay S L, Kumar M, Chickabasaviah Y T, Bahubali V K H, Raj PA, Bharath R D, Siddaiah N. Cerebellar cryptococcoma due to Cryptococcus gattii VGI; a rare and first report from India. JMM Case Reports. 2015; 2(3). <https://doi.org/10.1099/jmmcr.0.000052>
13. Perry A, Rosenblum MK. Central Nervous System. In: Goldblum, Lamp, Mckenny, Myers (editor). Rosai and Ackerman. Surgical Pathology. Eleventh edition. Philadelphia: Elsevier Saunders, 2018:1948-78.
14. Xia S, Li X and Li H. Imaging characterization of cryptococcal meningoencephalitis. Radiology of Infectious Disease. 2016; 3:187-91. <https://doi.org/10.1016/j.ijrid.2016.05.003>
15. Pappas PG, Perfect JR, Cloud G A, Larsen R A, Pankey G A, Lancaster D J, Handerson H, Kauffmann CA, Haas DW, Saccante M, Hamill R J, Holloway MS, Warren MR and Dismukes WE. Cryptococcus in Human Immunodeficiency Virus-negative patients in the era of effective azole therapy. HIV/AIDS. 2001; 33:690-9. <https://doi.org/10.1086/322597>