

Laryngotracheal Stenosis: A Retrospective Analysis of Their Aetiology, Diagnose and Treatment

Nikola Nikolovski*, Gabriela Kopacheva-Barsova, Ana Pejkovska

University Clinic for Ear, Nose and Throat, Faculty of Medicine, Ss. Cyril and Methodius University in Skopje, MK 1109, Republic of Macedonia

Abstract

Citation: Huriyati E, Darwin E, Yanwirasti Y, Wahid I. Laryngotracheal Stenosis: A Retrospective Analysis of Their Aetiology, Diagnose and Treatment. Open Access Maced J Med Sci. 2019 May 31; 7(10):1649-1656. <https://doi.org/10.3889/oamjms.2019.339>

Keywords: Laryngotracheal stenosis; Etiology; Diagnose; Treatment; Postintubation

***Correspondence:** Nikola Nikolovski. University Clinic for Ear, Nose and Throat, Faculty of Medicine, Ss. Cyril and Methodius University in Skopje, MK 1109, Republic of Macedonia. E-mail: drnikolanikolovski@yahoo.com

Received: 16-May-2019; **Revised:** 21-May-2019; **Accepted:** 22-May-2019; **Online first:** 26-May-2019

Copyright: © 2019 Nikola Nikolovski, Gabriela Kopacheva-Barsova, Ana Pejkovska. This is an open-access article distributed under the terms of the Creative Commons Attribution-NonCommercial 4.0 International License (CC BY-NC 4.0)

Funding: This research did not receive any financial support

Competing Interests: The authors have declared that no competing interests exist

BACKGROUND: Laryngotracheal stenosis created as a result of a long-term consequence of prolonged endotracheal intubation is a state of narrowing of the airway, which, depending on the degree of narrowing, can be from an asymptomatic to a potentially life-threatening condition.

AIM: To understand the severity of postintubation laryngeal stenoses, their diagnosis, endoscopic evaluation, endoscopic and surgical treatment and their success in a multi-year period realised in the University Clinic for Ear, Nose and Throat in Skopje, Macedonia.

MATERIAL AND METHODS: Through a proper history, physical examination, endoscopic and imaging evaluation of the ear, nose and throat in the Clinic, in the period of 8 years, that is, from 2010 to 2017, laryngotracheal stenosis was diagnosed in a total of 36 patients. During this period, 24 male or 66.7% were diagnosed, as were 12 female subjects or 33.3% of diagnosed patients. Of the analysed total of 36 patients, by Mayers cotton classification, 14 or 38% are patients with grade 1 stenosis, 5 or 13% are grade 2, and 10 or 27% are grade 3, while 7 or 19% are grade 4 stenosis

RESULTS: It is essential for all laryngotracheal stenoses to exist or to provide a breathing path that depends on the degree of stenosis. Further course of treatment also depends on the characteristics of the stenotic zone that is visualised endoscopically. At the Clinic for ear nose and throat in Skopje, endoscopic treatment was performed through a series of dilatations within 21 patients, or 58 % of the examinee, as well as the administration of mitomycin and corticosteroids in 21 patients or 52% of the examinee. The applied actions and procedures had shown 100% outcome on stenoses not longer than 2 cm, who have a fibro-inflammatory scar and by Myer cotton classification 1 and second stadium. Patients that have failed endoscopic treatment, surgical treatment are a method of choice. Surgical treatments have been performed in 4 patients with realised end of the anastomosis, and 3 cryotracheal reconstructions, which is decannulated. After an extensive follow-up of these patients, depending on their condition, multiple endoscopic evaluations have been decannulated to 21 patients or 58%, and after a series of multiple unsuccessful endoscopic treatments, a condition with tracheal stoma occurs in 8 patients or 22% of the examinee.

CONCLUSION: The observations indicate that the methods used, which are explained previously, have good effects in terms of the achieved outcomes. Due to limited resources, it is necessary to improve new methods and approaches in the treatment of stenoses, depending on their type and severity, thereby improving patient outcomes. Also, to reduce laryngotracheal stenoses, appropriate tubes and low pressure of the caffeine in the endotracheal tubules should be used.

Introduction

Laryngotracheal stenosis is a disease that is characterised by mucosal inflammations and bounded fibrosis resulting blockage of the upper airway and life treating conditions. Cricoid is the narrowest portion of the larynx. The first tracheal ring is partially anchored to the lower limit of the cricoid cartilage and, sometimes, can be attached to it [1]. Small changes of the diameter of the laryngotracheal stem and length of

the narrowed segment create important variation in airflow that results in immediately progressive dyspnea requiring urgent interventions [2]. Symptoms occurred when airway change of 30%, and distress of change of 80%. This condition affects patients their ability to; breathe, modification of voice or swallowing problems [3].

It is serious problems that affect adult and children. Treatment depends on the aetiology of the occurrence. It is often caused by autoimmune diseases, infection, scar formation post-intubation or

post tracheotomy and idiopathic causes.

The most common cause remains mechanical ventilation. As one of the most common causes, mechanical ventilation leads to mucosal injuries through a cuff pressure ischemic damage to the trachea, post tracheostomy injury or combination of the two. High pressure of balloon cuff or tube surpasses the capillary pressure, with loss of the regional blood flow, leading to ischemia or necrosis. Local ischemia promotes and stimulates fibrinolytic pathway, which generates the proliferative phase characterised by angiogenesis, collagen deposition and granulation tissue formation, and the third phase maturation and remodelling phase with the creation of membranous web-like stenosis.

Idiopathic subglottis stenosis is defined as laryngotracheal stenosis of unknown origin. Diagnose is made as exclusion and lack of history of traumatic intubation, tracheostomy and negative serologic autoimmune markers. It is a rare, fibroinflammatory process which leads to narrowing the airway of the subglottis, first and the second tracheal ring. When the patient is evaluated by the laryngologist, the scar is mature, circumferential, laryngotracheal stenosis. Mostly affected by woman, probably because of the anatomic predisposition of smaller female subglottis, frequent coughing causing mechanical trauma, subtle vascular disease. It a slowly progressive condition, mild symptoms present in mouths [4], [5], [6].

Autoimmune laryngotracheal stenosis – It's not an isolated phenomenon; it's a present of other organ system involvement. It is known as Wegener granulomatosis, relapsing polychondritis, sarcoidosis. Wegener granulomatosis refers to pulmonary disease. Necrotising vasculitis, cANCA positive and renal disease. Autoimmune laryngotracheal stenosis can have two stages. The first stage is inflammatory is distinguished with erythematic, oedema of the epithelium and granulation tissue. The second stage is mature scar marked as rigid white scar with cicatrice line of fibrosis. If the autoimmune disease is already diagnosed, that the appearance of laryngotracheal stenosis is as a result of inflammatory exacerbation in the larynx. The follow-up course and treatment depend on whether the pre-diagnosed autoimmune disease has been diagnosed or not [7], [8], [9].

Congenital subglottic stenosis defined as the diameter of the cricoid of less than 3.5 mm. Congenital subglottic stenosis is the third most common congenital anomaly of the larynx, which accounts for 15% of all cases. Etiopathogenesis: as a defect in the formation of cone elastics and cricoid cartilage, creating an elliptical cricoid, flaccid cricoid, or excessively submucosal cough. Congenital subglottic stenosis can be classified into two types: Membranous congenital subglottic stenosis (granulation tissue, fibrous connective tissue, hyperplastic submucosal glands.) This type is the

most common and mild form of congenital subglottic stenosis. The cartilaginous congenital subglottic stenosis results from abnormal cricoid cartilage.

This condition is the most common laryngeal anomaly that requires tracheotomy in infants. Male children are affected twice as often as females [10], [11], [12].

Material and Methods

The observation period lasted from 05.2012 until 05.2018 and included a patient who was treated in the University Clinic in Skopje, Republic of Macedonia.

Prolonged analysis from their diagnosis to the level corresponding to subsequent treatment was carried out in a total of 36 patients.

Results

In the following diagram, it is demonstrated the percentage of a patient with laryngotracheal stenosis that has been examined. Of them infant, toddlers and preschooler represent 5 patients or 20%, on the other hand, children and adolescent 9 persons or 37% others represent adults and seniors.

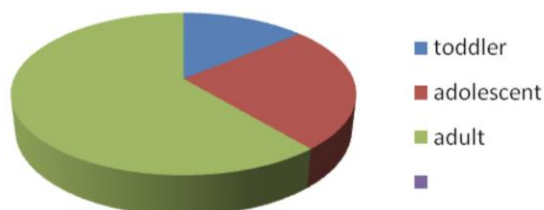


Figure 1: Patient with laryngotracheal stenosis

Evaluation of on each is done, including their medical data (age and sex, aetiology, morphologic description of the laryngotracheal stenosis, degree of airway narrowing, location, transitions zone abruptness of stenosis. Clinical presentation, laboratory results, imaging, treatment, diagnosis, complication and hospitalisation time). All age group are included.

Cough is one of the most common symptoms refer to 83%, as well as the history of intubation 66%, and change in voice 61%. Patients with acquired stenosis have been diagnosed for several days to 10 years or more after the initial injury.

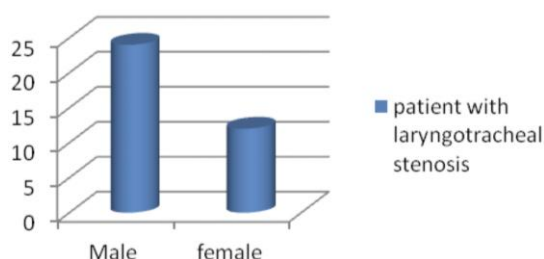


Figure 2: Gender distribution

The majority of cases have been diagnosed within a year. Many patients before the discovery of stenosis are diagnosed as asthma and recurrent bronchitis. A high index of suspicion is justified by the onset of respiratory symptoms and indications.

Table 1: The symptoms that mostly occur in our examinees

Difficulty swallowing	6 m-9m	20	55 %
Change in voice	4 m-6m	22	61 %
reflux	5 m	7	19 %
Degree of limitation of daily activity	5 m	13	36 %
Degree of chest recession on breathing	5 m	18	50 %
dyspnea	3m-6 m	15	41 %
Vacuties	2 years	2	5 %
History of intubation	3m- 6m	24	66 %
Verified Wegener	1	1	2 %
Recurrent bronchitis	6m-9 m	10	27 %
Asthma	6m-9m	15	41 %

The manifestations of congenital subglottic stenosis usually occur in the first few months of life. Patients with mild congenital stenosis are usually asymptomatic, and they are diagnosed after severe intubation or while undergoing endoscopy for other reasons. Stenosis is usually not evident until the child develops an acute inflammatory process, which further compromises the subglottis. The clinical presentation of a child during these periods is no different from infectious laryngotracheobronchitis (large). Biphasic stridor with or without symptoms of respiratory distress is the most common symptom of presentation. A child may have a fake cough, but the cry is usually normal. Anatomically highly susceptible to congenital subglottic stenosis, these symptoms are repeated or prolonged after the normal duration of the infectious break (1-3 d). Asymptomatic children who are difficult to intubate, extubate, or debunk represent another clinical scenario that causes suspicion of congenital stenosis. Children with Down syndrome are at increased risk of having congenital subglottic stenosis and can be presented in this way.

According to the way of development, the most common aetiology is posted polytraumatic condition in a total number of 24 patients or percentage 66% of the 27% occurs post-intubation or 10 patient and 38% occur post tracheotomy. Other conditions are presented, but there are in much smaller percentages. In Table 2 is presented the most common aetiology. Accurate setting of the aetiology of the incidence of laryngotracheal stenosis will lead to an accurate diagnosis.

Table 2: The most common aetiology

Aetiology	Total number	Percentage
post-polytraumatic	24	66 %
Post combustion	4	11 %
post suicidal	3	8 %
Congenital	2	5 %
Idiopathic	2	5 %
Inflammatory conditions	1	2 %
post-intubation	10	27 %
post – tracheostomy	14	38 %

Investigations

Laboratory investigations in the absence of a history of previous trauma or when suggested by other findings, evaluate for inflammatory or infectious causes, including the following: granulomatosis Wegener, recurrent polychondritis, syphilis, tuberculosis, sarcoidosis, leprosy, diphtheria, Scleroma and presence of antibodies.

Pulmonary function test

First pulmonary function test is spirometry to acknowledge reduce air volume or airflow.

Flow-volume loops may help monitor restenosis following the intervention.

Imaging Investigations

Standard chest radiography can often provide a great deal of information regarding the flow of air through the trachea and the location and degree of stenosis, especially anteroposteriorly.

MRI is useful in assessing the length and width of stenotic regions using coronary and sagittal cross-sections.

CT scanning is not as useful as MRI, because its views are usually only in the axial plane. CT cannot, however, differentiate between the true lumen and the overlying secretions, which introduces a defect in the presence of blood, mucus and crusting. The degree of stenosis can be underestimated on CT scan because the imaging is a form of sampling unless fin cuts are made ½ mm with sagittal and/or coronal reconstructions may be useful, the apex of the stenosis can be missed. CT scans help to confirm airway compromise and act as a guideline to its severity.

Endoscopy is the main tool of evaluation and treating laryngotracheal stenosis. It establishes endoluminal therapy, observation of laryngotracheal dynamic and direct visualisation of luminal pathology.

Flexible endoscopic examination of the upper aerodigestive tract will allow assessment of vocal cord function, evidence of reflux, demonstrate pooling of secretions and may also determine the site and degree of airway stenosis. A detailed assessment of vocal cord function and swallowing is vital if laryngotracheal surgery is to be considered. Visualization of the larynx with a flexible or rigid telescopic (90- or 70-degree range) in the clinic is

crucial for the assessment of airway lesions. Flexible bronchoscope allows evaluation of the dynamic airway, the trachea and bronchi. But when flexible bronchoscope is placed through narrow stenosis, the patient airway becomes obstructed.

Table 3: Presentation of the degree of airway narrowing

Grade I	Obstruction from 0-50%	14	38%
Grade II	Obstruction from 51-70%	5	13%
Grade III	Obstruction from 71-99%	10	27%
Grade IV	No lumen 100%	7	19%
	Grading	Patient	Total

Suspension laryngoscopy allows the use of rigid optical endoscopes and flexible bronchoscopes to access the airway. Advantages allow two hands-frees for instrumentation; the patient is sedated, a series of investigations can be made, dilators, laser, stent, can be inserted and used with relative ease. Measurements required: location of the stenosis in relations of the vocal fold and the light of stenoses segment.

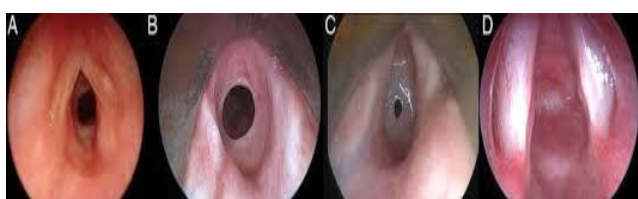

Figure 3: Classification of the laryngotracheal stenosis

Leight of stenoses segment is measured by gentle traction of the endoscopic vision first distal level of the stenosis then proximal end mark with pen allowing biaxilar calibration and radial extent of the area being measured.

Table 4: Length of laryngotracheal stenosis

Grades	McCaffrey classification of the laryngotracheal stenosis, based on their light	Patient	Total
Grade 1	Subglottic or tracheal lesion < 1 sm	15	41 %
Grade 2	Subglottic lesion > 1 sm	4	11 %
Grade 3	Subglottic/tracheal lesion without glottis	12	33 %
Grade 4	Glottis lesion	5	13 %

A multidimensional system is necessary for the detection of laryngotracheal systems including the degree of airway narrowing, vertical light, Four types of consistency (soft, hard, cartilaginous, and mixed), Location (glottis, subglottic area and upper trachea).

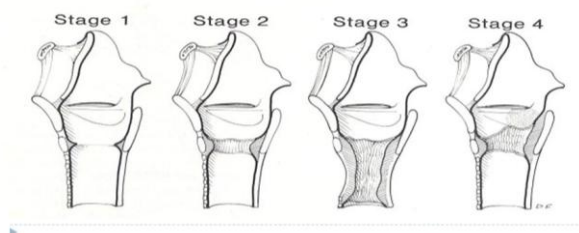


Figure 4: McCaffrey classification system (1992)

In the follow-up tables, our aim to show the multidisciplinary approach in measuring the laryngotracheal stenosis, in these tables, by Myer cotton classification most common is patient with grade I and 38%. On the other hand, Mc Caffey classifications 41% are presented with grade one. Based on their location, subglottis and upper trachea are the most common location in developing laryngotracheal stenosis.

Table 5: Location of laryngotracheal stenosis

Subsite location	Patient	Total
Glottis	5	13 %
Subglottic area	12	33 %
Upper trachea first third	16	44 %
Upper trachea second third	0	0 %
Two locations or more	3	8 %

Treatment

There are 3 types of treatment categorised: 1) endoscopic dilatation of the tracheal stenosis; 2) endoscopic resection of the stenosis (medical therapy after surgery); and 3) open surgery resection end to end anastomosis.

The principle of endoscopic dilatation is maximal preservation of the tracheal mucosa and minimal trauma during procedure. Evaluation of the location and severe in stenosis, the inter arytenoid area for stenosis or long dual fissures and the position of the vocal cords is mandatory.

Transoral exposure of the tracheal scar using rigid tracheobronchoscopy is necessary for balloon dilatation or controlled radial expansion device. Airway balloons are passed through the rigid endoscope, expanding balloon is placed in the middle of the stricture. As the balloon expands, the energy is transmitted of the area of least resistance. The balloon is inflated in enlargement with periodical collapsing to observe progress. Periods of appearing for about 4minuts occur between balloon dilatation intervals. Desideration may occur. Patient with fibro-inflammatory stenosis required fewer procedures rather than mature stenosis.

The follow-up and several endoscopic interventions can take up to 8, for 3 years result in longer intervention free trials. Most patients are high surgical risk patient, and in the poor general condition, it allows minimal invasiveness.

Disadvantages' is associated with a higher rate of recurrence, restenosis and repeated surgery.

In post tracheostomy stenosis. The stricture is often anterior, sparing the posterior membranous portion of the airway. Because of that balloon dilatation is often noneffective.

Complications that can occur during balloon dilatation is no complications, perforation, wall rupture, postoperative airway obstruction oedema, overtreatment and restenosis, postoperative bleeding,

aspiration pneumonia, pneumothorax.

In table 6 shown, our goal is to draw the treatment of the balloon dilatation and the best outcome from it.

Table 6: Treatment of the balloon dilatation and the best outcome from it

classifications	Balloon dilatation	Radial Incision (3, 6, 9, 12)	applicati ons Intra-steroids	Application of Mitomycin C	No. of endoscopi c interventi ons	of decann ulation	stoma
Myer cotton scale	Grade I	14	14	14	4	14	0
	Grade II	5	5	5	6	5	0
	Grade III	10	10	10	8	2	8
	Grade IV	0	0	0	0	0	7
Scar type	Fibro inflammatory scar formation	19	19	19	6	19	0
	Mature scar	17	17	17	9	2	0
location	Subglottis	12	12	12	64	6	6
	Upper trachea	16	16	16	96	10	6
Vertical leight	grade 1	15	15	15	5	15	0
	Grade 2	4	4	4	6	6	0
	Grade 3	12	12	12	6	12	12

It can be said that the best treatment of balloon dilatation has fibro-inflammatory stenosis with a 100% outcome, as well as grade 1 and 2 of laryngotracheal stenosis. Decanilman is produced after more permanent treatments with a balloon dilatator, on the other hand, Grades 3 and 4 and patients who cannot be realised balloon dilatation open surgery is the option of treatment.

Applications of intralesional steroid injections have shown to have benefited in Wegener granulomatosis and sarcoidosis also it has a positive impact on fibro-inflammatory laryngotracheal stenosis. Mitomycin C is a chemotherapeutic agent that prevents collagen synthesis and scar formation.

In the last few decades, the increased use of carbon dioxide (CO2) laser have been seen, which offers advantages of delayed formation and maturation of collagen in the wounds, which allows for re-epithelialization before the formation of a scar and minimal tissue injuries. The laser allows precise control of areas whose scars are removed and excused hemostasis from preserving the mucosa used for reparation. Negative treatments with burns and injury from laser CO2 rays as for the surgeon and hospital staff, thermal injury, which may result in perioperative oedema and postoperative scarring of the headache.

The idea of placing a stent is to support the airway wall, restore airway patency. Silicone stents are effective in splitting the laryngotracheal stenosis for palliation airway narrowing in nonsurgical candidates.

Stents are placed in stenosis greater than 70% and no longer than 5 mm for 4-6 weeks to aid healing. Disadvantages are granulation tissue formation of the proximal and distal end of the T-tube and stent.

An open approach is indicated after the failure

of the endoscopic approach when the degree of stenosis is severe, or factors are unfavourable for this approach. Choosing the specific technique is based on the length of the resection, the need for cartilage tissue and the need for mucosal coverage, placement of a stent is necessary for some procedures. In advanced stages of the laryngotracheal stenosis, especially in the matriculated stenosis, the treatment of choice is resection and end to end anastomosis.

Table 7: The modalities of the operative treatment and their outcome

classifications	no.intervention failed endoscopy	Stent	Cricotracheal resection	End to end anastomosis	decannulation	stoma	Contracture of stoma
Myer cotton maturati on	Grade III	10	3	1	2	3	7
	Grade IV	7	4	2	2	4	3
	Mature scar	17	7	3	4	7	10
Locatio n	Subglottis	6	3	3	0	3	3
	Upper trachea	6	4	1	4	4	2
Vertical leight	Grade 3	12	6	1	5	6	6
	Grade 4	5	1		0	1	4

Pediatric laryngotracheal stenosis is researched all rib graft if possible, tracheal or cricotracheal resection and an end to end anastomosis. On the other hand, adult laryngotracheal stenosis treatment options are tracheostomy, tracheal resection or cricotracheal resection associated with great morbidity and mortality. Anterior and/or posterior cricoid split with stenting and graft is rarely used in our country.

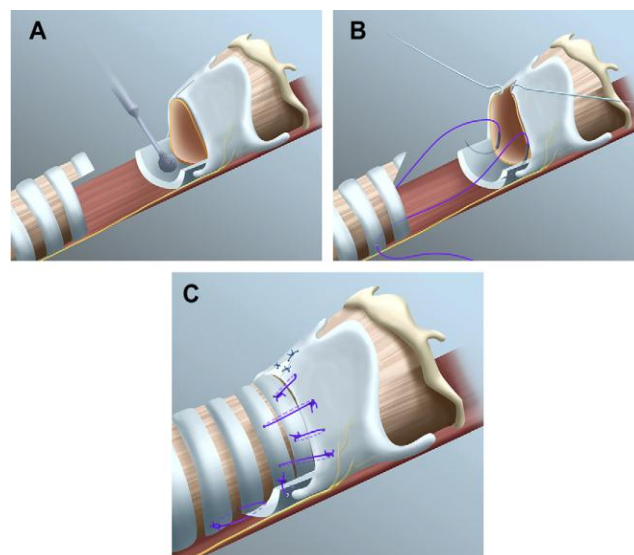


Figure 5: Cricotracheal anastomosis

Tracheal resection is preserved for a patient with a long segment complete or complete collapse of the cartilaginous tracheal support. Cricotracheal resection is a procedure that requires the removal of subglottic scar tissue, with anastomosis of a healthy trachea with the healthy larynx. The procedure is consisting of elevation of perichondrium from cricoid

cartilage anteriorly to avoid recurrent nerve injury, removal of subglottic stenotic tissue, removing soft tissue in posterior cricoids. Laryngofissure may be made to increase the lumen in the laryngeal box, a tracheal submucosal flap in the treatment of posterior subglottic stenosis, full reconstruction with end-end anastomosis.

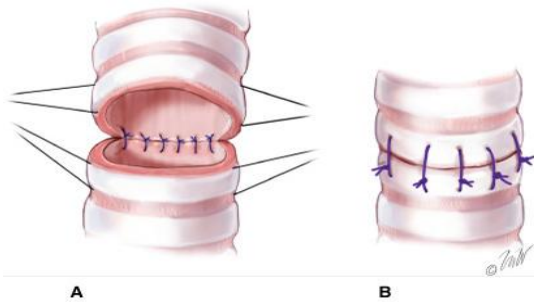


Figure 6: End to end anastomosis

Over resection of the anterior tracheal rings during tracheostomy, at decannulation can cause scarring and contracture of the stoma site. It looks like a lambda shaped stenotic deformity tie the lateral regions fragment resulting wound contracture. Endoscopic is more recommended in this condition rather than open tracheal resection and anastomosis.

Patients with grade 3 and 27% of respondents are on 30% of them subject to laryngotracheal resection with excellent outcome, the remaining patients due to their accompanying comorbidities are with a tracheostomal aperture or the remaining 70%.

Table 8: The outcome of the treatment

	Balloon dilatation	Open surgery
Curative	21	7
Improvement	0	0
Failure	8	0

Patients with grade 4 and 19% of respondents use 57% of them subject to laryngotracheal resection with excellent outcome, the remaining patients due to their accompanying comorbidities with a tracheostomal aperture or the remaining 43%.

Table 8: Postoperative complications in the patient

Type of complication	Number of complications	percentage
Granulations	10	27 %
Restenosis	7	19 %
Wound infection	0	
Dysphonia	7	19 %
Sepsis	0	
Detachment of anastomosis	0	
Injury of the recurrent nerve	0	
Bleeding / hematoma	0	
Stent migration	4	11 %
Death	0	0

Mature scar distinguishes itself with a positive treatment of 70% about its total number.

Subglottic/tracheal stenosis that do not involve glottis or grades 3 at McCaffery classification is 12 patients. Of them, 6 patient laryngotracheal

resection and anastomosis were performed or 50% leading to decannulation in all of them. Some recommend prolonged postoperative neck flexion with the tongue or chin-to-breast sewing in the end-to-end anastomosis.

In the postoperative treatment: antibiotics are given for 1-3 weeks, depending on the degree of recovery and general health of the laryngotracheal mucous membrane. According to the surgical intervention administration of antibiotic is needed. Authors advocate the elimination of antibiotics when a stent is used. Intensive anti-reflux therapy is needed Injecting steroid sprays (not nasal sprays) are sometimes useful for reducing the granulation tissue of the surgical wound.

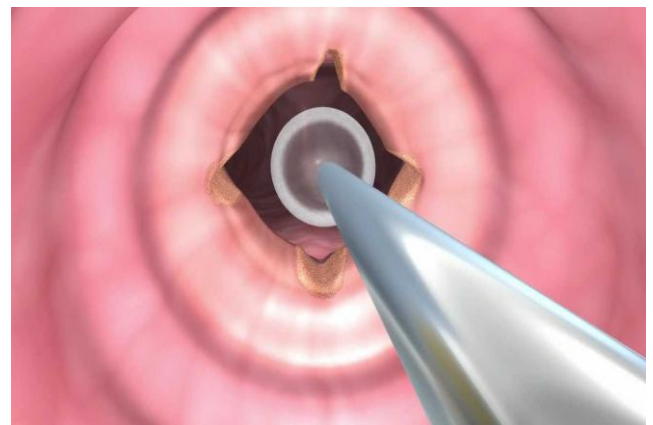


Figure 7: Balloon dilatation with radial incisions

After 6 weeks, control is taken to determine the condition of treatment and the need for further procedure. Whenever is required or not, tracheostomy was implemented.

Some authors want immediate extubation after reparation; some support 1-2 days of postoperative intubation in intensive care units; and some require extubation in the operating room, rather than in intensive care units.

Discussion

These evidence-based procedures made it possible that most patients required open surgery can be managed with airway augmentation rather than resection [13], [14].

Assessments and initial endoscopic treatment provide beneficial information in recognition of the degree of tracheal cartilaginous support and carefully chosen patients in whom tracheal resection could be acknowledged [15]. We should mention that active obstructive autoimmune inflammatory disease under

any conditions should not undergo open surgical intervention because of its ability to expand. Only intralesional steroid injection is replicated.

Follow-up is recommended at least 1-2 years of evaluation postoperatively as cicatricial changes continue to be remodelled and matriculated. Follow-ups included: symptomatic and/or flow-volume estimates loop, imaging in suspicious relapses, endoscopy before decannulation if tracheotomy is present.

Out of the total number of respondents 21, in the following table 8, they were decannulated from a total of 36 or 77 per cent, with successful treatment for the treatment of these patients.

Postoperative complications can occur. The most common complication is granulation in 27 %, followed by restenosis and dysphonia. Stent migration is present in 57% or 4 patient of the total number of the patient, whose stent is set or 7 patients.

Another complication is not shown in our examinee.

In conclusion, endoscopic treatment is minimal invasive allow restoration of vocal function to a sizable proportion and decannulation can occur during the initial visit. It's a treatment of intraluminal inflammatory process Intra steroid, balloon dilatation and reduction of granulation without open surgical intervention can be an effective treatment for acute post-intubation airway stenosis.

Movement of the tube superiorly, inadequately high tube placement, granulation tissue is some of the causes of tracheostomy tube injuries that cause traumatic laryngotracheal stenosis. These events can lead to mucosal ulceration, perichondritis, chondritis and cartilage necrosis [16].

The spectrum of injuries depending on their depths can cause mucosal injuries to full thickness injuries inducing cartilage

It should be mention that active obstructive autoimmune inflammatory disease under any conditions should not undergo open surgical intervention because of its ability to expand. Just intralesional steroid injection and follow up treatment

Patient with laryngotracheal stenosis generates more negative intrathoracic pressure due to their increased inspiratory force, potentiating reflux after the development of laryngotracheal stenosis.

A multidisciplinary approach is recommended, as the decision for a specific intervention is guided by the urgency of each patient and demands a high degree of competence and collaboration between otolaryngologist, interventional pulmonologists and thoracic surgeons

Treatment indices are designed to improve the compromised airway and progress to decay. Rapid intervention before forming contracture or

cartilage damages is the preferred method of choice in early diagnostics.

To prevent the formation of subglottic stenoses, the appropriate size and technique for endotracheal intubation are recommended. Prolonged endotracheal intubation of more than 7-10 days is associated with a high-risk factor for laryngotracheal stenosis.

A highly set tracheostomal opening results in a higher risk of laryngotracheal stenosis.

Higher pressures on cuffs lead to increased ischemia on the mucous membrane of the laryngotracheal stem and thus result in a higher percentage of stenos [17], [18].

References

- Grillo H, Donahue D, Mathisen D, Wain J, Wright C. Postintubation tracheal stenosis: treatment and results. *J Thorac Cardiovasc Surg.* 1995; 109:486-93. [https://doi.org/10.1016/S0022-5223\(95\)70279-2](https://doi.org/10.1016/S0022-5223(95)70279-2)
- Myer C, O'Connor D, Cotton R. Proposed grading system for subglottic stenosis based on endotracheal tube sizes. *Ann Otol Rhinol Laryngol.* 1994; 103:319-23. <https://doi.org/10.1177/000348949410300410> PMID:8154776
- Spector G. Developmental anatomy of the larynx. In: Ballenger J, editor. *Diseases of the Ear, Nose, and Throat.* Philadelphia: Lea & Febiger, 1984.
- Szmuk P, Ezri T, Evron S, Roth Y, Katz J. A brief history of tracheostomy and tracheal intubation, from the Bronze Age to the Space Age. *Intensive Care Med.* 2007. <https://doi.org/10.1007/s00134-007-0931-5> PMID:17999050
- Evans J, Todd G. Laryngo-tracheoplasty. *J Laryngol Otol.* 1974; 88:589-97. <https://doi.org/10.1017/S0022215100079147> PMID:4422396
- Monnier P, Lang F, Chapuis G. Partial cricoid resection with primary tracheal anastomosis for subglottic stenosis in infants and children. *Laryngoscope.* 1993; 103:1273-8. <https://doi.org/10.1288/00005537-199311000-00011> PMID:8231582
- Cosano Povedano A, Munoz Cabera L, Cosano Povedano F. Endoscopic treatment of central airway stenosis: five year's experience. *Arch Bronconeumol.* 2005; 41(6):322-7. <https://doi.org/10.1157/13076000> PMID:15989889
- Eliachar R, Eliachar I, Esclamado R, Gramlich T, Strome M. Can topical mitomycin prevent laryngotracheal stenosis? *Laryngoscope.* 1999; 109:1594-600. <https://doi.org/10.1097/00005537-199910000-00009> PMID:10522927
- Miller M, Hankinson J, Brusasco V. Standardisation of Spirometry. *Eur Respir J.* 2005; 26:319-38. <https://doi.org/10.1183/09031936.05.00034805> PMID:16055882
- Nouraei SAR, Giussani DA, Howard DJ, Sandhu GS, Ferguson C, Patel A. Physiological comparison of spontaneous and positive - pressure ventilation in laryngotracheal stenosis. *Br J Anaesth.* 2008; 101(3):419 -23. <https://doi.org/10.1093/bja/aen171> PMID:18577538
- Seegobin R, van Hasselt G. Endotracheal cuff pressure and tracheal mucosal blood flow: endoscopic study of effects of four

large volume cuffs. Br Med J. 1984; 288:965-8.

<https://doi.org/10.1136/bmj.288.6422.965> PMID:6423162
PMCID:PMC1442489

12. Grillo H. Complications of Tracheal Reconstruction. In: Grillo H, editor. Surgery of the Trachea and Bronchi. Hamilton: BC Decker Inc., 2003:483-97.

13. Langford C, Sneller M, Hallahan C, Hoffman G, Kammerer W, TalarWilliams C, et al. Clinical features and therapeutic management of subglottic stenosis in patients with Wegener's granulomatosis. Arthritis Rheum. 1996; 39:1754-60.

<https://doi.org/10.1002/art.1780391020> PMID:8843868

14. Marie J-P. Nerve Reconstruction. In: Remacle M, Eckel H, editors. Surgery of Larynx and Trachea. Berlin: Springer-Verlag, 2009:279-94. https://doi.org/10.1007/978-3-540-79136-2_24

15. Sarper A, Ayten A, Eser I, Demircan A, Isin E. Review of posttracheostomy and postintubation tracheal stenosis with special regard to etiology and treatment. The Internet Journal of Thoracic and Cardiovascular Surgery. 2002; (6)1.

<https://doi.org/10.5580/1616>

16. Oh SK, Park KN, Lee SW. Long-term results of endoscopic dilatation for tracheal and subglottic stenosis. Clinical and experimental otorhinolaryngology. 2014; 7(4):324.

<https://doi.org/10.3342/ceo.2014.7.4.324> PMID:25436054
PMCID:PMC4240492

17. Prasad KT, Dhooria S, Sehgal IS, Aggarwal AN, Agarwal R. Complete subglottic tracheal stenosis managed with rigid bronchoscopy and T-tube placement. Lung India. 2016; 33:661-3.

<https://doi.org/10.4103/0970-2113.192879> PMID:27890997
PMCID:PMC5112825

18. Madkour A, Elmansoury A, Elsharkawy S. Interventional bronchoscopy in the initial management of benign and malignant tracheal stenoses. Egypt J Bronchol 2015; 9:146.

<https://doi.org/10.4103/1687-8426.158049>