

# Correction of Upper Incisor Proclination by Applying Lingual Crown Torque with Pre adjusted Lingual Brackets in a Skeletal-Class III Patient – Case Report

Viet Anh Nguyen<sup>1\*</sup>, Nguyen Vu Thai Lien<sup>2</sup>, Vu Thi Nga<sup>3</sup>

<sup>1</sup>*Viet Anh Orthodontic Clinic, Nam Tu Liem, Hanoi, Vietnam;* <sup>2</sup>*Department of Pediatric Dentistry, Faculty of Dentistry, Hanoi University of Business and Technology, Hanoi, Vietnam;* <sup>3</sup>*Institute for Research and Development, Duy Tan University, 03 Quang Trung, Danang, Vietnam*

## Abstract

**Citation:** Nguyen VA, Lien NVT, Nga VT. Correction of Upper Incisor Proclination by Applying Lingual Crown Torque with Pre adjusted Lingual Brackets in a Skeletal-Class III Patient – Case Report. Open Access Maced J Med Sci. 2019 Dec 30; 7(24):4189-4193. <https://doi.org/10.3889/oamjms.2019.343>

**Keywords:** Lingual bracket; Lingual Crown Torque; Skeletal class III relationship

**\*Correspondence:** Viet Anh Nguyen. Viet Anh Orthodontic Clinic, Nam Tu Liem, Hanoi, Vietnam. E-mail: [nvatk16@gmail.com](mailto:nvatk16@gmail.com)

**Received:** 09-Sep-2019; **Revised:** 20-Nov-2019; **Accepted:** 21-Nov-2019; **Online first:** 15-Oct-2019

**Copyright:** © 2019 Viet Anh Nguyen, Nguyen Vu Thai Lien, Vu Thi Nga. This is an open-access article distributed under the terms of the Creative Commons Attribution-NonCommercial 4.0 International License (CC BY-NC 4.0)

**Funding:** This research did not receive any financial support

**Competing Interests:** The authors have declared that no competing interests exist

**BACKGROUND:** After levelling and alignment in skeletal Class III patients with upper anterior crowding, the upper incisors usually have excessive proclination. In these cases, the upper incisors' axial proclination need to be reduced to improve esthetics.

**CASE REPORT:** This case report presents an invisible orthodontic treatment of a 24-year-old adult female patient with skeletal Class III relationship, anterior crossbite, proclined upper incisors, and reduced incisor showing. Patients denied extraction and interproximal reduction. With multi-slotted lingual brackets and straight archwires, we applied lingual crown torque to upper anterior teeth to reduce axial proclination. The resulting uprighted position of upper incisors led to increased incisor showing. A good smile and stable occlusion were obtained after 15 months of active treatment.

**CONCLUSION:** The use of lingual brackets to apply lingual crown torque helps to reduce axial proclination and increasing upper incisor showing without interproximal reduction nor extraction in skeletal Class III patients with upper anterior crowding.

## Introduction

Since the first introduction of multilingual bracket system by K. Fujita in 1979 [1], lingual orthodontic treatment has become popular. Recent advances in lingual orthodontics include the transition from mushroom archwire to straight wire concept [2], [3], the use of multi-slot lingual bracket [4], [5], the application of self-ligating lingual brackets [6], [7], the customised lingual bracket, and individual robot-bending archwire [8]. The fifth generation of Dr Fujita's lingual brackets was the first lingual bracket with the multi-slot concept. Based on this concept, CLB lingual brackets was developed to have the additional advantages of the straight lingual archwire.

Skeletal Class III patients have proclined upper incisors due to the dentoalveolar compensation to the skeletal discrepancies. In compensation Class III cases with crowding, after levelling the upper arch with nonextraction approach, upper incisors usually have increased proclination. Also, the vertical maxillary deficiency accompanying with skeletal Class III may express as decreased upper incisor showing. By uprighting the upper incisors, orthodontists can increase the incisor display to create a better smile arc. In this case report, the authors applied lingual crown torque to upright the upper incisors, using preadjusted lingual appliances with straight tandem archwire mechanics.

## Case Report

### Diagnosis and Treatment Plan

A 24-year-old female patient presented to the author's clinic with the request to correct anterior crossbite using an invisible appliance. She also wanted to reduce upper incisor proclination and have more incisor showing on a smile without neither tooth extraction nor orthognathic surgery.

On clinical examination, she showed a straight profile with normal nasolabial angle and labiomental sulcus without facial asymmetry (Figure 1). On smile, she has reduced incisor showing with a flat smile arc. Intraoral examination revealed a crossbite involving the upper right central and lateral incisors, overerupted lower incisors and dental midline deviation. She had a Class I molar and canine relationship on the left, a mild Class II canine and Class I molar on the right.

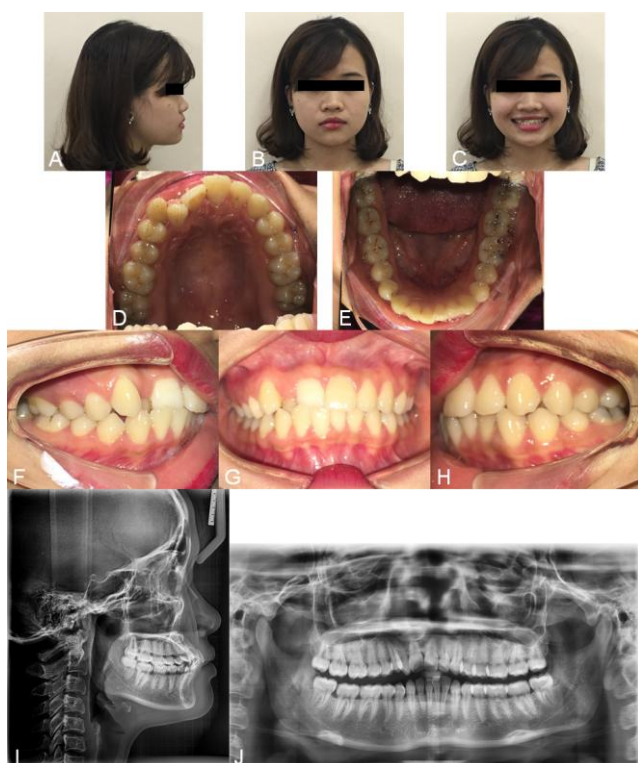


Figure 1: 24-year-old female patient with anterior crossbite and mild skeletal Class III relationship before treatment. A) Extraoral profile view; B) Extraoral straight view; C) Smile straight view; D) Maxillary occlusal view; E) Mandibular occlusal view; F) Intraoral right lateral view; G) Intraoral straight view; H) Intraoral left lateral view; I) Cephalometric radiograph; J) Panoramic radiograph

The panoramic radiograph revealed the presence of all teeth, including the third molars. She also had an impacted supernumerary tooth in the right central incisor region. Cephalometric analysis (Table 1) showed a mild skeletal Class III relationship (ANB =  $-1.8^\circ$ ) with prognathic mandible (SNB =  $85.5^\circ$ ) and horizontal growth pattern (FMA =  $16^\circ$ ). Both upper and lower incisors were proclined labial (U1-SN =

$124.1^\circ$  and IMPA =  $106.2^\circ$ ).

Table 1: Cephalometric Analysis

	Pretreatment	Post-treatment
SNA	$83.7^\circ$	$84.4^\circ$
SNB	$85.5^\circ$	$85.4^\circ$
ANB	$-1.8^\circ$	$-0.9^\circ$
FMA	$16^\circ$	$16.2^\circ$
U1-SN	$124.1^\circ$	$112.2^\circ$
Wit appraisal	$-0.9$ mm	$-1.9$ mm
IMPA	$106.2^\circ$	$104^\circ$
Interincisal Angle	$107.9^\circ$	$122.2^\circ$
L1-NB	$5.6$ mm	$5.9$ mm
U1 protrusion (U1-APo)	$9.3$ mm	$8.7$ mm
L1 protrusion (L1-APo)	$6.4$ mm	$6.0$ mm
Upper lip to E-line	$-2.2$ mm	$-1.4$ mm
Lower lip to E-line	$0.3$ mm	$0.7$ mm

The treatment objectives were to eliminate the anterior crossbite, level the curve of Spee, obtain normal overjet and overbite, correct the dental midlines, establish Class I molar and canine relationship, upright and extrude the upper incisors to reduce incisor proclination and increase incisor show. The patient was explained about the need for surgical removal of the supernumerary tooth but she denied this invasive surgery and accepting the risk of root resorption of adjacent teeth during orthodontic treatment.

After correcting the anterior crossbite and aligning the upper teeth without extraction of premolars, upper incisors flaring would be inevitable. There were three possible treatment options to reduce upper incisor proclination. The first option would be the interproximal reduction and anterior teeth retraction. The second option would involve third molars extraction and the entire arch distalization. The third option would be uprighting the upper incisors by applying lingual crown torque. Because the patient wanted neither tooth extraction nor tooth stripping, she chose the third option.

### Treatment progress

CLB lingual brackets were bond indirectly in both arches using a thermoplastic splint. A large .012" Ni-Ti continuous straight archwire was inserted in the upper arch, and a medium wire of the same type was inserted in the lower arch. Bite turbos were placed on lower molars for allowing the upper right incisors to move forward. In the next months, archwire size was increased to .014" and .016" Ni-Ti. Bite turbos were gradually grinded at each appointment. After four months of levelling, the anterior crossbite was eliminated but the inclination of upper right lateral incisors had not been corrected, it's root was still in the palatal side (Figure 2). Two months later, .018" x .018" stainless steel archwires were inserted to both gingival and occlusal slots in both arches. Labial brackets were bonded to upper and lower molars to control the molars. After another two months, .018" x .025" stainless steel archwire was inserted to the occlusal slots of upper incisor and canine brackets for torque control.

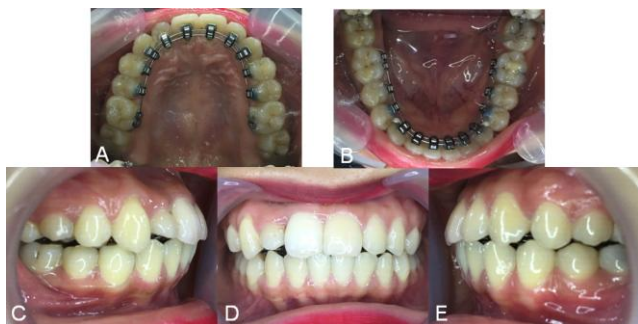

Figure 2: After four months of levelling with lingual appliances and nickel-titanium archwires, the anterior crossbite was eliminated but the upper right lateral incisors had excessive proclination; A) Maxillary occlusal view; B) Mandibular occlusal view; C) Intraoral right lateral view; D) Intraoral straight view; E) Intraoral left lateral view

Two months later, the upper right lateral incisor's torque was improved (Figure 3). At this time, the upper incisors still had excessive proclination.

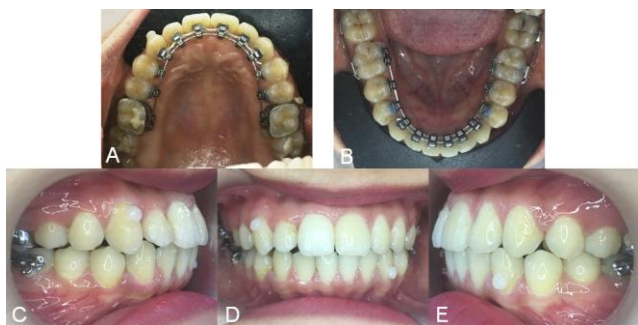

Figure 3: Progress after 10 months of treatments. The upper right lateral incisor's torque was improved. Composite buttons were bonded for using intermaxillary elastics; A) Maxillary occlusal view; B) Mandibular occlusal view; C) Intraoral right lateral view; D) Intraoral straight view; E) Intraoral left lateral view

Both upper main archwire and anterior segmental wire were applied 15° lingual crown torque in the anterior teeth to further upright them. The main archwire had detorque bends distal to the canine to maintain the torque of buccal segments (Figure 4).




Figure 4: A) The main archwire has 15° lingual crown torque in the anterior teeth; B) Zero torque of the main archwire in the buccal segments

Steel ligature was used for full engagement of the archwires to the bracket slot. Composite buttons were bonded to lower canines and upper right canine for Class III elastic on the right side and anterior diagonal elastic. After three months of applying lingual

crown torque, the upper incisors' proclination was improved (Figure 5). Intermaxillary elastics continued to be used for midline correcting and settling the occlusion.

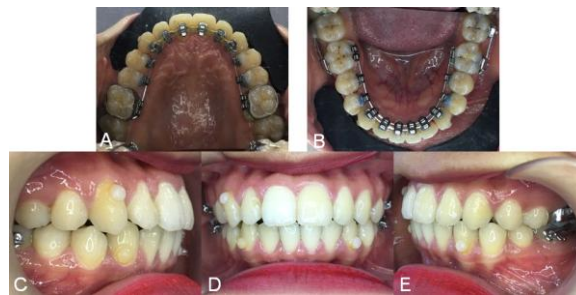

Figure 5: After three months of inserting main archwire and anterior segmental wire with - 15° torque to upper anterior brackets, the upper incisors were uprighted; A) Maxillary occlusal view; B) Mandibular occlusal view; C) Intraoral right lateral view; D) Intraoral straight view; E) Intraoral left lateral view

### Treatment result

Class I canine and molar relationships were established with normal overjet and overbite (Figure 6). The anterior crossbite was eliminated, dental midlines of both arches were straightened, the curve of Spee was levelled. The smile arc became more curved, and the upper incisor show upon smile was increased. The patient satisfied with the treatment results.

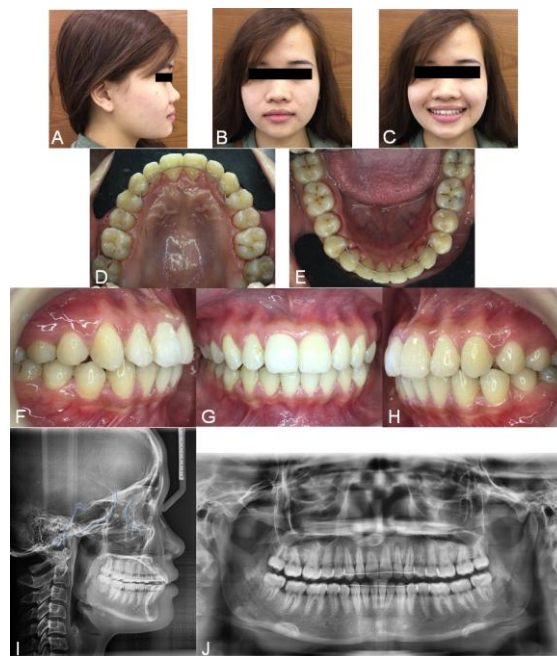


Figure 6: Patient after 14 months of treatment; A) Extraoral profile view; B) Extraoral straight view; C) Smile straight view; D) Maxillary occlusal view; E) Mandibular occlusal view; F) Intraoral right lateral view; G) Intraoral straight view; H) Intraoral left lateral view; I) Cephalometric radiograph; J) Panoramic radiograph

The panoramic radiograph showed proper root parallelism with moderate root resorption on the right central incisor. This resorption may be due to root contact with the impacted supernumerary tooth during orthodontic tooth movement, as explained with

the patient before treatment. The cephalometric analysis demonstrated the reduction in upper incisors' proclination (Table 1). Cephalometric superimposed revealed the upright and extrusion of upper incisors and the intrusion and slightly lingual tipping of lower incisors (Figure 7).

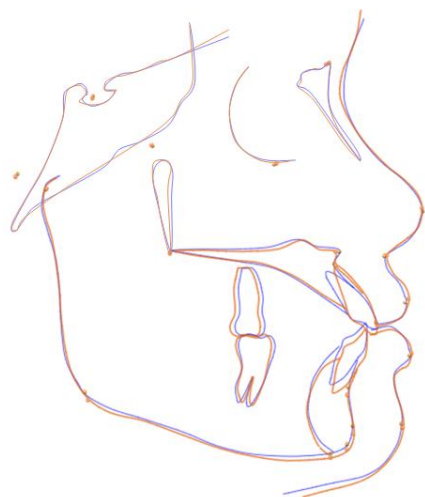


Figure 7: Superimposition of pre- and post-treatment cephalometric tracings

The total active treatment period was 15 months. Following bracket removal, fixed retainers were bonded on the lingual surface of teeth from right first premolars to the left first premolars to keep the alignment in both arches. Besides, removable thermoforming retainers were made for both maxillary and mandibular arch. The patient was instructed to wear the removable retainers only at night. The treatment result remained stable 1 year follow up (Fig 8).

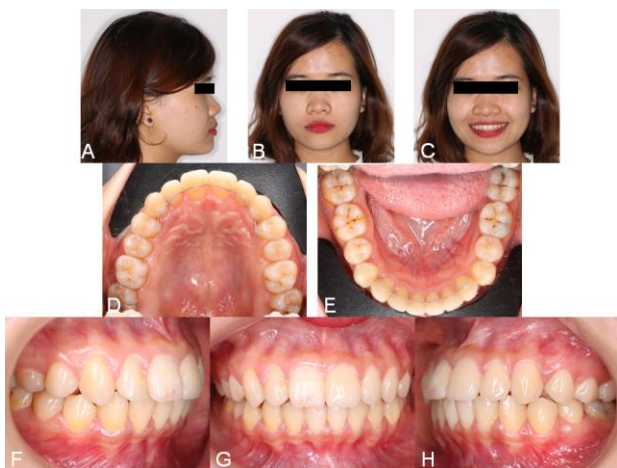


Figure 8: Patients after 1 year of retention; A) Extraoral profile view; B) Extraoral straight view; C) Smile straight view; D) Maxillary occlusal view; E) Mandibular occlusal view; F) Intraoral right lateral view; G) Intraoral straight view; H) Intraoral left the lateral view

The use of lingual brackets to apply lingual crown torque helps to reduce axial proclination and increasing upper incisor showing without neither interproximal reduction nor extraction. The result is a

better esthetic improvement for skeletal Class III patients with upper anterior crowding.

## Discussion

Since the first introduction of multilingual bracket system by K. Fujita in 1979, there have been many improvements to overcome the disadvantages of lingual orthodontic treatment [2]. Two of them are the transition from mushroom archwire to straight wire concept [2], [3], and the use of multi-slot lingual bracket [4], [5]. The application of straight lingual archwire leads to the elimination of offset bends between canines and premolars, and between premolars and molars so that the technique becomes simpler and the chair time may be reduced. Because of the small inter bracket distance and bracket size, it is hard to engage the archwire into bracket slots fully, so controlling three-dimensional tooth movement in lingual orthodontics become difficult. There is two main slot design in lingual orthodontics: vertical and horizontal slot. The vertical slot is efficient for in-and-out and rotational control and the horizontal slot is efficient for angulation (tip) control [5] (Figure 9). By combining the advantages of two-slot design into one bracket system, the multi-slot lingual brackets allow inserting simultaneously to the archwire so that the traditional complex double overtie method may be eliminated. However, the tooth movement is still well controlled.

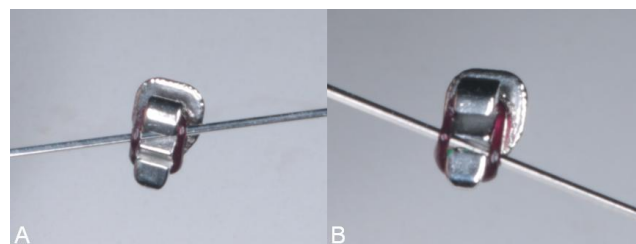


Figure 9: Because it is difficult to engage the archwire into bracket slots fully, the horizontal slots can't control in-out and rotation well A), and the vertical slots find difficulty in controlling tip B)

In this case, report, applying lingual crown torque to upper incisors helped to limit incisor proclination after decrowding, as many Asians prefer uprighted incisors to proclined incisors [9]. In labial orthodontics, some authors advocate using the low-torque bracket for upper anteriors to upright maxillary incisors in non-extraction cases, such as Dr Pitts, he inverted upper incisor brackets to have negative torque value [10]. Another advantage of uprighting upper incisors, in this case, was more upper incisor extrusion to increase incisor show and create a more harmonious smile arc. This effect increases in lingual orthodontic treatment because vertical tooth movement is greater with a lingual bracket than with a

labial bracket when applying torque to bracket slot [11].

## Informed Consent

Informed consent was obtained from the patient included in the study

## References

1. Fujita K. New orthodontic treatment with lingual bracket mushroom archwire appliance. *American Journal of Orthodontics*. 1979; 76(6):657-75. [https://doi.org/10.1016/0002-9416\(79\)90211-2](https://doi.org/10.1016/0002-9416(79)90211-2)
2. Takemoto K, Scuzzo, G. The straight-wire concept in lingual orthodontics. *Journal of Clinical Orthodontics*. 2001; 35:46-52.
3. Kyung HM, Park HS, Bae SM, Sung JH, Kim IB. The lingual plain-wire system with Micro-Implant Anchorage. *Journal of Clinical Orthodontics*. 2004; 38:388-95.
4. Hong RK, Lim SM. The Tandem Archwire Technique in Lingual Orthodontics. *Journal of Clinical Orthodontics*. 2013; 47(4):232-40.
5. Choi YB, Choi SH. Tandem mechanism with multi-slot bracket. *Journal of the Japan Lingual Orthodontic Association*. 2012; 23:65-73.
6. Geron S. Self-Ligating Brackets in Lingual Orthodontics. *Seminars in Orthodontics*. 2008; 14(1):64-72. <https://doi.org/10.1053/j.sodo.2007.12.007>
7. Fillion D. The Lingual Liberty system: Advantages of a digital lingual straight wire system. *Seminars in Orthodontics*. 2018; 24(3):286-96. <https://doi.org/10.1053/j.sodo.2018.08.005>
8. Wiechmann D, Rummel V, Thalheim A, Simon J-S, Wiechmann L. Customized brackets and archwires for lingual orthodontic treatment. *American Journal of Orthodontics and Dentofacial Orthopedics*. 2013; 124(5):593-99. <https://doi.org/10.1016/j.ajodo.2003.08.008> PMID:14614428
9. Cao L, Zhang K, Bai D, Jing Y, Tian Y, Guo Y. Effect of maxillary incisor labiolingual inclination and anteroposterior position on smiling profile esthetics. *Angle Orthodontist*. 2011; 81(1):121-29. <https://doi.org/10.2319/033110-181.1> PMID:20936964
10. Pitts TR. Bracket positioning for smile arc protection. *Journal of Clinical Orthodontics*. 2017; 51(3):142-56.
11. Hong RK. The mushroom archwire technique in Lingual Orthodontic Treatment. ed RK Hong and HM Kyung, Dentos, Daegu, Korea, 2009:95-103.