

# Transplantation of Bone Marrow-Derived Mesenchymal Stem Cells Preserve the Salivary Glands Structure after Head and Neck Radiation in Rats

Basma Elsaadany<sup>1\*</sup>, Mai Zakaria<sup>1</sup>, Mohamed Refat Mousa<sup>2</sup>

<sup>1</sup>Oral Medicine and Periodontology Department, Faculty of Dentistry, Cairo University, Cairo, Egypt; <sup>2</sup>Pathology Department, Faculty of Veterinary Medicine, Cairo University, Cairo, Egypt

## Abstract

**Citation:** Elsaadany B, Zakaria M, Mousa MR. Transplantation of Bone Marrow-Derived Mesenchymal Stem Cells Preserves the Salivary Glands Structure after Head and Neck Radiation in Rats. Open Access Maced J Med Sci. <https://doi.org/10.3889/oamjms.2019.350>

**Keywords:** Salivary gland; Radiotherapy; BM-MSCs; Mesenchymal stem cells

**\*Correspondence:** Basma Elsaadany, Oral Medicine and Periodontology Department, Faculty of Dentistry, Cairo University, Cairo, Egypt. E-mail: [Basma.abdelalim@dentistry.cu.edu.eg](mailto:Basma.abdelalim@dentistry.cu.edu.eg)

**Received:** 18-Mar-2019; **Revised:** 18-May-2019; **Accepted:** 19-May-2019; **Online first:** 28-May-2019

**Copyright:** © 2019 Basma Elsaadany, Mai Zakaria, Mohamed Refat Mousa. This is an open-access article distributed under the terms of the Creative Commons Attribution-NonCommercial 4.0 International License (CC BY-NC 4.0)

**Funding:** This research did not receive any financial support

**Competing Interests:** The authors have declared that no competing interests exist

**BACKGROUND:** The salivary glands are one of the radiation sensitive tissues during radiotherapy in the treatment of head and neck cancer. Within the first weeks of radiotherapy, the radiation causes progressive loss of gland function, then continue throughout the later of the patient's life.

**AIM:** The present work was designed to discover the potential effect of bone marrow-derived mesenchymal stem cells (MSCs) injected locally and in decreasing the unwanted effects of radiation on rats salivary gland.

**MATERIAL AND METHODS:** 6 rats used as the control group (N) and 12 rats had a single radiation dose of 13Gy in the head and neck then, they were equally allocated into two groups: Irradiated only as a group (C), irradiated then treated with MSCs as a group (S). The animals were euthanised 7 days post radiation. Then, submandibular salivary glands were cut up; the histological examination was done.

**RESULTS:** Histological examination of the treated group(S) shown an apparent improvement in the SG structure and function compared to the irradiated group (C), this improvement represented mainly as preserving acini diameter ( mean diameter in  $\mu\text{m}$  group ( C )  $183.1 \pm 4.5$ , in group (S)  $356.3 \pm 33.5$  while, in (N) group  $408.9 \pm 5.9$ ) and decrease in fibrotic areas in the gland ( mean fibrosis parentage in group ( C )  $26.5 \pm 5.9$  in (C ) group , in group (S)  $11.7 \pm 4.13$  while in (N) group  $0.2 \pm 0.31$ ).

**CONCLUSION:** BM-MSCs has revealed to be promising in mitigating the side effects of radiotherapy on salivary glands structure.

## Introduction

Xerostomia, which is hypofunction of the salivary glands, is the greatest noteworthy undesirable sequelae of radiotherapy in the management of head and neck neoplasms [1]. Approximately, more than 500000 patients experience radiotherapy every year all over the world, and as an outcome, the greater part of these patients will encounter serious hypofunction of the salivary glands (SGs) [2].

This could prompt an expansive series of medicinal complications and symptoms, for example, dry mouth, improper function of speaking, deglutition and mastication, serious dental caries, dysgeusia and oral mucositis. These long-lasting complications extremely lessen the post-treatment personal

satisfaction and increment the pain of a substantial number of patients undergoing radiotherapy in the head and neck area [3].

The obvious destruction of salivary glands as a result to radiation treatment radiation-actuated SG harm shows the necessity for progressively dynamic measures through as well as directly after the prior stage post-radiation, as opposed to managing hypofunction till the point when permanent harm has happened. Available approaches avoiding or limiting damage to salivary glands as a result to radiation incorporate the utilisation of defensive substances, for example, amfostin or tempol, submandibular salivary gland relocation surgically and reduction of the radiation dosage conveyed to non-target typical tissues of the salivary glands [4], [5]. However, a reasonable protective treatment has not been

developed to defend the salivary glands from damage produced by radiotherapy.

Attention in the treatment approaches intended to heal and additionally reestablish harmed SGs is expanding, and with regards to tissue engineering and regenerative medicine, these approaches involve the re-grafting of autologous SG cells [6], the embedding of engineered salivary glands synthetically prepared [7], stem cell treatment [8], and gene therapy [9]. Bone-marrow-derived mesenchymal stem cells (BM-MSCs) were in recent times suggested as probable applicants for the treatment of hypofunction of salivary glands [10].

The present work was designed to discover the potential effect of bone marrow-derived mesenchymal stem cells injected locally and in decreasing the unwanted effects of radiation on rats salivary gland.

## Material and Methods

### ***Experimental animals and ethical statement***

The current study was done on 24 healthy male albino rats, weight about 100 to 150 grams and age ranged between 3 to 4 months. The sample size was divided into 6 rats in each group. The animals were obtained and housed under standardised conditions with controlled temperature and humidity (30-35%) and a 12-12 h light-dark cycle.

The rats had free access to standard rat chow and tap water at the research animal house of National Cancer Institute – Cairo, Egypt.

All aspects of the animal's care and experimental protocols were reviewed and approved by the ethical committee in the faculty of Oral and Dental Medicine– Cairo University. Furthermore, the protocol was by the recommendation of the National Institutes of Health guide for the care and use of Laboratory Animals (NIH Publications No. 8023, revised 1978).

### ***BM-MSCs Preparation***

Six 6 weeks old male white albino rats (100-120 g) were euthanised by cervical dislocation, isolation of bone marrow was done in the Research animal house of National Cancer Institute – Cairo, Egypt. Bone marrow was harvested by flushing the tibiae and femurs of rats with DMEM (GIBCO/BRL) supplemented with 10% fetal bovine medium (GIBCO/BRL). Nucleated cells were isolated with a density gradient [Ficoll/Paque (Pharmacia)]. The cells were then incubated in a CO<sub>2</sub> incubator at 37°C in 5%

humidified CO<sub>2</sub> for 12-14 days as a primary culture or upon the formation of large colonies. When large colonies developed (80-90% confluence), the cultures were washed twice with phosphate buffer saline (PBS), and the cells were trypsinised with 0.25% trypsin in 1 mM EDTA (GIBCO/BRL) for 5 minutes at 37°C. After centrifugation, cells were resuspended in PBS. MSCs in culture were characterised by their adhesiveness, fusiform shape and by detection of CD29, one of the surface markers for MSCs by RT-PCR [11].

### ***Experimental Design***

The selected rats were randomised into 3 groups, one normal control group (N) and two experimental groups. In experimental groups, rats were anaesthetised by i.p. Injection of sodium pentobarbital (Nembutal®, 40 mg/kg body weight) and ketamine chloride (ketalar®, 40 mg/kg body weight) then received a single radiation dose of 13 Gray (Gy) to the head and neck region at the National Cancer Institute, Cairo, Egypt, using linear accelerator (Electa-precise T System) using 4 MeV electron beam with 1 cm bolus (the source of radiation, the dose and the time for evaluation were determined based on a pilot study to generate salivary gland injury in rats in response to regional radiation), then they were equally subdivided to Irradiated only group (C) + (PBS), Irradiated + mesenchymal stem cells (MSCs) group (S). Group (S), received an injection with ( $1 \times 10^5$  cells in 0.2 ml) in (PBS). The injection in both groups was immediately after irradiation within the first hour using a 1 ml insulin syringe with a needle size 27 gauge x 1/2 inch (BD Nokor™). It was at submandibular gland through a horizontal incision in the neck to expose the gland. Euthanasia by concussion occurred in day 7 after radiation. Then, submandibular salivary glands collected and were fixed in 10% formalin for specimen preparation and histological evaluation. Acini diameters and area were assessed histologically in the H & E section in addition to an assessment of areas of fibrosis in Masson's trichrome MTC stained sections.

### ***Histological evaluation***

The assessor was completely blind about the sample groups during evaluation. The diameter of the acini was assessed using Leica Quin 500 analyser computer system (Leica Microsystems, Switzerland). The cursor was utilised to draw a straight line representing the length of the acinus in H & E stained sections. The image analyser is calibrated automatically to transform the measurement units (pixels) produced by the image analyser program into actual micrometre units. The length was estimated in 2 different acini in 5 different fields, in each specimen using magnification (x 100). The area percentage of MTC stain in the sections were analysed in 3 sections

for each slide. At least 3 fields per section were accounted for using CellSens dimensions software (Olympus).

### Statistical analysis

Statistical Package for Social Sciences (SPSS) was used, Version 18.0 for Windows. As the data following a normal distribution, ANOVA was utilised to relate the values between the experimental and control groups, followed by post hoc Tukey, if results of ANOVA were significant. A p-value of  $\leq 0.05$  was considered statistically significant.

## Results

Microscopic examination of the normal group showed the normal histological structure of submandibular salivary gland that composed of the mixed serous-mucous acinus, the serous acinus forms serous demilune around mucous acinus and intercalated ducts, the later were lined by simple cuboidal epithelium and surrounded by myoepithelial cells with limited periductal and perivascular fibrous connective tissue. Meanwhile, examination of the stem cells treated group (S) showed relatively well preserved histological structure compared to irradiated only group (C), this presented in the detected changes in acini diameter in the MSCs group (mean  $356.3 \pm 33.5 \mu\text{m}$ ) is significantly higher than in irradiated only group (mean  $183.1 \pm 4.5 \mu\text{m}$ ) but did not reach the normal group (mean  $408.9 \pm 5.9 \mu\text{m}$ , P value  $\leq 0.05$ ). The irradiated only group showed necrosis of the ductal lining epithelium with apoptosis that was less commonly observed in the stem cells treated group.

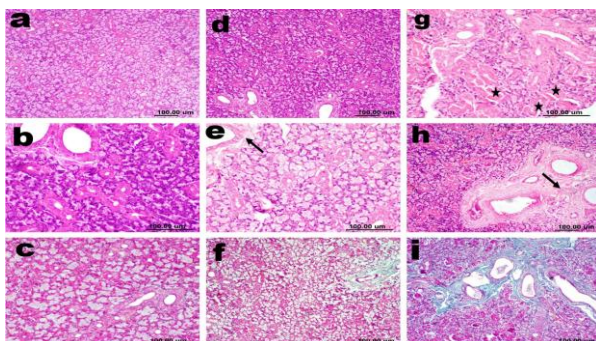


Figure 1: Photomicrographs of rat submandibular salivary gland a) and b) control group showing normal gland composed of mixed secretory units with intercalated ducts (H & E); c) Control group showing normal fine connective tissue stroma (MTC); d) Stem cells treated group showing well preserved histological structure of the gland (H & E); e) Stem cells treated group showing less periductal fibrosis (arrow) (H & E); f) Stem cells treated group showing less periductal and perivascular fibrosis by (MTC); g) Irradiated group showing ductal necrosis (stars) (H & E); h) Irradiated group showing diffuse fibrosis periductal, perivascular and around acini (arrow) (H & E); i) Irradiated group showing diffuse fibrosis periductal, perivascular and around acini (MTC)

Also, fibrosis was evaluated in tissue sections stained with Masson's trichrome (MTC) stain; irradiated group showed significant diffuse periductal and perivascular fibrosis that was extending into the lobules in-between the acini (area of fibrosis  $26.5 \pm 5.9$ ) compared to the treated group (area of fibrosis  $11.71 \pm 1.8$ , P value  $\leq 0.05$ ) Figure 1, and 2.

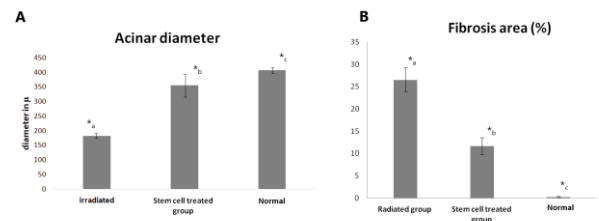


Figure 2: Bar charts representing A) changes in mean acini diameter among the groups, while B) changes in the percentage of fibrosis among the groups; Values are the Means  $\pm$  standard deviation \*(P-value  $\leq 0.05$ ), a, b and c indicate significant differences between values

## Discussion

Our results demonstrate that intraglandular transplantation of BM-MSCs during the early post-radiation phase mitigates SG damage following head and neck radiation at a single dose of 13 Gy. Many former studies utilised a dosage of 15 Gy to examine the outcome of stem cell in the management of radiation brought SG destruction [1], [10], [12], [13]. In the current study, we designated dose of 13 Gy based on a pilot study to detect the lowest dose that induces detectable histopathological changes after single dose during different time points in the first week after regional irradiation. The same dose was used in the model created by Fang et al., [14]. We choose to use intraglandular route this was by [10], [15] to ensure homing and detect the early changes and the ability of the treatment to preserve the structure. We found that radiation caused a remarkable decrease in the acinar field area as well as acinar diameter, a remarkable increase in fibrosis and a significant decrease in proliferation activity. However, in the stem cells treated animals, these changes were significantly decreased with obvious preservation of the normal structure — the definite underlying mechanisms explaining the role of BM-MSCs in the protection of radiation-induced SG damage controversial. Paracrine effects, trans-differentiation and/or cell fusion and angiogenesis may be involved in the protection of SG structure [4], [5], [16]. On the one hand, Lombaert et al. found that transplanted BM-MSCs could engraft in the damaged SGs inducing repair by paracrine stimulation preserving glands function and structure [17].

Similarly, the findings of Tran et al., that BM Soup was as effective as whole live BM cells in

repairing irradiated-SG, suggesting a paracrine effect of BM cells on SGs [12]. Recently, a study by Fang et al. reported that injections of BM soup within 3 weeks after irradiation could preserve 90–100% of salivary flow in irradiated mice [14]. The paracrine actions of MSCs, via secreting anti-inflammatory, anti-apoptotic agents and increase expression of proliferation-promoting factors, have been suggested to have a role in tissue repair in many diseases [18], [19], [20], [21], [22], [23]. On the other hand, few studies showed that intravenous transplantation of BM-MSCs [24], or intraglandular injection with BM-MSCs co-cultured with acinar cells [25] could preserve the function of SGs post radiation via transdifferentiation into glandular cells. These studies used mixed cells so that the type of cells that improves the SG function is not identified.

In conclusion, immediate transplantation of BM-MSCs after regional radiotherapy has shown to be effective in preserving the salivary gland morphology and function, minimizing the side effects of radiation on normal salivary glands.

## References

- Lim J-Y, Ra JC, Shin IS, Jang YH, An H-Y, Hye-Youn An, Choi J-S, Cheol W-K, Young M-K. Systemic transplantation of human adipose tissue-derived mesenchymal stem cells for the regeneration of irradiation-induced salivary gland damage. *PLoS ONE*. 2013; 8(8):e71167. <https://doi.org/10.1371/journal.pone.0071167> PMID:23951100 PMCid:PMC3739795
- Schwarz S, Huss R, Schulz-Siegmund M, Vogel B, Brandau S, Stephan Lang S, Rotter N. Bone marrow-derived mesenchymal stem cells migrate to healthy and damaged salivary glands following stem cell infusion. *INT J ORAL SCI*. 2014; 6:154-161. <https://doi.org/10.1038/ijos.2014.23> PMID:24810808 PMCid:PMC4170149
- Lia Z, Wang Y, Xing H, Wang Z, Hua H, Anc R, Xuc H, Xu H, Liu Y, Liu B. Protective efficacy of intravenous transplantation of adipose-derived stem cells for the prevention of radiation-induced salivary gland damage. *Arch. Oral Biol*. 2015; 60:1488-1496. <https://doi.org/10.1016/j.archoralbio.2015.07.016> PMID:26263537
- Bhide SA, Miah AB, Harrington KJ, Newbold KL, Nutting CM. Radiation-induced xerostomia: pathophysiology, prevention and treatment. *Clin Oncol*. 2009; 21(10):737-744. <https://doi.org/10.1016/j.clon.2009.09.002> PMID:19833490
- Vissink A, Mitchell JB, Baum BJ, Limesand KH, Jensen SB, Fox PC, Elting LS, Langendijk JA, Coppes RP, Reylan ME. Clinical management of salivary gland hypofunction and xerostomia in head-and-neck cancer patients: successes and barriers. *Int J Radiat Oncol Biol Phys*. 2010; 78(4): 983-91. <https://doi.org/10.1016/j.ijrobp.2010.06.052> PMID:20970030 PMCid:PMC2964345
- Sugito T, Kagami H, Hata K, Nishiguchi H, Ueda M. Transplantation of cultured salivary gland cells into an atrophic salivary gland. *Cell Transplant*. 2004; 13:691-699. <https://doi.org/10.3727/000000004783983567> PMID:15648739
- Aframian DJ, Palmon A. Current status of the development of an artificial salivary gland. *Tissue Eng Part B Rev*. 2008; 14:187-198. <https://doi.org/10.1089/ten.teb.2008.0044> PMID:18471085
- Coppes RP, Stokman MA. Stem cells and the repair of radiation-induced salivary gland damage. *Oral Dis*. 2011; 17:143-153. <https://doi.org/10.1111/j.1601-0825.2010.01723.x> PMID:20796229
- Baum BJ, Zheng C, Alevizos I, Cotrim AP, Liu S, McCullagh L, Goldsmith CM, McDermott N, Chiorini JA, Nikolov NP, Illei GG. Development of agene transfer-based treatment for radiation-induced salivary hypofunction. *Oral Oncol*. 2010; 46:4-8. <https://doi.org/10.1016/j.oraloncology.2009.09.004> PMID:19892587 PMCid:PMC2818419
- Lim JY, Yi T, Choi JS, Jang YH, Lee S, Kim HJ, Song SU, Kim YM. Intraglandular transplantation of bone marrow-derived clonal mesenchymal stem cells for amelioration of post-irradiation salivary gland damage. *Oral Oncol*. 2013; 49:136-143. <https://doi.org/10.1016/j.oraloncology.2012.08.010> PMID:22981389
- Rocheffort YG, Vaudin P, Bonnet N, Pages JC, Domenech J, Charbord P, Eder V. Influence of hypoxia on the domiciliation of mesenchymal stem cells after infusion into rats: possibilities of targeting pulmonary artery remodeling via cells therapies? *Respir Res*. 2005; 6(1):125. <https://doi.org/10.1186/1465-9921-6-125> PMID:16253136 PMCid:PMC1291404
- Tran SD, Liu Y, Xia D, Maria OM, Khalili S, Wang RW, Quan VH, Hu S, Seuntjens J. Paracrine effects of bone marrow soup restore organ function, regeneration, and repair in salivary glands damaged by irradiation. *PLoS One*. 2013; 8(4):e61632. <https://doi.org/10.1371/journal.pone.0061632> PMID:23637870 PMCid:PMC3634855
- Yamamura Y, Yamada H, Sakurai T, Ide F, Inoue H, Muramatsu T. Treatment of salivary gland hypofunction by transplantation with dental pulp cells. *Arch Oral Biol* 2013; 58(8):935-942. <https://doi.org/10.1016/j.archoralbio.2013.02.015> PMID:23570866
- Fang D, Shang S, Liu Y, Bakkar M, Sumita Y, Seuntjens J, Tran SD. Optimal timing and frequency of bone marrow soup therapy for functional restoration of salivary glands injured by single-dose or fractionated irradiation. *Journal of tissue engineering and regenerative medicine*. 2018; 12(2):e1195-205. <https://doi.org/10.1002/term.2513> PMID:28714550
- Wang Z, Xing H, Hu H, Dai T, Wang Y, Li Z, An R, Xu H, Liu Y, Liu B. Intraglandular transplantation of adipose-derived stem cells combined with platelet-rich fibrin extract for the treatment of irradiation-induced salivary gland damage. *Exp Ther Med*. 2018; 15(1):795-805. <https://doi.org/10.3892/etm.2017.5497>
- Ortholan C, Chamorey E, Benezery K, Thariat J, Dassonville O, Poissonnet G, Bozec A, Follana P, Peyrade F, Sudaka A, Gerard JP. Modeling of salivary production recovery after radiotherapy using mixed models: determination of optimal dose constraint for IMRT planning and construction of convenient tools to predict salivary function. *International Journal of Radiation Oncology\* Biology\* Physics*. 2009; 73(1):178-86. <https://doi.org/10.1016/j.ijrobp.2008.03.068> PMID:18565687
- Lombaert IM, Wierenga PK, Kok T, Kampinga HH, deHaan G, Coppes RP. Mobilization of bone marrow stem cells by granulocyte colony-stimulating factor ameliorates radiation-induced damage to salivary glands. *Clin Cancer Res*. 2006; 12:1804-12. <https://doi.org/10.1158/1078-0432.CCR-05-2381> PMID:16551865
- Wu Y, Chen L, Scott PG, Tredget EE. Mesenchymal stem cells enhance wound healing through differentiation and angiogenesis. *Stem Cells*. 2007; 25:2648-59. <https://doi.org/10.1634/stemcells.2007-0226> PMID:17615264
- Zarjou A, Kim J, Traylor AM, Sanders PW, Balla J, Agarwal A, Curtis LM. Paracrine effects of mesenchymal stem cells in cisplatin-induced renal injury require heme oxygenase-1. *Am J Physiol Renal Physiol*. 2011; 300:F254-62. <https://doi.org/10.1152/ajprenal.00594.2010> PMID:21048024 PMCid:PMC3023217
- Nemeth K, Leelahavanichkul A, Yuen PS, Mayer B, Parmelee A, Doi K, Robey PG, Leelahavanichkul K, Koller BH, Brown JM, Hu X, Jelinek I, Star RA, Mezey E. Bone marrow stromal cells attenuate sepsis via prostaglandin E(2)-dependent reprogramming of host macrophages to increase their interleukin-10 production. *Nat Med*. 2009; 15:42-9. <https://doi.org/10.1038/nm.1905> PMID:19098906 PMCid:PMC2706487

21. Prockop DJ, Olson SD. Clinical trials with adult stem/progenitor cells for tissue repair: let's not overlook some essential precautions. *Blood*. 2007; 109:3147-51. <https://doi.org/10.1182/blood-2006-03-013433> PMID:17170129 PMCID:PMC1852233
22. Rosenzweig A. Cardiac cell therapy - mixed results from mixed cells. *N Engl J Med*. 2006; 355:1274-7. <https://doi.org/10.1056/NEJMe068172> PMID:16990391
23. Elsaadany B, El Kholy S, El Rouby D, Rashed L, Shouman T. Effect of Transplantation of Bone Marrow Derived Mesenchymal Stem Cells and Platelets Rich Plasma on Experimental Model of Radiation Induced Oral Mucosal Injury in Albino Rats. *Int J Dent*. 2017; 2017:8634540. <https://doi.org/10.1155/2017/8634540> PMID:28337218 PMCID:PMC5346393
24. Sumita Y, Liu Y, Khalili S, Maria OM, Xia D, Key S, Cotrim AP, Mezey E, Tran SD. Bone marrow-derived cells rescue salivary gland function in mice with head and neck irradiation. *Int J Biochem Cell Biol*. 2011; 43:80-7. <https://doi.org/10.1016/j.biocel.2010.09.023> PMID:20933096 PMCID:PMC3403826
25. Lin CY, Chang FH, Chen CY, Huang CY, Hu FC, Huang WK, Ju SS, Chen MH. Cell therapy for salivary gland regeneration. *J Dent Res*. 2011; 90:341-6. <https://doi.org/10.1177/0022034510386374> PMID:21297017