

Perforator Mapping of the Superficial and Deep Inferior Epigastric Artery in the Abdominal Region of the Vietnamese

Tran Dang Khoa¹, Nguyen Duy Bac^{2*}, Cao Ngoc Bich³, Hoang-Long Vo⁴, Nguyen Vu Thai Lien⁵, Thien Chu Dinh⁶

¹Pham Ngoc Thach University of Medicine (PNTU), Ho Chi Minh City, Vietnam; ²Vietnam Military Medical University (VMMU), Hanoi, Vietnam; ³Thanh Van Cosmetic Surgery Hospital, Ho Chi Minh City, Vietnam; ⁴Institute for Preventive Medicine and Public Health, Hanoi Medical University, Hanoi, Vietnam; ⁵School of Odonto Stomatology, Hanoi Medical University, Hanoi, Vietnam; ⁶Institute for Research and Development, Duy Tan University, 03 Quang Trung, Danang, Vietnam

Abstract

Citation: Khoa TD, Bac ND, Bich CN, Vo H-L, Lien NVT, Dinh TC. Perforator Mapping of the Superficial and Deep Inferior Epigastric Artery in the Abdominal Region of the Vietnamese. Open Access Maced J Med Sci. <https://doi.org/10.3889/oamjms.2019.362>

Keywords: Deep inferior epigastric artery; Superficial epigastric artery; Fourth space; Eight regions; Perforators

***Correspondence:** Nguyen Duy Bac. Vietnam Military Medical University (VMMU), Hanoi, Vietnam. E-mail: nguyenduybac@vmmu.edu.vn

Received: 26-May-2019; **Revised:** 20-Aug-2019; **Accepted:** 19-Jun-2019; **Online first:** 15-Oct-2019

Copyright: © 2019 Tran Dang Khoa, Nguyen Duy Bac, Cao Ngoc Bich, Hoang-Long Vo, Nguyen Vu Thai Lien, Thien Chu Dinh. This is an open-access article distributed under the terms of the Creative Commons Attribution-NonCommercial 4.0 International License (CC BY-NC 4.0)

Funding: This research did not receive any financial support

Competing Interests: The authors have declared that no competing interests exist

BACKGROUND: Previous studies worldwide have investigated the anatomy of the perforators of the deep inferior epigastric arteries to figure out the navigation patterns of the perforators on the abdominal wall. This has been inconsistent amongst the researchers about how to select the perforator to increase the blood supply area for the flap.

AIM: To explore the blood supply area of the perforators of the superficial and deep inferior epigastric artery in the abdominal region of the Vietnamese by dissection and 64-slice multislice computed tomography (64-slice MSCT).

METHODS: A descriptive cross-sectional study Center from September 2014 to September 2016 on two groups including 30 cadavers fixed by formalin 10% in Anatomy Department of UPNT, and 37 patients getting the 64-slice MSCT abdominal arteries angiogram.

RESULTS: The superficial epigastric arteries at the level of the inguinal ligament were located in the middle region, with 96% (right) and 88.5% (left). The anterior superior iliac spine level was in the middle, and lateral regions of 68% and 32% respectively. The level of the umbilical cord was in the lateral region with 66.7% and 85.7%, respectively. There were about 6 perforators of the deep inferior epigastric arteries located in the navel area. These perforators were 70% in the medial region and 30% in the middle region.

CONCLUSION: Mapping the blood supply based on the fourth space in the abdominal region in which the superficial inferior epigastric arteries supplied the lateral area. The middle and the internal ones were the perforators of the deep inferior epigastric arteries.

Introduction

Abdominoplasty is one of the aesthetic procedures performed increasingly commonly. Despite this made procedure for a long time, the outcome has not satisfied both physicians and cosmetic surgery clients due to its esthetic effects and safety. Particularly, the most important complication is the necrosis of the residual abdominal skin with various levels, which results from lacking of blood supply after the operation. Thus, the adequate knowledge about the characteristics of blood supply of the superficial and deep inferior epigastric artery as well as their perforators plays an important role that helps the surgeons calculate the dimensions of the removable flap in the operation procedure so that this

procedure is ensured safely [1]. Up to now, previous studies worldwide have investigated the anatomy of the perforators of the deep inferior epigastric arteries to figure out the navigation patterns of the perforators on the abdominal wall. From that, they can identify four standard blood supply spaces as Hartrampf [2], [3], [4]. However, this has been inconsistent amongst the researchers forward how to select the perforator to increase the blood supply area for the flap. A Quynh et al.' study reported this issue in Vietnam, which has been not yet systematic for both the arteries [3]. The present study, therefore, aimed to explore blood supply area of the perforators of the superficial and deep inferior epigastric artery in the abdominal region of Vietnamese by dissection and 64-slice multislice computed tomography (64-slice MSCT).

Material and methods

Study design and participants

A descriptive cross-sectional study was conducted between September 2014 and September 2018. The participants in the study were divided into two groups. A group included 30 cadavers fixed with formalin 10% in Anatomy Department of UPNT. Other group included 37 adult patients getting the 64-slice MSCT angiography of the abdominal artery in Hoa Hao Medical Center. The participants were selected in this study with the convenience sampling method. We included the Vietnamese patients (i) over 18 years and (ii) not undergoing any surgery in the groin and thigh areas. We excluded the patients (i) with the distortions in the groin and thigh areas (congenital, pathological abnormalities, and previous surgery), and (ii) vascular malformation in these areas (transplantation, binding vessels, etc.).

Procedures

In the cadaver group, we performed an incision in the abdominal area along to inguinal ligament in the supine position of the cadavers. Then we determined the origins of the superficial and deep inferior epigastric artery. We continued to dissect along the deep inferior epigastric artery until we could not determine the vessel in the abdominal wall. Moreover, we dissected along the superficial epigastric artery to find perforators. We examined them about position, direction and their relationship with the medial or lateral of the anterior abdominal wall as well as their coordination.

In the patient group, the patients getting 64-slice MSCT contrast injection undergo function tests of liver and kidney, abdominal sonography, blood pressure, height and weight measurement. The contrast dose was 2 ml/kg. The patient was conducted with 64-slice MSCT in the supine position (the depth of slice: 1mm (0.8) overlap 0.2). The outcomes were evaluated by the same diagnostic imaging doctor and the same researcher. We identified the number of perforators of the deep inferior epigastric artery, their position and relationship with the medial or lateral of the anterior abdominal wall.

Data analysis

Data were collected and analysed with IBM SPSS 21 software package. Descriptive statistics (percentages, frequencies, means and standard deviations) for the various groups distinguished, were computed. Independent t-tests were applied to test the significance of differences between groups. The significance level was considered at $p < 0.05$.

Results

The blood supply area of the superficial epigastric artery in the abdominal wall: Characteristics of the direction of the superficial epigastric artery

In the cadaver group, the direction of the superficial epigastric artery which toward the anterior superior iliac spine was 64% in the right and 69.2% in the left. In the patient group with 64-slice MSCT, the patient percentage of the direction of the arteries, which straight down the hypochondriac region was more than 50% than.

Table 1: Direction of the superficial epigastric artery in the abdominal wall of cadavers and patients with 64-slice MSCT

Sample	Direction	To the right	To the left	p
Cadavers (nR = 25, nL = 26)	Toward to anterior superior iliac spine	17 (68%)	20 (76.9%)	0.26
	Toward to middle line	4 (16%)	3 (11.5%)	
	Straight down hypochondriac region	4 (16%)	3 (11.5%)	
	Superficial epigastric artery-inguinal ligament angle	50 ± 15.94	46 ± 12.6	0.35
64-slice MSCT (nR = 5, nL = 4)	Toward to anterior superior iliac spine	1 (20%)	1 (25%)	0.09
	Toward to middle line	1 (20%)	1 (25%)	
	Straight down hypochondriac region	3 (60%)	2 (50%)	
	Superficial epigastric artery-inguinal ligament angle	42.0 ± 22.3	53.5 ± 16.8	0.29

The proportion of the angle of the superficial epigastric artery and inguinal ligament was smaller in the patient group than in the cadaver group. There were no significant differences in directions from two sides (Table 1 and Figure 1).

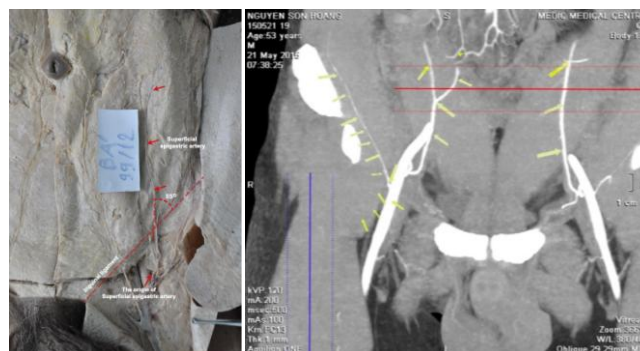


Figure 1: The angle of the superficial epigastric artery and the left hypochondriac region (Right); the right superficial epigastric artery goes toward to anterior superior iliac spine, then goes into lateral line toward to the hypochondriac region in 64-slice MSCT (Left)

Mapping the blood supply area of the superficial epigastric artery based on three lines in the abdominal wall

In the cadaver group, the relative position of the superficial epigastric artery which is at the level of an inguinal ligament in the middle line accounted for the highest percentage with both right and left sides (96.0% and 88.5%, respectively), followed by in the lateral line. No observation in the medial line. At level of anterior superior iliac spine, the artery running into the lateral line started to increase to 32% in the right side and to 50% in the left side (the lower the

percentage of artery in the middle line became, the upper the percentage of artery in the lateral line became), and once at level of navel, the position of the artery in the lateral line was up to 66.7% in the right side and up to 85.7% in the left side. This supported that, in the cadaver group, the direction of the superficial epigastric artery ran from the medial to the lateral line, and the cases of the superficial epigastric artery at that level decreased to 1/2 in the right side and about 1/4 in the left side. Moreover, there was a significant difference in the relative position of the superficial epigastric artery based on three lines amongst the sides (p < 0.05).

Table 2: Localizing the superficial epigastric artery based on three lines in the abdominal wall of cadaver and patient groups

Location		Cadaver group		64-slice MSCT group	
Standard landmark	Line	Right	Left	Right	Left
Level of inguinal ligament	Medial	0	0	1 (20%)	1 (25%)
	Middle	24 (96%)	23 (88.5%)	4 (80%)	3 (75%)
	Lateral	1 (4%)	3 (11.5%)	0	0
	Total	25	26	4	3
	p-values	0.143		0.25	
Level of anterior superior iliac spine	Medial	0 (0,0%)	1 (3,8%)	1 (25,0%)	1 (33,3%)
	Middle	17 (68,0%)	12 (46,2%)	3 (75,0%)	1 (33,3%)
	Lateral	8 (32,0%)	13 (50%)	0	1 (33,3%)
	Total	25	26	4	3
	p-values	0.008*		1	
Level of navel	Medial	0	0	1 (33,3%)	1 (50%)
	Middle	4 (33,3%)	1 (14,3%)	1 (33,3%)	1 (50%)
	Lateral	8 (66,7%)	6 (85,7%)	1 (33,3%)	0
	Total	12	7	3	2
	p-values	0.248		1	

*: significant at 0.05.

There is no significant difference at the level of the navel, perhaps because the numbers of the arteries at that level were very few.

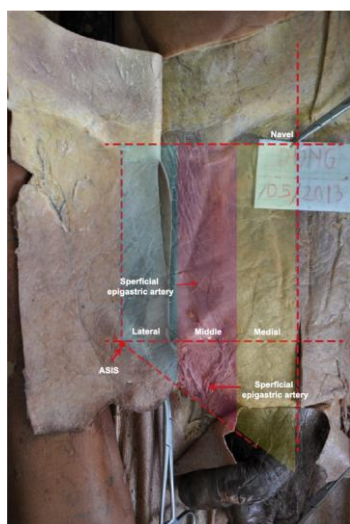


Figure 2: Mapping the right superficial epigastric artery based on three lines: at the level of the inguinal ligament, the right superficial epigastric artery is in the middle line; at level of anterior superior iliac spine, it is still in the middle line; and at level of navel, it is at the lateral line

In, the relative position of the superficial epigastric artery which is at the level of the anterior superior iliac spine is the highest in both right and left sides (80.0% and 75.0%, respectively), this is still at the middle line when the artery runs into the level of the anterior superior iliac spine.

However, in the patient group with 64-slice MSCT, it is difficult to identify the branches of the superficial epigastric artery which were more than 0.5 mm in diameter, so there was an extremely significant difference in the frequency of the appearance of the superficial epigastric artery amongst cadaver and patient groups (Table 2 and Figure 2).

The blood supply area of the perforators of the deep inferior epigastric artery in the abdominal wall

We documented the position of perforators of the deep inferior epigastric artery based on 3 lines and the vertical axis going through the navel. We could not observe any perforators in the lateral line, but the number of the perforators in the medial line was the highest (approximately 70%), followed by in the middle line (30%). By dividing based on three lines (medial, middle and lateral lines) which were different in the distance from the anterior superior iliac spine and the axis going through navel, the number of perforators in the medial line decreased to 30%, and in the middle line, there was an increase reported (Table 3).

Table 3: The proportion of perforators based on these landmarks

Artery	Side	Medial line	Middle line	At level about 1/4 under the navel	Right	Left	At the level at the navel and about 1/4 upper	Right	Left
1	Right	25 (83.3%)	5 (16.7%)	Space 1	27 (96.4%)	21 (77.8%)	Space 1	2 (100%)	3 (100%)
	Left	27 (90%)	3 (10%)	Space 2	1 (3.6%)	6 (22.2%)	Space 2,3,4	-	-
2	Right	19 (67.9%)	9 (32.1%)	Space 1	21 (100%)	23 (100%)	Space 1	7 (100%)	6 (100%)
	Left	24 (82.8%)	5 (17.2%)	Space 2	-	-	Space 2,3,4	8 (80%)	7 (58.3%)
3	Right	20 (76.9%)	6 (23.1%)	Space 1	16 (100%)	16 (100%)	Space 1	2 (20%)	5 (41.7%)
	Left	20 (71.4%)	8 (28.6%)	Space 2	-	-	Space 2	-	-
4	Right	15 (71.4%)	6 (28.6%)	Space 1	7 (100%)	13 (100%)	Space 1	4 (28.6%)	3 (37.5%)
	Left	14 (66.7%)	7 (33.3%)	Space 2	-	-	Space 2	-	-
5	Right	13 (72.2%)	5 (27.8%)	Space 1	1 (100%)	5 (100%)	Space 1	5 (29.4%)	2 (18.2%)
	Left	12 (75%)	4 (25%)	Space 2	-	-	Space 2	-	1 (9.1%)
6	Right	10 (71.4%)	4 (28.6%)	Space 1	1 (100%)	-	Space 1	3 (23.1%)	2 (13.3%)
	Left	9 (60%)	6 (40%)	Space 2	-	-	Space 2	2 (15.4%)	1 (6.7%)
							Space 3	-	1 (6.7%)
							Space 4	2 (100.0%)	3 (100.0%)

As was shown in Table 3, the percentage of perforator 1 under the navel was 90%. While the percentage of the perforators number 2, 3, 4 under the navel decreased to 50%, the figures for the perforators number 2, 3, 4 upper the navel increased. Most of the perforator number 6 to number 11 were upper the navel. As the results from 64-slice MSCT, most perforators number 1 were under the navel (90%). The percentage of the perforators number 2, 3, 4 under the navel decreased to 50%, while the figures for the perforators number 2, 3, 4 upper the navel increased, but the slope in the patient group was recorded to be smaller than in the cadaver group.

With the perforators number 6 to number 11, most of them were upper the navel. In summary, the presence of each perforator was absolutely under the navel about 40 mm (unless the left perforator number 1 lies up to space 2, the percentage of these cases is about 22.2%). The percentage of perforators number 1 and 2 staying in space 1 was 100%, while the percentage of perforators number 3, 4, 5 which stayed in space 1 decreased from 80% to 60%. However, there had the perforators number 3, 4, 5 in the space 2 and 3, and the percentage of these cases were about 20%.

Discussion

The division pattern which divided the abdominal wall into 8 spaces along the axis going through the navel of N.T.Quynh was consistent with us, however, Quynh's pattern was considered as easier than ours. In the upper navel space, Quynh used the line going through the middle point of navel and xiphisternum to divide that space into space 3-4 (space 3 is medial and space 4 is lateral) and space 1-2 (space 1 is medial and space 2 is lateral), which were space 1-2 and space 3-4 respectively in our study (2 spaces in our study was consistent with 1 space in N.T.Quynh' study). The similar statistics was also applied in our study; we found that our results were strongly consistent with others. The distribution of the perforators originated from $\frac{1}{2}$ under the navel, and the highest concentration around the navel and the distribution decreased from there to xiphisternum. Therefore, the artery supplying blood for upper navel space is the deep inferior epigastric artery, not the superior epigastric artery. This was an important note in designing the flap. No similarity in the distribution of the perforators based on the horizontal axis going through the navel between N.T.Quynh' study and our ones. This could be because of N.T.Quynh divided the medial and lateral space based on the rectus abdominis muscle [3].

When research investigated the sample study, he often gives a series of different dimensions such as 4 cm, 5 cm, 8 cm, 10 cm or a few centimetres. This is a general disadvantage because the dimension has no rule. In this study, we found that our data was followed the rule of 4 (a distance equals 4cm long) and the distance was followed the fifty-fifty rule, which is the easy way for the practice because it did not depend on height, size and weight of the patient. If we multiplied the 4 cm-distance twice or $\frac{1}{2}$, our result might be consistent with previous studies (8 cm equals two 4cm-distances, 10 cm is 2.5 times of 4 cm-distance) [2], [3], [4].

We offered a division pattern with 4cm-distance in the abdominal wall to map the branches of the superficial epigastric artery and the deep inferior epigastric artery. Firstly, a line from the pubis to navel

need drawing, then divide that line into two equal segments and continue to divide each segment into two equal segments. So, we will have 4 segments (each segment which is called 4 cm-distance is 4 cm long). With this segment, we can identify that (i) the place where the inferior epigastric artery runs into muscle is at the point which divides navel-pubis distance into two segments; (ii) the place which has the first perforator is at the point which $\frac{3}{4}$ long from navel to pubis; (iii) perforators round up 100% at the 4cm-distance under navel. Secondly, with the medial point in the inguinal ligament, we draw a circle whose radius equals a 4 cm-distance from the pubis to navel, the probability to find the origin of the superficial epigastric artery is 90.2%. Thirdly, we draw 2 parallel lines which divide the distance from anterior superior iliac spine to the medial line of the abdomen into 3 rows (medial, middle and lateral rows) whose width equals a 4 cm-distance from the pubis to the navel. With 3 rows, we can identify the blood supply area of the arteries, such as the lateral row is the area which is supplied by the superficial epigastric artery, the middle row is the area we can find 30% perforators, and the medial row has 70% perforators of the deep inferior epigastric artery.

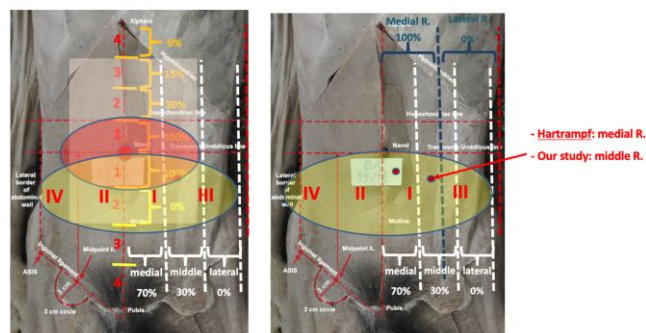


Figure 3: Mapping the perforators based on the vertical and horizontal axes which run through navel in our study (right), compared with the division pattern of Hartrampf (left)

The division pattern dividing the abdominal wall into 3 rows exists several advantages. The dimension of each segment is equivalent so that we can use it to estimate a distance. Secondly, segment $\frac{1}{4}$ upper navel, $\frac{1}{4}$ under the navel, $\frac{1}{2}$ anterior superior iliac spine - navel have a similar measurement regardless of anyone. Thus, we offered using this segment as a unit measurement to estimate the distance in the abdominal wall or to map the arteries as using proportion in traditional medicine. If we divided 2 rows: medial and lateral as a four-space pattern of Hartrampf or Schefflan and Dinner, most perforators are in the medial row, the result of our study is 100%. This would be an illogical appointment if we used the division pattern. This point was supported by Wong C.'s study [5], the blood supply area of perforators in the medial row near the middle row is different from the blood supply area of perforators in the medial row near the lateral row. The flat which is supplied blood by perforators in the

medial row near middle line more concentrated in the center and has an area bigger than the flat which is supplied blood by perforators in the medial row near lateral row [5]. In consequence, they are both perforators in the medial row, but near the middle line or not; their blood supply areas are different. Thus, based on the division pattern which divides abdominal wall into 3 rows in our study, perforators in the medial row near middle line belong to medial row, and perforators in the medial row far from middle line belong to medial row and the lateral row belong to the blood supply area of the superficial epigastric artery. In our point of view, 6 divided areas are logical and content with the explanation about blood supply area.

In a previous study of Eric M, et al., [6], the authors divided Hartrampf's spaces into smaller pieces followed 3 patterns: (a) 9 subspaces numbered from 1 to 9; (b) 3 subspaces near, middle, far; and (c) 3 subspaces medial, middle and lateral. The percentage of the presence of the perforators in space I was 79.43%, in space II was 6.38%, in space III was 13.48%, and in space, IV was 0.71%. The probability of finding out a perforator in space I was the highest (100%), while the probability to find out a perforator in space II, III and IV were 65%, 25% and 5%, respectively [6]. This division pattern divided each space of Hartrampf into 3 smaller pieces into horizontal and vertical axes to localise the mapping of perforators, not as the division pattern in our study. In Vietnam, N.T.Quynh divided into 2 rows including medial and lateral. However, this pattern was based on the horizontal axis of rectus abdominis muscle, not the horizontal of abdominal wall, thus, in fact, these two rows belonging the medial row in Hartrampf's pattern or the medial and lateral in our study's pattern. Wong C et al. found that the peripheral branches were larger in diameter and tend to run straight, which helped the surgeon dissect faster and easier [5]. The perforators in the lateral row were used for semi-abdominal flap having more than one centre and the risk of necrosis of a part of flap's apex or border. Thus, the semi-abdominal flaps tended to be safe when they are taken based on a simple perforator in the lateral row. Holm et al. did several studies of the blood supply area and they proved that Hartrampf's space II and III needed to be converted. The authors emphasised that the division pattern of Hartrampf was wrong and "the blood supply area which goes through middle line was always delayed and less ingrained than the other area in the same side" [7]. Hamdi M et al. found that the perforators in the lateral row were larger and dissected more easily. The perforators in the medial row supplied blood better for space III and IV, however, if the surgeons want to dissect these vessels, they have to dissect a segment of a vessel running in the muscle longer, and this procedure is much along the vertical axis. The perforator ran through the rectus muscle which has transverse tendinous. The distance from this area to skin was shorter, it might be difficult to dissect these vessels.

In conclusion, the direction of the superficial epigastric artery running toward inguinal ligament was almost in the middle row. When this artery reached the anterior superior iliac spine, it belonged to the lateral row. Once mapping the perforators in the abdominal wall, most perforators were in the medial row (93-100%), and there were very few perforators in the lateral row. Mapping the perforators in the abdominal wall based on 3 rows (medial, middle and lateral) in the line between the anterior superior iliac spine and the vertical axis running through the navel, the proportion rates of the perforators in the medial and middle row were 70% and 30%, respectively. The percentage of the superficial epigastric artery running toward the anterior superior iliac spine was observed at 65%. Once mapping blood area, this artery supplied for the 4cm-distance lateral row, while the deep inferior epigastric artery supplied for the middle and medial rows.

References

1. Tran NV, Buchel EW, Convery PA. Microvascular complications of DIEP flaps. *Plastic and reconstructive surgery*. 2007; 119(5):1397-405. <https://doi.org/10.1097/01.prs.0000256045.71765.96> PMID:17415232
2. Masia J, Kosutic D, Clavero JA, Larranaga J, Vives L, Pons G. Preoperative computed tomographic angiogram for deep inferior epigastric artery perforator flap breast reconstruction. *Journal of reconstructive microsurgery*. 2010; 26(01):021-8. <https://doi.org/10.1055/s-0029-1223854> PMID:19742426
3. Quynh N.T. Study on anatomy of the abdomen muscle flap on Vietnamese people: Hanoi Medical University; 2006.
4. Saber AA, Mesleman AM, Davis R, Pimentel R. Safety zones for anterior abdominal wall entry during laparoscopy: a CT scan mapping of epigastric vessels. *Annals of surgery*. 2004; 239(2):182. <https://doi.org/10.1097/01.sla.0000109151.53296.07> PMID:14745325 PMCID:PMC1356210
5. Wong C, Saint-Cyr M, Mojallal A, Schaub T, Bailey SH, Myers S, et al. Perforasomes of the DIEP flap: vascular anatomy of the lateral versus medial row perforators and clinical implications. *Plastic and reconstructive surgery*. 2010; 125(3):772-82. <https://doi.org/10.1097/PRS.0b013e3181cb63e0> PMID:20195105
6. Erić M, Ravnik D, Žic R, Draganić N, Krivokuća D, Lekšan I, et al. Deep inferior epigastric perforator flap: An anatomical study of the perforators and local vascular differences. *Microsurgery*. 2012; 32(1):43-9. <https://doi.org/10.1002/micr.20944> PMID:22113874
7. Hamdi M, Rebecca A. The deep inferior epigastric artery perforator flap (DIEAP) in breast reconstruction. In *Seminars in plastic surgery* 2006; 20(02):095-102. <https://doi.org/10.1055/s-2006-941716> PMCID:PMC2884777