

The Correlation between the Structures of the Nasal Tip on the Ultrasound and the Anthropometry of the Nose in Vietnamese

Tran Dang Khoa^{1*}, Nguyen Thanh Van², Ho Nguyen Anh Tuan¹, Nguyen Duy Bac³, Pham Dang Dieu¹, Nguyen Thi Phuong⁴, Vu Thi Nga⁵

¹Department of Anatomy, Pham Ngoc Thach University of Medicine (PNTU), Ho Chi Minh City, Vietnam; ²Thanh Van Cosmetic Surgery Hospital, Ho Chi Minh City, Vietnam; ³Department of Anatomy, Vietnam Military Medical University (VMMU), Hanoi, Vietnam; ⁴NTT Hi-tech Institute, Nguyen Tat Thanh University, Ho Chi Minh City, Vietnam; ⁵Institute for Research and Development, Duy Tan University, Danang, Vietnam

Abstract

Citation: Khoa TD, Van NT, Tuan HNA, Bac ND, Dieu PD, Phuong NT, Nga VT. The Correlation between the Structures of the Nasal Tip on the Ultrasound and the Anthropometry of the Nose in Vietnamese. Open Access Maced J Med Sci. 2019 Dec 30; 7(24):4214-4219. <https://doi.org/10.3889/oamjms.2019.363>

Keywords: The protrusion of the nasal tip; The nasal tip; The interdomal fat pad; Tip point

***Correspondence:** Tran Dang Khoa, Department of Anatomy, Pham Ngoc Thach University of Medicine (PNTU), Ho Chi Minh City, Vietnam. E-mail: khoatrandr@gmail.com

Received: 26-May-2019; **Revised:** 20-Nov-2019; **Accepted:** 21-Nov-2019; **Online first:** 15-Oct-2019

Copyright: © 2019 Tran Dang Khoa, Nguyen Thanh Van, Ho Nguyen Anh Tuan, Nguyen Duy Bac, Pham Dang Dieu, Nguyen Thi Phuong, Vu Thi Nga. This is an open-access article distributed under the terms of the Creative Commons Attribution-NonCommercial 4.0 International License (CC BY-NC 4.0)

Funding: This research did not receive any financial support

Competing Interests: The authors have declared that no competing interests exist

BACKGROUND: Nowadays, there are few types of research held in Vietnam to investigate the anthropometric index of the nose as well as analysis the structure of nasal tip on ultrasound to identify the relationship between these parameters.

AIM: To determine the relationship between the height and the width of the nasal tip and the structures constructed these areas by anthropometric and ultrasound measurement.

METHODS: A descriptive study in Thanh Van Hospital from December 2017 to April 2019.

RESULTS: There were 94 women (62.7%), and 56 men (37.3%) and the average age were 33.6 years old. The height and width of the nasal tip are 10.1 mm and 21.7 mm, respectively. Through the ultrasound, the thickness of the adipose tissues is 3 mm. The width of the interdomal fat pad is 6.5 mm and the distance between two tip point is 5.6 mm. There are the relationships between the distance of two tip points and the width of the tip ($r = 0.341$), and the width of the interdomal fat pad ($r = 0.72$). There is also the correlation between the width of the nasal tip with the distance of two tip points ($r = 0.46$) and the height of the tip with the thickness of the interdomal fat pad ($r = 1.23$).

CONCLUSION: The thickness of the interdomal fat affects the height of the tip, and the distance of two tip points influences the width of the tip.

Introduction

The structures such as lower lateral cartilages, tip points, interdomal area, interdomal fat pad, interdomal ligament are described widely and in detail by the ENT clinicians and the cosmetic doctors. In contrast, the anatomists describe the structure of the nose at the level of morphology and simplicity [1]. Most surgeons noticed that rhinoplasty on nasal tip was extremely difficult because the nasal tip after the operation should look natural if not, people know that nose had undergone a rhinoplasty, and the complexity of nose anatomies such as tip points, interdomal fat

pad, interdomal ligament and the harmony of nose on face [2]. Moreover, the characteristics of structures which build nasal tip change depending on the anthropometric index of a race, it made nose harmonise with the other structures on a face. Thus, the operation may be complex because of the mobility, variety and anthropometric index [3].

Nowadays, there are many extensive studies about the anthropometric index of nose and face. However, there are few types of research held in Vietnam to investigate these dimensions as well as analysis the structure of nasal tip on ultrasound to identify the relationship between these parameters.

Thus, we started a study “The correlation between the structures of the nasal tip on the ultrasound and the anthropometry of the nose in Vietnamese” with two objects: 1) Identify the relationship between the anthropometry of the height of nasal tip and the thickness of the soft tissues on the nasal tip by ultrasound and 2) Identify the relationship between the anthropometry of the width of nasal tip and the distance between two tip points and the interdomal fat pad by ultrasound.

Processing and Analysing data

Statistics, description, processing, and analysing data with the statistical test in SPSS 19. We compared the average values by the t-test and the ratios by X^2 test, CI 95%. We used multivariable linear regression to find the relationship.

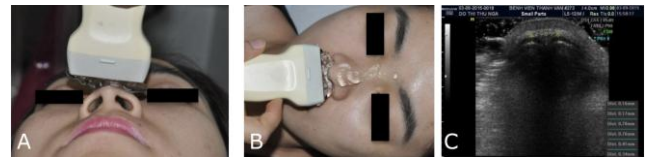


Figure 1: The patient's position when we did an ultrasound

Material and Methods

Study design

Descriptive cross-sectional study.

Participants

We chose 150 adults Vietnamese by convenient sampling method.

Inclusive criteria: 1. Adult Vietnamese, 18 years old and above; 2. The nasal tip is intact; the participant has never undergone any surgery on the nose; and 3. The participant has no congenital malformation, trauma, cosmetic surgery, tumour or anatomic abnormality in structures of the face.

Exclusive criteria: We excluded people who use filler in the nose area or have dyslipidemia or Cushing syndrome. - Study period: from December 2017 to April 2019 and - Study area: Thanh Van Hospital in HCMC.

Study materials: - A calliper, compass, anthropometric ruler; - Camera NIKON D90, lens Nikon AF-S Micro NIKKOR 60 mm 1: 2.8G ED; and - Ultrasound machine Accuvix with probe 12MHz.

Measuring the anthropometric index of face

We used a calliper to measure the index such as distance from nasion (n), (g) to the subnasal point (sn) directly. We recorded and measured the dimensions of nasal tip such as the protrusion of nasal tip, width and height of nasal tip.

Using ultrasound

We used ultrasound machine with probe 12 MHz to measure the thickness of the skin at the nasal tip, the thickness of the subcutaneous fat pad, the width, height and thickness of the interdomal fat pad, the thickness of the cartilage at the tipping point and the distance between two tip points.

Results

We investigated 150 patients including 94 females (62.7%), 56 male (37.3%) and the average age is 33.6 ± 13.4 years old (Table 1) (ranged from 18 to 65 years old) (E.g. 1 case in Figure 1).

The relationship between the anthropometry of the height of the nasal tip and the thickness of the soft tissues on the nasal tip by ultrasound

The average protrusion of the nasal tip is 16.9 mm; the average height of the nasal crus is 6.8 mm; the average height of the nasal tip is 10.1 mm. These dimensions are significantly different between the two sex ($p < 0.05$) and these dimensions of the male are more than ones of female (Table 1).

Table 1: The dimensions of nasal tip

The dimensions of nasal tip	Male (n = 56)	Female (n = 94)	Total (n = 150)	P-values
The protrusion of nasal tip (sn-prn)	17.8 ± 3.3	16.4 ± 3.8	16.9 ± 3.7	0.023 ^e
The height of nasal crus (sn-c)	7.3 ± 1.3	6.6 ± 1.2	6.8 ± 1.3	0.001 ^e
The height of nasal tip (c-prn)	10.5 ± 3.0	9.9 ± 4.0	10.1 ± 3.6	< 0.001

c. T-student test; e. Mann-Whitney test.

The thickness of the skin at interdomal area is 3 mm, the thickness of subcutaneous fat tissue at interdomal area is 3 mm.

Table 2: The thickness of soft tissue on nasal tip on ultrasound

Dimension (mm)	Male (n = 56)	Female (n = 94)	Total (n = 150)	P-values
Skin at interdomal area	3.0 ± 0.5	2.8 ± 0.5	2.9 ± 0.5	0.167 ^c
Subcutaneous fat tissue at interdomal area	3.1 ± 0.7	2.9 ± 0.7	3.0 ± 0.7	0.160 ^c
Interdomal fat pad	3.1 ± 0.7	2.9 ± 0.7	3.0 ± 0.5	0.09 ^c

c. T-student test.

There is no significant difference in the thickness of subcutaneous fat tissue between male and female ($p > 0.05$) (Table 2) (Figure 2).

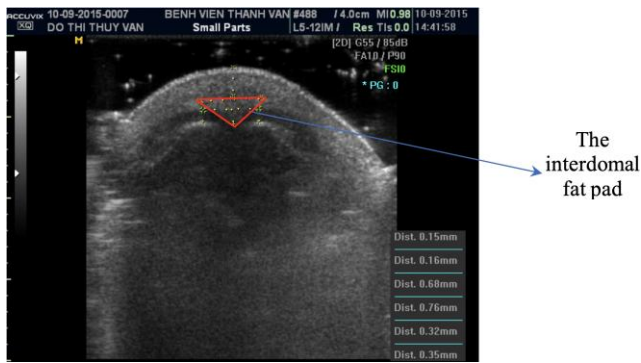


Figure: 2 The interdomal fat pad on ultrasound

The result showed that the male's cartilage at tip point is thicker than females.

Table 3: The thickness of cartilage of nasal tip on ultrasound

Thickness of cartilage	Male (n = 56)	Female (n = 94)	Total (n = 150)	p-values
The right tip point	2.2 ± 0.5 mm	1.7 ± 0.4 mm	1.9 ± 0.5 mm	0.0001 ^e
The left tip point	2.2 ± 0.5 mm	1.7 ± 0.4 mm	1.9 ± 0.5 mm	0.0001 ^e

e. Mann – Whitney test.

With Table 2, the patients' cartilage of tip point in both sides is thicker than on ultrasound ($p = 0.0001$) (Table 3) (Figure 3).

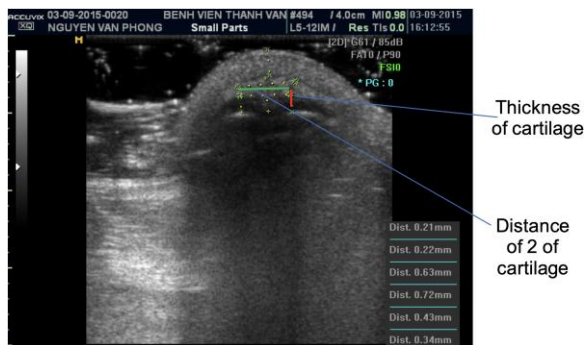

Figure: 3 The thickness of cartilage and distance between two tip points on ultrasound

Investigating the relationship between the height of the nasal tip on external and internal structures

In single variable correlation, the height of tip point is closely correlated with the thickness of interdomal fat pad, the thickness of interdomal subcutaneous fat tissue and the thickness of skin and interdomal fat pad, and it is not correlated with the thickness of interdomal skin and the thickness of cartilage on tip point (Table 4).

Table 4: The correlation between the height of the nasal tip and the other structures (in single - variable correlation)

The correlation of the height of the nasal tip and	Coefficient	p
The thickness of interdomal skin	0.18	0.764
The thickness of interdomal fat pad	1.19	0.003
The thickness of subcutaneous fat tissue	0.99	< 0.001
The thickness of cartilage on the right nasal tip point	0.11	0.862
The thickness of cartilage on the left nasal tip point	0.39	0.512
The thickness of skin and interdomal subcutaneous fat tissue	1.01	< 0.001

There is a close relationship between the height of the nasal tip and the thickness of interdomal fat pad. The equation to estimate the height of nasal tip: The height of the nasal tip ($c'-prn$) = $6.7 + 1.23 x$ the thickness of interdomal fat pad (Table 5).

Table 5: The correlation between the height of the nasal tip and the other structures (in multivariable correlation)

The correlation between the height of the nasal tip ($c'-prn$) and	Coefficient	p
The thickness of interdomal skin	0.003	0.996
The thickness of interdomal fat pad	1.23	0.004
The thickness of cartilage on the right nasal tip point	- 0.89	0.364
The thickness of cartilage on the left nasal tip point	0.78	0.394
Constant	6.70	0.005

The anthropometric index of the width of the nasal tip

The index of the width of the nasal tip is different between male and female ($p < 0.05$); these male's index is larger than female's (Table 6).

Table 6: The index of the width of nasal tip

The index of the width of nasal tip	Male (n = 56)	Female (n = 94)	Total (n = 150)	p
The width of nasal tip	23.1 ± 2.3	20.9 ± 2.0	21.7 ± 2.4	0.0001 ^e
The width of crus at the bottom of nose ($sn'-sn'$)	6.1 ± 1.0	5.5 ± 1.0	5.7 ± 1.0	0.001 ^e
The width of crus at the top of nose ($c'-c'$)	11.1 ± 1.8	9.9 ± 1.5	10.3 ± 1.7	0.0001 ^e

c. T-student test; e. Mann-Whitney test.

The distance between two tip points and the width of interdomal fat pad

The male's distance between two tip points is $5.8 ± 1.7$ mm, the female's one is $5.6 ± 1.2$ mm, and the average distance is $5.6 ± 1.4$ mm, there is no significant difference about these indexes between male and female ($p = 0.319$) (Table 7).

Table 7: Classification of the distance between two tip points on ultrasound

Classification of the distance between two tip points	Male (n = 56)		Female (n = 94)		Total (n = 150)	
	n	%	n	%	n	%
2 – 4 mm	8	14.3	9	9.6	17	11.3
4 – 6 mm	24	42.9	51	54.3	75	50.0
6 – 8 mm	17	30.4	30	31.9	47	31.3
8 – 10 mm	6	10.7	3	3.2	9	6.0
> 10 mm	1	1.8	1	1.1	2	1.3

The distance between two tip points on ultrasound is more than 6 mm, which would decrease 38.6%, and there is no significant difference in this distance between male and female.

Table 8: The dimension of interdomal fat pad on ultrasound

Dimensions	Male (n = 56)	Female (n = 94)	Total (n = 150)	p-values
The width of interdomal fat pad	6.5 ± 1.9	6.4 ± 1.8	6.5 ± 1.4	0.89 ^e
The thickness of interdomal fat pad	3.1 ± 0.7	2.9 ± 0.7	3.0 ± 0.5	0.09 ^e

c. T – student test; e. Mann – Whitney test.

The thickness of cartilage on tip point in male is 2.2 mm, which is thicker than in female (1.7 mm); and

the thickness of cartilage on tip point in patient is thicker than in cadaver on both sides.

The thickness of interdomal fat pad equals 1/2 the width (6.5 mm in average), and there is a significant difference between male and female, the male's one is thicker than female's (p < 0.05) (Table 8) (Figure 4).

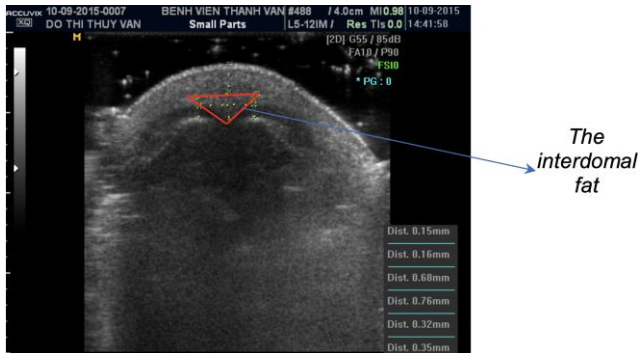


Figure: 4 The interdomal fat pad on ultrasound

Investigating the relationship between the width of the nasal tip on external anatomy and internal structures

By investigating the relationship between two nasal tip points with the width of the nasal tip on ultrasound, we found that the relative coefficient (r) = 0.341 with p = 0.001.

We also considered the correlation between the distance of two tip points and the width of interdomal fat pad in population study and we found that the relative coefficient r = 0.72 (p = 0.001).

The linear correlation equation: the distance between two tip points = 2.356 + 0.612 x the width of interdomal fat pad.

In single variable correlation, we found that there is a correlation between the width of nasal tip and the distance between two tip points, the width of interdomal fat pad and two factors above (Table 9).

Table 9: The relationship between the width of the nasal tip and the other structure (in single variable correlation)

The correlation between the width of the nasal tip and	Coefficient	p
The distance between two tip points	0.6	< 0.001
The width of interdomal fat pad	0.39	< 0.001
The distance between two tip points and the thickness of interdomal fat pad	0.28	< 0.001

When analysing with multivariable correlation, we noted that the width of the nasal tip correlates with the distance between two tip points.

Table 10: The correlation between the width of the nasal tip and the other structure (in multivariable correlation)

The correlation between the width of the nasal tip and	Coefficient	p
The distance between two tip points	0.46	0.012
The width of interdomal fat pad	0.16	0.250
Constant	18.12	< 0.001

The equation to estimate the width of the nasal tip: The width of the nasal tip = 18.12 + 0.46 x the distance between two tip points (Table 10).

Discussion

The relationship between the anthropometry of the height of the nasal tip and the thickness of the soft tissues on the nasal tip by ultrasound

In our study, the protrusion of the nasal tip is shorter, compared with the other foreign studies. It demonstrated that Vietnamese nose is shorter, the length of the alar nostril is shorter than the foreigners; the difference is mostly based on the race of the population study (Table 11).

Table 11: The protrusion of nasal tip in some other studies

Dimension	Ngeow W.C. [4]	Anderson K.J. [5]	Duskova M. [6]	Khandekar B. [7]	Choe K.S. [8]	Farkas L.G. [9]	Our research
The protrusion of nasal tip (mm)	17.8	Male: 24.9 Female: 23.0	21.4	Male: 20.4 Female: 16.9	19.6	19.3	Male: 17.8 Female: 16.4

The ratio of the width of nasal tip and the width of nasal soft tissues (al-al) is 0.6, smaller the result of Porter J.P. [10] with white population study (0.75), the difference may be due to the population study. The ratio of the width of nasal tip and the width of the nose in anatomy is 80%, which much higher than the result of Prendergast P.M. [11] (35-45%), it demonstrated that the Vietnamese nasal tip is bigger than the others. The big nasal tip is one of the characteristics of Asian and African people, the factors contributing the big nasal tip are the distance between two tip points, the divergent angle of the nasal tip, the interdomal fat pad and the thickness of nasal SMAS. Thus, how to choose an appropriate method to diminish the width of the nasal tip is too difficult for the surgeon. These methods include interdomal suture, transdermal suture, SMAS resection.

The ratio of the height of nasal tip and the height of nasal base in our study is 0,6 or 3/5, which larger than the result of Prendergast P.M. [11] (1/3 in White people), Porter J.P. [11] (2:1), and Farkas L.G. [9] (58,2). It demonstrated that the height of the Vietnamese nasal tip is more than 1/2 the protrusion of nasal tip. In other word, the Vietnamese nasal tip is thick, big and nasal crus is short.

All the values and ratios made a general point of view about Vietnamese nasal base, whose characteristics are short, wide, nasal nostril is puff, nasal crus is short and nasal tip is big and thick. These are reasons which make rhinoplasty become one of the most popular cosmetic surgery to

restructure nasal tip and base by diminishing nasal tip and alar base reduction, lengthening nasal crus.

We investigated the relationship between the height of nasal tip and the other structures such as the thickness of cartilage at nasal tip point, the thickness of interdomal fat pad, the skin of interdomal area, interdomal subcutaneous fat tissue. In single variable correlation, the height of tip point is closely correlated with the thickness of interdomal fat pad, the thickness of interdomal subcutaneous fat tissue and the thickness of skin and interdomal fat pad, and it is not correlated with the thickness of interdomal skin and the thickness of cartilage on tip point. When investigating the multivariable correlation between the factors affecting the height of the nasal tip, we found that there is a close relationship between the height of the nasal tip and the thickness of the interdomal fat pad.

By investigating the single and multi-variable correlations, we found that the height of the nasal tip is affected most by the thickness of interdomal fat pad. This object should be noted in the rhinoplasty on a nasal tip because it can change the dimensions of this area when interceding the interdomal fat pad.

The relationship between the anthropometric index of the width of the nasal tip and ultrasound

We found that the thickness of cartilage on tip point in male is 2.2 mm, which thicker than in female (1.7 mm). Our results are consistent with the other foreign studies which showed that the nasal tip point has the thickest cartilage, the tip points of two domain area in both sides would build up the nasal tip. Thus, the distance between the two tip points would affect the nasal tip.

In our study, the distance between two tip points on ultrasound is more than 6 mm, which would decrease by 38.6%, and there is no significant difference in this distance between male and female. So, the prevalence of big Vietnamese nose is about 40%. The Asian nasal tip is often bigger and less prominent than the White people because [1] the fat fibre tissue of interdomal area is thicker and the distance between the tip points is larger, [2] the medial crus of LLC does not adhere to the nasal septum cartilage, [3] the Asian LLC develop less than the White's one. However, it is not smaller [1] and [4] the last important reason which affects the nasal tip is the thickness of nasal SMAS.

The results showed that this fat pad is subcutaneous, thickest at the nasal tip area, it covered all the interdomal area, about 50% patients having a medium-thick skin or above also have an interdomal fat pad and even when they have a thin skin, they also have this fat pad [12]. In our study, the interdomal fat pad is 1.8 – 3.2 mm, it lied in the interdomal area about 2.9 mm. Our results are

consistent with the results of Copcu E. which found that the dimension 1.8 x 3.2 mm [12], but our results are larger than the results of Anderson K.J. [5], which found that the thickness of fat pad on nasal tip in male and female is 0.38 mm and 0.19 mm, respectively.

By investigating the relationship between two nasal tip points with the width of the nasal tip on ultrasound, we found that the relative coefficient ($r = 0.341$; $p = 0.001$) showed that the effect was at the medium level (perhaps the further the distance is, the bigger the nasal tip is).

We also considered about the correlation between the distance of two tip points and the width of interdomal fat pad in population study and us found that the relative coefficient $r = 0.72$ ($p = 0.001$), this means it is a close correlation, the width of interdomal fat pad would mostly affect the distance of two tip points, the thicker and wider this fat pad is, the bigger the nasal tip is. Based on this result, we designed a linear correlation equation: the distance between two tip points = $2.356 + 0.612 \times$ the width of interdomal fat pad. We showed the interdomal fat pad has an important role more than the distance of two tip points and the domal divergent angle this fat pat attached to nasal SMAS. Thus, we could confirm that the nasal tip is big because of the interdomal fat pad and the thickness of nasal SMAS, which can be investigated before the operation procedure by ultrasound.

By investigating the single variable correlation between the width of nasal tip using anthropometric index on ultrasound such as the distance between two tip points and the width of interdomal fat pad, we found that there is a correlation between the width of nasal tip and the distance between two tip points, the width of interdomal fat pad and two factors above. When analysing with multivariable correlation, we noted that the width of the nasal tip has a close correlation with the distance between two tip points.

In conclusion, the height and width of the nasal tip, the protrusion of nasal tip is significantly different between male and female; the dimensions of the male are larger than of female. There is a relationship between the distance between two tip points and the width of interdomal fat pad. By investigating the nasal tip, we found that the thickness of interdomal fat pad would affect the height of the nasal tip, the distance of two tip points would affect the width of the nasal tip. During operation procedure of rhinoplasty, we should notice about the interdomal fat pad and the nasal tip.

Ethical approval

All procedures performed in studies involving human participants were in accordance with the

ethical standards of institutional and/or national research committee and with the 1964 Helsinki declaration and its later amendments or comparable ethical standards. This study was approved by The Pham Ngoc Thach university research committee with No 005.

Informed Consent

Informed consents were obtained from the patients included in the study.

Acknowledgement

We would like to thank Ms. Hoang Thi Anh (Faculty of Biology, Hanoi National University of Education, Hanoi, Vietnam) checking and improving the English in the manuscript.

References

1. Dieu PD. Anatomy of the Head, Face and Neck. Ho Chi Minh City: Medical Publishing House; 2010.
2. Soliemanzadeh P, Kridel RWH. Tip Grafts in Revision Rhinoplasty. Facial Plastic Surgery Clinics of North America. 2006;

- 14:331-41. <https://doi.org/10.1016/j.fsc.2006.06.014> PMID:17088181
3. Burrell S. Tip Points: Defining the Tip. Aesthetic Plastic Surgery. 1999; 23:113-8. <https://doi.org/10.1007/s002669900252> PMID:10227911
4. Ngeow WC, Aljunid ST. Craniofacial anthropometric norms of Malays. Singapore Medical Journal. 2009; 50(5):525-8.
5. Anderson KJ, Henneberg M, Norris RM. Anatomy of the nasal profile. American Journal of Anatomy. 2008; 213:210-6. <https://doi.org/10.1111/j.1469-7580.2008.00924.x> PMID:19172735 PMCid:PMC2526105
6. Duskova M, Kristen M, Smahel Z. The Anthropometric Verification of Corrective Surgery Outcome in Cleft Secondary Deformities. The Journal Of Craniofacial Surgery. 2006; 17(3):447-53. <https://doi.org/10.1097/00001665-200605000-00011> PMID:16770180
7. Khandekar B, Srinivasan S, Mokal N. Anthropometric analysis of lip-nose complex in Indian population. Indian Journal of Plastic Surgery. 2005; 38(2):128-31. <https://doi.org/10.4103/0970-0358.19781>
8. Choe KS, Yalamanchili HR, Litner JA. The Korean american woman's nose. Archives of Facial Plastic Surgery. 2007; 8:319-23. <https://doi.org/10.1001/archfaci.8.5.319> PMID:16982988
9. Farkas LG, Kolar JC, Munro IR. Geography of the Nose: A Morphometric Study. Aesthetic Plastic Surgery. 1986; 10:191-223. <https://doi.org/10.1007/BF01575292> PMID:3812136
10. Porter JP, Lee JI. Facial analysis: maintaining ethnic balance. Facial Plastic Surgery Clinics of North America. 2002; 10:343-9. [https://doi.org/10.1016/S1064-7406\(02\)00030-5](https://doi.org/10.1016/S1064-7406(02)00030-5)
11. Prendergast PM. Facial Proportions: Advanced surgical facial rejuvenation Art and Clinical practice, Springer; 2012. https://doi.org/10.1007/978-3-642-17838-2_2
12. Copcu E, Metin K, Ozsunar Y, et al. The interdomal fat pad of the nose: a new anatomical structure. Surgical and Radiologic Anatomy. 2004; 26:14-8. <https://doi.org/10.1007/s00276-003-0172-4> PMID:14574464