

# Anatomical Characteristics of Facial Nerve Trunk in Vietnamese Adult Cadavers

Tran Dang Khoa<sup>1</sup>, Nguyen Duy Bac<sup>2</sup>, Hoang Van Luong<sup>2</sup>, Tran Ngoc Anh<sup>2</sup>, Nguyen Thi Phuong<sup>3</sup>, Vu Thi Nga<sup>4</sup>, Toi Chu Dinh<sup>5</sup>

<sup>1</sup>Department of Anatomy, Pham Ngoc Thach University of Medicine (PNTU), Ho Chi Minh City, Vietnam; <sup>2</sup>Department of Anatomy, Vietnam Military Medical University (VMMU), Hanoi, Vietnam; <sup>3</sup>NTT Hi-tech Institute, Nguyen Tat Thanh University, Ho Chi Minh City, Vietnam; <sup>4</sup>Institute for Research and Development, Duy Tan University, Danang, Vietnam; <sup>5</sup>Department of Human and Animal Physiology, Faculty of Biology, Hanoi National University of Education, Hanoi, Vietnam

## Abstract

**Citation:** Khoa TD, Bac ND, Luong HV, Anh TN, Phuong NT, Nga VT, Chu Dinh T. Anatomical Characteristics of Facial Nerve Trunk in Vietnamese Adult Cadavers. Open Access Maced J Med Sci. 2019 Dec 30; 7(24):4230-4238. <https://doi.org/10.3889/oamjms.2019.366>

**Keywords:** Facial nerve; Superior ramus; Inferior ramus; Mandibular angle; Retromandibular vein

**\*Correspondence:** Toi Chu Dinh, Department of Human and Animal Physiology, Faculty of Biology, Hanoi National University of Education, Hanoi, Vietnam. E-mail: [chudinhtoi@hnue.edu.vn](mailto:chudinhtoi@hnue.edu.vn)

**Received:** 28-May-2019; **Revised:** 20-Sep-2019; **Accepted:** 21-Sep-2019; **Online first:** 15-Oct-2019

**Copyright:** © 2019 Tran Dang Khoa, Nguyen Duy Bac, Hoang Van Luong, Tran Ngoc Anh, Nguyen Thi Phuong, Vu Thi Nga, Toi Chu Dinh. This is an open-access article distributed under the terms of the Creative Commons Attribution-NonCommercial 4.0 International License (CC BY-NC 4.0)

**Funding:** This research did not receive any financial support

**Competing Interests:** The authors have declared that no competing interests exist

**BACKGROUND:** In medical literature, there are few studies provided a precise and detailed description of the facial nerve rami and its branches.

**AIM:** Identify several practical anatomic landmarks related to the facial nerve main trunk and its rami.

**METHODS:** A descriptive study, 30 cadavers in the anatomy department of UPNT from October 2012 to April 2015.

**RESULTS:** The average distance from the mandibular angle to the division of the facial nerve is 40.8 mm, and is 86.6% from range 36 – 50 mm. There is 86.7% case in which the facial nerve is in the lateral of the retromandibular vein, and there is a significant difference about both sides. Eighty percent of the case has the superior and inferior ramus in the lateral to the retromandibular vein. There are 2 cases in which the superior ramus makes the circle of the vein. Eighty percent of the facial nerve is in the lateral to the external carotid artery.

**CONCLUSION:** The distance from the mandibular to the division of the facial nerve is longer. The relationship between the superior/inferior ramus and the retromandibular vein maybe not the same in both sides. In some cases, it makes the circle of the vein to cause some complication in the parotid gland surgery.

## Introduction

In medical literature, even though many authors already have done many studies about the facial nerve anatomy on Caucasian and non-Caucasian race, specifically about its course through the parotid gland, its rami and its branching pattern to innervate its end-organ, none of them provided precise and detailed description about its rami and its branches [1], [2]. Also, they notice that the variability of the facial nerve origin and ramification proximal to the intraparotid course have an intimate anatomic relationship with other structures such as the digastricus, the mastoid process, the mandibular

angle, the retromandibular vein, the external carotid artery, etc. [1], [3]. Therefore, achieving a basic understanding of the exact course of the facial nerve in the parotid gland and its rami is critical for every surgeon to prevent facial nerve injury in parotid gland-related surgeries. There are anatomic landmarks that help pinpoint the facial nerve trunk, e.g. mastoid process, posterior belly of the digastricus, tragal “pointer”, retromandibular vein, etc. [4]. The key to successfully locate the facial nerve trunk lies in those landmarks that act as reference points for the surgeons to predict the safety of nearby structures. Additionally, given that these reference points are fixed during surgery, they should be easily palpable and should permit surgeons to quickly, safely identify

and preserve anatomic structures.

Based on our assumptions as mentioned above, we've decided to conduct a study on "The anatomic characteristics of the facial nerve trunk in Vietnamese cadavers". This study aims to (1) describe the facial nerve trunk anatomy as well as its rami in Vietnamese adult cadavers, (2) to identify several practical anatomic landmarks related to the main trunk and its rami.

## Materials and methods

### Design

Descriptive cross-sectional study, on 30 hemifaces that belong to formalin-treated male and female Vietnamese cadavers, at the Department of Anatomy of Pham Ngoc Thach University of Medicine, from October 2012 to April 2015. We used a convenient sample from the available population of cadavers at the university. The average age of the cadavers is 70, in which female accounts for 33.3% and male 66.7% (10 females: 20 males).

The inclusion criteria were: 1. Vietnamese adult cadaver, older than 18 years of age; 2. The head, face, and neck must be intact with no previous surgical history in these regions; and 3 — the normal anatomy of the head, face, and neck. No deformities or tumours allowed.

Exclusion criteria: All cadavers that have deformities in the head, face and neck region, as well as damaged cadavers due to dissection errors or previous facial, parotid gland-related surgeries.

### Dissection techniques and data collection

First, an incision was made along the external auditory canal – lateral canthus, and then continued the incision along the orbital rim, 30 mm above the supraorbital margin. The incision will go from the superolateral orbital rim to the aperture of the external auditory canal and run along the superior temporal line. Then make an incision from the earlobe and continue parallel with the mandibular ramus and then go along the orbicularis oris. The skin is then separated, the second layer is then exposed, continue dissecting the second layer into the third layer; the incision is perpendicular with external auditory canal – lateral canthus line and is 40mm lateral to the external ear canal, and the inferior incision still goes along the mandibular ramus. These incisions will be dissected into the third layer. Dissecting the third layer (SMAS) based on the available incisions, reflecting the SMAS the zygoma superiorly, until the flap reaches the zygomatic and orbital ligaments, masseteric ligaments anteriorly, and mandibular ligaments inferiorly.

Continue dissecting the SMAS towards the orbicularis oculi muscle, the temporal, the nose, mouth, chin, and neck.

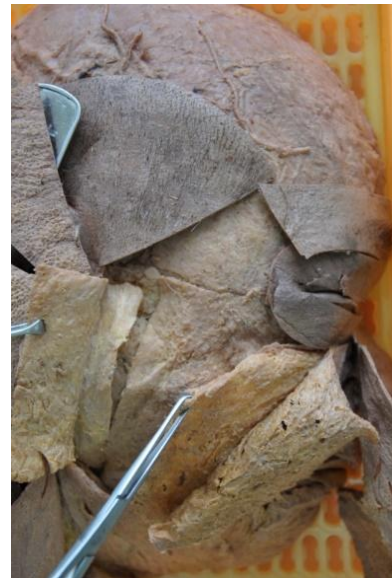

Figure 1: Exposed third layer (SMAS)

The fourth layer is exposed, namely sub-SMAS (Figure 1), the parotid fascia is dissected carefully so that facial nerve branches are not damaged. Identify anatomic landmarks such as the mastoid process, the suprasternal notch, and the clavicles to mark the anterior margin of the sternocleidomastoid muscle. Expose the following landmarks: the cartilaginous portion of the ear canal and the posterior belly of the digastric. The facial nerve trunk usually lies deep, 10 – 15 mm below the anteroinferior margin of the cartilaginous portion of the ear canal (so-called tragal "pointer"), and 10 mm below and deep to the midpoint of the posterior belly of the digastric. After identifying the facial nerve trunk, proceed to dissect along the main trunk to expose the two following rami: zygomaticotemporal ramus and the cervicofacial branch, sometimes a third ramus can exist. Dissect and expose the retromandibular vein and the external carotid artery.

### List of parameters to be collected

- Relationship between the retromandibular vein and the facial nerve rami: whether the vein is lateral or medial to the nerve.
- Relationship between the superior, inferior division and the retromandibular vein.
- Relationship between the external carotid artery and the main trunk as well as its ramification: whether the artery is lateral or medial to the nerve.
- The number of branches of the temporofacial ramus and the cervicofacial ramus.
- Branching pattern of the facial nerve main

trunk based on Tsai's studies and branching pattern of its division based on Davis et al. classification.

- Mean distance of the facial nerve trunk from the skin surface after it emerges from the stylomastoid foramen.

- Mean angle formed by the facial nerve rami: superior, middle, inferior and other division (if available).

- Diameter and length of the facial nerve trunk, superior and inferior division.

All parameters are collected into a data sheet (see attached files). Measurement values are rounded to the nearest tenth.

## Materials

Measurements and data were collected using:

- A Nikon D90 digital single-lens reflex camera, Macro lens equipped;
- A dissection kit: scalpel, dissection knife, Kelly clamp, Allis clamp, toothed and non-toothed forceps, single-prong hook, double-prong hook; and
- Measurement devices include: analogue calliper, a compass, a depth gauge, a protractor.

### Statistical procedures

- Raw data were collected from measurement records and encoded in corresponding variables. These statistics are analysed by calculating Pearson's Chi-squared exact test as well as Student's t-test using SPSS 19.0. Measurements are rounded to the nearest tenth, and  $p < 0.05$  is considered statistically significant.

## Results

In this study, we've done dissections on 30 hemifaces with an average of 70, in which female accounts for 33.3% and male 66.7%.

We identify the facial nerve trunk quickly and safely using the centre of the triangle formed by the temporomandibular joint, mastoid process and the angle of the mandible, as these reference points are easily palpable during the dissection. Besides, we also employ the commonly accepted classical approach to localise the facial nerve trunk for its safety as it exits the stylomastoid foramen, which is to find landmarks such as the posterior belly of the digastricus to measure its depth, the mandibular angle, the retromandibular vein, and the tragal "pointer". In this approach, the relationship between

the nerve trunk and the retromandibular vein along with the bifurcation location of the former about the mandibular angle and the posterior belly of the digastricus are easily identified concerning the tragal "pointer" (Figure 2), because its reference point is difficult to localise.

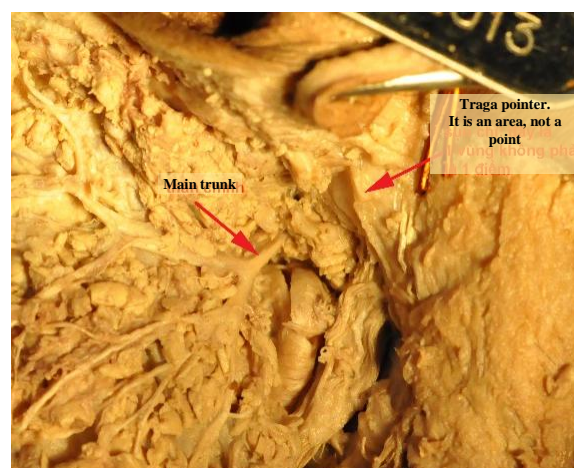


Figure 2: Tragal pointer pointing at the main trunk of the facial nerve

### Anatomical characteristics of facial nerve main trunk

There is only a single facial nerve trunk (Figure 3) emerging from the stylomastoid foramen, and no specimen has been found to have a double trunk.

Mean distance of the right facial nerve trunk from the skin surface after it emerges from the stylomastoid foramen is 28.9 mm, which is deeper than that of the left side, 25.1 mm, and this difference is statistically significant.

The average length of the facial nerve trunk is 14.1 mm. The facial nerve trunk diameter is 2.5 mm.

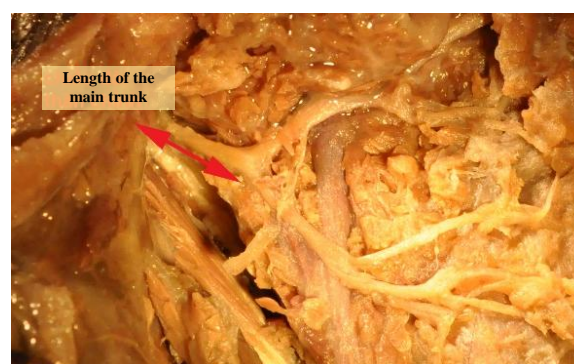

Figure 3: Length of the facial nerve trunk

The average number of divisions is 2.1 on both sides, in which bifurcation of the trunk mostly accounts for 93.3% and trifurcation only accounts for 6.7%.

The angle formed by the superior and inferior division of the main trunk appears to be almost

perpendicular to each other, an angle of  $91.2^\circ$ , in which 66.7% of our specimens are acute, and 33.3% are obtuse.

Mean superior division length is 15.2 mm, which is much shorter than that of inferior division, 23.6 mm.

There are three branching patterns (Figure 4) of the facial nerve trunk, according to Tsai:

- Pattern 1: the main trunk divides into superior and inferior division, closely followed by the bifurcation of the marginal and cervical branches. 20.0% of our specimens displayed this pattern.



Figure 4: Branching pattern 1 of the facial nerve trunk

- Pattern 2 (Figure 5), is the largest group (60% right-sided and 66.7% left-sided), the upper and lower trunks divide, then branch into their 5 respective classical divisions.

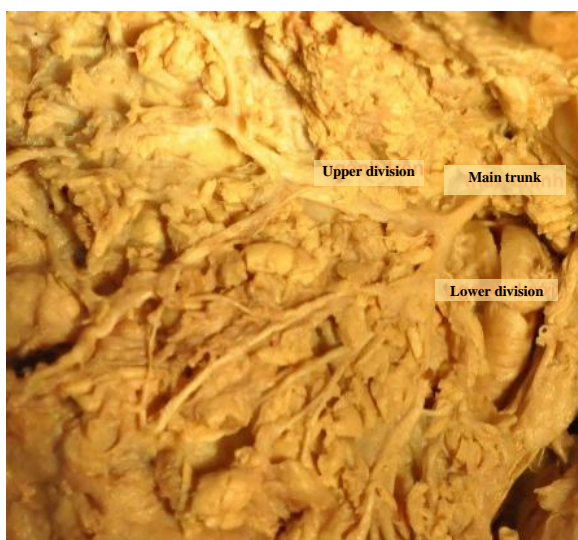

Figure 5: Branching pattern 2 of the facial nerve trunk

+ Pattern 3 (Figure 6): 20% right-sided and 13.3% left-sided, the upper-division branches immediately after the bifurcation of the upper and lower divisions.

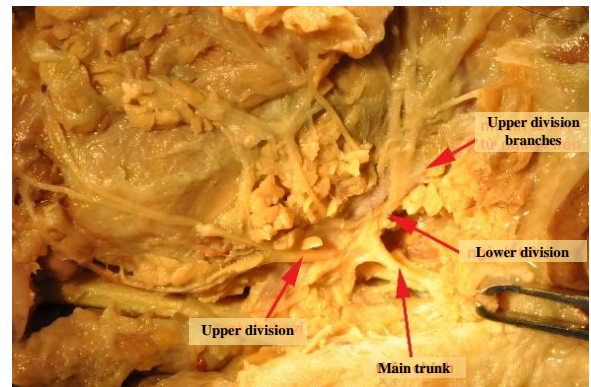


Figure 6: Branching pattern 3 of the facial nerve trunk

### Facial nerve main trunk localisation method and its application

The distance (Figure 7) from the mandibular angle to the bifurcation location of the facial nerve is 40.8 mm.

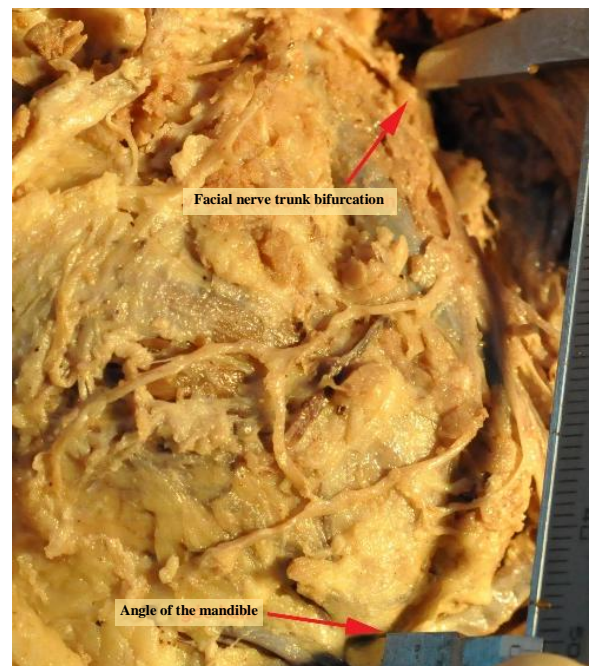


Figure 7: The distance from the angle of the mandible to the facial nerve trunk bifurcation

The distance from the mandibular angle to the bifurcation ranges from 36 – 50 mm and accounts for 86.6% on both sides.

We found that 86.7% of our specimens have facial nerves running laterally to the retromandibular vein on both sides and this difference is statistically significant about the location of the facial nerve to the retromandibular vein on both sides with  $p = 0.03$ , which means the location of the nerve about the vein is not identical on both sides.

In our study, 80% of specimens on both sides, the superior division runs laterally to the retromandibular vein, and we found this difference in the location of the superior division with the vein to be statistically significant on both sides. As for the inferior division, it runs laterally to the vein in 80% of cases on both sides, and we found no statistically significant difference about the location of the facial nerve with the vein on both sides (Figure 8).

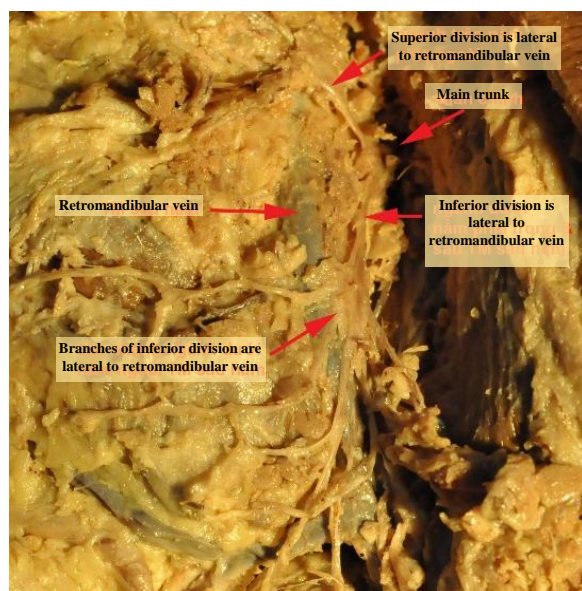


Figure 8: The inferior division's relation to the retromandibular vein, but its branches and the superior division are lateral to the vein

## Discussion

Based on our findings, we conclude that there is only a single facial nerve trunk emerging from the stylomastoid foramen and no specimen has been found to have a double trunk, including one domestic study by Thanh N.V. (1997) [4]. However, a foreign study by Kilic C. has noted the existence of the double facial nerve trunk exiting the stylomastoid foramen [5]. Besides, a study by Katz and Catalano shows that 3% of their specimens have double facial nerve trunk [6], and 4.4% and 13.3% in another study by Park and Lee [7]. Does this inconsistency require a larger sample of cadavers, as well as the need for radiographic characteristics in Vietnamese adults to see whether a double facial nerve trunk exists or not?

Mean distance of the right facial nerve trunk from the skin surface after it emerges from the stylomastoid foramen is 28.9 mm, which is deeper than that of the left side, 25.1 mm. This difference is statistically significant in a way that surgeons have to take precautions when carrying out the surgery on the left hemiface and children because the facial nerve is more superficial in the latter. Therefore in our study,

the location of the facial nerve regarding the skin surface appears to be deeper than that of Myint K [8] (from 10 – 20 mm deeper than the skin), but more superficial than that of Rodrigues (50 mm) [9]. This variation is influenced by many factors which can be different among individuals and races, e.g. skin thickness, subcutaneous tissue, SMAS layer, sub-SMAS layer, and the parotid parenchyma (Table 1).

Table 1: Comparison of length of the facial nerve trunk in literature

Author	Length (mm)
Thanh N.V [4]	22.4
Salame [10]	16.4
Kandari [11]	10 – 15
Dias F.L [12]	13
Rodrigues [9]	10
Ekinci [13]	9
Kwak [14]	9.38
Our study	14.1

The average length of the facial nerve trunk is 14.1 mm, which is shorter when compared to studies of Thanh N.V (22.4 mm) [4] and Salame (16.44 mm) [10], but is equivalent to results from Kandari (from 10 – 15 mm) [11] and Dias F.L (13 mm) [12]. Furthermore, our measurements are longer than those of Rodrigues (about 10 mm) [9], Ekinci (9 mm) [13] and Kwak (9.38 mm) [14]; this difference might vary due to an individual's race and ramification of the main trunk. Salame emphasised the importance of its length in facial nerve anastomosis because the trunk needs to be long enough to allow anastomosis with other branches without being too overstretched or too slack [10].

The average number of divisions is 2.1 on both sides, in which bifurcation of the trunk mostly accounts for 93.3% and trifurcation only accounts for 6.7%; this is in agreement with findings of Myint K [8]. However, as Park and Lee's recommendation stated, surgeons should be suspicious for the presence of the third division as they can accidentally damage it [7]. Based on our findings, trifurcation takes up 6.7% which is in agreement with Park and Lee's findings, 4.4% [7]; but our findings are lower than that of Thanh N.V (24%) [4], Kalaycioğlu A (18.8%) [15], Ekinci (18.6%) [13] and Kopuz (18%) [16], and higher than that of Salame (2.2%) [10]. This disparity might be due to racial factors or inherent inaccuracy in our insufficient sample. Nevertheless, the probability of having the third division is non-negligible (albeit small) has an important meaning to all surgeons: pay attention to its probable existence and avoid injuring it.

Besides, we found that the angle formed by the superior and inferior division of the main trunk appears to be almost perpendicular to each other, an angle of 91.2°, in which 66.7% of our specimens are acute, and 33.3% are obtuse. This is in agreement with Myint K's findings in a way that when the nerve reaches the posterior border of the mandibular ramus, its divisions almost form a perpendicular angle [8]. Meanwhile, Thanh N.V's findings show that 56% are obtuse, and 44% are acute [4]. Mathematically, any angle greater than 90° is obtuse, and if it's less than

90°, it will be an acute angle. However, in our study, the values of the angle formed by the superior and inferior division vary around 90, or in other words, they form a perpendicular angle.

Mean superior division length is 15.2 mm, which is much shorter than that of inferior division, 23.6 mm. This finding is statistically significant and in agreement with Thanh N.V's findings, in which the former is 15.1 mm but the latter is notably shorter than of ours, 12.4 mm [4] (Table 2). This inconsistency in the inferior division is due to individual variability as in our study it travels a considerably long course after its branching from the main trunk before dividing into the mandibular branch, the cervical branch or the anastomotic branch. As for the diameter, the superior is 2 mm and inferior division is 1.4 mm, but when we use paired t-test to compare between the two, the finding isn't statistically significant ( $p > 0.05$ ). Therefore, the diameter of the two is identical. Compared to another domestic study by Thanh N.V, the superior division diameter is 1.94 mm, which agrees with our findings, but the inferior diameter is smaller, 1.07 mm [4]. In contrast with international findings by Myint K, the superior temporofacial division has a diameter nearly twice that of the inferior ramus [8]. As for Pia F's findings, the superior division runs in a superomedial fashion and has a greater diameter [17].

**Table 2: Comparison of pattern ratio in literature**

Author	Pattern 1 (%)	Pattern 2 (%)	Pattern 3 (%)
Tsai [18]	24.7	42.0	33.3
Thanh N.V [4]	10.0	82.0	6.0
Our study	20.0	60.0	20.0

Specifically, 60% of our specimens display pattern 2 on both sides and the ratio between patterns is not statistically significant. Pattern 1 and 3 take up 20% evenly. Compared to Tsai's findings, 24.7% of their specimens display pattern 1 (the main trunk divides into superior and inferior division, closely followed by the bifurcation of the marginal and cervical branches), which agrees with our findings; as for pattern 2 (the upper and lower trunks divide, then branch into their 5 respective classical divisions), their findings are lower than those of us (42%); regarding pattern 3, their findings are higher than those of us [18]. Compared to Thanh N.V's findings, type 1 (equivalent to Tsai pattern 2) accounts for 82%; type 2 (Tsai pattern 3) accounts only 6% and type 3 (Tsai pattern 1) accounts 10% [4].

The distance from the mandibular angle to the bifurcation location of the facial nerve is 40.8 mm, which agrees with Thanh N.V's findings of 38.6 mm [4]. This can be explained by the fact that both authors have conducted their corresponding studies on Vietnamese, so the mandibular ramus length is approximately identical. Besides, according to other authors' explanation, this distance in Caucasian is remarkably longer due to their greater body size as well as larger, stronger mandible. However, in our study, the distance from the angle to the bifurcation is

longer than that of international counterparts, such as Myint K (28.06 mm, range from 11 – 40 mm) [8], McCormack (34 mm on Caucasian, range from 14 – 46.9 mm) [19], Davis et al. (32mm, range from 25 – 45 mm) [20], Park and Lee (28.8 mm on Korean, ranging from 12.1 – 39.8 mm) [7]. Is the facial nerve trunk in Vietnamese truly located at a higher position than other races? To achieve this finding, we need to conduct a study with large enough samples together with location comparison between the main trunk and the mandibular angle about the zygomatic arch.

Besides, the distance from the mandibular angle to the bifurcation ranges from 36 – 50 mm and accounts for 86.6% on both sides, which is drastically higher than Myint K's findings, in which most of their specimens (81.0%) has the bifurcation 21 – 35 mm above the mandibular angle [8] (Table 3).

**Table 3: Comparison of distance from the angle of the mandible to the bifurcation of the facial nerve with Myint K's findings**

Distance in mm	Myint K.		Our study	
	Number	Proportion (%)	Number	Proportion (%)
11 – 15 mm	3	3.8%	0	0%
16 – 20 mm	6	7.6%	0	0%
21 – 25 mm	12	15.2%	0	0%
26 – 30 mm	30	38.0%	0	0%
31 – 35 mm	22	27.8%	3	10.0%
36 – 40 mm	6	7.6%	14	46.7%
41 – 45 mm	0	0%	8	26.7%
46 – 50 mm	0	0%	4	13.3%
51 – 55 mm	0	0%	1	3.3%
	79	100.0%	30	100.0%

We also noticed that the distance from the mandibular angle to the bifurcation of the facial nerve ranges from 31 – 55 mm, compared to Myint K's findings of 11 – 40 mm [8], which means if we divide the distance into 5mm portion, we can miss the in-between values. This could mean that in our upcoming study, maybe we should calculate the ratio between the distances from the bifurcation to the whole mandibular ramus length so that it may be more significant. Identifying the distance from the angle of the mandible to the bifurcation is critical to clinical otolaryngology as it prevents facial nerve injury during parotid gland-related surgeries.

We found that 86.7% of our specimens have facial nerves running laterally to the retromandibular vein on both sides and this difference is statistically significant about the location of the facial nerve to the retromandibular vein on both sides with  $p = 0.03$ , which means the location of the nerve concerning the vein isn't identical on both sides. This finding agrees with Alzahrani, in which 83% of their specimens have facial nerve running laterally to the retromandibular vein, and 17% lies medially to the vein, and this relationship isn't identical on both sides [21]. As for Astik R.B, their findings show that 90% of retromandibular vein lies medially to the temporofacial and cervicofacial division, 10% of their specimens have divisions running laterally to the vein, as the main trunk and its divisions form a "fork" that runs between the mandibular and the superficial temporal vein [22].

In our study, 80% of specimens on both sides, the superior division runs laterally to the retromandibular vein, and we found this difference in the location of the superior division with the vein to be statistically significant on both sides. As for the inferior division, it runs laterally to the vein in 80% of cases on both sides, and we found no statistically significant difference about the location of the facial nerve with the vein on both sides. This is in agreement with Kim et al. findings, larger inferior division mostly runs laterally to the retromandibular vein (83%), and few of them (17%) goes medially to the vein [23]. As for Wang et al., 100% of cases have mandibular branch running at a more superficial layer to the retromandibular vein [3]; Dingman found that 98% of retromandibular veins run medially to the marginal branch and only 2% runs laterally [24]; Savary et al., found that the all cervicofacial division run laterally to the retromandibular vein [25]. Therefore, despite disparities in each of the division's proportion, most of the authors concluded that over 80% of the main trunk, a superior and inferior division run laterally to the retromandibular vein and the location of the facial nerve concerning the nerve might be different between the two sides. Also, we found no difference about the location of the superior and inferior division concerning the right retromandibular vein, but we found a statistically significant difference about the superior division with the left vein ( $p = 0.024$ ). This shows that, on the same individual, the location of the superior and inferior division about the vein can be different ipsilaterally or bilaterally, and the nerve-vein relationship doesn't appear to obey any law as shown by Laing and McKerrow's findings in which the superior division runs laterally and medially to the vein while the inferior division runs laterally [1].

Unexpectedly, Toure G. et al., study shows that there are 4 cases in which the retromandibular vein forms a ring through which the facial nerve trunk travel (2 cases) and the remaining 2 cases have the inferior division goes inferiorly to this venous ring [2]. Also, Alzahrani noted that the retromandibular vein forms two rings and both superior and inferior division go through these rings [21]. This is in contrast with our study in a way that our finding shows the superior division forms a ring around the retromandibular vein (Figure 9), and as a consequence, encountering this variation may increase facial nerve injury risk or cause bleeding during parotid gland tumour removal. In normal anatomical settings, the facial nerve runs laterally to the vein, so bleeding risk due to nerve injury is negligible. However, in special cases, the retromandibular vein runs laterally to the main trunk or its division, so bleeding and facial nerve injury risk will be substantially higher in parotid gland tumour removal surgery.

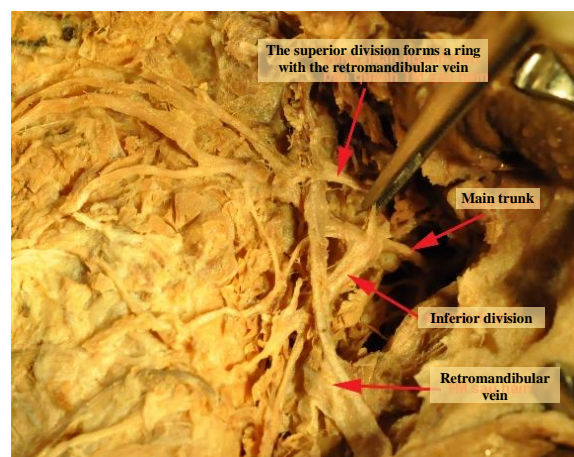


Figure 9: The superior division forms a ring with the retromandibular vein

As for otolaryngology application, Alzahrani F. R. used the retromandibular vein to identify the facial nerve by first successfully identifying the former at the cervical region and then dissect in an upwards fashion to the inferior division of the facial nerve as the latter usually lies superficial to the retromandibular vein. After successfully pinpointing the inferior division, the facial nerve will be identified and exposed [21]. This is the method commonly employed by various authors in the world. As for Ariyoshi and Shimahara [26], they provide standards based on the retromandibular vein. If the vein is pushed medially or the vein is not displaced, and the location of the tumour lies laterally to this vein, the tumour is considered to be lying in the superficial portion of the parotid gland. The method of using the retromandibular vein as an anatomic landmark in preoperative radiography has an accuracy of up to 86.4%. Therefore, a basic understanding of the existence of the changing relationship between the facial nerve and the retromandibular vein is not only important in evaluating preoperative safety but also has great value in locating the location of the parotid gland tumour, but this prediction doesn't guarantee 100% accuracy.

#### **Application perspective of the study**

The dissection technique described in the study can assist surgeons in recognising the facial nerve trunk and its rami before surgical dissection, which will avoid damage to this nerve. In particular, we defined the relationship between the retromandibular vein and the facial nerve rami; the superior, inferior division and the retromandibular vein; diameter and length of the facial nerve trunk as compared to other literature studies. This allows scientists to acknowledge the variations of facial nerve distribution in response to racial factors, individual background, personal landmarks. According to our knowledge, this study was the first research about this subject to be conducted in Southeast Asia. In general,

our results can be indicated as a useful surgical guide. Future studies are justified to determine further research on the variability in ramification patterns of the facial nerve among distinct racial and ethnic groups. Other studies using alternative research methods such as external palpation landmarks, facial nerve electrical stimulation should also be performed to optimise the accurate results, lesser time consumption and improve cost-efficiency.

Our findings about the anatomical characteristics of the facial nerve main trunk and its division include: all cadavers have a unique trunk exiting from the stylomastoid foramen, none of the specimens has been found to have double trunk, the distance of the facial nerve to the skin surface on the right side is deeper than the left side which must be respected during surgery. Mean trunk length is 14.1 mm, the diameter of 2.5 mm, an average number of divisions is 2.1 in which bifurcation proportion accounts for 93.3%, and the third division may exist and might be damaged intraoperatively. The angle formed by the superior and inferior division appears to be almost perpendicular ( $91.2^{\circ}$ ), and mean superior division length is 15.2 mm, which is notably shorter than inferior division, 23.6 mm. We found that most of our specimens displayed Tsai pattern 2 (60%).

To identify the main trunk and its division, we found that the distance from the angle of the mandible to its bifurcation location is 40.8 mm, which is considerably longer than other authors due to the bifurcation lies at a higher level and the distance to the bifurcation ranges from 36 – 50 mm, which accounts for 86.6%. Based on our findings, to avoid facial nerve injury during parotid gland-related surgery, surgeons need to correctly identify the facial nerve bifurcation along the posterior border of the mandibular ramus to the mandibular angle. Approximately 86.7% of cases have facial nerve running laterally to the retromandibular vein on both sides, and over 80% of the superior and inferior division run laterally to the retromandibular vein. Based on this finding, we conclude that the location of the superior and inferior division about the retromandibular vein may not be identical ipsilaterally and bilaterally, and this nerve-vein relationship doesn't seem to obey any law. Also, we found that the superior division forms a ring around the retromandibular vein, and bleeding and facial nerve injury risk might be increased during parotid gland tumour removal procedures.

## Acknowledgements

We want to thank Mr Ninh Tung Duong (Faculty of Biology, Hanoi National University of Education, Hanoi, Vietnam) and Ms Tran Uyen Ngoc (Faculty of Veterinary Medicine, Nong Lam University,

Ho Chi Minh, Vietnam) checking and improving the English in the manuscript.

## References

1. Laing MR, McKerrow WS. Intraparotid anatomy of the facial nerve and retromandibular vein. *Br J Surg.* 1988; 75(4):310-312. <https://doi.org/10.1002/bjs.1800750405> PMID:3359141
2. Touré G, Vacher C. Relations of the facial nerve with the retromandibular vein: anatomic study of 132 parotid glands. *Surg Radiol Anat.* 2010; 32(10):957-961. <https://doi.org/10.1007/s00276-010-0674-9> PMID:20473672
3. Wang TM, Lin CL, et al. Surgical anatomy of the mandibular ramus of the facial nerve in Chinese adults. *Acta Anat (Basel).* 1991; 142(2):126-131. <https://doi.org/10.1159/000147176> PMID:1781251
4. Thanh NV. Study the types of branching of the parotid facial nerve applied in parotid gland surgery. University of Medicine and Pharmacy at Ho Chi Minh City: Master's thesis in Medicine, 1997.
5. Kirici Y, Kilic C, Kazkayasi M. Topographic anatomy of the peripheral branches of the facial nerve. *Journal of Experimental and Integrative Medicine.* 2011; 1(3):201-204. <https://doi.org/10.5455/jeim.040711.br.005>
6. Katz AD, Catalano P. The clinical significance of the various anastomotic branches of the facial nerve. Report of 100 patients. *Arch Otolaryngol Head Neck Surg.* 1987; 113:959-962. <https://doi.org/10.1001/archotol.1987.01860090057019> PMID:3606847
7. Park IY, Lee ME. A morphological study of the parotid gland and the peripheral branches of the facial nerve in Koreans. *Yonsei Med J.* 1977; 18:45-51. <https://doi.org/10.3349/yjm.1977.18.1.45> PMID:617028
8. Myint K, Azian AL, Khairul A. The clinical significance of the branching pattern of the facial nerve in Malaysian subjects. *Med. J. Malaysia.* 1992; 47(2):114-120.
9. Rodrigues AC, et al. Anatomy of the Facial Nerve and its Implication in the Surgical Procedures. *Int. J. Morphol.* 2009; 27(1):183-186. <https://doi.org/10.4067/S0717-95022009000100031>
10. Salame K, Ouaknine GER, et al. Microsurgical anatomy of the facial nerve trunk. *Clin Anat.* 2002; 15:93-99. <https://doi.org/10.1002/ca.1102> PMID:11877786
11. Kandari QAA. Facial Paralysis: Reconstructive Surgery: State of Art Egypt. *J Plast Reconstr Surg.* 2011; 35(2):317-324.
12. Dias FL, Roberto AL, Jorge P. Practical Tips to Identify the Main Trunk of the Facial Nerve. *Pearls and Pitfalls in Head and Neck Surgery: Basel Karger,* 2008.
13. Ekinci N. A study on the branching pattern of the facial nerve of children. *Kaibogaku Zasshi.* 1999; 74:447-450.
14. Kwak HH, et al. Branching patterns of the facial nerve and its communication with the auriculotemporal nerve. *Surg Radiol Anat.* 2005; 26:494-500. <https://doi.org/10.1007/s00276-004-0259-6> PMID:15368081
15. Kalaycioğlu A, Yeginoğlu G, et al. An anatomical study on the facial nerve trunk in fetus cadavers. *Turkish Journal of Medical Science.* 2014; 44:484-489. <https://doi.org/10.3906/sag-1302-145> PMID:25558653
16. Kopuz C, Turgut S, et al. Distribution of facial nerve in parotid gland: analysis of 50 cases. *Okajimas Folia Anat Jpn.* 1994; 70:295-300. <https://doi.org/10.2535/ofaj1936.70.6.295> PMID:8041565
17. Pia F, et al. Centripetal approach to the facial nerve in parotid surgery: personal experience. *Acta Otorhinolaryngol Ital.* 2003; 23:111-115.



18. Tsai SC, Hsu HT. Parotid neoplasms: diagnosis, treatment, and intraparotid facial nerve anatomy. *The Journal of Laryngology & Otology*. 2002; 116(5):359-62. <https://doi.org/10.1258/0022215021911013> PMID:12080993
19. McCormack D, Cauldwell EW, Anson BI. The surgical anatomy of the facial nerve with special reference to the parotid gland. *Surg Gynecol and Obstet*. 1945; 80:620-630.
20. Davis RA, Anson BJ, et al. Surgical anatomy of the facial nerve and parotid gland based upon a study of 350 cervicofacial halves. *Surg Gynecol Obstet*. 1956; 102:385-412.
21. Alzahrani FR, Alqahtani KH. The facial nerve versus the retromandibular vein: a new anatomical relationship. *Head Neck Oncol*. 2012; 4(4):82.
22. Astik RB, Dave UH, Gajendra KS. Variant position of the facial nerve in parotid gland. *International Journal of Anatomical Variations*. 2011; 4:3-4.
23. Kim DI, et al. The marginal mandibular branch of the facial nerve in Koreans. *Clin Anat*. 2009; 22(2):207-214. <https://doi.org/10.1002/ca.20739> PMID:19089998
24. Dingman RO, Grabb WC. Surgical anatomy of the mandibular ramus of the facial nerve based on the dissection of 100 facial halves. *Plast Reconstr Surg Transplant Bull*. 1962; 29:266-272. <https://doi.org/10.1097/00006534-196203000-00005> PMID:13886490
25. Savary V, Robert R, et al. The mandibular marginal ramus of the facial nerve: An anatomic and clinical study. *Surg Radiol Anat*. 1997; 19:69-72. <https://doi.org/10.1007/BF01628127> PMID:9210238
26. Ariyoshi Y, Shimahara M. Determining whether a parotid tumour is in the superficial or deep lobe using magnetic resonance imaging. *J Oral Maxillofac Surg*. 1998; 56(1):23-26. [https://doi.org/10.1016/S0278-2391\(98\)90909-0](https://doi.org/10.1016/S0278-2391(98)90909-0)