

Correcting Corneal Astigmatism with Corneal Arcuate Incisions during Femtosecond Laser Assisted Cataract Surgery

Nguyen Xuan Hiep¹, Pham Thi Minh Khanh¹, Do Quyet², Than Van Thai³, Vu Thi Nga⁴, Toi Chu Dinh⁵, Nguyen Duy Bac^{2*}

¹Vietnam National Institute of Ophthalmology, Hanoi, Vietnam; ²Vietnam Military Medical University (VMMU), Hanoi, Vietnam; ³NTT Hi-tech Institute, Nguyen Tat Thanh University, Ho Chi Minh City, Vietnam; ⁴Institute for Research and Development, Duy Tan University, 03 Quang Trung, Danang, Vietnam; ⁵Department of Human and Animal Physiology, Faculty of Biology, Hanoi National University of Education, Hanoi, Vietnam

Abstract

Citation: Hiep NX, Khanh PTM, Quyet D, Thai TV, Nga VT, Dinh TC, Bac ND. Correcting Corneal Astigmatism with Corneal Arcuate Incisions during Femtosecond Laser Assisted Cataract Surgery, Open Access Maced J Med Sci. <https://doi.org/10.3889/oamjms.2019.371>

Keywords: Femtosecond laser; Corneal astigmatism; Arcuate incision

***Correspondence:** Nguyen Duy Bac. Vietnam Military Medical University (VMMU), Hanoi, Vietnam. E-mail: nguyenduybac@vmmu.edu.vn

Received: 01-Jul-2019; **Revised:** 20-Nov-2019; **Accepted:** 21-Nov-2019; **Online first:** 20-Dec-2019

Copyright: © 2019 Nguyen Xuan Hiep, Pham Thi Minh Khanh, Do Quyet, Than Van Thai, Vu Thi Nga, Toi Chu Dinh, Nguyen Duy Bac. This is an open-access article distributed under the terms of the Creative Commons Attribution-NonCommercial 4.0 International License (CC BY-NC 4.0)

Funding: This research did not receive any financial support

Competing Interests: The authors have declared that no competing interests exist

BACKGROUND: Astigmatic management is an important step to achieve the best visual quality after refractive cataract surgery. Nowadays, along with progress in cataract surgery, the femtosecond laser can produce the arcuate incisions high precisely that help the astigmatic correction. In Vietnam, it has not yet any study about this issue, so we perform this study.

AIM: To assess the efficacy and safety of arcuate corneal incisions in treatment corneal astigmatism during femtosecond laser-assisted cataract surgery.

METHODS: In this clinical interventional study, forty-five cases with cataract and corneal astigmatism (> 0.50D) were treated with corneal arcuate incisions and femtosecond-laser assisted cataract surgery in Vietnam National Institute of Ophthalmology, from January 2017 to May 2018. The uncorrected and corrected distance visual acuity, refraction spherical equivalent, corneal astigmatism were measured (using an OPD-Scan III topographer) before, 1 week and 3 months after surgery. Some features of arcuate corneal incisions (quantity, depth, length and morphology), spectacle independence at a distance and complications were recorded.

RESULTS: The rate of postoperative spherical refraction equivalent was within $\pm 0.50D$ and $\pm 1.0D$ at 3 months (in 95.6% and 100% of the eyes respectively). Mean length of arcuate corneal incisions was 53.780 ± 17.6830 (range: 20 to 85). The average of preoperative corneal astigmatism was $1.65 \pm 0.83D$, decreased to $0.59 \pm 0.549D$ in the third month after surgery. Surgical induced astigmatism was $1.05 \pm 0.449D$ and lower than preoperative corneal astigmatism ($1.65 \pm 0.83D$), thereby this indicated undercorrection. However, the rate of spectacle independence was 82.3%, and no complications were recorded.

CONCLUSION: Correcting of corneal astigmatism in femtosecond laser-assisted cataract surgery combined with the formation of the arcuate incisions is a new and modern method for high safety and efficacy.

Introduction

Astigmatic management is an important step to achieve the best visual quality after refractive cataract surgery. Astigmatism postoperative from 0.50D or less could result due to glare, halos, ghosting, symptomatic blur, and so on[1]. A report in Spain from 4540 cases showed that the corneal astigmatism was prevalent in patients after cataract surgery with at least 1.50D in 22.2% of cases[2]. About 38% of cataract eyes had corneal astigmatism at least 1.00D before surgery, and 72% of cases had 0.50D or more [3]. In an investigation, in 2017 to evaluating the ocular biometric index on Vietnamese

patients undergoing cataract surgery that indicated around 40.4% of study eyes which have corneal astigmatism preoperative with at least 1.0D.

There are two main procedures for the treatment of corneal astigmatism in cataract surgery: using the corneal incisions, and toric intraocular lens implantation. In which toric intraocular lens is often used for high astigmatic cases, and the mild to moderate astigmatic cases may be corrected by corneal incisions (up to 2.50D to 3.0D or more) [4]. They could create a single or a paired arcuate incision at limbus or clear cornea. Their position is located at the steeper corneal meridian. They are non-penetrating arcuate incisions with 80% to 90% of corneal pachymetry which the length depends on the

amount of power corneal astigmatism. In the world, many studies showed the role of corneal incisions that may occur due to flat the steeper meridian, and at the same time, it inflates the flatter meridian of the cornea. The phenomenon has called the coupling effect. The achieved outcomes were pretty good [5], [6]. However, in the past, the creation of manual arcuate incisions with a diamond knife had a lot of potential risks such as a dislocated incision, the ability to penetrate the cornea, uncorrected depth that may cause to reduce the efficacy of arcuate corneal incisions and unpredictable results [7]. Nowadays, the appearance of femtosecond laser helps to create precisely the position, size, length and depth of the arcuate incisions [8]. Thereby, the correction of astigmatism is more effective that due to increase the visual acuity and decrease the dependence on patient's spectacles.

Materials and Methods

The design of the study

This prospective, cumulative, interventional, nonrandomized, case series included forty-five eyes undergoing Femtosecond Laser Assisted Cataract Surgery (FLACS) and IOL implantation from January 2017 to May 2018 at Vietnam National Institute of Ophthalmology (VNIO), Vietnam. Selection criteria were patients who had indicated cataract surgery and had cornea astigmatism more 0.5D. Exclusion criteria were patients with a history of trauma, previous glaucoma or intraocular surgery, small palpebral fissure, nystagmus or visible eyelid spasm, inflammatory or infectious pathology of the eye, scar or opacity of the cornea, and poorly dilated pupil (< 6 mm). The clinical study was accepted by the institutional ethics committee of VNIO. All patients understood and voluntarily participated in this study.

Preoperative and postoperative index measurements

All cases were examined carefully before surgery including slit-lamp biomicroscopy, tonometry, uncorrected and corrected distance visual acuity (UDVA and CDVA), fundus evaluation, measurement axial length, keratometry, non-contact specular microscopy, and corneal topography. At the first week, first month and third month postoperative, the UDVA and CDVA, tonometry, slit-lamp biomicroscopy, and measurement of corneal topography were repeated. The manifest refraction spherical equivalent (MRSE), corneal astigmatism, the average number and length of arcuate incisions were also measured. The rate of patient's satisfaction, spectacle independence, and complications were recorded.

Plan of arcuate incisions

Length and number of arcuate incisions were determined on a web site (<http://www.lricalculator.com>, last accessed May 25, 2018) to achieve lowest residual astigmatism. It was essential to reduce the length of incision because the LRIs calculator was the limbus relaxing incisions. At this moment, using the Donnenfeld Nomogram, we employed the arcuate incisions that were 2 / 3 LRI-incision size, at 8 mm optical zone, and with 85% of corneal depth in the area of incision.

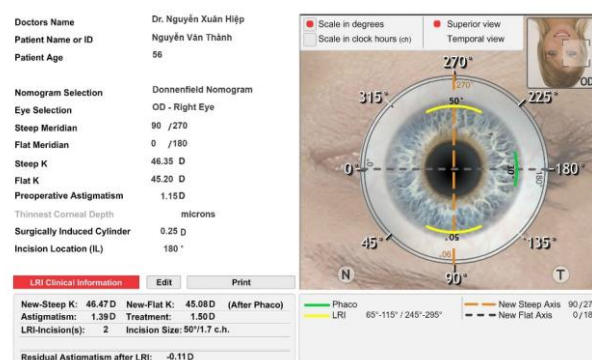


Figure 1: The Donnenfeld Nomogram is available at <http://www.lricalculator.com>

Surgical technique

All procedures were realized with system LenSx (Alcon, USA) for femtosecond laser and Infiniti machine (Alcon) for phacoemulsification. Before surgery, all patients have cleaned the eyelashes, eyebrow, flushing of the lacrimal drainage system, and conjunctival sac. They were also received the solution topical antibiotic, inflammation non-steroid, dilated pupil, and topical anesthesia eye drops on day surgery. We have used a speculum to fixation the palpebral, then put the patient interface (PI) (Soffit, Alcon) to docking and suction ocular. By observation the screen containing the OCT imaging of patient's eye, we could check all steps (limbus, primary incision, second incision, arcuate incisions, lens and capsulotomy), then perform the laser. After the opening the primary and second incisions by a hook, the viscoelastic solution was injected to the anterior chamber. Then, we used the capsulorhexis forceps to take off the anterior capsule, which was cut by laser before. Next, the phacoemulsification system had been responsible for performing its functions that were phacoemulsification of the nucleus and aspiration the cortex. The final steps of the procedure were implantation foldable intraocular lens in the capsular bag, and hydration the primary and second incisions.

Data analysis

Data were analyzed by using SPSS 16.0. The number of data was presented as $X \pm SD$, and the percentage of data were shown in %. A P-value less

0.05 was considered statistically significant. Student's t-test was used to compare corneal astigmatism, UDVA, CDVA, MRSE preoperative, one week, one month, and three months postoperative. We used Chi-square test to analyze the rate of patient's satisfaction, spectacle independence, and complications. Fisher's exact test was used when the number of data was smaller than 5 to do Chi-square test.

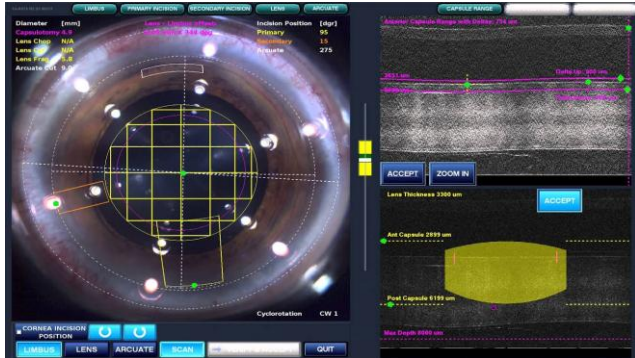


Figure 2: Screen of LenSx system shows the image OCT scan the patient's eye

Results

This study included 45 eyes of 33 patients (22 male and 11 female). The average of the age of the patients was 50.15 ± 16.672 years at the time of surgery. Among them, the most common are patients aged 40 to 60 years old.

Preoperative corneal astigmatism				
Valid	Frequency	Percent	Valid Percent	Cumulative Percent
0.53	1	2.2	2.2	2.2
0.6	1	2.2	2.2	4.4
0.76	1	2.2	2.2	6.7
0.8	1	2.2	2.2	8.9
0.84	1	2.2	2.2	11.1
0.89	1	2.2	2.2	13.3
0.98	1	2.2	2.2	15.6
1	1	2.2	2.2	17.8
1.01	1	2.2	2.2	20.0
1.02	2	4.4	4.4	24.4
1.07	1	2.2	2.2	26.7
1.12	1	2.2	2.2	28.9
1.13	1	2.2	2.2	31.1
1.23	1	2.2	2.2	33.3
1.26	1	2.2	2.2	35.6
1.31	2	4.4	4.4	40.0
1.32	1	2.2	2.2	42.2
1.36	1	2.2	2.2	44.4
1.38	1	2.2	2.2	46.7
1.44	1	2.2	2.2	48.9
1.49	1	2.2	2.2	51.1
1.51	1	2.2	2.2	53.3
1.64	1	2.2	2.2	55.6
1.66	1	2.2	2.2	57.8
1.7	1	2.2	2.2	60.0
1.71	1	2.2	2.2	62.2
1.75	1	2.2	2.2	64.4
1.76	1	2.2	2.2	66.7
1.89	2	4.4	4.4	71.1
1.94	1	2.2	2.2	73.3
1.97	1	2.2	2.2	75.6
2.03	1	2.2	2.2	77.8
2.26	1	2.2	2.2	80.0
2.28	2	4.4	4.4	84.4
2.33	1	2.2	2.2	86.7
2.34	1	2.2	2.2	88.9
2.35	1	2.2	2.2	91.1
2.53	1	2.2	2.2	93.3
2.86	1	2.2	2.2	95.6
3.86	1	2.2	2.2	97.8
4.97	1	2.2	2.2	100.0
Total	45	100.0	100.0	

Figure 3: Preoperative corneal astigmatism

Subjects of the study were patients with cataract who had corneal astigmatism before surgery more 0.50D. Among them, mostly astigmatic eyes were from 1.0D to 2.0D with 27 / 45 eyes accounting for 60% (Table 1).

Table 1: Preoperative corneal astigmatism

Preoperative corneal astigmatism	n	%
0.50 → 1.00 (D)	8	17.8
1.00 → 2.00 (D)	27	60.0
> 2.00 (D)	10	22.2

There were 10 / 45 eyes (22.2%) with corneal astigmatism more 2.0D. In particular, there were 2 eyes of one patient with high astigmatism (3.86D and 4.97D). This patient underwent FLACS with IOL Toric T6 (Alcon) implantation, combining two arcuate corneal incisions 85 degrees by femtosecond laser, resulting in postoperative astigmatism reduced to 1.0D and 1.50D. The patient was satisfied with the visual acuity of 20 / 40 and spectacle independent.

Table 2: Preoperative and postoperative corneal astigmatism, refraction and visual acuity outcomes

	Corneal Astigmatism (D)	MRSE (D)	UDVA (logMAR)	CDVA (logMAR)
Preoperative	1.65 ± 0.828	- 1.95 ± 4.987	1.44 ± 0.714	0.72 ± 0.456
1 week postoperative	1.18 ± 0.761	- 0.27 ± 0.398	0.23 ± 0.141	0.12 ± 0.132
1 month postoperative	0.80 ± 0.599	- 0.11 ± 0.299	0.14 ± 0.122	0.08 ± 0.124
3 months postoperative	0.59 ± 0.549	- 0.08 ± 0.255	0.10 ± 0.103	0.07 ± 0.104
p (pre-op and 3 months post-op)	< 0.001	< 0.001	< 0.001	< 0.001

Note: MRSE: Manifest refraction spherical equivalent; UDVA: Uncorrected distance visual acuity; CDVA: Corrected distance visual acuity; P values were determined by comparison value data preoperative with 3 months postoperative.

The Table 2 showed that the mean preoperative corneal astigmatism was $1.65 \pm 0.828D$, which was significantly reduced to $0.59 \pm 0.549D$ at 3 months postoperatively ($p < 0.001$). Thus, surgical induced astigmatism averaged $1.05 \pm 0.449D$, was lower than corneal astigmatism before surgery was $1.65 \pm 0.828D$, the correction index of surgery was 0.64 (ratio between surgical induced astigmatism and preoperative corneal astigmatism). This result indicated the undercorrection in this study that was presented in Figure 4 below.

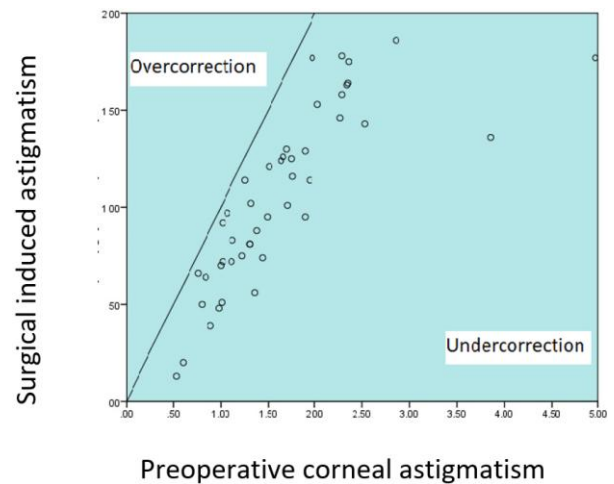


Figure 4: The scatter plot of Preoperative corneal astigmatism and surgical induced astigmatism.

The MRSE have defined the significant increase ($p < 0.001$) between preoperative and postoperative values. Statistically significant improvements in UDVA and CDVA were determined at the third month postoperative ($p < 0.001$). Table 1 indicated the change of MRSE and visual acuity outcomes in detail.

Table 3: Manifest refraction spherical equivalent postoperative within $\pm 0.50D$ and $\pm 1.0D$

Manifest refraction spherical equivalent (MRSE)	$\pm 0.50D$ (%)	$\pm 1.0D$ (%)
1 week postoperative	75.6	100
1 month postoperative	93.4	100
3 months postoperative	95.6	100

One hundred percent of study eyes that MRSE after surgery were within $\pm 1.0D$ and 95.6% was the rate of MRSE within $\pm 0.50D$ at 3 months follow up.

Table 4: The average length and number of arcuate incisions

Number of arcuate incisions	N	Length of arcuate incisions (°)
1 arcuate incision (opposite of primary incision)	16	62.81 \pm 13.901
2 arcuate incisions (symmetry through the central cornea)	29	48.79 \pm 17.761
Total	45	53.78 \pm 17.683
Range		20 to 85

In the study, there were 16 eyes with astigmatic axis according to the main incision axis, so only using a single arcuate corneal incision had a mean length of 62.81 \pm 13.901 degrees. Twenty-nine eyes needed to create a pair of arcuate corneal incisions symmetrically across the central cornea, at 9 mm optical zone, and the mean length of each incision was 48.79 \pm 17.761 degrees. Thus, the mean length of an arcuate corneal incision to correct astigmatism in the FLACS in this study was 53.78 \pm 17,638 degrees.

Discussion

Cataract surgery has been one of the most commonly performed refractive procedure worldwide. The recent progress in cataract surgery has brought excellent results as the recovery of visual acuity quickly and stably. That has met the high requirements of patients for both visual qualities as well as the independence of the patient's spectacle. Previous studies indicated the pre-existing corneal astigmatism is fairly popular in the patient undergoing cataract surgery. Residual astigmatism postoperative of 0.50D may occur due to halos, glare, monocular diplopia, asthenopia, and other visual distortions [1]. As a result, the treatment of corneal astigmatism in cataract surgery is indispensable.

To obtain at least postoperative astigmatism, the surgeons may choose the different methods such as using the limbus relaxing incisions (LRIs), toric IOL

implantation, and implementation excimer laser for residual astigmatic treatment after cataract surgery. Each method has its benefits and drawbacks. The cost of Toric IOLs is reasonably high. Furthermore, some studies have shown that there was the relative rotation of the IOL after surgery cause to increase astigmatism [9], [10]. Implementation excimer laser for residual astigmatic treatment after cataract surgery also requires a high cost. Moreover, it may have the complications concerned with corneal flap and not apply for cases with thin cornea [11].

LRIs may be used in cataract surgery to treat corneal astigmatism. Its advantage is low cost and ability to perform in the operation room or at a slit lamp microscopy in the examination room. However, in the past, the creation of LRIs with a diamond knife had a lot of potential risks such as a dislocated incision, the ability to penetrate the cornea, uncorrected depth that may cause to reduce the efficacy and stability of LRIs as well as unpredictable results [12]. Moreover, LRIs also can make irregular troubles at the limbus. Anyway, they have less glare and discomfort than the clear corneal incisions [13].

At this moment, we assessed the efficacy and safety of arcuate clear corneal incisions, which were implemented by femtosecond laser in FLACS. Many previous articles presented about the role of femtosecond laser in creation the arcuate incisions with more precision and safety by creating reproducible incisions for the position, size, length and depth of the arcuate incisions [8].

Depending on the amount of preoperative corneal astigmatism and its axis, we used a single arcuate incision (opposite of the main incision) or a pair of arcuate incisions symmetrically across the central cornea to correct astigmatism. The mean length of an arcuate corneal incision to correct astigmatism in the FLACS in this study was 53.78 \pm 17,638 degree (Table 4). Corneal astigmatism reduced from 1.65 \pm 0.828D (preoperative) to 0.59 \pm 0.549D (at 3 months postoperatively). Surgical induced astigmatism averaged 1.05 \pm 0.449D, was lower than preoperative corneal astigmatism (1.65 \pm 0.828D), the correction index of surgery was 0.64 (ratio between surgical induced astigmatism and preoperative corneal astigmatism). This result indicated the undercorrection in this study that was presented in Figure 4.

The study by Harry W. Roberts et al., (2018) also had similar results with this study when it showed that cataract surgery combined astigmatic correction by the arcuate corneal incision made by femtosecond laser had under correction postoperative [14]. Several other studies also have outcomes with under correction. It could be seen that researches have been still very prudent in using femtosecond laser to create the arcuate corneal incisions because of the worry about their great effects that may lead due to unpredictable outcomes, overcorrection and increase

of astigmatism with axial inversion. Therefore, most studies have remained slight residual astigmatism. In our study, residual astigmatism after surgery 3 months was $0.59 \pm 0.549D$, approximately to physiological astigmatism.

Moreover, by James S Wolffsohn et al., (2013), astigmatism plays a role in increasing the depth of focus of patients with healthy corneas or following laser refractive surgery [15]. Another research suggested that residual against-the-rule cylinder after cataract surgery with IOL implantation benefits the uncorrected near vision [16]. Thereby, undercorrection with astigmatism in cataract surgery may be a beneficial factor for visual quality postoperative. However, in the scope of this study, we have not yet any conditions to evaluate this issue.

Manifest refraction spherical equivalent of 100% of study eyes after surgery were within $\pm 1.0D$, and 95.6% was the rate of MRSE within $\pm 0.50D$ at 3 months follow up. This rate was very high, contributing to explain the result of very good visual acuity. This result, according to a survey by questionnaires to evaluate the patient's satisfaction and the glasses dependence showed that the rate of spectacle independence was 83.2%. 100% of patients was the rate of patient's satisfaction with the surgical results, of which 81.8% of patients was high satisfaction. Most of the patients felt comfortable because the good vision was regardless of glasses.

The study also found that there was not any complication related to creating arcuate incisions by femtosecond laser such as corneal perforation, dislocated incision, tear of incision, inadequate depth of incision, folded edge of incision, and penetrate the epithelium into the incision.

In conclusion, correcting of corneal astigmatism in femtosecond laser-assisted cataract surgery combined with the formation of the arcuate incisions is a new and modern method for high safety and efficacy. Corneal astigmatism was reduced about 64.0% compared to before surgery (correction index was 0.64). We have not yet any complications related to creating the arcuate incisions by femtosecond laser. Uncorrected distance visual acuity after surgery 3 months was 0.10 ± 0.103 , and 83.2% of patients did not depend on glasses. These results reinforced the evidence of the safety and efficacy of the surgery. However, the limitation of this study was that the sample size was small, and the follow-up time was short (3 months). The next task of the study is to collect more data to achieve a larger sample size and longer follow-up time. From that point, we could have a comprehensive view of the role, progress and stability of arcuate incisions in femtosecond laser-assisted cataract surgery. The authors also would like to find a nomogram of the arcuate corneal incision using femtosecond laser that is intended for Vietnamese patients with specific ethnic and genetic characteristics. Therefore, the research direction that

is reserved for femtosecond laser remains very much and requires more time and resources in the future.

Ethical approval

Our study was accepted by the institutional ethics committee of Vietnam National Institute of Ophthalmology. All patients understood and voluntarily participated in this study.

References

- Nichamin LD. Nomogram for limbal relaxing incisions. *J Cataract Refract Surg.* 2006; 32(9):1408. <https://doi.org/10.1016/j.jcrs.2006.03.046> PMID:16931238
- Ferrer-Blasco T, et al. Prevalence of corneal astigmatism before cataract surgery. *J Cataract Refract Surg.* 2009; 35(1):70-5. <https://doi.org/10.1016/j.jcrs.2008.09.027> PMID:19101427
- Hill, W., Expected effects of surgically induced astigmatism on AcrySof toric intraocular lens results. *J Cataract Refract Surg.* 2008; 34(3):364-7. <https://doi.org/10.1016/j.jcrs.2007.10.024> PMID:18299058
- Nanavaty MA, et al. Toric Intraocular Lenses Versus Peripheral Corneal Relaxing Incisions for Astigmatism Between 0.75 and 2.5 Diopters During Cataract Surgery. *Am J Ophthalmol.* 2017; 180:165-177. <https://doi.org/10.1016/j.ajo.2017.06.007> PMID:28647461
- Fares U, et al. Management of postkeratoplasty astigmatism by paired arcuate incisions with compression sutures. *Br J Ophthalmol.* 2013; 97(4):438-43. <https://doi.org/10.1136/bjophthalmol-2012-302128> PMID:23390168
- Lindstrom RL. The surgical correction of astigmatism: a clinician's perspective. *Refract Corneal Surg.* 1990; 6(6):441-54.
- Cleary C, et al. Beveled femtosecond laser astigmatic keratotomy for the treatment of high astigmatism post-penetrating keratoplasty. *Cornea.* 2013; 32(1):54-62. <https://doi.org/10.1097/ICO.0b013e31825ea2e6> PMID:22968362 PMID:PMC3754433
- Abbey A, et al. Femtosecond laser-assisted astigmatic keratotomy in naturally occurring high astigmatism. *Br J Ophthalmol.* 2009; 93(12):1566-9. <https://doi.org/10.1136/bjo.2008.149971> PMID:19939795
- Ahmed II, et al. Visual function and patient experience after bilateral implantation of toric intraocular lenses. *J Cataract Refract Surg.* 2010; 36(4):609-16. <https://doi.org/10.1016/j.jcrs.2009.10.044> PMID:20362853
- Khan MI, Ch'ng SW, Muhtaseb M. The use of toric intraocular lens to correct astigmatism at the time of cataract surgery. *Oman J Ophthalmol.* 2015; 8(1):38-43. <https://doi.org/10.4103/0974-620X.149865> PMID:25709273 PMID:PMC4333542
- Bayramlar H, Daglioglu MC, Borazan M. Limbal relaxing incisions for primary mixed astigmatism and mixed astigmatism after cataract surgery. *J Cataract Refract Surg.* 2003; 29(4):723-8. [https://doi.org/10.1016/S0886-3350\(02\)01821-7](https://doi.org/10.1016/S0886-3350(02)01821-7)
- Budak, K., Friedman NJ, Koch DD. Limbal relaxing incisions with cataract surgery. *J Cataract Refract Surg.* 1998. 24(4):503-8. [https://doi.org/10.1016/S0886-3350\(98\)80292-7](https://doi.org/10.1016/S0886-3350(98)80292-7)
- Muller-Jensen K, Fischer P, Siepe U. Limbal relaxing incisions

to correct astigmatism in clear corneal cataract surgery. J Refract Surg; 1999; 15(5):586-9.

14. Roberts HW, et al. Refractive outcomes after limbal relaxing incisions or femtosecond laser arcuate keratotomy to manage corneal astigmatism at the time of cataract surgery. J Cataract Refract Surg. 2018; 44(8):955-963.

<https://doi.org/10.1016/j.jcrs.2018.05.027> PMID:30033111

15. Wolffsohn JS, Bhogal G, Shah S. Astigmatism and vision:

should all astigmatism always be corrected? Br J Ophthalmol. 2014; 98(1):2-3. <https://doi.org/10.1136/bjophthalmol-2013-303599> PMID:24338839

16. Trindade F, Oliveira A, Frasson M. Benefit of against-the-rule astigmatism to uncorrected near acuity. J Cataract Refract Surg. 1997; 23(1):82-5. [https://doi.org/10.1016/S0886-3350\(97\)80155-1](https://doi.org/10.1016/S0886-3350(97)80155-1)