

Assessing the Status of Filtering Blebs at 5 Year Post-Trabeculectomy

Bui Thi Van Anh¹, Nguyen Thai Dat¹, Anh Tuan Vu², Nguyen Trung Hieu³, Do Quyet⁴, Than Van Thai⁵, Vu Thi Nga⁶, Toi Chu Dinh⁷, Nguyen Duy Bac^{4*}

¹Vietnam National Institute of Ophthalmology, Hanoi, Vietnam; ²Hanoi Medical College, Hanoi, Vietnam; ³Ninhbinh Province Eye Hospital, Ninh Binh, Vietnam; ⁴Vietnam Military Medical University (VMMU), Hanoi, Vietnam; ⁵NTT Hi-tech Institute, Nguyen Tat Thanh University, Ho Chi Minh City, Vietnam; ⁶Institute for Research and Development, Duy Tan University, 03 Quang Trung, Danang, Vietnam; ⁷Department of Human and Animal Physiology, Faculty of Biology, Hanoi National University of Education, Hanoi, Vietnam

Abstract

Citation: Anh BTV, Dat NT, Vu AT, Hieu NT, Quyet D, Thai TV, Nga VT, Dinh TC, Bac ND. Assessing the Status of Filtering Blebs at 5 Year Post-Trabeculectomy. Open Access Maced J Med Sci. <https://doi.org/10.3889/oamjms.2019.374>

Keywords: Filtering bleb; OCT anterior; Trabeculectomy

***Correspondence:** Nguyen Duy Bac. Vietnam Military Medical University (VMMU), Hanoi, Vietnam. E-mail: nguyenduybac@vmmu.edu.vn

Received: 01-Jul-2019; **Revised:** 20-Nov-2019; **Accepted:** 21-Nov-2019; **Online first:** 20-Dec-2019

Copyright: © 2019 Bui Thi Van Anh, Nguyen Thai Dat, Anh Tuan Vu, Nguyen Trung Hieu, Do Quyet, Than Van Thai, Vu Thi Nga, Toi Chu Dinh, Nguyen Duy Bac. This is an open-access article distributed under the terms of the Creative Commons Attribution-NonCommercial 4.0 International License (CC BY-NC 4.0)

Funding: This research did not receive any financial support

Competing Interests: The authors have declared that no competing interests exist

BACKGROUND: Glaucoma is a common cause of blindness in the world as well as in Vietnam. It is treated by many different methods but trabeculectomy is still the most popular and highly effective surgical method to treat this condition.

AIM: To analyze the status of 5 years filtering blebs following trabeculectomy and to explore multiple factors associated with filtering blebs.

METHODS: This is a retrospective, cross-sectional descriptive study. Eyes had been performed trabeculectomy for 5 years were included in these results. The filtering blebs were assessed using slit lamp and OCT. the OCT captured bleb area to evaluate fluid subconjunctival spaces, thickness and height of bleb and to evaluate the related factors

RESULTS: A group of 106 primary glaucoma eyes of 97 patients (88 patients with 1 eye, 9 patients 2 eyes) had been performed trabeculectomy for 5 years were taken OCT anterior image. The proportion of female patients is 1.5 times that of male patients. IOP was controlled with or without topical medication in all eyes. The filtering bleb had a high echo reflection, which accounted for 42.5%, the average echo reflection was 38.6%, the low echo reflection response of 18.9%. 66% of the eyes had the aqueous space under the conjunctiva, 65.1% have the aqueous space under sclera flap, the average height of the bleb on OCT was 0.4 mm ± 0.3 mm. Young patients often have a higher rate of bleb fibrosis and loss of function than older patients

CONCLUSION: OCT is capable of assessing the function of bleb. After 5 years of trabeculectomy, on the OCT image, most cases of blebs are maintaining drainage function.

Introduction

Glaucoma is a common cause of blindness in the world as well as in Vietnam. In most countries, glaucoma is the second-leading cause of blindness and a dangerous threat to public health. The disease has many different pathogenesis and pathophysiology mechanisms and is treated with many different methods but trabeculectomy is still the most popular and highly effective surgical method to treat glaucoma [1], [2]. The aim of the surgery is to create a pathway which allows the aqueous humor to drain from the anterior chamber into an area underneath the

conjunctiva where it creates a filtering bleb and subsequently absorbed into the conjunctival capillary system. However, with time, the effect of lowering pressure of the surgery tends to decrease. According to Ehrnooth P, the rate of IOP below 21mmHg after 1 year of trabeculectomy is 82%, after 2 years is 70%, after 3 years is 64%, after 4 years is 52% [3]. Studies by many authors show that the cause of failure of PT has many reasons, but mainly the increase in fibrosis after surgery causes failure of filtering bleb. The structural manifestations of bleb indicate the ability of fluid to pass through the fistula. So that assessment of bleb manifestations can predict its drainage function.

Beside of clinical assessment, OCT images of anterior part of the eyeball allows to accurately record and measure the internal structures of bleb such as: the thickness of the bleb wall, the echo reflection inside of the bleb, the aqueous space subconjunctival or under the sclera flap, the scleral flap thickness, aqueous pathway under the sclera flap and the fistula. This is a non-invasive examination that can help doctors clearly assess the condition of bleb as well as determine the cause of failure of filtration surgery. There are many filtering bleb classification system but Zang Yi 'one is a clear, complete and easy to use in practice [4], [5].

According to Zhang Yi, there are 4 types of filtering bleb [4]: 1) Diffuse bleb: bleb function. There are several microcapsules under the conjunctiva with low or moderate echogenicity gaps. These blebs have a thick conjunctiva, a fluid space above sclera flap, an aqueous pathway under sclera flap and a visible fistula; 2) Cystic bleb: also a bleb with function. The walls of the scar are relatively thin (usually below 0.2 mm), varying in height and are composed of a wide aqueous cavity or some small or medium space above sclera flap, some of which are fused with the space subconjunctiva. The fluid fistula under sclera flap is clearly visible; 3) Encapsulated bleb: is a non-functional bleb in which the fluid space above sclera flap is surrounded by tissues with high echogenicity. The tissue of the sclera and conjunctiva is not clearly distinguished, may even stick (the entire scar wall is thickened). The fluid cavity on the sclera is surrounded by dense connective tissue with high echogenicity, aqueous pathway under the sclera flap and fistula are usually very thin; and 4) Flattened bleb: is a non-functional bleb. Flat blebs are similar to an encapsulated bleb but there is no aqueous space under the conjunctiva or above the sclera flap. The whole scar is low, the wall is thick. Conjunctiva and sclera are intertwined, with high echogenicity, similar to the echogenicity of the sclera. The aqueous pathway under the sclera flap is often not visible, although openings are visible.

Therefore, we conducted the study to investigate the bleb of trabeculectomy on the OCT image taken 5 years after surgery.

Materials and Methods

A retrospective, cross-sectional descriptive study was conducted on 106 eyes of 97 patients diagnosed with primary glaucoma who had been performed trabeculectomy at the Glaucoma department – Vietnam National Institute of Ophthalmology from September 2008 to March 2009. Among them, 97 patients had unilateral trabeculectomy and 9 patients had bilateral trabeculectomy.

Selection criteria

Primary glaucoma eyes which were performed trabeculectomy with or without anti-metabolic drugs. The study ruled out the patients who had trabeculectomy more than one-time, combined phaco-trabeculectomy, patients with a history of trauma or other pathological treatment surgery of the eye.

The protocol included

Gathering all medical records of patients in the selected subjects, inviting the patients to re-examine, assessing the functional and physical condition, then all patients will be taken OCT to assess filtering blebs. During OCT images were taken, the patients were asked to look down, the photographer gently pulled the upper eye lash to reveal the limbus, filtering bleb and conjunctival area, avoiding pressing on the eyeball and the bleb. The first slice was directly taken through the bleb center, the second horizontal slice was taken passed through the center of the bleb, parallel to the cornea limbus [6], [7].

Capturing and observing filtering blebs

The echogenicity within filtering blebs, the sub conjunctiva aqueous space, the fluid cavity and pathway under sclera flap, the fistula were recorded. Measuring the height, width, the wall thickness of the blebs was calculated on OCT images.

Clinical bleb assessment is performed by slit lamp examination: - Height of blebs was recorded with flattened, low, medium and high performance; - The diffuse of blebs were recorded and classified to less than 1 hour, from 1 hour to 2 hours, from 2 hours to 4 hours, over 4 hours; - Blood vessels were observed on the surface of bleb and were classified to no blood vessels, little blood vessels, average blood vessels, many blood vessels and whether there is congestion or not; - Seidel test: The rate of Seidel negative (blebs had no drainage fluid), Seidel positive within 5 seconds, Seidel positive after 5 seconds (those had drainage fluid); and - In addition, we noted the cases with excessively large filtering blebs, blebs with thin walls with a risk of wound leakage.

General clinical assessment based on classification of Buskirk (1992) [8]: - Good bleb: diffuse and avascular blebs with the presence of small micro- cysts intra conjunctival epithelium; - Moderate bleb: diffuse blebs with many blood vessels on the surface or tend to stick at the bleb margin; and - Bad bleb: Excessively large filtering blebs, bleb fibrosis, conjunctiva lacks mobility, presence of many blood vessels on the surface of the blebs.

The OCT images were taken and filtering blebs were evaluated

The height of bleb measured at highest axis and recorded with less than 1 mm, from 1 – 2 mm and over 2 mm. The echogenicity of blebs was divided to low, medium high echo reflection. Status of fluid space under the conjunctiva or under sclera flap was recoded as visible or invisible. The fluid pathway below the sclera flap and the fistula of sclerectomy was also recorded as visible or invisible. In overall, the blebs were classified into Type D, Type C, Type E, Type F according to Zhang Yi [4].

Results

Demographic characteristics

The average age of the study group is 60.27 ± 9.13, majority of patients aged 55 and over. Of the 97 patients in the study group, there were 39 males and 58 females.

The average intraocular pressure before surgery was 30.3 ± 4.1 mmHg, the IOP level from 26 – 32 mmHg accounted for the highest rate (62.3%). At the time of re-examination, the average intraocular pressure was 19.97 ± 3.3 mmHg with/without glaucoma eye drops, none of which had IOP above 32 mmHg.

In 106 primary glaucoma eyes, there were 89 angle-closure glaucoma (83.9%) and 17 open-angle glaucoma eyes (16.1%). Only 18 (PACG and POAG) eyes were at the primary stage with no glaucomatous optic damages or glaucomatous visual field damages identified. 21/106 eyes were applied 5FU or MMC during the operation. 81.1% had more than 1 anti-glaucoma drop before surgery.

Filtering bleb status after 5 years of surgery

Most of cases had medium size bleb. The proportion of flat blebs was 23.6% and very high blebs accounted for 11.3%. The width of the blebs is mainly 2 to 4 hours (79/106 eyes). The number of eyes with a width of bleb smaller than 1 hour or larger more than 4 hours was very low. 23.6% of eyes had moderate vessels on the bleb surface, 58.5% had few, 6.6% had many blood vessels and 11.3% avascular on the bleb surface. All eyes in the study resulted in a negative Seidel test.

Clinically, the number of eyes with flat fibrous blebs accounted for 44.3% (Figure 1), followed by diffuse blebs and those with small microcysts, accounting for the lowest percentage was capsule-shaped bleb. Besides, we have recorded 7 excessively large blebs, these blebs have thin walls,

high roughness, great width.

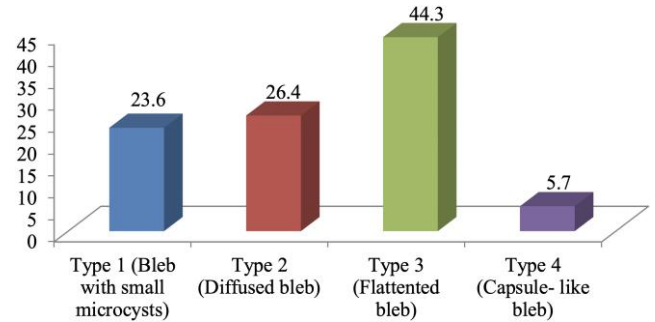


Figure 1: Clinical classification of filtering blebs

Assessing filtering bleb status on OCT

In our study, the rate of bleb with high echogenicity accounted for the highest rate (42.5%), then the bleb had an average echogenicity (38.6%), the lowest was the blebs with the least echo-genecity (18.9%). There were 66% of the eyes which showed visible subconjunctival aqueous spaces, 34% of the eyes showed no aqueous accumulation. 82.1% of cases had aqueous space under sclera flap, 17.9% had blebs without aqueous cavity under the sclera flap.

Fluid pathway under the sclera flap was visible in 69 eyes (accounting for 65.1%), 85/106 of cases had visible fistula while the fistula was not observed in 21eyes (accounting for 34.9%). 61.3% of the eyes had bleb height less than 1 mm; 38.7% were 1 to 2 mm and none of eyes had big bleb with the height more than 2 mm

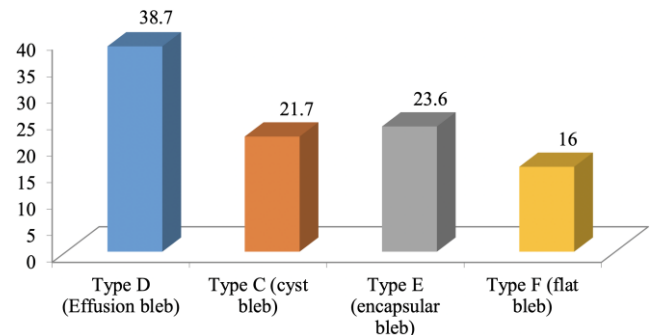


Figure 2: Classification of filtering bleb on OCT

The bleb classification on OCT according to Zhang Yi is described according to the above chart [4]. Type D is the diffuse bleb, which accounts for the highest rate of 38.7%, type C is the bleb with small microcysts that accounts for 21.7%, type E is capsule-like bleb, accounting for 23.6%, type F is the flat bleb, accounting for 16%.

Factors related to blebs

At the age more than or equal to 55, the percentage of eyes with type D was 47.3%, much

higher than the age less than 55, which was 18.8%. Meanwhile, the percentage of eyes with type E blebs at age less than 55 is 40.6%, much higher than those with type E which is 16.2%.

Table 1: IOP at the time of re-examination and bleb status IOP/re- examination

	Type C		Type D		Type E		Type F		Total	
	No of eyes	Rate (%)	No of eyes	Rate (%)	No of eyes	Rate (%)	No of eyes	Rate (%)	No of eyes	Rate (%)
14 - 25 mmHg	23	23.2	41	41.4	22	22.2	13	13.1	99	100
26 - 32 mmHg	0	0	0	0	3	42.9	4	57.1	7	100
Total	23	21.7	41	38.7	25	23.6	17	16.0	106	100

P < 0.01
P value were determined by Chi-square test.

At the time of re-examination, there were 99/106 eyes with IOP from 14 mmHg to 25 mmHg and 7 eyes with IOP from 26 mmHg to 32 mmHg (Maclakov tonometer). In IOP controlled group, the rate of type D accounted for the highest rate (41/99 eyes), then the eye had type C (23/99 eyes), followed by the eyes in type E (22/99 eyes), finally the eyes of type F had the lowest rate (13/99 eyes) (Table 1).

On the contrary, uncontrolled IOP group, the rate of type F accounted for the highest proportion (4/7 eyes), followed by those with type E (3/7 eyes), whereas no eye in this group had blebs of type C and type D.

Table 2: Anti-metabolite application and blebs status

Anti-metabolic application	The bleb classification on OCT								Total	
	Type C		Type D		Type E		Type F		Number of eyes	Rate (%)
	Number of eyes	Rate (%)	Number of eyes	Rate (%)	Number of eyes	Rate (%)	Number of eyes	Rate (%)		
Yes	13	61.9	4	19.0	4	19.0	0	0	21	100
No	10	11.8	37	43.5	21	24.7	17	20.0	85	100
Total	23	21.7	41	38.7	25	23.6	17	16.0	106	100

p < 0.01
P values were determined by Chi-square test.

5FU or MMC had been applied during operation in 21 eyes, in which the number of type C blebs accounted for the highest percentage of 61.9% (13/21), followed by the number of type D and type E all accounted for the proportion 19% (4/21), no eye has bleb in type F. 85 eyes were not applied anti-metabolic drugs. In this group, the number of eyes with type D had the highest rate of 43.5% (37/85), followed by the type E 24.7% (21/85), type F accounted for 20% (17/85), the lowest was Type C accounted for 11.8% (10/85) (Table 2).

Discussion

Most blebs can spread from 2-4 hours, number of blebs which spread under 1 hour is less, usually only seen on very fibrous, flattened eyes, sometimes with these eyes must be examined carefully to find out conjunctival wound. The blebs spread > 4 hours, which is more common in patients

with anti-metabolic drugs, is also very small number. In our study, there were 7 cases of excessively large blebs causing discomfort for patients and sometimes spreading over the edge of the upper limbus, leading a risk of leakage and being ruptured. Good functional blebs often spread, flattened, not too stretch, no vessels on the surface, many microcapsules are adjacent to the conjunctival epithelium. In contrast, poorly functioning blebs are located blebs, many blood vessels, conjunctival fibrosis anchored to sclera underneath or over stretch. In fact, the blebs that function are not necessarily complete avascular but still have a few blood vessels on the surface of the bleb, but these blood vessels are small and not dense. That is why the number of blebs with blood vessels is the lowest, not the avascular blebs [6], [7].

With the Visante-OCT machine, the image inside the bleb will be clearly observed thanks to the high resolution. In OCT image, type D blebs (diffuse blebs) and type C (blebs with microcysts) usually have low or moderate echogenicity found in homogeneous tissue as a liquid, E-type blebs (capsule-like blebs) and F-type blebs (flat blebs) often have high echogenicity. In this study, of the 61 blebs with low and medium echogenicity, up to 43 blebs in type D and type C, accounting for 70.5% are functional blebs. The rate of low echogenicity was less than those in studies of Leung CK, Nghiem Thi Hong Hanh (2010) due to longer follow up (Leung CK study in 12 months, Nghiem Thi Hong Hanh's study in 26 months) [6], [9]. The longer the time after surgery, the more fibrosis the bleb, so the higher echogenicity inside the bleb.

Besides, in the functional blebs, which means that the pathway for aqueous humor is created, IOP were well controlled, a good bleb was usually highly visible to see the fluid pathway below the sclera flap [10], [11]. In 106 research eyes, 69 eyes have bleb seeing the fluid under the sclera flap, accounting for 65.1%, of which 58/69 eyes are blebs in type D and type C (accounting for 84%), 11/69 eyes are blebs belonging to type E (accounting for 16%), no bleb of type F, p < 0.01. In our study, there was a significant higher rate of the eye with visible fluid pathway under the scleral flap than the Leung CK study [9] probably because this author used the Stratus-OCT which is more limited about depth penetration than the Visante OCT machine we used in the study. Thus, the age group ≥ 55 has the rate of blebs of type D and type C (the blebs that were still functional), accounting for a high proportion (67.6%). On the contrary, at the age of < 55, the rate of type E blebs and type F blebs (which were not functional) is higher than the rate of type D and type C (functional blebs). This difference has statistical significance with p < 0.05. This is also understandable because in the elderly, the fibrosis after surgery is always reduced compared to young people.

In the study group, Of the 21 eyes had anti-metabolic application up to 17/21 eyes had blebs of type D and type C accounted for 81%, only 19% type

E and type F. Meanwhile, in the eyes that do not use anti-metabolite, the rate of type D and type C is 55.3%. This difference is statistically significant with $p < 0.01$. Thus, anti-metabolic application with trabeculectomy increased markedly the rate of bleb function (type D and type C). In histopathological studies, it has also been shown that anti-metabolite has the effect of inhibiting fibroblast proliferation, thus improving the hydrological drainage efficiency of bleb after trabeculectomy [12], [13], [14].

At the time of re-examination, in IOP controlled group, 64.6% of cases had blebs belonged to type D and type C and 35.4% type E and type F was statistically significant difference ($p < 0.01$) comparing to 100% blebs belonged to type E and type F in uncontrolled IOP group. Our results are similar to Zhang Yi's study, with 72% eyes was Type F in group IOP uncontrolled [4], this result is similar to the study by Weizer JS [15].

In conclusion, five years after trabeculectomy for primary glaucoma treatment, 93% of blebs in these cases were maintaining the function of lowering IOP, 65.1% blebs had low and medium echogenicity, 74.5% bleb with a width of 2 to 4 hours zones and a few blood vessels, most of these blebs on OCT examination still observe the cavity under the conjunctiva, the fluid pathway under the sclera flap.

Young patients often have a higher rate of bleb fibrosis and loss of function than older patients. Anti-metabolite application increase IOP controlled but also increase the the excessively large blebs. The uncontrolled IOP eyes use to have its bleb belong to type E or type F on OCT.

Acknowledgement

We would like to acknowledge the support of many colleagues from the Departments of Glaucoma, Vietnam National Institute of Ophthalmology.

References

1. Kanski JJ. The glaucomas: Clinical Ophthalmology. A systematic approach. Oxford: Butterworth-Heinemann, 1994.
2. Shaarawy T, Flammer J. Trabeculectomy - The golden standard. Glaucoma Therapy Current Issues and Controversies. London: Martin Dunitz, 2004. <https://doi.org/10.3109/9780203488911>
3. Ehrnrooth P, et al. Long-term outcome of trabeculectomy in terms of intraocular pressure. Acta Ophthalmol Scand. 2002; 80(3):267-71. <https://doi.org/10.1034/j.1600-0420.2002.800307.x> PMID:12059864
4. Zhang Y, et al. Evaluating subconjunctival bleb function after trabeculectomy using slit-lamp optical coherence tomography and ultrasound biomicroscopy. Chin Med J. 2008; 121(14):1274-9. <https://doi.org/10.1097/00029330-200807020-00005> PMID:18713546
5. Yamamoto T, Sakuma T, Kitazawa Y. An ultrasound biomicroscopic study of filtering blebs after mitomycin C trabeculectomy. Ophthalmology. 1995; 102(12):1770-6. [https://doi.org/10.1016/S0161-6420\(95\)30795-6](https://doi.org/10.1016/S0161-6420(95)30795-6)
6. Hoàng, Đ.L., Khảo sát sự phù hợp về kết quả khám đánh giá sẹo bong sau mổ cắt bè cứng mạc bằng đèn khe và bằng máy Visante OCT. Tạp chí y học thực hành, 2012. 810:24-27.
7. Izatt JA, et al. Micrometer-scale resolution imaging of the anterior eye in vivo with optical coherence tomography. Arch Ophthalmol. 1994; 112(12):1584-9. <https://doi.org/10.1001/archoph.1994.01090240090031> PMID:7993214
8. Van Buskirk EM. Mechanisms and management of filtration bleb failure. Aust N Z J Ophthalmol. 1992; 20(3):157-62. <https://doi.org/10.1111/j.1442-9071.1992.tb00934.x> PMID:1449767
9. Leung CK, et al. Analysis of bleb morphology after trabeculectomy with Visante anterior segment optical coherence tomography. Br J Ophthalmol. 2007; 91(3):340-4. <https://doi.org/10.1136/bjo.2006.100321> PMID:17005548 PMID:PMC1857643
10. Kojima S, et al. Filtration bleb revision guided by 3-dimensional anterior segment optical coherence tomography. J Glaucoma. 2014; 23(5):312-5. <https://doi.org/10.1097/IJG.0b013e3182741ee6> PMID:23377583
11. Mastropasqua R, et al. Anterior segment optical coherence tomography imaging of conjunctival filtering blebs after glaucoma surgery. Biomed Res Int. 2014; 2014:610623. <https://doi.org/10.1155/2014/610623> PMID:25136603 PMID:PMC4127298
12. Heuer DK, et al. 5-Fluorouracil and glaucoma filtering surgery. III. Intermediate follow-up of a pilot study. Ophthalmology. 1986; 93(12):1537-46. [https://doi.org/10.1016/S0161-6420\(86\)33542-5](https://doi.org/10.1016/S0161-6420(86)33542-5)
13. Megevan GS, et al. The effect of reducing the exposure time of mitomycin C in glaucoma filtering surgery. Ophthalmology. 1995; 102(1):84-90. [https://doi.org/10.1016/S0161-6420\(95\)31049-4](https://doi.org/10.1016/S0161-6420(95)31049-4)
14. Mermoud A, Salmon JF, Murray AD. Trabeculectomy with mitomycin C for refractory glaucoma in blacks. Am J Ophthalmol. 1993; 116(1):72-8. [https://doi.org/10.1016/S0002-9394\(14\)71747-7](https://doi.org/10.1016/S0002-9394(14)71747-7)
15. Weizer JS, et al. Bleb morphology characteristics and effect on positional intraocular pressure variation. Ophthalmic Surg Lasers Imaging. 2010; 41(5):532-7. <https://doi.org/10.3928/15428877-20100726-06> PMID:20795573