

Evaluation of Phacoemulsification Cataract Surgery Outcomes After Penetrating Keratoplasty

Le Xuan Cung¹, Do Thi Thuy Hang¹, Nguyen Xuan Hiep¹, Do Quyet², Than Van Thai³, Vu Thi Nga⁴, Nguyen Duy Bac², Dinh Ngan Nguyen²

¹Vietnam National Institute of Ophthalmology, Hanoi, Vietnam; ²Vietnam Military Medical University (VMMU), Hanoi, Vietnam; ³NTT Hi-tech Institute, Nguyen Tat Thanh University, Ho Chi Minh City, Vietnam; ⁴Institute for Research and Development, Duy Tan University, 03 Quang Trung, Danang, Vietnam

Abstract

Citation: Cung LX, Hang DTT, Hiep NX, Quyet D, Thai TV, Nga VT, Bac ND, Nguyen DN. Evaluation of Phacoemulsification Cataract Surgery Outcomes After Penetrating Keratoplasty. Open Access Maced J Med Sci. 2019 Dec 30; 7(24):4301-4305. https://doi.org/10.3889/oamjms.2019.379

Keywords: Complicated Cataract; Corneal graft; Penetrating Keratoplasty; Phacoemulsification

***Correspondence:** Dinh Ngan Nguyen. Vietnam Military Medical University (VMMU), Hanoi, Vietnam. E-mail: ngan.ophtal@gmail.com

Received: 10-Jul-2019; **Revised:** 20-Nov-2019; **Accepted:** 21-Nov-2019; **Online first:** 20-Dec-2019

Copyright: © 2019 Le Xuan Cung, Do Thi Thuy Hang, Nguyen Xuan Hiep, Do Quyet, Than Van Thai, Vu Thi Nga, Nguyen Duy Bac, Dinh Ngan Nguyen. This is an open-access article distributed under the terms of the Creative Commons Attribution-NonCommercial 4.0 International License (CC BY-NC 4.0)

Funding: This research did not receive any financial support

Competing Interests: The authors have declared that no competing interests exist

BACKGROUND: Cataract is one of the reasons which causes impaired visual acuity (VA) of the eyes after penetrating keratoplasty (PK), which can be treated by cataract surgery after PK or triple procedure. Cataract surgery after PK has advantages that parameters of the eyes such as axial length, anterior chamber depth (ACD) as well as corneal curvature are stabilized after removing all sutures postoperatively, and intraocular lens (IOL) power can be calculated correctly. Therefore, postoperative VA will be improved significantly. In Vietnam, there have not been any study about cataract surgery after PK, therefore we conduct this research.

AIM: To evaluate the outcomes of phacoemulsification cataract surgery following primary PK.

METHODS: Non-randomized controlled intervention study. Nineteen eyes (19 patients) that underwent phacoemulsification plus IOL insertion after initial PK in Cornea department, Vietnam National Institute of Ophthalmology, from December 2013 to September 2014.

RESULTS: All patients presented with reduced VA, including 17 eyes (89.9%) with VA \leq 20/200, mean astigmatism was 7.9 ± 1.0 D. Clear corneal grafts in 16 eyes while corneal opacity was seen in 3 eyes. All eyes with cataract were diagnosed from grade 2. After cataract surgery, improved VA $>$ 20/200 was achieved in 72.22% of cases. There was a markable reduce of postoperative astigmatism with 1.8 ± 0.8 D ($p < 0.05$). However, the immunologic graft reaction was presented in one eye, and two edematous corneas also reported after cataract surgery. After treatment, there was one cornea achieved its clarity.

CONCLUSION: Phacoemulsification cataract surgery following initial PK showed good outcomes with improved postoperative VA, reduced astigmatism, and the ultimate graft survival rate was high.

Introduction

Cataract is considered as one of the reasons that cause impaired VA of the eyes after penetrating keratoplasty (PK). It could be occurred before or after the initial PK. There are several reasons which cause postoperative cataract, that is an accelerated pre-existing cataract, steroid-induced cataract or corneal graft rejection [1], [2]. However, whenever penetrating keratoplasty is considered and cataract is present, one must decide whether to remove the cataract at the same time as corneal transplantation. The arguments suggested that an advantage of a triple procedure (which performing PK, extracapsular cataract extraction as well as intraocular lens (IOL) implantation as one-stage surgery) are less expense for one combined procedure [3], less damage to the endothelium of the transplanted cornea from

subsequent cataract surgery and faster visual improvement [4], [5]. However, a triple procedure has some potential intraoperative complications that encountered during the open-sky technique, for example, expulsive hemorrhage, IOL implantation failure due to posterior capsule rupture, prolapse of the vitreous body [6], [7]. Particularly, the main drawback of this procedure is that intraocular lens (IOL) power calculation could not performed accurately, resulting in a high degree of myopia or hyperopia postoperatively [8], [10]. The reason is that axial length, ACD and corneal curvature could be considerably changed after keratoplasty, affecting the accurate biometric information. Therefore, the postoperative keratometric readings can only be estimated, and estimates can be quite inaccurate. This drawback will be fixed by cataract surgery after PK when all these parameters have been stabilized after removing all sutures, and IOL power can be

calculated correctly. Corneal astigmatism can be reduced with corneal incisions placed in the steepest meridian in cataract surgery. Therefore, postoperative VA will be improved significantly. However, cataract surgery after initial PK is a difficult surgical procedure which requires experienced surgeons to do. The aim of our study is to assess the phacoemulsification cataract surgery outcomes after primary PK in Corneal Department – VNIO.

Patients and Methods

Patients

This study got an approval from the Scientific Board of VNIO. Patients received phacoemulsification and IOL implantation who underwent a primary PK were included. 19 eyes (19 patients) were included in this study and they all signed an informed consent forms before surgeries. All phacoemulsification cataract surgeries were performed from December 2013 to September 2014 at the Cornea department, VNIO.

Methods

It was a non-randomized controlled intervention study. Patients were asked about their medical records and medical history was collected as well. Patients were examined by a complete ophthalmic examination, such as VA by the standard Snellen chart, IOP measurement with applanation tonometry, slit-lamp biomicroscopy, fundus examination after dilating pupil, A-scan ultrasound for axial length, and keratometric readings measured by topography. Preoperative evaluations including the status of the corneal graft (clear, edema, endothelial decompensation, endothelial immunological rejection, corneal incision), anterior chamber, iris, pupil shape, and the grades of cataract. IOL power calculation used the SRK/T formula and targeted emmetropia.

Keratoplasty

All PKs were performed under general anesthesia. The donor corneas for the PKs taken from our eye bank and imported from CorneaGens eye bank. We used the endothelial punch to prepare the corneal donors and Teflon block with a diameter of 0.50 mm that greater than the recipient bed. Recipient corneas were trephined using handle corneal trephines. 16-bite interrupted sutures using 10-0 nylon were placed. Then we made the suture adjustment to reduce the corneal astigmatism post operation.

Cataract Surgery

Nuclear hardness was defined using the Emery-Little lens opacities classification system. Topical anesthesia with 2% Alcain was administered three times before performing the surgery. Making main corneal incision by using a 2.8 mm knife, and the position of corneal incision was in the steepest meridian to reduce astigmatism. Then, the next step is to put a viscoelastic agent into anterior chamber, followed by making the second incision in a position of 90 degrees away from the main incision on cornea. A continuous curvilinear capsulorhexis is made about 6 mm using a rhexis forceps and after that, injecting BSS during hydro dissection to isolate the lens cortex from the capsule. After that, to sculpt the nucleus using Phaco tip, and the energy using for phacoemulsification is often low not to cause endothelial damage. Then, IOL implantation in the capsular bag will be done, followed by hydration of the corneal incision with BSS or 10-0 nylon suture, if needed. Topical antibacterial and steroid eyedrop were administered four times per day, then it was tapered over several months.

Postoperative examination

Patients will be evaluated on the first postoperative day, one week, one, three and six-month postoperation. At each follow-up visit, operated eyes were examined: VA, IOP, refractive error, astigmatism, corneal graft clarity, graft rejection signs, infection, IOL centeration in the capsular bag and posterior capsule's status. Good results will be corneal graft clarity, stable in-the-bag IOL, posterior capsule clarity, improved VA. Moderate results are blurry graft, stable in-the-bag IOL, posterior capsule clarity or light posterior capsular opacity, little increased VA or unchanged VA. Bad results are graft edema, IOL dislocation, severe posterior capsular opacity, reduced vision compared with pre-op VA.

Results

There were 19 eyes of 19 patients had phacoemulsification plus IOL implantation after original PK. The mean age in our study group was 49.3 ± 17.4 years old, patients aged over 50 accounted for the highest rate (57.95) and the ratio of male/female was the same.

Table 1 shows the preoperative VA. Of 19 eyes included in the study, VA $\leq 20/200$ accounted for 89.9%.

Table 1: Preoperative VA

VA	Countfinger (CF) < 3m	CF 3 m – 20/200	> 20/200
Eye	13	4	2

Preoperative IOP was all normal, ranged from 12.05 ± 1.6 mmHg, using Icare tonometer. The mean keratometric was highest at 41.67 D and lowest at 29.48 D. The mean preoperative astigmatism was 7.9 ± 1.0 D with the highest was 12 D, and the lowest was 2.2 D. Characteristics of cataract in pre-op examination showed 4 eyes had complete cataract due to herpes simplex keratitis and 3 eyes had therapeutic keratoplasty.

Table 2: Postoperative VA

VA Time	CF < 3m (n, %)	CF 3m - < 20/200 (n, %)	20/200- 20/100 (n, %)	> 20/100 (n, %)	Total (n, %)
Pre-op	13 (68.42%)	4 (21.05%)	2 (10.53%)	0 (0%)	19 (100%)
1 st pre-op day	6 (31.58%)	3 (15.79%)	6 (31.58%)	4 (21.05%)	19 (100%)
1-week post-op	3 (15.79%)	4 (21.05%)	9 (47.37%)	3 (15.79%)	19 (100%)
1-month post-op	6 (31.58%)	1 (5.26%)	7 (36.84%)	5 (26.32%)	19 (100%)
3 months post-op	2 (11.11%)	3 (16.67%)	7 (38.89%)	6 (33.33%)	18 (100%)
6 months post-op	2 (25%)	1 (12.5%)	4 (50%)	1 (12.5%)	8 (100%)

Besides, a majority of eyes identified nuclear sclerosis cataract (57.9%). This suggests that age-related cataract also plays a vital role in cataract development after keratoplasty. Regarding postoperative VA, all data showed in Table 2. It is clear in the table 2, VA showed improvement gradually and reached the best vision after 3 months (72.22% cases had VA \geq 20/200) (Table 2 and Table 3).

Table 3: Corneal graft status

Time Graft	1 week post-operation (n, %)	1 month post-operation (n, %)	3 months post-operation (n, %)	6 months post-operation (n, %)
Corneal clarity	17 (89.47%)	16 (84.21%)	16 (88.88%)	8 (100%)
Edema	2 (10.53%)	2 (10.53%)	1 (5.56%)	0
Immunological rejection	0	1 (5.26%)	1 (5.56%)	0
Infection	0	0	0	0
Total (%)	19 (100%)	19 (100%)	18 (100%)	8 (100%)

The first week post-operation, 1-month post-operation and 3 months post-operation, corneal clarity was noted in 17 eyes, 16 eyes, 16 eyes, respectively (Figure 1).

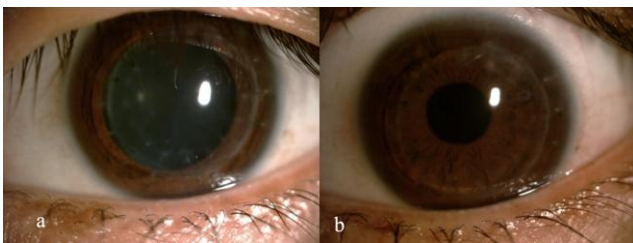


Figure 1: Cataract in PK eye; A) before cataract surgery; B) after cataract surgery

After 6 months post-operation, there were 8 eyes remaining the corneal clarity. According to Table 3, at the presentation of the first postoperative week, there was one eye had endothelial immunological rejection because the patient could not follow the treatment, stop using steroid eyedrop for one week (Figure 2). There were two edematous corneas from the 1st post-op day to 3 months follow-up visit. Then, after treatment, the graft status of this eye was back to

corneal clarity, improved vision, while the other eye had endothelial decompensation. IOL position in all examinations was in the capsular bag.

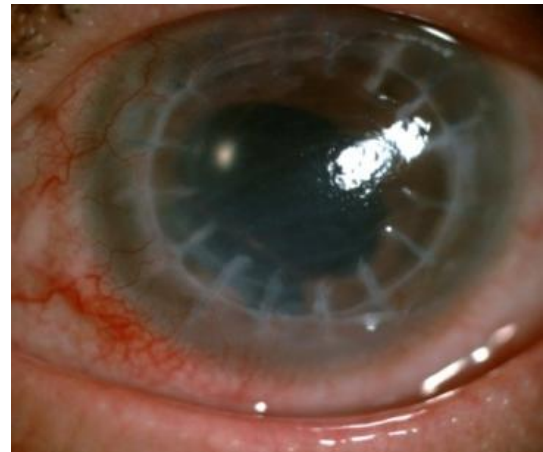


Figure 2: Corneal graft rejection after cataract surgery

We reported 2 of 19 eyes, 4 of 19 eyes and 3 eyes had the posterior capsular opaque in the first-month post-operation, 3 months post-operation and 6 months post-operation, respectively. However, the posterior capsular opaque only happened slightly, and it is no need to do YAG laser posterior capsulotomy. The reduced astigmatism was 1.8 ± 0.8 D postoperatively, and it shows statistically significant difference.

Table 4: Comparison of astigmatism

Astigmatism	$\bar{X} \pm SD$	p
Pre-op Astigmatism	7.9 ± 1.0	< 0.05
Post-op Astigmatism	6.1 ± 0.6	

Note: P values were determined by T-test.

The Table 4 shows the post-operative astigmatism was decreased to 1.8 ± 0.8 D. The result was statistically significant difference with $p < 0.05$.

Discussion

Cataract is an age-related disease considered as a leading cause of blindness worldwide. Apart from age-related factor, corneal transplantation can also cause the cataract formation significantly after surgery. Rathi VM studied on 184 eyes underwent PK as the first surgery, reported that 45 eyes developing cataract a few years later, accounted for 24.45% of cases. Particularly, of 45 eyes, 31 had cataract in their first corneal transplantation year [1]. Therefore, cataract surgery is an essential requirement to provide better vision for transplanted eyes.

Regarding cataract surgery outcomes, final VA is an important criterion. In our preoperative evaluation, there were 17 of 19 eyes (89.47%) had the

VA \leq 20/200, 13 of which considered profound visual impairment with VA of counting fingers lower than the distance at 3 meters. These data showed remarkably very inferior vision of all patients before cataract surgery.

After compared with the high rate of postoperative refractive error in a triple procedure, we performed cataract surgery after PK to achieve better refraction outcomes. In our findings, with the stabilization of keratometric readings after removing all sutures, we had a reliable calculation of IOL powers. The mean keratometric reading was 41.76 D. However, there were only two eyes had keratometric readings ranged from 40 – 44 D. Given the majority of keratometric readings in transplanted eyes were not identified in the normal range (40 – 44 D), our study showed similar findings with a study of Dietrich T, Duran JA [11], [12]. These findings support the benefits of phacoemulsification cataract surgery after initial PK (2-stage procedure), compared with PK combined with extracapsular cataract extraction and IOL insertion (a triple procedure). In previous studies, there was a high astigmatism generally observed after a triple procedure [9], [13] up to 17.0 D in a study of Mohammad-Ali Javadi [14].

Because of the accurate IOL powers calculation using keratometric readings of the transplanted clear cornea in a 2-stage procedure, this technique is preferred in terms of better postoperative refraction. This is also the main drawback of a triple procedure in an attempt to achieve optimal postoperative target refraction. Additionally, in our study, the mean astigmatism was 6.35 D (ranged from 2.2 D to 12 D). Based on corneal topography, we reduced corneal curvature by placing a corneal incision in phacoemulsification surgery at the highest refractive meridian, thereby reducing astigmatism. This is a significant benefit of a 2-step procedure compared with a triple procedure.

In our study, there was no dislocation of the inserted IOL or endophthalmitis was documented. At the first postoperative day, the uncorrected VA was 20/200 or even better that noted in 10 of 19 eyes (52.6%). This VA increased gradually over time. VA in 13 of 18 eyes stabilized completely after 3 months follow-up, in which 6 eyes had VA of above 20/100. Binder's study reported the similar result of VA, that is VA in 19 of 33 eyes (57%) was 20/100 or better [15]. Hsiao CH showed the similar result in 22/24 eyes (81%) [16]. Some authors reported higher results such as Nagra PK with 13/29 eyes achieving 20/70 VA or better, Geggel HS 's study with 91% (20/22) eyes was 20/100 or better. The explanation for the difference between our results and other studies is that the majority of corneal grafts in other studies was optical transplantation, while our PKs were therapeutic keratoplasty.

Postoperative astigmatism reduced 1.8 ± 0.8 D in comparison with preoperative values, and this

indicated statistically significant difference ($p < 0.05$). Our finding of astigmatism is similar to other reports, that are HsiaoC (1.55 ± 1.3 D) [16], Shi WY (1,0D) [17], Geggel HS (1.96 D) [18], FeiziS (3.03 D) ($P < 0.05$) [19], Nagra PK (2.77 ± 2.36 D), Dietrich T (3.3 ± 2.1 D) [11]. The reduced postoperative astigmatism in our study was partly due to the selection of the corneal incision at the steepest meridian, and the removal of sutures at the time of follow-up visits as well. The study of Kamal A. M. Solaiman conducted from 2014 – 2017 also reported the similar result to our study with better visual outcomes. Therefore, even though a triple approach using a standard keratometry value, or keratometry values in the fellow normal eye still has the major drawback of refraction [4], [5], [20].

In postoperative evaluation, we found 17 eyes (89.47%) had clear corneal grafts, while two eyes presented graft edema. There were two edematous corneas experienced difficulties during cataract surgery due to scarring, vascularization and pupil posterior synechia, causing a prolonged time of surgery. After treatment, these two eyes were stable without any presence of endothelial decompensation. Unfortunately, one eye had graft rejection episodes resulting in corneal opacity, while other grafts showed graft transparency at the last visit.

To control postoperative intraocular inflammation after corneal transplantation is essential to maintain the graft clarity and prepare well for the cataract surgery later. Once postoperative inflammation is controlled well, the situation of capsular adhesions and pupillary membranes hardly happens. Phacoemulsification cataract surgery had some difficulties due to the tough observation through scarring transplanted eyes, irregular corneal astigmatism or unstable anterior chamber, pupil posterior synechia or even contracted pupil. The phacoemulsification cataract surgery with IOL implantation was successfully done with no complications in all our patients. A study of Binder P.S also presented a similar outcome with 100% cases that in-the-bag IOL successfully inserted. posterior capsular Opaque presented in 4 of 19 eyes (21.05%), 2 of which showed early opaque in 1-month post-op. However, there were no cases needed YAG laser posterior capsulotomy.

In summary, the findings in our study showed the remarkable safety and efficacy of phacoemulsification cataract surgery after initial PK. IOL stayed safely in the capsular bag, and the rate of posterior capsular opaque was not significant. Reduced astigmatism leads to significant visual improvement, and the ultimate graft survival rate was good. However, we need to do long-term follow-up examinations for patients to identify more accurate long-term outcome.

Acknowledgement

We would like to acknowledge the support of all colleagues from Cornea Department and other colleagues from Vietnam National Institute of Ophthalmology.

Ethics in Research

Research subjects voluntarily participate in the research, patients' information is confidentiality. Research is only contributed to the vision of patients. Research subjects have the right to end the study at any time.

Informed Consent

All patients agreed and signed an informed consent form before surgeries.

Reference

- Rathi VM, Krishnamachary M, Gupta S. Cataract formation after penetrating keratoplasty. *Journal of cataract and refractive surgery*. 1997; 23(4):562-4. [https://doi.org/10.1016/S0886-3350\(97\)80214-3](https://doi.org/10.1016/S0886-3350(97)80214-3)
- Na KS, Chung SK. Cataract Formation after Penetrating Keratoplasty. *J Korean Ophthalmol Soc*. 2007; 48(12):1636-42. <https://doi.org/10.3341/kos.2007.48.12.1636>
- Lee JR, Dohlman CH. Intraocular lens implantation in combination with keratoplasty. *Annals of ophthalmology*. 1977; 9(4):513-8.
- Shimmura S, Ohashi Y, Shiroma H, Shimazaki J, Tsubota K. Corneal opacity and cataract: triple procedure versus secondary approach. *Cornea*. 2003; 22(3):234-8. <https://doi.org/10.1097/00003226-200304000-00010> PMID:12658089
- Oie Y, Nishida K. Triple procedure: cataract extraction, intraocular lens implantation, and corneal graft. *Current opinion in ophthalmology*. 2017; 28(1):63-6. <https://doi.org/10.1097/ICU.0000000000000337> PMID:27820748
- Baca LS, Epstein RJ. Closed-chamber capsulorhexis for cataract extraction combined with penetrating keratoplasty. *Journal of cataract and refractive surgery*. 1998; 24(5):581-4. [https://doi.org/10.1016/S0886-3350\(98\)80249-6](https://doi.org/10.1016/S0886-3350(98)80249-6)
- Malta JB, Banitt M, Musch DC, Sugar A, Mian SI, Soong HK. Long-term outcome of combined penetrating keratoplasty with scleral-sutured posterior chamber intraocular lens implantation. *Cornea*. 2009; 28(7):741-6. <https://doi.org/10.1097/ICO.0b013e31819bc31f> PMID:19574915
- Acar BT, Buttanri IB, Sevim MS, Acar S. Corneal endothelial cell loss in post-penetrating keratoplasty patients after cataract surgery: Phacoemulsification versus planned extracapsular cataract extraction. *Journal of Cataract & Refractive Surgery*. 2011; 37(8):1512-6. <https://doi.org/10.1016/j.jcrs.2011.03.039> PMID:21782095
- Davis EA, Azar DT, Jakobs FM, Stark WJ. Refractive and keratometric results after the triple procedure: experience with early and late suture removal. *Ophthalmology*. 1998; 105(4):624-30. [https://doi.org/10.1016/S0161-6420\(98\)94015-5](https://doi.org/10.1016/S0161-6420(98)94015-5)
- Shimmura S, Ohashi Y, Shiroma H, Shimazaki J, Tsubota K. Corneal Opacity and Cataract: Triple Procedure Versus Secondary Approach. *Cornea*. 2003; 22(3):234-8. <https://doi.org/10.1097/00003226-200304000-00010> PMID:12658089
- Dietrich T, Viestenz A, Langenbacher A, Naumann GO, Seitz B. [Accuracy of IOL power prediction in cataract surgery after penetrating keratoplasty--retrospective study of 72 eyes]. *Klinische Monatsblätter für Augenheilkunde*. 2011; 228(8):698-703. <https://doi.org/10.1055/s-0029-1245640> PMID:21117018
- Duran JA, Malvar A, Diez E. Corneal dioptric power after penetrating keratoplasty. *The British journal of ophthalmology*. 1989; 73(8):657-60. <https://doi.org/10.1136/bjo.73.8.657> PMID:2669941 PMID:PMC1041840
- Viestenz A, Seitz B, Langenbacher A. Intraocular lens power prediction for triple procedures in Fuchs' dystrophy using multiple regression analysis. *Acta ophthalmologica Scandinavica*. 2005; 83(3):312-5. <https://doi.org/10.1111/j.1600-0420.2005.00418.x> PMID:15948783
- Javadi MA, Feizi S, Moein HR. Simultaneous penetrating keratoplasty and cataract surgery. *Journal of ophthalmic & vision research*. 2013; 8(1):39-46.
- Binder PS. Intraocular lens implantation after penetrating keratoplasty. *Refractive & corneal surgery*. 1989; 5(4):224-30.
- Hsiao CH, Chen JJ, Chen PY, Chen HS. Intraocular lens implantation after penetrating keratoplasty. *Cornea*. 2001; 20(6):580-5. <https://doi.org/10.1097/00003226-200108000-00005> PMID:11473156
- Shi WY, Zeng QY, Li SW, Xie LX. [Cataract extraction and intraocular lens implantation after high-risk penetrating keratoplasty]. [Zhonghua yan ke za zhi] *Chinese journal of ophthalmology*. 2003; 39(11):678-82.
- Geggel HS. Intraocular lens implantation after penetrating keratoplasty. Improved unaided VA, astigmatism, and safety in patients with combined corneal disease and cataract. *Ophthalmology*. 1990; 97(11):1460-7. [https://doi.org/10.1016/S0161-6420\(90\)32387-4](https://doi.org/10.1016/S0161-6420(90)32387-4)
- Feizi S, Zare M, Einollahi B. Simultaneous phacoemulsification and graft refractive surgery in penetrating keratoplasty eyes. *ISRN ophthalmology*. 2011; 2011:495047. <https://doi.org/10.5402/2011/495047> PMID:24527227 PMID:PMC3912586
- Gruenauer-Kloevekorn C, Kloevekorn-Norgall K, Duncker GI, Habermann A. Refractive error after triple and non-simultaneous procedures: is the application of a standard constant keratometry value in IOL power calculation advisable? *Acta ophthalmologica Scandinavica*. 2006; 84(5):679-83. <https://doi.org/10.1111/j.1600-0420.2006.00705.x> PMID:16965501