

Bullous Keratopathy Secondary to Anterior Chamber Angle Foreign Body

Pham Ngoc Dong¹, Nguyen Thi Nga Duong¹, Le Xuan Cung¹, Duong Nguyen Viet Huong², Nguyen Dinh Ngan³, Chu Dinh Thien⁴, Do Quyet³, Nguyen Duy Bac^{3*}

¹Vietnam National Institute of Ophthalmology, Hanoi, Vietnam; ²Ho Chi Minh University of Medicine and Pharmacy, Ho Chi Minh City, Vietnam; ³Vietnam Military Medical University (VMMU), Hanoi, Vietnam; ⁴Institute for Research and Development, Duy Tan University, 03 Quang Trung, Danang, Vietnam

Abstract

Citation: Dong PN, Duong NTN, Cung LX, Huong DNV, Ngan ND, Thien CD, Quyet D, Bac ND. Bullous Keratopathy Secondary to Anterior Chamber Angle Foreign Body. Open Access Maced J Med Sci. <https://doi.org/10.3889/oamjms.2019.381>

Keywords: Foreign body in the chamber angle; Bullous keratopathy; Corneal edema

***Correspondence:** Nguyen Duy Bac. Vietnam Military Medical University (VMMU), Hanoi, Vietnam. E-mail: nguyenduybac@vmmu.edu.vn

Received: 16-Aug-2019; **Revised:** 20-Nov-2019; **Accepted:** 21-Nov-2019; **Online first:** 20-Dec-2019

Copyright: © 2019 Pham Ngoc Dong, Nguyen Thi Nga Duong, Le Xuan Cung, Duong Nguyen Viet Huong, Nguyen Dinh Ngan, Chu Dinh Thien, Do Quyet, Nguyen Duy Bac. This is an open-access article distributed under the terms of the Creative Commons Attribution-NonCommercial 4.0 International License (CC BY-NC 4.0)

Funding: This research did not receive any financial support

Competing Interests: The authors have declared that no competing interests exist

BACKGROUND: Penetrating ocular trauma with intraocular foreign body is a serious injury often resulting in loss of vision. Anterior chamber foreign bodies account for a considerable portion of all cases of all intraocular foreign bodies (up to 15%); however, they can be missed due to inconspicuous location.

CASE REPORT: We report two cases of retained intraocular foreign bodies in the iridocorneal angle that was missed at the first ophthalmic examination. They were only discovered when complications occurred, such as corneal edema and increased intraocular pressure. In the case whereby the foreign body was taken out early, corneal damages were reversible. However, in the case whereby the foreign body was taken out late, endothelial damage was irreversible and endothelial transplantation was needed.

CONCLUSION: Regarding trauma patients, a careful examination should be performed to discover foreign bodies in the iridocorneal angle. If local peripheral corneal edema occurred, attention should be paid to the trauma history and to timely discovery of the foreign body. This will prevent any irreversible corneal damages.

Introduction

Intraocular foreign bodies present commonly in penetrating ocular trauma. Large foreign bodies with conspicuous entry sites are often detected at the first ophthalmic examination. However, in the case of small foreign bodies locating at the anterior chamber angle, they may not be detected or removed promptly. Thus, in patients with an unclear history of trauma and insignificant symptoms, intraocular foreign bodies may be missed [1], [2].

Anterior chamber foreign bodies can be asymptomatic and only manifest after many years with various complications such as corneal edema, anterior uveitis, cataract, and endothelial decompensation, etc. Late diagnosis and

management of a retained intraocular foreign body may lead to complications that affect the structure and function of the penetrating eye [3].

Intraocular foreign bodies' surgical management depends largely on the origin, location, nature of the foreign material, structural and functional damages. It is advised not to remove the foreign body if it is small and does not affect visual acuity [4], [5].

In this article, we report two cases of a retained intraocular foreign body at the iridocorneal angle that were missed at the first ophthalmic examination, and were only discovered when severe complications occurred, such as corneal edema and increased intraocular pressure.

Case Reports

Case N° 1

A 35-year-old man presented with a history of traffic accident. His left eye had a penetrating ocular wound and retinal detachment. The wound was closed promptly. Unfortunately, the eye globe gradually shrunk and lost its function due to severe injury and complications (Figure 1 and Figure 2).

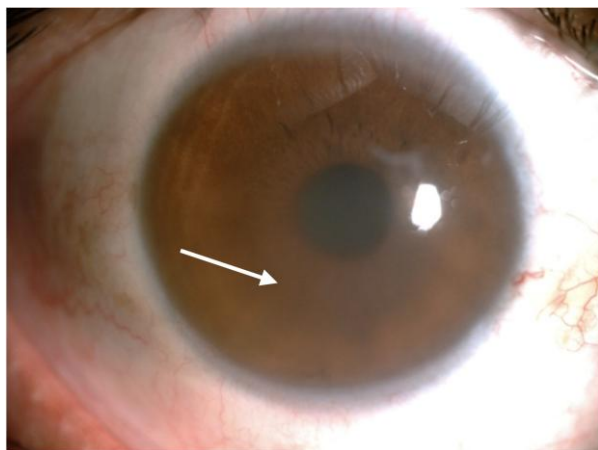


Figure 1: Inferior corneal edema and paracentral corneal scarring

One month after the accident, inferior corneal edema, increased intraocular pressure, and decreased vision (20/200) developed in his right eye. After being treated with topical steroids and glaucoma medications, the cornea became clear and intraocular pressure was well controlled. However, it relapsed after one to two months when medications were stopped.

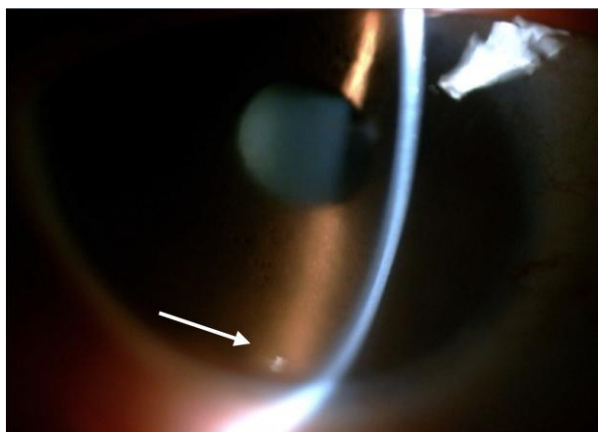


Figure 2: Glass-like foreign body at 6 o'clock (arrow)

At the time of examination, the cornea was clear; on detailed anterior chamber examination, a small glass-like foreign body at 6 o'clock of the inferior iridocorneal angle was detected. In the paracentral cornea, small corneal scarring was observed, this may be the foreign body's point of entry. Consequently, the intraocular foreign body (a piece of glass at 1 × 2 mm) was removed in the operating room. After surgery, corneal edema and increased intraocular pressure disappeared completely without any medications.

Visual acuity was 20/40.

Case N° 2

A 56-year-old woman presented at our department complaining of blurred vision, glare, grittiness and epiphora in her left eye, which first occurred 4 months ago. She had been diagnosed with keratitis at the provincial eye hospital and was treated with topical steroids, nonsteroidal anti-inflammatories and artificial tears. There was no improvement and the symptoms worsened. She had strabismus surgery done in both eyes 20 years ago. Other personal and familial history was unremarkable.

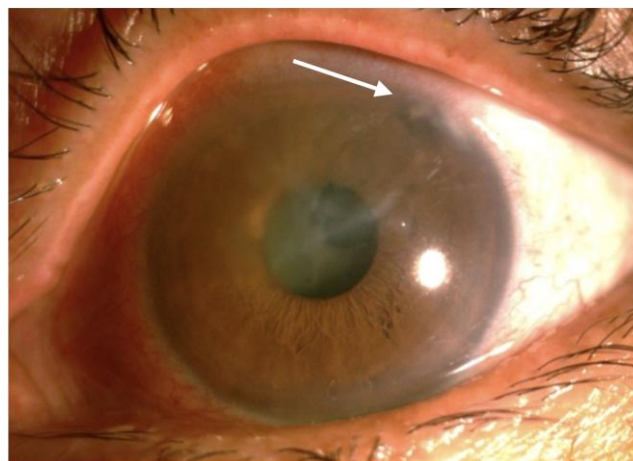


Figure 3: Superior corneal edema and corneal scarring at 1 o'clock

On clinical examination, her best-corrected visual acuity was 20/80 in the right eye and counting finger at 0.3 m in the left eye. Intraocular pressure was 17 mmHg in both eyes.

The left eye experienced irritation, epiphora, and redness. Slit lamp examination revealed central stromal edema, diffuse epithelial microcystic edema, corneal epithelial erosion, Descemet's membrane thickening and peripheral corneal scarring at the 1 o'clock meridian. Gonioscopic examination revealed a retained 1 × 1 mm foreign body located at 1 o'clock in the anterior chamber angle, on the surface of the iris and surrounded by pigments. The iris and pupil were normal. Grade 3 nuclear cataract was observed. Failure to examine the vitreous body and the fundus was due to corneal edema and cataract. The right eye was normal and only had a grade 3 nuclear cataract.

The presence of the anterior chamber foreign body was confirmed by ultrasonic biomicroscopy. It also showed vitreous opacities and no retinal detachment in both eyes.

The patient was finally diagnosed with bullous keratopathy secondary to anterior chamber foreign body, with peripheral corneal scarring at 1 o'clock in the left eye, and nuclear cataract in both eyes (Figure 3 and Figure 4).

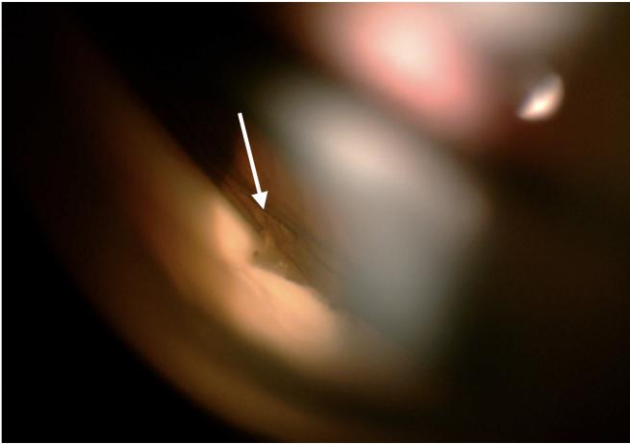


Figure 4: Tube-like anterior chamber foreign body, behind corneal scarring (arrow)

The tube-like anterior chamber foreign body suggested the structure of a glaucoma drainage device but the patient had neither been diagnosed with glaucoma nor undergone any glaucoma drainage surgery. On the other hand, the corneal scarring may be the foreign body's entry site. Thorough history taking revealed a penetrating ocular trauma in her left eye caused by a bamboo branch one year ago. At the first ophthalmic examination after trauma, the symptoms were transient, and insignificant; which spontaneously disappeared after one day and only manifested 6 months after the injury.

The foreign body was removed surgically with foreign body forceps, through a clear corneal incision at 11 o'clock (Figure 5).

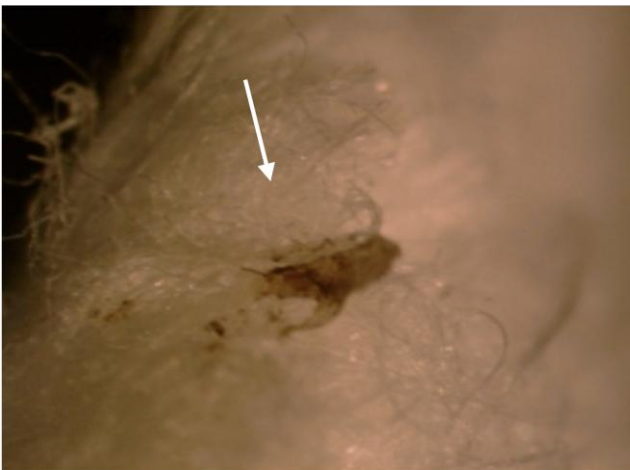

Figure 5: Plastic foreign body (arrow)

The foreign body was plastic with rolled edges and measured about 1.0 x 0.5 mm in size. Due to nuclear cataract in both eyes, phacoemulsification was also performed and then followed by intraocular lens insertions. Unfortunately, 4 months after the surgery, symptoms and signs of bullous keratopathy still existed and progressed worse. Thus, Descemet Stripping Automated Endothelial Keratoplasty was

performed to replace the damaged endothelium. After keratoplasty, the graft and recipient cornea became clearer and symptoms and signs disappeared completely. Her best corrected vision was 20/40 (Figure 6).

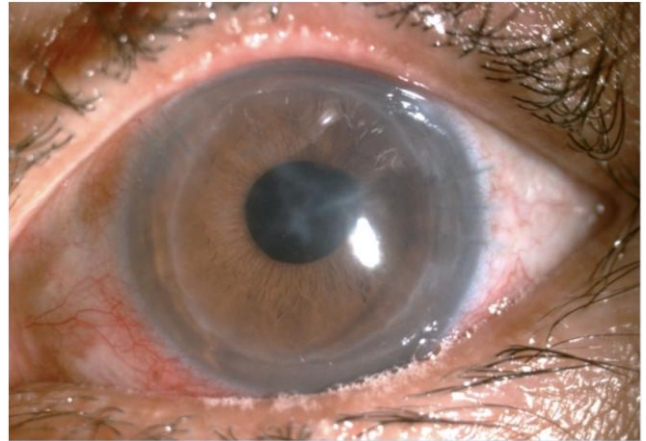


Figure 6: After foreign body removal and endothelial keratoplasty

Discussion

Penetrating ocular trauma is a common injury in ophthalmic emergency, which can result in structural and functional damage to the affected eye. Intraocular foreign bodies take up 40%-53% of penetrating ocular trauma and open globe injuries. In these cases, the prevalence of anterior chamber foreign bodies is about 15% [1]. The velocity of entry, and the size of the foreign body will determine the location at which a foreign body comes to rest. Small non-metallic foreign bodies generally have a lower velocity compared to metallic. Once they have penetrated the cornea, they tend to remain in the anterior chamber. Clinical manifestations and course of progress can vary, depending on the foreign body's composition, shape, and reaction to adjacent structures. In patients with a clear history of penetrating ocular trauma and significant symptoms, the diagnosis of intraocular foreign bodies is often confirmed at the first visit. However, intraocular foreign bodies can be missed by both the doctor and the patient due to its unapparent presence and absence of symptoms [4].

In the first patient, localized corneal edema occurred episodically with increased intraocular pressure. Treatment with medications to control inflammatory reaction and intraocular pressure only had temporary effects and it relapsed after medications were stopped. However, corneal edema and high intraocular pressure completely disappeared after the foreign body's removal.

The second patient's history revealed a

previous penetrating ocular injury caused by a bamboo branch. At the first ophthalmic examination after injury, symptoms were transient and insignificant. She presented in the first visit with grittiness, irritation and epiphora, which developed 6 months after trauma. Only when the anterior chamber foreign body was detected by gonioscopy, we found out about the history of trauma by thorough history taking. Before coming to our service, the patient was diagnosed with keratitis and managed accordingly at another eye hospital. The reason for this late discovery was that the small foreign body could have been hidden by corneal scarring. There was also no inflammatory response in the anterior chamber, which made it clinically undetectable. Thus, gonioscopic examination plays an important role in detecting intraocular foreign bodies in patients with doubtful history of penetrating trauma, peripheral corneal scarring near the limbus and localized corneal edema. Many authors have also emphasized the importance of gonioscopy to assess anterior chamber damage and identify the retained intraocular foreign bodies in penetrating ocular trauma [4], [6]. Anterior chamber foreign bodies can cause endothelial damage due to their sudden shifting or repeated small movements and mechanical contacts between them and the corneal endothelium [1], [7], [8], [9]. Furthermore, due to the endothelium's ability to compensate, patients may be asymptomatic for a long period of time. Thus, the anterior chamber foreign body can be easily missed. The existence of an anterior chamber foreign body may result in corneal edema and severe conditions such as endothelial decompensation.

Acher et al., reported ten cases of non-metallic anterior chamber foreign bodies, in which seven cases caused by glass foreign bodies, two cases of wooden and the rest of plastic material. The most common complication was corneal edema, which may not develop until months or even years (up to 20 years) after the original injury. There was one case whereby the foreign body was removed one year after trauma, and corneal edema consequently progressed to bullous keratopathy [1].

In our first case, corneal edema and increased intraocular pressure occurred one month after injury and only completely disappeared after the foreign body's removal. The second case presented with significant symptoms six months after the trauma but was diagnosed and treated as viral keratitis for a long time. Thus, although the foreign body was taken out, severe bullous keratopathy resulted in decompensation of the cornea and the need for keratoplasty. Similarly, Zengin et al., also reported a case that was treated as herpetic stromal keratitis and the history of ocular injury was not found out until the foreign body was detected by careful gonioscopic examination [7]. These interesting cases showed that the anterior chamber foreign body should be kept in mind as a differential diagnosis, and we should pay more attention to look for and detect it.

In conclusion, anterior chamber foreign body is a cause of decompensation of the corneal endothelium. Patients may be asymptomatic for a long period of time and corneal edema may not develop until the cornea has decompensated. Our cases highlighted the need to have a careful examination to detect intraocular foreign bodies, especially those located in the anterior chamber, based on the history of the ocular trauma. In patients with localized corneal edema near the limbus, thorough history taking and careful examination are necessary to diagnose the intraocular foreign body and manage promptly, which can minimize corneal lesions, and decrease the risk of complications such as endothelial damage, increased intraocular pressure, and loss of vision.

Ethics Approval

All procedures performed in studies involving human participants were in accordance with the ethical standards of the institutional and/or national research committee and with the 1964 Helsinki declaration and its later amendments or comparable ethical standards.

Informed Consent

Informed consents were collected from participating patient(s) for their anonymized information to be reported in the study.

References

1. Archer DB, Davies MS, Kanski JJ. Non-metallic foreign bodies in the anterior chamber. *Br J Ophthalmol.* 1969; 53(7):453-6. <https://doi.org/10.1136/bjo.53.7.453> PMID:5804029 PMCID:PMC1207449
2. Pujar, Chandrakant M, Narayan et al. *Journal of Evolution of Medical and Dental Sciences.* 2015; 4:2223-2227. <https://doi.org/10.14260/jemds/2015/320>
3. Iqbal M. Retained Intraocular Foreign Body. *Pak J Ophthalmol.* 2010; 26(3):158-161.
4. Griffiths ML, Lee GA. Retained intraocular foreign body. *Clin Exp Optom.* 2004; 87(1):34-6. <https://doi.org/10.1111/j.1444-0938.2004.tb03144.x> PMID:14720119
5. Anil MS, Nicholson AD, Murade SM, et al. Clinical presentations and outcomes following ocular injury with intraocular foreign bodies. *Sudanese Journal of Ophthalmology.* 2015; 7:35-40. <https://doi.org/10.4103/1858-540X.169384>
6. Loporchio D, Mukkamala L, Gorukanti K, Zarbin M, Langer P, Bhagat N. Intraocular foreign bodies: A review. *Surv Ophthalmol.* 2016; 61(5):582-96.

<https://doi.org/10.1016/j.survophthal.2016.03.005> PMID:26994871

7. Han ER, Wee WR, Lee JH, Hyon JY. A case of retained graphite anterior chamber foreign body masquerading as stromal keratitis. *Korean J Ophthalmol.* 2011; 25(2):128-31.

<https://doi.org/10.3341/kjo.2011.25.2.128> PMID:21461226

PMCID:PMC3060390

8. Zengin MO, Çinar E, Tuncer I, et al. A presenting as Retained Iridocorneal Angle Foreign Body Resembling to Disciform Keratitis A Case Report. *Journal of Glaucoma-Cataract.* 2015; 10(1):55-57.

9. Panahibazaz M, Zamani M, Borna F. Huge Bullous Keratopathy following Trauma. *J Ophthalmic Vis Res.* 2010; 5(4):278-9.