

Surpass Flow-Diverter in the Treatment of Two Wide-Neck Aneurysms in the Scheme of an Arteriovenous Malformation Patient: A Case Study

Dang Duc Phuc¹, Do Duc Thuan¹, Pham Dinh Dai¹, Dang Minh Duc¹, Nguyen Quang Anh^{2,3}, Nguyen Thi Nga⁴, Chu Dinh Toi⁵, Dao Viet Phuong⁶, Duy Ton Mai^{6,*}

¹Department of Stroke, Military Hospital 103, No 261 Phung Hung Street, Ha Dong District, Hanoi, Vietnam; ²Radiology Center, Bach Mai Hospital, Hanoi, Vietnam; ³Faculty of Radiology, Hanoi Medical University, Hanoi, Vietnam; ⁴Institute for Research and Development, Duy Tan University, 03 Quang Trung, Danang, Vietnam; ⁵Faculty of Biology, Hanoi National University of Education, Hanoi, Vietnam; ⁶Emergency Department, Bach Mai Hospital, Hanoi, Vietnam

Abstract

Citation: Duc DP, Thuan DD, Dai PD, Duc DM, Quang Anh N, Nga NT, Toi CD, Viet PD, Mai DT. Surpass Flow-Diverter in the Treatment of Two Wide-Neck Aneurysms in the Scheme of an Arteriovenous Malformation Patient: A Case Study. *Open Access Maced J Med Sci*. 2019 Dec 30; 7(24):4316-4318. <https://doi.org/10.3889/oamjms.2019.382>

Keywords: Wide-neck aneurysm; Arteriovenous malformation; Surpass flow-diverter stent

***Correspondence:** Duy Ton Mai. Emergency Department, Bach Mai Hospital, Hanoi, Vietnam. E-mail: BsTonvbachmai@gmail.com

Received: 16-Aug-2019; **Revised:** 20-Nov-2019; **Accepted:** 21-Nov-2019; **Online first:** 20-Dec-2019

Copyright: © 2019 Dang Phuc Duc, Do Duc Thuan, Pham Dinh Dai, Dang Minh Duc, Nguyen Quang Anh, Nguyen Thi Nga, Chu Dinh Toi, Phuong Dao Viet, Duy Ton Mai. This is an open-access article distributed under the terms of the Creative Commons Attribution-NonCommercial 4.0 International License (CC BY-NC 4.0)

Funding: This research did not receive any financial support

Competing Interests: The authors have declared that no competing interests exist

BACKGROUND: The cerebral arterial aneurysm, especially in the circumstances of arteriovenous malformation (AVM), has higher risk of rupture than normal isolated aneurysm. Therefore, the treatment strategy needs to be plan very carefully in such case.

CASE PRESENTATION: We report a patient with 2 wide-neck aneurysms located in the feeding artery of the arteriovenous malformation and he, then, was treated by using Surpass stent (flow-diverter) to eliminate the aneurysms.

CONCLUSION: In our case, multiple wide-neck aneurysms in combination with low risk unruptured AVM, using long Surpass stent-diversion is an effective way to eliminate all the aneurysms in the main feeding artery while still preserving the AVM anatomy.

Introduction

Cerebral arteriovenous malformation (AVM) is a brain vascular abnormality with incidence ranging from 0.89 – 1.34 case/100.000 people/year [1]. In this circumstance, the aneurysms associated with the AVM always has higher risk of rupture than the isolated ones [2], [3], [4], [5]. This is due to the high-flow in the feeding arteries of the AVM. In our case study, we want to report an AVM-patient having 2 wide-neck aneurysms in his feeding artery of right

middle cerebral artery (MCA) which was treated later by Surpass stent flow-diverter (Stryker). The rate of multiple aneurysms normally in case of subarachnoid hemorrhage ranged from 7%-45% in some previous studies [6], [7], [8], [9], [10], [11]. Additionally, aneurysms with wide-neck are defined by neck diameters greater than 4 mm or dome-to-neck ratios less than 2 and are the most difficult to treat with the endovascular method. With the appearance of flow-diverter recently, these wide-neck aneurysms can be treated in an easier way with a low rate of recurrence and complications [12].

Case Presentation

A female patient, 56 years old, was hospitalized due to slight to mild headache for a long time. A base-line CT-Scanner revealed a right parietal lesion with hyperdensity and calcification (Figure 1A) that suggested a brain AVM. Digital subtraction angiography (DSA) then confirmed the AVM diagnosis in combination with multiple aneurysms of the right ICA, the main feeding artery. The malformation size was 5x5x4 cm and its venous drained into the superior sagittal sinus (SSS) (Figure 1B). The Spetzler Martin score was 3. The first aneurysm located at the bifurcating terminal of M1 (size: 12 x 7 mm; neck: 8.3 mm) meanwhile the second aneurysm (size: 4 x 4.2 mm; neck: 3 mm) was at the M2 segment and 25 mm further from the previous one. Both aneurysms need to be treated, especially the first due to their high risk of rupture.

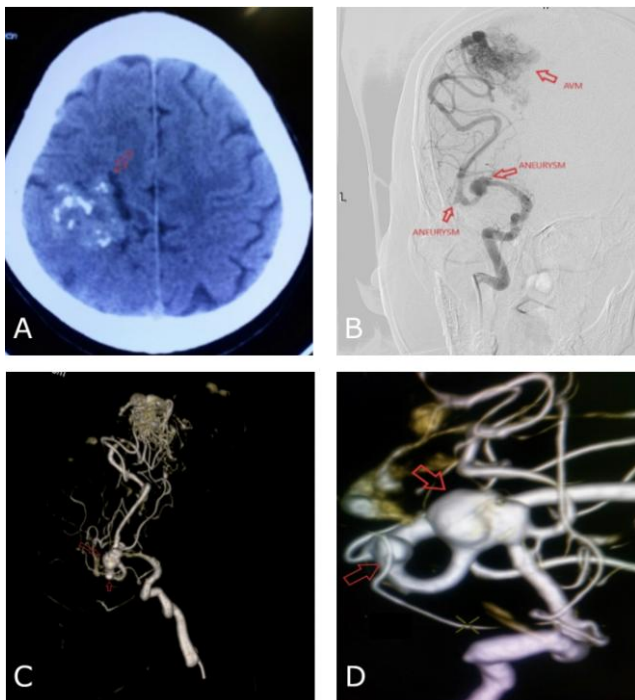


Figure 1: Fifty six year old female patient admitted to hospital due to slight headache; A) Base-line CT Scanner image showed heterogeneous hyperdensity of the right parietal lesion; B) DSA revealed the AVM with main feeding artery from right MCA; C) and D) Morphology and location of two MCA aneurysms

Dual antiplatelet therapy (DAPT) including clopidogrel 75mg/day and aspirin 100 mg/day was indicated for this patient in 5 days. The antiplatelet resistance test with ADP later showed good result of 28%. The procedure was performed under general anesthesia. Long sheath Neuron MAX 6F was placed from groin puncture to the cavernous segment of right ICA. We advanced the AXS Catalyst-5 Distal Access Catheter co-axial to the M2 segment, 10 mm further from second aneurysm location. A 4/50 Surpass flow-diverter was deployed from this point upstream to the

M1 segment to cover both aneurysms neck.

Figure 2 showed good result of stent position and coverage post deployment; no thrombus but slight vasospasm seen at M1 segment closed to the proximal part of flow-diverter. This condition was solved by 15 mins infusing solution of Natriclorid 0,9% 500 ml + heparin 5000 UI + 1,5 mg nimodipine through the Long Sheath. The final angiography showed normal contrast material through carotid vessel system.

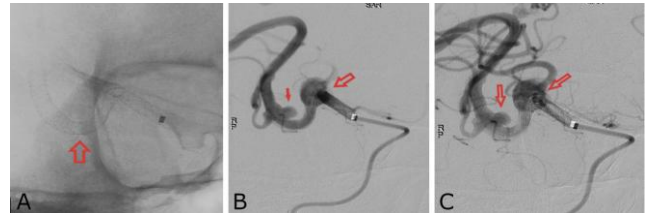


Figure 2: Angiography result during procedure; A) Surpass 4/50 after deployment: good aneurysm neck coverage and no stenosis inside stent; B) and C) Good result post flow-diversion placement with contrast material remained inside both aneurysm

Patient was discharged after 1 week and the modified Rankin scale (mRS) was 0. She was prescribed to continuously use DAPT for 6 months and followed by aspirin 100 mg daily for the rest of life.

Discussion

The normal hemorrhagic risk for unruptured AVM is low (about ~ 1.3%) meanwhile this risk of unruptured aneurysms with diameter ≥ 12 mm, according to Williams L.N. et al., is higher and need to be treated as soon as possible [13], [14]. Additionally, this patient had superficial drainage venous system (lower rate of bleeding) so that we strategized that 2 wide-neck aneurysms in the high-flow feeding MCA should be our treatment priority.

Considering between two kinds of intervention including balloon assisted-coiling or flow-diverter, we chose stent diversion because it could help to treat both wide-neck aneurysms in one phase with high rate of success and less complications [15], [16]. Akgul E. reported his case using 1 Surpass stent to treat 3 aneurysms in 2016 [17]. In our patient, to cover 2 aneurysms with 25 mm of distance between them, we needed the length of stent ≥ 50 mm. Among these available flow-diverter stents in Vietnam, only Surpass and FRED adequated this length. Moreover, with good coverage and delievery system (3.7F delivery catheter/outer catheter in combination with pusher catheter), Surpass stent was reported to have easier procedural deployment compared to other systems [18]. Therefore, surpass 4/50 was our first option in

this case. The good result post-operation showed that it was a good choice.

In conclusion, the unruptured aneurysms related to AVM have the higher risk than normal isolated one due to high-flow of main feeding artery. We need to consider the bleeding risk of both AVM and aneurysm to identify which one is our first treatment goal. In our case, multiple wide-neck aneurysms in combination with low risk unruptured AVM, using long Surpass stent-diversion is an effective way to eliminate all the aneurysms in the main feeding artery while still preserving the AVM anatomy.

Ethical Statements

This study was approved by a local Ethics Committee of Military Hospital 103.

Informed Consent

The patient has agreed in writing for using her medical data in scientific publications.

Reference

- Laakso A, Hernesniemi J. Arteriovenous Malformations: Epidemiology and Clinical Presentation. *Neurosurgery Clinics of North America*. 2012; 23(1):1-6. <https://doi.org/10.1016/j.nec.2011.09.012> PMID:22107853
- Stapf C, et al. Concurrent arterial aneurysms in brain arteriovenous malformations with haemorrhagic presentation. *Journal of Neurology, Neurosurgery & Psychiatry*. 2002; 73(3):294-298. <https://doi.org/10.1136/jnnp.73.3.294> PMID:12185161 PMCid:PMC1738025
- Abla AA, et al. The natural history of AVM hemorrhage in the posterior fossa: comparison of hematoma volumes and neurological outcomes in patients with ruptured infra- and supratentorial AVMs. *Neurosurgical focus*. 2014; 37(3):E6. <https://doi.org/10.3171/2014.7.FOCUS14211> PMID:25175444 PMCid:PMC4425310
- Platz J, et al. Frequency, risk of hemorrhage and treatment considerations for cerebral arteriovenous malformations with associated aneurysms. *Acta neurochirurgica*. 2014; 156(11):2025-2034. <https://doi.org/10.1007/s00701-014-2225-3> PMID:25246143
- Thompson RC, et al. The Management of Patients with Arteriovenous Malformations and Associated Intracranial Aneurysms. *Neurosurgery*. 1998; 43(2):202-211. <https://doi.org/10.1097/00006123-199808000-00006> PMID:9696071
- Solander S, et al. Endovascular treatment of multiple intracranial aneurysms by using Guglielmi detachable coils. *Journal of neurosurgery*. 1999; 90(5):857-864. <https://doi.org/10.3171/jns.1999.90.5.0857> PMID:10223451
- Ellamushi, H.E., et al., Risk factors for the formation of multiple intracranial aneurysms. *Journal of neurosurgery*. 2001; 94(5):728-732. <https://doi.org/10.3171/jns.2001.94.5.0728> PMID:11354403
- Jeon P, et al. Treatment of multiple intracranial aneurysms with 1-stage coiling. *American Journal of Neuroradiology*. 2014; 35(6):1170-1173. <https://doi.org/10.3174/ajnr.A3821> PMID:24371032
- Oh K, Lim YC Single-session coil embolization of multiple intracranial aneurysms. *Journal of cerebrovascular and endovascular neurosurgery*. 2013; 15(3):184-190. <https://doi.org/10.7461/jcen.2013.15.3.184> PMID:24167798 PMCid:PMC3804656
- Inagawa T. Incidence and risk factors for multiple intracranial saccular aneurysms in patients with subarachnoid hemorrhage in Izumo City, Japan. *Acta neurochirurgica*. 2009; 151(12):1623. <https://doi.org/10.1007/s00701-009-0479-y> PMID:19669689
- Kaminogo M, Yonekura M, Shibata S. Incidence and outcome of multiple intracranial aneurysms in a defined population. *Stroke*. 2003; 34(1):16-21. <https://doi.org/10.1161/01.STR.0000046763.48330.AD> PMID:12511744
- Lubicz B, et al. Flow-Diverter Stent for the Endovascular Treatment of Intracranial Aneurysms. *Stroke*. 2010; 41(10):2247-2253. <https://doi.org/10.1161/STROKEAHA.110.589911> PMID:20798369
- Kim H, et al. Untreated brain arteriovenous malformation: patient-level meta-analysis of hemorrhage predictors. *Neurology*. 2014; 83(7):590-7. <https://doi.org/10.1212/WNL.0000000000000688> PMID:25015366 PMCid:PMC4141996
- Williams LN, Brown RD. Management of unruptured intracranial aneurysms. *Neurology: Clinical Practice*. 2013; 3(2):99-108. <https://doi.org/10.1212/CPJ.0b013e31828d9f6b> PMID:23914319 PMCid:PMC3721237
- Rouchaud A, et al. Endovascular Treatment of Ruptured Blister-Like Aneurysms: A Systematic Review and Meta-Analysis with Focus on Deconstructive versus Reconstructive and Flow-Diverter Treatments. *American Journal of Neuroradiology*. 2015; 36(12):2331-2339. <https://doi.org/10.3174/ajnr.A4438> PMID:26381557
- Wakhloo AK, et al. Surpass flow diverter in the treatment of intracranial aneurysms: a prospective multicenter study. *American Journal of Neuroradiology*. 2015; 36(1):98-107. <https://doi.org/10.3174/ajnr.A4078> PMID:25125666
- Akgul E, et al. A Patient with Eight Intracranial Aneurysms: Endovascular Treatment in Two Sessions. *Case reports in neurological medicine*. 2016; 2016. <https://doi.org/10.1155/2016/9637905> PMID:27668108 PMCid:PMC5030425
- Rajah G, Narayanan S, Rangel-Castilla L. Update on flow diverters for the endovascular management of cerebral aneurysms. *Neurosurg Focus*. 2017; 42(6):E2. <https://doi.org/10.3171/2017.3.FOCUS16427> PMID:28565980