

Primary Cementless Bipolar Long Stem Hemiarthroplasty for Unstable Osteoporotic Intertrochanteric Fracture in the Elderly Patients

Tran Trung Dung^{1,2}, Nguyen Dinh Hieu³, Le Manh Son⁴, Thien Chu Dinh⁵, Toi Chu Dinh^{6*}

¹Department of Orthopaedic and Sport Medicine, Saint Paul Hospital, Hanoi, Vietnam; ²Department of Orthopaedic and Neurosurgery, Hanoi Medical University Hospital, Hanoi, Vietnam; ³Department of Orthopaedic and Traumatology, E Hospital, Hanoi, Vietnam; ⁴Department of Orthopaedic and Traumatology 3, Viet Duc Hospital, Hanoi, Vietnam; ⁵Institute for Research and Development, Duy Tan University, 03 Quang Trung, Danang, Vietnam; ⁶Department of Human and Animal Physiology, Faculty of Biology, Hanoi National University of Education, Hanoi, Vietnam

Abstract

Citation: Dung TT, Hieu ND, Son LM, Chu Dinh T, Chu Dinh T. Primary Cementless Bipolar Long Stem Hemiarthroplasty for Unstable Osteoporotic Intertrochanteric Fracture in the Elderly Patients. Open Access Maced J Med Sci. 2019 Dec 30; 7(24):4342-4346. <https://doi.org/10.3889/oamjms.2019.388>

Keywords: Unstable intertrochanteric fracture; Osteoporotic; Elderly patient; Bipolar long stem hemiarthroplasty; Cementless

***Correspondence:** Toi Chu Dinh. Department of Human and Animal Physiology, Faculty of Biology, Hanoi National University of Education, Hanoi, Vietnam. E-mail: chudinhtoi.hnue@gmail.com

Received: 05-Sep-2019; **Revised:** 20-Nov-2019; **Accepted:** 21-Nov-2019; **Online first:** 20-Dec-2019

Copyright: © 2019 Tran Trung Dung, Nguyen Dinh Hieu, Le Manh Son, Thien Chu Dinh, Toi Chu Dinh. This is an open-access article distributed under the terms of the Creative Commons Attribution-NonCommercial 4.0 International License (CC BY-NC 4.0)

Funding: This research did not receive any financial support

Competing Interests: The authors have declared that no competing interests exist

BACKGROUND: Intertrochanteric fracture (ITF) is a major part of fracture in femoral head fracture. 95% of ITF are found in elderly patients. Osteosynthesis is the preferred method of choice. However, elderly patients had osteoporotic, combined with many of chronic disease conditions that increase the rate of osteosynthesis failure. Hemiarthroplasty bipolar long-stem is a surgical method that helps patients relieve pain, facilitate early rehabilitation, limit long-term complications, and improve quality of life for patients.

AIM: The aim of our study is to evaluate the clinical of result of primary cementless bipolar long stem hemiarthroplasty in treatment for unstable ITF in the elderly patients who have severe osteoporosis.

METHODS: Between 01/2016 and 12/2017, 35 patients with ITF type A2.2 and A2.3 (AO) were included in our prospective study. These patients were over 70 years old and treatment by hemiarthroplasty cementless long stem at E hospital and Saint Paul hospital by one group surgeons.

RESULTS: Mean age of studied subjects was 84.29 ± 6.17 , the lowest was 71, the highest was 96; ratio male/female was 1/4. Follow-up of 35 patients for at least 6 months showed 88.6% caused by a low-energy injury; Average rehabilitation time was 4.63 ± 1.7 days. The average Harris point at the end was 90.4 ± 4.72 .

CONCLUSION: Primary cementless bipolar long stem hemiarthroplasty is one of good choices in treatment unstable ITF in elderly patients with severe osteoporosis helped patients improve the quality of life.

Introduction

ITF is a major part of fracture in femoral head fracture. Ninety-five percent of ITF are found in elderly patients [1]. The most common cause is the poor bone with low energy injury [2]. 90% patients over the age of 70, the mortality rate after fracture from 15%-20%, treatment cost about 10 billion dollars a year [3]. Osteosynthesis is the preferred method of choice. However, elderly patients had osteoporotic, combined with many of chronic disease conditions that increased the rate of osteosynthesis failure. Won Sik Choy (2010) studied and reported 40 patients with cardiovascular disease and diabetes at the highest percentage of patients in the study 45% and 27.5%

[4].

Hemiarthroplasty bipolar long-stem is a surgical method that helps patients to relieve pain, facilitate early rehabilitation, limit long-term complications, and improve quality of life for patients. For more than a decade, many authors have studied and evaluated the result of this surgery. Won Sik Choi (2009) has evaluated in 45 patients with ITF, aged 70 and over, after 2 years follow the average Harris hip score (HHS) at the last time was 80.6 ± 9.3 [4]. That was excellent result with patients osteoporotics have fractures unstable intertrochanterics. The author concluded that "the short-term result of cementless bipolar hemiarthroplasty in elderly patients with unstable ITF demonstrated satisfactory results" [4].

Materials and Methods

Between 01/2016 to 12/2017, 35 patients with unstable comminuted ITF and osteoporosis (Figure 1) were treated by primary cementless bipolar long stem hemiarthroplasty at E Hospital and Saint Paul Hospital. The track period was 6 months. Average age was 84.29 years (range 71-96). They were included from the AO classification A2.2 in 14 patients and A2.3 in 21 patients. The Singh index was 2 in 27 patients and 3 in 8 patients. Average time from hospitalisation to intervention was 3.4 days. The elderly patients often have many chronic diseases association, including cardiovascular disease, diabetes mellitus, lung disease, and others.

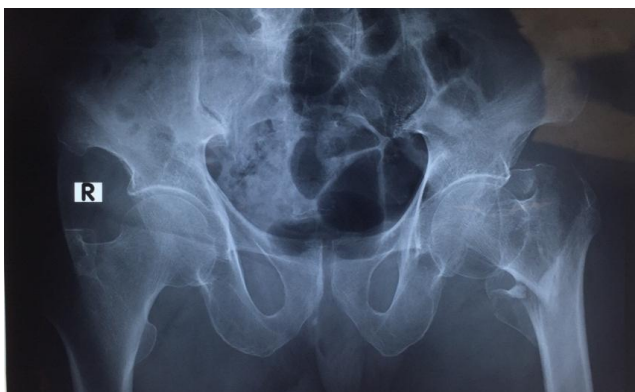


Figure 1: Pre-operative X-ray

Operative technique

Posterior lateral approach was used. Orientation of the prosthesis was made out using the lesser trochanter anatomically and posterior condylar plane. The fracture trochanter was reduced and fixed to the prosthesis with stainless steel wires (Figure 2).

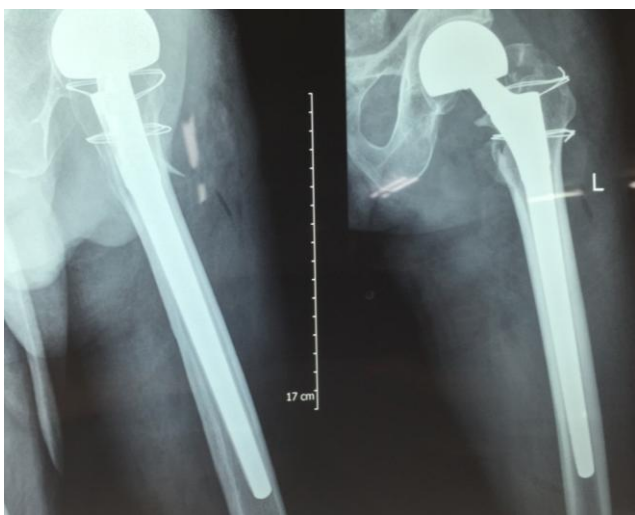


Figure 2: Post-operative x-ray

Pre-operation 12h, we used antibiotic and low-molecular weight heparin (enoxaparin) for the

patients. In post-operative phase, we used antibiotic and enoxaparin for 5 days. Non-weight bearing (WB) exercises were started on the second day after operation, partial WB exercises were started in 4 post-operation days.

Patients were followed in 1 month, 3 months, and 6 months. Follow-up patients were assessed according to the score of HHS.

Data in our study were analysed and calculated by the medical statistics software SPSS 20.2

Results

Average follow up time was 6 months. Mean age was 84.29 ± 6.17 years (range 71-96). The ratio men/women were $\frac{1}{4}$. 88.6% were caused by a low-energy injury. Average Singh index was 2.23 ± 0.426 . Most patients with chronic disease in which the two groups accounted for the highest rate of cardiovascular disease and diabetes accounted for 40% and 22.9% (Table 1).

Table 1: Accompanied medical diseases

Medical disease	n	%
Respiratory disease	2	5.7
Cardiovascular	14	40
Diabete	8	22.9
Urinary disease	5	14.3
Rheumatology disease	3	8.6
Other	9	25.7

Mean operation time was 64 ± 24.9 ; mean peri-operative blood transfer was 643.7 ml; mean time rehabilitation was 4.63 days; mean time hospital was 14.69 days.

Complications post-operative was included in 3 patients accounted 8.6% (Table 2). One patient was superficial infection and two others were pulmonary infection. All of them were treated well before being discharged from the hospital.

Table 2: Complication post-operative

Complication	n	%
Superficial infection	1	2.9
Dislocation	0	0
Lung infection	2	5.7
Cardiovascular	0	0
Die	0	0
Total	3	8.6

After 6 months, 22 patients had no pain, 13 had mild pain; 30 patients without aids, 5 patients with crutches; The mean HHS was 90.4 ± 4.72 , of which 24 were excellent (68.6%), 10 were very good (28.6%), 1 was good (2.9%) and none show poor results (Table 3).

Table 3: Harris hip score post-operative 6 months

Result	Excellent	Very good	Good	Poor	Total
n	24	10	1	0	35
%	68.6	28.6	2.9	0	100
Average	90.4 ± 4.72				

Discussion

According to the previous researches, the method osteosynthese is preferred with a lot of material such as lock plate, DHS plate, Pfna nail, and gamma nail. However, there are many problems associated with osteosynthese of unstable ITF in senile patients with osteoporotic bone: pseudarthrose, loss of fixation, and cut-out of the lag screw. For earlier WB after operation and to protect the fracture stable, some surgeons have recommended prosthetic replacement, especially with a long stem prosthesis hemiarthroplasty for the treatment of unstable ITF [5], [6], [7].

Our results indicate that a primary partial replacement with long stem prosthesis decrease pain, early rehabilitation, stability of the implant in long time, decrease complications in unstable ITF of femur osteoporosis severe.

Mean time rehabilitation in our study is 4.63 ± 1.7 days. This is a period of early rehabilitation, helps patients to move early, facilitate the process of care, avoid the risk of long-term complications such as pressure sores, pneumonia, urinary tract inflammation. According to Su-Hyun Cho (2014) the average time to partial weight-bearing is 7 days after hemiarthroplasty surgery for patients with fracture intertrochanteric [8]. Shin-Yoon Kim (2005) compared two groups of arthroplasty and osteosynthese with PFNa, showing the average time of rehabilitating exercise in the arthroplasty group was 7.8 ± 1.6 days, while in the group osteosynthese was 8.8 ± 2.9 days [9]. Parvjeet et al., (2009) compared two groups of hemiarthroplasty bipolar long stem and osteosynthese with DHS plate, which resulted in an average partial stand-up time of the arthroplasty group was 7 days, while osteosynthese group was 10.1 days. The reason is the hemiarthroplasty bipolar long-stem strengthened the joints and fractures so that the patient could practice early and weight-bearing early [10].

When compared with previous results of osteosynthese, hip replacement surgery gave the same or better results [9], [11], [12], [13]. In the osteoporotic patients, treatment osteosynthese for unstable ITF needed a long time to WB. And this solution has many complications such as loss of fixation, pseudarthrose, and cut-out of the lag screw [14].

Some authors supported the point of view

primary hemiarthroplasty to evade these complications of osteosynthese and help the patient have early rehabilitation, early come back to the normal activity before fracture. However, with a canal of osteoporotic femur, the stable fixation of stem into the canal is very poor. And they preferred cemented stem to get an immediate stability of the prosthesis [14]. Though, the intervention with cement rise the risk of embolism and may cause secondary cardiopulmonary complications, particularly in senile patients with many chronic diseases. With the cementless long stem we can avoid using cement while still ensuring the stability of the fracture. The stem which was used is a tapered round-rectangular stem. It fits into the distal diaphysis of femur (Figure 2). This method is based on the principle of fixation at the distal of femur which reduces the impact on the level fracture. With this stem, first stability and long-term biologic fixation can be got even in osteoporotic proximal femur with large bone defect [15].

In the study of Rothman, the author has noticed that the problems such as bleeding, and operative time in cementless stems is lower than cemented stems [16].

Deniz et al., (2013) compared two hemiarthroplasty groups: cemented and cementless treatment to fracture intertrochanteric, resulting in HHS of the group cemented higher than the cementless group, however the rate of complications in and after surgery of the group cemented much higher. The ratio of patients who died after surgery during hospital stay was 13% compared to 0% in cementless group with $p < 0.05$ with statistical significance. Therefore, the author still recommends the use arthroplasty cementless, and a method to improve the stability of postoperative joints is using a long stem to fix at the distal of the femoral [13].

Keating (2017) the ratio of patients with general complications (including infection, pneumonia, deep vein thrombosis ...) in the osteosynthese group was 22.73% in the hemiarthroplasty group was 18.01% [17].

Florian Geiger (2007) studied the ratio mortality patients postoperative with osteosynthese group and arthroplasty group, the results as follows: mortality after 1 year in osteosynthese group is 39.8% also in arthroplasty group is 33% [14].

Jaswinder compared two groups including hemiarthroplasty (group 1) and totalarthroplasty (group 2) in the elderly, showing that the HHS on group 2 were higher than that of the group 1. However, the rate of articular dislocation in the group 2 was higher than that of the group 1 (8% vs 0%), while the length of surgery was longer, the cost of surgery was higher. The authors recommend that although total joint replacement should be more effective, the option of hemiarthroplasty should be selected in treatment unstable ITFs in the elderly patients [18].

A study compares between hemiarthroplasty and osteosynthese of Khadoun Sinno in 2010. Result post-operative: for the group arthroplasty time fullWB was earlier than group osteosynthese and the point Harris was higher [19].

Yeesuk Kim followed 161 elderly patients after bipolar hemiarthroplasty with the time average was 3.8 years, the result obtained was positive with an average HHS at the last time was 82 [20]. The author also recommends that bipolar hemiarthroplasty is a good choice for senile patients with osteoporotic unstable ITFs [20].

In the study of Kayali et al., [21], when they compared 2 groups in treatment un stable ITF . group 1 included 42 hemiarthroplasties with group 2 included 45 osteosynthese. And they found that average time rehabilitation of group 1 lower than group 2.

In this study, we obtained excellent and very good about 97% post-operative 6 months, there were no dislocation and loosening. Time rehabilitation was about 4 days. Short- term cementless long stem bipolar seems to give better results than osteosynthese with the death rate, complication, early WB and early return to pre-fracture activities.

In 2011 Young Kyun Lee reported 87 patients with long stem bipolar for unstable intertrochanteric results 14.7 points for the scale Merle d'Aubigné [22], [23]. The author assumed even if the final results were not quite good and good, the long-term hemiarthroplasty method is still an effective method which can be applied for the unstable ITF in senile patients [22].

In our study, there were some restrictions. First, our study had short follow-up. Because a long follow-up study is very difficult for us, and has a few of clinical relevance in senile patients who have a short life and limited activity during their life. Secondly, our study has not compared between osteosynthese and arthroplasty. In addition we have not conducted a collation with cemented procedure. This is because we were afraid of the complications of cemented procedure. We will elaborate further on this matter in our future work reports.

Although these restrictions, we has successfully demonstrated that primary cementless bipolar long stem hemiarthroplasty is a satisfactory indication for elderly patients with unstable ITF of femur osteoporosis severe.

In conclusion, the difficulty is that we cannot say this method is better than internal fixation, but according to the result of our study, cementless bipolar long stem hemiarthroplasty is also a good indication when treating unstable ITF in elderly patients osteoporotic. The patients have better prognosis, early WB, early rehabilitation, decrease the complications and increase quality of life. In order to better evaluate the effectiveness of this method,

research on larger numbers of patients is required, and in the longer term, with more evaluation criteria, this helps to open up ideas for our studies next.

Ethical approval

This is a one of indications to treat unstable ITF in the elderly patients who have severe osteoporosis. This method has been applied in many countries as well as many hospitals in Vietnam, so this study does not require the ethical approval.

Informed consent

The consent and commitment were signed by the patients in the study and their families.

Reference

1. Guyton JL. Fractures of hip - Acetabulum and Pelvis. Campbells operative orthopaedics, 9th Edit (Mosby), 2003:2181-2262.
2. Lindskog DM, Baumgaertner MR. Unstable Intertrochanteric hip Fractures in the Elderly. J. Am Acad Orthop Surg. 2004; 12:179-190. <https://doi.org/10.5435/00124635-200405000-00006> PMID:15161171
3. Lorich DG, Geller DS, Nielson JH. Osteoporotic pertrochanteric hip fractures. Management and current controversies. J. Bone Joint Surg Am. 2004; 86:398-410. <https://doi.org/10.2106/00004623-200402000-00028>
4. Choy WS, Ahn JH, Ko JH, Kam BS, Lee DH. Cementless bipolar hemiarthroplasty for unstable intertrochanteric fractures in elderly patients Clinics in orthopedic surgery. 2010; 2(4):221-226. <https://doi.org/10.4055/cios.2010.2.4.221> PMID:21119938 PMID:PMC2981778
5. Broos PL, et al. Pertrochanteric fractures in the elderly. Is the Belgian VDP prosthesis the best treatment for unstable fractures with severe comminution? Acta Chir Belg. 1991; 91:242-9. <https://doi.org/10.1097/00005131-199112000-00010>
6. Harwin SF, Stern RE, Kulick RG. Primary Bateman-Leinbach bipolar prosthetic replacement of the hip in the treatment of unstable intertrochanteric fractures in the elderly. Orthopedics. 1990; 13:1131-6.
7. Green S, Moore T, Proano F. Bipolar prosthetic replacement for the management of unstable intertrochanteric hip fractures in the elderly. Clin Orthop Relat. 1987; 224:169-77. <https://doi.org/10.1097/00003086-198711000-00024>
8. Cho SH, Cho HL, Cho H. Primary Cementless Hip Arthroplasty in Unstable Intertrochanteric Femur Fracture in Elderly: Short-term Results. Hip Pelvis. 2014; 26(3):157-65. <https://doi.org/10.5371/hp.2014.26.3.157> PMID:27536574 PMID:PMC4971141
9. Kim SY, Kim YG, Hwang JK. Cementless calcar-replacement hemiarthroplasty compared with intramedullary fixation of unstable intertrochanteric fractures: a prospective, randomized study. JBJS.

2005; 87(10):2186-92. <https://doi.org/10.2106/00004623-200510000-00005>

10. Parvjeet Singh Gulati, et al., Comparative study of treatment of intertrochanteric fracture of femur with long-stem bipolar prosthetic replacement versus dynamic hip screw fixation. *Pb Journal of Orthopaedics*. 2009; 1:38-40.

11. Little NJ, et al. A prospective trial comparing the Holland nail with the dynamic hip screw in the treatment of intertrochanteric fractures of the hip. *J Bone Joint Surg Br*. 2008; 8:1073. <https://doi.org/10.1302/0301-620X.90B8.20825> PMID:18669966

12. Lihong F, Dang X, Wang K. Comparison between bipolar hemiarthroplasty and total hip arthroplasty for unstable intertrochanteric fractures in elderly osteoporotic patients. *PLoS One*. 2012; 7(6):e39531. <https://doi.org/10.1371/journal.pone.0039531> PMID:22745778 PMCID:PMC3382155

13. Cankaya D, Ozkurt B, Tabak AY. Cemented calcar replacement versus cementless hemiarthroplasty for unstable intertrochanteric femur fractures in the elderly. *Ulus Travma Acil Cerrahi Derg*. 2013; 19(6):548-53. <https://doi.org/10.5505/tjtes.2013.57615> PMID:24347215

14. Geiger F, et al. Trochanteric fractures in the elderly: the influence of primary hip arthroplasty on 1-year mortality. *Arch Orthop Trauma Surg*. 2007; 127(10):959-66. <https://doi.org/10.1007/s00402-007-0423-7> PMID:17899138 PMCID:PMC2111040

15. Keisu KS, Orozco F, Sharkey PF. Primary cementless total hip arthroplasty in octogenarians. Two to eleven-year follow-up. *J Bone Joint Surg Am*. 2001; 3:359. <https://doi.org/10.2106/00004623-200103000-00007> PMID:11263639

16. Rothman RH, Cohn JC. Cemented versus cementless total hip arthroplasty. A critical review. *Clin Orthop Relat Res*. 1990;

254:153. <https://doi.org/10.1097/00003086-199005000-00024>

17. Keating JF, et al. The journal of bone and joint surgery. 2017; 88(2):249-260. <https://doi.org/10.2106/JBJS.E.00215> PMID:16452734

18. Walia JP, Sansanwal D, Walia SK, Singh S, Gupta AC. Role of primary bipolar arthroplasty or total hip arthroplasty for the treatment of intertrochanteric fracture femur in elderly. *Pb Journal of Orthopaedics*. 2011; 12(1):5-9.

19. Sinno K, Sakr M, Girard J, Khatib H. The effectiveness of primary bipolar arthroplasty in treatment of unstable intertrochanteric fractures in elderly patients. *North American journal of medical sciences*. 2010; 2(12):561. <https://doi.org/10.4297/najms.2010.2561> PMID:22558568 PMCID:PMC3338223

20. Kim Y, Moon JK, Hwang KT, Choi IY, Kim YH. Cementless bipolar hemiarthroplasty for unstable intertrochanteric fractures in octogenarians. *Acta Orthop Traumatol Turc*. 2014; 48(4):424-430. <https://doi.org/10.3944/AOTT.2014.13.0119> PMID:25230266

21. Kayali C, et al. Treatment for unstable intertrochanteric fractures in elderly patients: internal fixation versus cone hemiarthroplasty. *Journal of Orthopaedic Surgery*. 2006; 14(3):240-244. <https://doi.org/10.1177/230949900601400302> PMID:17200522

22. Lee YK, et al. Cementless bipolar hemiarthroplasty using a hydroxyapatite-coated long stem for osteoporotic unstable intertrochanteric fractures. *J Arthroplasty*. 2011; 26(4):626-32. <https://doi.org/10.1016/j.arth.2010.05.010> PMID:20637559

23. D'Aubigne RM, Postel M. Functional results of hip arthroplasty with acrylic prosthesis. *J Bone Joint Surg Am*. 1954; 3:451. <https://doi.org/10.2106/00004623-195436030-00001>