

# “False Patellar Duplication” Originated from Synovial Osteochondromatosis in Knee Joint: A Rare Case Report

Dung Tran Trung<sup>1,2</sup>, Tung Pham Son<sup>1</sup>, Thien Chu Dinh<sup>3</sup>, Toi Chu Dinh<sup>4\*</sup>

<sup>1</sup>Saint Paul University Hospital, Hanoi, Vietnam; <sup>2</sup>Hanoi Medical University, Hanoi, Vietnam; <sup>3</sup>Institute for Research and Development, Duy Tan University, 03 Quang Trung, Danang, Vietnam; <sup>4</sup>Department of Human and Animal Physiology, Faculty of Biology, Hanoi National University of Education, Hanoi, Vietnam

## Abstract

**Citation:** Trung DT, Son TP, Chu Dinh T, Chu Dinh T. “False Patellar Duplication” Originated from Synovial Osteochondromatosis in Knee Joint: A Rare Case Report. Open Access Maced J Med Sci. <https://doi.org/10.3889/oamjms.2019.389>

**Keywords:** False patellar duplication; Synovial osteochondromatosis

**\*Correspondence:** Toi Chu Dinh, Department of Human and Animal Physiology, Faculty of Biology, Hanoi National University of Education, Hanoi, Vietnam. E-mail: [chudinhtoi.hnue@gmail.com](mailto:chudinhtoi.hnue@gmail.com)

**Received:** 05-Sep-2019; **Revised:** 20-Nov-2019; **Accepted:** 21-Nov-2019; **Online first:** 20-Dec-2019

**Copyright:** © 2019 Dung Tran Trung, Tung Pham Son, Thien Chu Dinh, Toi Chu Dinh. This is an open-access article distributed under the terms of the Creative Commons Attribution-NonCommercial 4.0 International License (CC BY-NC 4.0)

**Funding:** This research did not receive any financial support

**Competing Interests:** The authors have declared that no competing interests exist

**BACKGROUND:** “False patellar duplication” is a situation where there are two pieces in the position of a knee-joint like patella. It can derive from cartilage tumors, soft tissue tumors, or gout tumors, or due to the heterotopic ossification, forming a sub patella in the knee joint.

**CASE REPORT:** A woman, 57 years old, healthy history, she has hospitalized for right knee joint pain since 2 years. Diagnosis: the synovial osteochondromatosis of the right knee. We decided to conduct and arthroscopy and removal. After 18 months surgery, the patient knee joint is currently good, range of motion (ROM) (-10)°- 0°- 160°, Lysholm Knee Scoring Scale 85/100 point.

**CONCLUSION:** This is the second case in the world and the first case in Vietnam. This is an experience in the process of diagnosis, arthroscopic treatment and differentiation from the “double patellae” status.

## Introduction

The synovial osteochondromatosis are a begin metaplasia of the synovial fluid, in which the connective cells have the ability to self-produce cartilages. The relapse rate is high, about 7.1%-39% [8], [9], [14], [13]. The synovial osteochondromatosis are commonly present in the knee joint, accounting for 50%-60%, then in other joints such as hip and shoulder joints, elbows and ankles joints. When the synovial osteochondromatosis in the knee joint have large size, they will limit the knee joints movement, cause pain for patient, limit movement, causing knee joint effusion; making doctors mistakenly think that it is patellar duplication, sub patella, nonunion of patella fracture, ... There have been many cases report of synovial osteochondromatosis in knee joint causing reported deformity, as reported by Tushar Kambale [3], Sunil Kukreja [4], Samir Dwidmuthe [7], Hugh Mackenzie [5] .... and all authors had to open surgery

to remove the cartilage osteochondromatosis.

“Double patellae” or “patellar duplication” means there are two patellae on one knee, this is a very rare case and in the world medical literature, currently only about 15 published cases [12]. When a child, the central cartilage develops into the patella. In some cases, the cartilages divides into another 2, 3 partite (this is very rare) which will develop into the patella, resulting in a “True patella duplication” [2]. “False patellar duplication” is a situation where there are two pieces in the position of a knee joint like patella, in which one is a true patella that originate from the central cartilage, another is a non- patella, but in an adjacent position and we think it is a patella too. It can derive from cartilage tumors, soft tissue tumors, or gout tumors, or due to the heterotopic ossification, forming a sub patella in the knee joint. In the world medical literature, there is only one case of “false patellar duplication” that originated from synovial osteochondromatosis published in 2012 by Yoshiteru Kajikawa [12] and he had to open surgery to

remove the these block, my case is the second case in the world and the first case in Vietnam of false patellar duplication originated from synovial osteochondromatosis that I had arthroscopic treatment and followed for the past 18 months.

## Case Report

The patient is a woman, 57 years old, healthy history, no history of right knee joint injury, not detected abnormalities in the right knee joint. She has hospitalized for right knee joint pain for 2 years. According to the patient, she felt an abnormal mass under the right patella 10 years ago. At the beginning, the mass was small that she could only touch but not see. She didn't have pain or feel pain. Gradually it increases the volume, in the last 2 years it has affected her knee joint function: more difficult walking, reduced movement, swollen knees, pain, not hot, no fever. She had many examinations and was diagnosed: right knee osteoarthritis and treated towards the knee joint osteoarthritis. After 2 years, it is not better, movement limit increased so she went to the Saint Paul Hospital for examination.

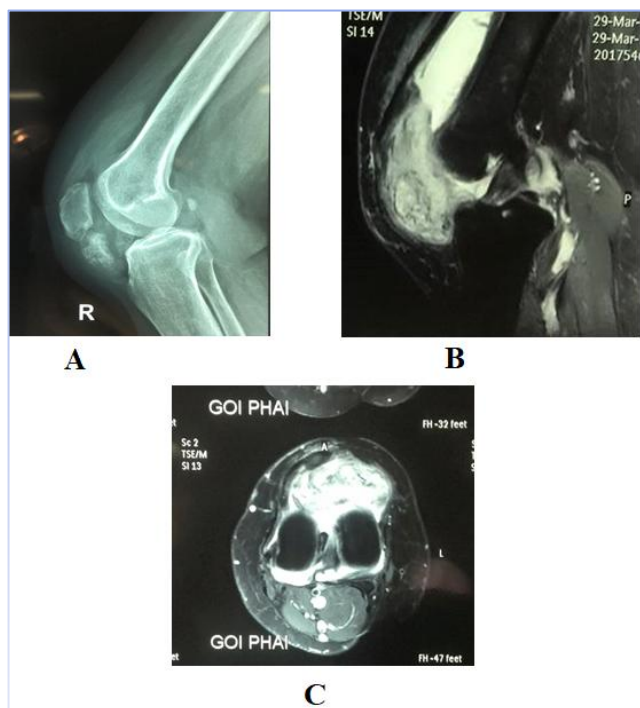


Figure 1: X-ray and MRI before surgery. A. X-ray before surgery; B and C. MRI before surgery

Through the examination, the doctors at the Saint Paul Hospital detected a positive mass of 26mm x 62mm size at the lower patella, with clear boundaries and not existence of penetration or metastasis, swollen knee, ROM 20°-30°-90° degree, Lysholm Knee Scoring Scale 50/100 points, no infection syndrome, leukocyte 4.5 G/l, neutral 58%, X-

ray: a mass with calcium deposits in the right lower patella; on MRI film, there is image of knee joint effusion, the thickest is 21 mm, the wall of the synovial fluid is thick with medicine after injection, the lower part of synovial fluid has the structure of 26 mm x 62 mm size, increasing and decreasing uneven signal on T1W and T2W, do not absorb the medicine after the magnetic contrast injection (Figure 1). Diagnosis before surgery: the synovial osteochondromatosis of the right knee.

We decided to conduct an arthroscopy, we may use the "bone cutter shaver blade" if the mass is hard and had an open surgery plan if it was not possible to cut them for arthroscopy removal. We carried out arthroscopy into the knee joint with 2 trocar holes, because cartilage takes up most of the lower inner cavity so our inlet hole must be placed higher than the normal position, from about 1cm to avoid the tumor. When we were checking, we found knee osteoarthritis, femoral condylar offset began to disappear, bilateral meniscus tear, the anterior cruciate ligament and the posterior cruciate ligament are normal with a lot of fluid. A cartilage mass located at the injury, not attached to the patella, derived from the synovial membrane, occupying the entire area of the anterior cavity and the inner cavity in the knee joint, limiting the right knee movement (Figure 2A).

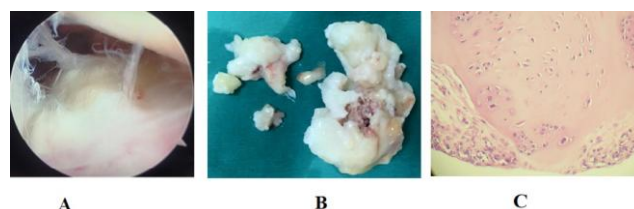


Figure 2: Image in surgery; A) Images in arthroscopy; B) Synovial osteochondromatosis after surgery; C) The anapathology of synovial osteochondromatosis

We used the bone cutter shaver blade and soft tissue cutter shaver blade, proceeded to clean the knee joint, meniscectomy, repaired the cartilage, cut and planed this cartilage tumor, then used the forceps to hold them out of the knee one after another and send to the anapathology (Figure 2B). After removing all of the masses, we checked the knee joint movement and saw that its movement is good, ROM 0°-5°-120°, we placed the drain and closed the skin. The operation time is 90 minutes. The patient used betalactam antibiotics, anti-inflammatory, analgesics and rehabilitation training on the first day after surgery, withdrew the drain after 2 days and discharged 5 days after surgery. The result of anapathology is synovial osteochondromatosis (Figure 2C). Through regular check-ups after 2 weeks, 1 month, 3 months, 6 months, 12 months, 18 months, the patient knee joint is currently good, ROM (-10°)-0°-160°, without pain while sitting, painful while walking due to the condition of knee osteoarthritis, Lysholm Knee Scoring Scale 85/100 point (Figure 3). We didn't find any signs of relapse of synovial

osteochondromatosis.

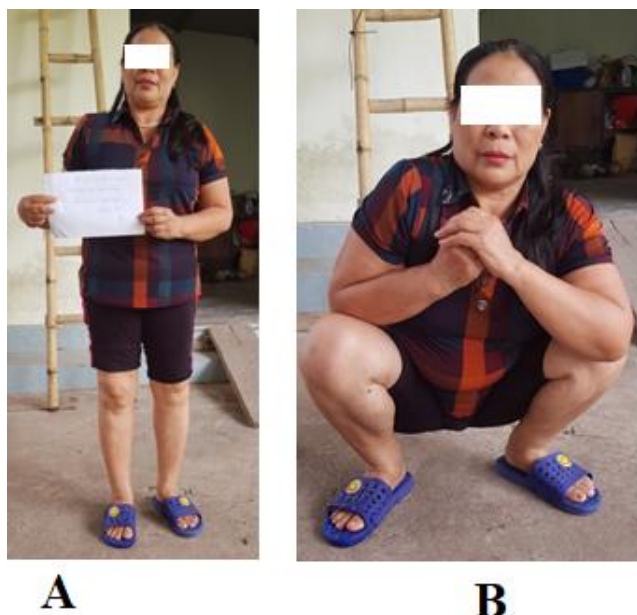

Figure 3: Knee function after 18 months of surgery; A) Extending knee posture; B. Flexing knee posture

## Discussion

The proportion of congenital "patellar duplication" or "double patella" is extremely low, very rare in the clinical world and in the world medical literature, now only about 15 cases have been published in the world; in which "false patellar duplication" due to the synovial osteochondromatosis, this is the second case published in the world, the first case was published by the Japanese author Yoshiteru Kajikawa [12] in 2012 and he had to open surgery to remove the these block . The "false patellar duplication" has many causes, probably of cartilage tumor, gout tumor, soft tissue tumor or sub patella, sometimes false knee joint of the patella. To know exactly what the "false patellar duplication" is and where it comes from, the best method is surgery to draw the false patella out and send it to the anapathology. However, we based on the question of the disease history, medical history and clinical examination, and we can also determine up to 80% of what the false patella is and where it came from. For example, if the false patella due to gout tumor, the patient has a gout history, this false patella was usually not mobile, has lied next to the bone for a long time; or the false patella originated from cartilage tumors, so these cartilage tumors were often mobile and have appeared for a long time. "False patellar duplication" is usually benign, just lies next to the patella and affects the patella's movement, not malignant, invasive and metastatic. It is for this reason

that in the image of X-ray film, the real patella, the femur condyle and the tibia higher head are normal, no secondary injury caused by the "false patellar duplication"; on the contrary, when "false patellar duplication" is malignant, invades the surrounding organs, making the surrounding soft tissues change the nature, the bone part will have the image of bone defect, periosteum reaction, bone deformity, ....

In case the first "false patellar duplication" originates from the synovial osteochondromatosis published by Yoshiteru Kajikawa, the author described the mass behind the patella in large size and there are many smaller cartilage tumors in the joint. Normally, the synovial osteochondromatosis are not rare, but often they are small in size and located in the joints for many years, however, there are some favorable conditions that facilitate the synovial osteochondromatosis to develop, the authors Itaru Tojyo [15] and Seiya Jingushi [11] have found a relation between hormones to the growth factor the synovial osteochondromatosis, which is specifically related to fibroblast growth factor (FGF: FGF-2 and FGF-3). These factors will facilitate the synovial osteochondromatosis to develop, promote cartilage division that makes the cartilage size grow larger than usual.

The false patellar duplication can be located anywhere in the knee joint, either inside or outside the patella, or can come out behind the patella. The authors Eric Yeung and John Ireland reported a case of the false patellar duplication appeared after a 6-year knee joint injury, after the surgery, the author concluded that the mass was bone, limiting movement for injured knee joints. In addition, the most recently in 2017, the author Annemieke [1], has published a case of the false patellar duplication behind the patella due to Multiple Epiphyseal Dysplasia (MED), causing a double layer of patella, that means the true patella lying on the other patella, the author asked to have MRI to accurately assess the level of the compression of the tendon, the patella cartilage and strange things hidden in the joint before treatment. The author Eric Saupe [6] studied and classified double patella into 3 types, each type has its own characteristics. The first type is that the patella is divided in the lower part, making the patella have 2 pieces: big piece at the top and the small piece at the bottom. The second type is the patella split vertically, a big piece and a small piece on the opposite side. The last type is the third type, the divider line at the upper corner into the big piece at the bottom and the small piece at the top.

The condition of false patellar duplication is largely asymptomatic, but in some cases, it may be the cause of knee joint pain that cannot be explained by other causes, which can cause knee joints movement limitations because they caused joints obstruction or block the movement of the patella and femoral condyle and tibial plateau. In addition, if their size is too large, they can cause patella dislocation, causing joint deformities, joint effusion or joint

stiffness. According to author Goebel [10], the surgery requests was set when the false double patella has complications, depending on the size and nature of that mass that the surgeons should consider arthroscopy surgery or open surgery to remove the mass and send it to the anapathology. The principle is to remove all the masses and correct the complications caused by them. In our opinion, if arthroscopy surgery is possible, it will still be used for arthroscopy surgery for patients to intervene at the minimum incision, avoiding damaging the surrounding parts, shortening the hospitalization time and early rehabilitation training.

In conclusion, this is the second case report of "false double patella" with the cause of the synovial osteochondromatosis in the world and the first case report in Vietnam and Southeast Asia. This status of "false double patella" needs to be distinguished from many other causes such as soft tissue tumors, gout tumor or "congenital double patella". Arthroscopic treatment is the treatment method that is planned because of complications for the patient. After 18 months of follow-up, this patient is now well-traveled, with good knee function and 85/100 points Lysholm Knee Scoring Scale.

## Informed consent

The consent and commitment were signed by the patient.

## References

1. Milants A, De Maeseneer M, De Mey J. Double-layered patella (DLP) in multiple epiphyseal dysplasia (MED). *Journal of the Belgian Society of Radiology*. 2017; 101(1). <https://doi.org/10.5334/jbr-btr.1219> PMID:30039000 PMCid:PMC5854308
2. J. Gasco J, Del Pino JM, Gomar-Sancho F. Double patella. A case of duplication in the coronal plane. *The Journal of bone and joint surgery*. British volume. 1987; 69(4):602-3.

- <https://doi.org/10.1302/0301-620X.69B4.3611165>
3. Kambale T, Iqbal B, Jain A. A case report of synovial chondromatosis of the knee. *Clin Cancer Investig J*. 2015; 4:105-7. <https://doi.org/10.4103/2278-0513.149065>
4. Kukreja S. A Case Report of Synovial Chondromatosis of the Knee Joint arising from the Marginal Synovium. *J Orthop Case Reports*. 2013; 3(1):7-10. <https://doi.org/10.1136/bcr-2013-202186> PMID:24326442 PMCid:PMC3863075
5. Mackenzie H, Gulati V, Tross S. A rare case of a swollen knee due to disseminated synovial chondromatosis: a case report. *Journal of medical case reports*. 2010; 4(1):113. <https://doi.org/10.1186/1752-1947-4-113> PMID:20416049 PMCid:PMC2873448
6. Saupe E. Beitrag zur patella. *Fortschr. Rontgenstr.*. 1921; 28:37-41.
7. Dwidmuthe S, Sharma M. A Case Report of Primary Synovial Chondromatosis with Bilateral Genu Valgum. *J Orthop Case Reports*. 2017; 7(5):92-95.
8. Boyer T, Dorfmann H. Arthroscopy in primary synovial chondromatosis of the hip: description and outcome of treatment. *J Bone Joint Surg Br*. 2008; 90(3):314-8. <https://doi.org/10.1302/0301-620X.90B3.19664> PMID:18310752
9. de Sa D, et al. Arthroscopic surgery for synovial chondromatosis of the hip: a systematic review of rates and predisposing factors for recurrence. *Arthroscopy*. 2014; 30(11):1499-1504.e2. <https://doi.org/10.1016/j.arthro.2014.05.033> PMID:25064754
10. Goebel S, Steinert AF, Barthel T. Surgical management of a double-layered patella: a case report. *Archives of orthopaedic and trauma surgery*. 2009; 129(8):1071-5. <https://doi.org/10.1007/s00402-008-0701-z> PMID:18677496
11. Jingushi S, et al. Transient exposure of fibroblast growth factor-2 induced proliferative but not destructive changes in mouse knee joints. *Connect Tissue Res*. 2006; 47(4):242-8. <https://doi.org/10.1080/03008200600883146> PMID:16987757
12. Kajikawa Y, Arai Y, Takamiya H, Higuchi T, Mori G, Morisaki S, Kubo T. A double patella-like condition secondary to synovial osteochondromatosis", *Sports medicine, arthroscopy, rehabilitation, therapy & technology : SMARTT*. 2012; 4(1):31-31. <https://doi.org/10.1186/1758-2555-4-31> PMID:22943294 PMCid:PMC3494534
13. Lee JB, et al. Arthroscopic treatment of synovial chondromatosis of the hip. *Am J Sports Med*. 2012; 40(6):1412-8. <https://doi.org/10.1177/0363546512445150> PMID:22539535
14. Marchie A, Panuncialman I, McCarthy JC. Efficacy of hip arthroscopy in the management of synovial chondromatosis. *Am J Sports Med*. 2011; 39(1):126-31. <https://doi.org/10.1177/0363546511414014> PMID:21709042
15. Tojyo I, et al. The expression of fibroblast growth factor receptor-3 in synovial osteochondromatosis of the temporomandibular joint. *Arch Oral Biol*. 2004; 49(7):591-4. <https://doi.org/10.1016/j.archoralbio.2003.12.009> PMID:15126141