

Preliminary Result of Arthroscopic Anterior Cruciate Ligament Reconstruction Using Anterior Half of Peroneus Longus Tendon Autograft

Dung Tran Trung^{1,2}, Son Le Manh³, Luan Nguyen Thanh³, Thien Chu Dinh⁴, Toi Chu Dinh⁵*

¹Department of Orthopaedic and Sport Medicine, Saint Paul Hospital, Hanoi, Vietnam; ²Department of Orthopaedic and Neurosurgery, Hanoi Medical University Hospital, Hanoi, Vietnam; ³Department of General Orthopaedic and Trauma, Viet Duc Hospital, Hanoi, Vietnam; ⁴Institute for Research and Development, Duy Tan University, 03 Quang Trung, Danang, Vietnam; ⁵Department of Human and Animal Physiology, Faculty of Biology, Hanoi National University of Education, Hanoi, Vietnam

Abstract

Citation: Trung DT, Manh SL, Nguyen Thanh L, Chu Dinh T, Chu Dinh T. Preliminary Result of Arthroscopic Anterior Cruciate Ligament Reconstruction Using Anterior Half of Peroneus Longus Tendon Autograft. Open Access Maced J Med Sci. <https://doi.org/10.3889/oamjms.2019.390>

Keywords: Anterior cruciate ligament; Anterior half peroneus longus tendon

***Correspondence:** Toi Chu Dinh, Department of Human and Animal Physiology, Faculty of Biology, Hanoi National University of Education, Hanoi, Vietnam. E-mail: chudinhtoi.hnue@gmail.com

Received: 08-Sep-2019; **Revised:** 20-Nov-2019; **Accepted:** 21-Nov-2019; **Online first:** 20-Dec-2019

Copyright: © 2019 Dung Tran Trung, Son Le Manh, Luan Nguyen Thanh, Thien Chu Dinh, Toi Chu Dinh. This is an open-access article distributed under the terms of the Creative Commons Attribution-NonCommercial 4.0 International License (CC BY-NC 4.0)

Funding: This research did not receive any financial support

Competing Interests: The authors have declared that no competing interests exist

BACKGROUND: Arthroscopic anterior cruciate ligament reconstruction is one of the most successful operations in sports medicine. At present, ligament autografts have been the best method due to good histocompatibility, rapid healing, no cross-contamination, and low cost of treatment. However, autografts do not have infinite amount and are also not always feasible. Anterior half of peroneus longus tendon autograft is likely to become a source of autograft with many advantages. This study aims to evaluate the clinical outcomes of arthroscopic anterior cruciate ligament reconstruction using anterior half of peroneus longus tendon autograft (AHPLT).

AIM: To evaluate the initial outcome of ACL reconstruction arthroscopy by anterior half of peroneus longus tendon.

METHODS: This is a prospective non-controlled case series.

RESULTS: A prospective study on 30 patients (from 9 / 2016 to 01 / 2019) had both ACL and MCL injury who had operated ACL reconstruction using anterior half of peroneus longus tendon autograft (AHPLT) at Department of General Orthopaedic and Trauma, Viet Duc hospital. Our outcome: the year average 35.4 ys, the rate of ACL rupture combined with meniscus injury was 40%. The average diameter AHPLT autograft is 7.0 mm. The function Lysholm scores improved from 59 to 94.27 postoperative 6 months. No difference between the AOFAS scale of preoperative and postoperative.

CONCLUSION: Peroneus longus tendon is recommended to be a safe and practical autograft resource for arthroscopic anterior cruciate ligament reconstruction.

Introduction

Sport injury and vehicle collision are among the most striking problems. In these circumstances, ligaments are the main suffered organ. The graft used for reconstruction surgery requires good biomechanics, rapid healing and easy ability to ligate from the body. Many different kinds of graft have been successfully used in clinical settings [1], [2]. Research about biomechanical features of anterior half of peroneus longus tendon auto-graft began in 1977, mostly for knee ligament reconstruction in general and ACL reconstruction in specific for preserving the

function of peroneus longus tendon [3].

In 2012, Jinzhong Zhao did a research about biomechanical features, application of anterior half of peroneus longus and its safety and effectiveness. This study compared the ankle function before and after operation of ligament reconstruction using AOFAS score [4]. It showed that AOFAS score pre- and post-operation was 97.4 ± 2.0 and 97.2 ± 1.6 respectively ($p = 0.85$). Author's conclusion was that it is a good autograft by advantages in bearing force, safety and risk.

Hong-Bin Cao (2012) treated ACL injury by using AHPLT tendons and assessed the clinical

results of ankles function. There were 35 patients suffering from injury requiring surgery following up from January 2006 to December 2009, average age 31.8 (21 to 56 years). Postoperative evaluation includes clinical assessment, Lysholm score, KT 3000 and AOFAS scale. Mean follow-up evaluation time was 55 months of follow-up. Lysholm score is classified as very good in 25 cases, quite good in 3 and poor in 1 case. AOFAS scores are not statistically different ($p > 0.05$). The author concluded that AHPLT is good enough to apply in ACL regeneration and did not affect the ankle joint function [5].

In the study done by Nhan TT in 2016, the research conducted over 61 patients with ACL reconstruction using AHPLT showed that post-op Lysholm score is classified as very good and good in 93.44% of patients (57 / 61 patients) [6]. In another done by Vinh PQ in 2017, the research recruited 150 patients over 18 years of age treated by arthroscopic ACL reconstruction. Results showed that Lysholm score is classified as good in 84.67% of patients and the function of ankle joint (AOFAS scale) before surgery was 97.13 ± 1.92 [7].

These studies demonstrated that the impact of taking AHPLT in ankle was not significant. At Viet Duc Hospital, research about AHPLT application in arthroscopic ACL reconstruction has been conducted, but no research has evaluated the effectiveness of AHPLT in arthroscopic ACL reconstruction. The patients in our research are both ACL and MCL injury. We do not use Hamstring tendon as standard technique for reconstruction because of adding more medial instability of the knee. Therefore, we conducted this study with two objectives [1]. Clinical symptoms and imaging of patients with ACL injury, and [2]. Evaluate the results of arthroscopic ACL reconstruction by AHPLT.

Material and Method

Thirty patients were diagnosed ACL injury with or without meniscus injury combined with mild and moderate MCL injury. All the patients were treated with conservation of MCL and arthroscopy ACL reconstruction by anterior half of peroneus longus tendon auto-graft in Vietduc hospital from September, 2016 to January, 2019 with more than 6 months follow-up.

Subjects

Recruitment criteria: The patient has ACL injury with or without meniscus injury with mild and moderate MCL injury based on MRI and clinical features. The patients agree to take part in the research.

Exclusion criteria: Simple ACL injury or PCL injury or external ligament. Patients with pathological injury of ankle joint and common fibular nerve.

Sample size and place

Thirty patients are appropriate to those criteria. We conducted the prospective non-controlled case series study from September, 2016 to January, 2019 at Department of General orthopedic and Trauma, Viet duc hospital.

Surgical technique

The endoscopic surgical instrument ACL reconstruction by anterior half of peroneus longus tendon, fixed the graft by Tightrope with all-inside technique. Exam the patient before surgery: (1) The patients selected for the study will be conducted for clinical examination and follow-up medical records (sample medical records). Record preoperative variables such as Lysholm score, IKDC score, AOFAS score; and (2) Surgical procedure for ACL reconstruction using anterior half of peroneus longus tendon auto-graft through arthroscopy including 4 steps: Step 1: Arthroscopy check the meniscus, treat the meniscus if injury available. Then reconstruct the ACL; Step 2: Take the graft: Skin incision 2-3 cm along the back of fibula and 2cm above the lateral malleolus, the peroneus longus tendon just below it. Separate the peroneus longus tendon at the farthest possible location without damage the upper retinaculum. Split the anterior half and posterior half of peroneus longus tendon and cut the anterior half. Using the surgical instrument to take the graft (Figure 1); Step 3: Preparing the graft: Four-fold the graft. Using tendon frames to stretch the graft with force of about 5 kg (50 – 60 N) for 10 minutes. Put 2 Tight-rope and sew 2 sides of graft on the piece about 2 cm. Measure the diameter and the length of the graft; and Step 4: Take the graft through endoscopy: Through endoscopy drilling tunnel tibial plateau and thigh the diameter of graft. Fix the graft to the tibial and thigh tunnel by Tight-rope. Check again by Lachman test. Maximum stretching the knee to assess the ligament. The post operation rehabilitation has been done by following Karistinos A. and James A. Walker [8]:

- Phrase 1: 6 weeks after surgery.
- + Patella glides and tilts
- + Decrease swelling
- + Quad sets
- + Straight leg raise and short arc quads $90^\circ - 40^\circ$
- + Hamstring PRE and move to aquatic therapy after wound is completely healed or a protective waterproof dressing is available
- + Proprioception exercises and prone terminal

knee extensions

- Phrase 2: from 7 weeks to 10 weeks after surgery

- + Bicycle with resistance
- + Leg press, progressive resistive exercises
- + 0°-30° leg extension exercises
- + Increase flexion as fast as possible

-Phrase 3: from 11 weeks to 16 weeks after surgery

- + Full PREs
- + Hamstrings and quads
- + Stair stepper
- + Patient may golf and hike

-Phrase 4: from 17 weeks to 24 weeks after surgery: Transition to Sport and Work

- + No contact or competition
- + Full weight lifting program
- + Advanced balance exercises
- + Begin progressive running program

-Phrase 5: from 6 months to 9 months: Return to play

- + Run up or down stairs
- + Progress cutting, jumping, and sport-specific drills
- + Transition to sport
- + Quad strength and Hamstring strength must be 90% of opposite side

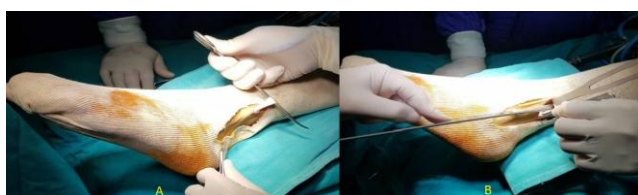

Figure 1: Skin incision to approach AHPLT tendon A) and Tendon stripping B)

Variable research and study tool

Genders, location of knee, and time of injury, clinical features: knee pain, knee instability, Lach-man test, Pivot shift test, Lysholm score, AOFAS score, IKDC score. We used optimal MR360 1.5T MRI scanning system, made in Florida, USA, November 2009, serial 037255, thin cut 1 mm, 256 slice and X-ray machine. Data were analysed by using SPSS software version 22. Frequency and percentage were used to show quantitative variable and mean and the standard deviation was used to show the quantitative variables.

Results

General characteristics

The average age of research group is 35.4 years old, of which the smallest is 18 years old, the oldest is 51 years old. There are 19 male patients accounting for 63.3%, higher than female with 11 patients occupy 36.7%. The most common cause is sport injury in 12 cases accounting for 40%, 12 cases of daily activities accident accounting for 40%, traffic accident occupy 20% (Figure 2).

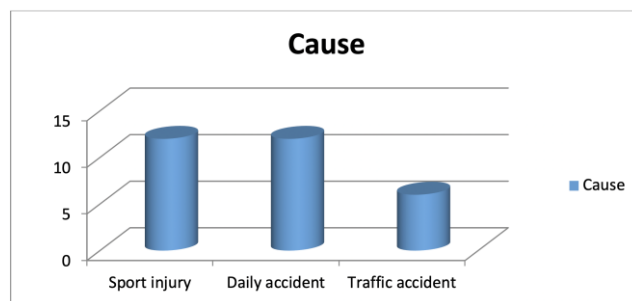


Figure 2: The cause of ACL injury

Common clinical symptoms are knee pain when strongly activities, loosen knee in daily activities, most of the patients have problems when going up and down the stairs. Clinical symptoms are valuable for preoperative diagnosis including Lachman sign, anterior drawer test and Pivot shift test with 82.3%, 100% and 86.7% sensitivity, respectively.

The average length of anterior half of peroneus longus tendon graft is 60 mm, the shortest is 60 mm and the longest is 65 mm. The graft mainly four-fold or three-fold to achieve the shortest length approximately 60 mm. We use All-in-side technique with Tightrope 2 head fixed. The average diameter of the research group is 7.0 mm, the smallest is 6.0 mm, the largest is 8.5 mm.

Through many studies, we found that the average of ACL size ranges from 7-12 mm, in the study group, the diameter of tendon mainly greater than 7mm (22 over 30 patients), just 4 patients were from 6.5 to 7mm. Graft size in ACL reconstruction is an important factor. Magnussen et al., [9] considered 7mm as the minimum graft size to avoid the revision surgery. In a study of 256 patients with hamstring autograft ACL reconstruction, grafts larger than 8.5 mm had a 1.7% revision rate, and grafts between 8.0 and 8.5 mm and 7.5 and 8.0 mm had a revision rate of 6.5% and 6.2%, respectively. In the same study, grafts that ranged from 7.0 to 7.5 mm and 7 mm or less had a revision rate of 11.3% and 33%, respectively.

Preoperative determination of hamstring graft size is challenging. Magnetic resonance imaging and ultrasound scanning have been used to predict hamstring graft sizes with moderate success

[10]. Anthropometric data collection has also been used with more success in the literature [11] though the confidence intervals remain too large for an accurate clinical use.

Clinical post-operative outcome

The stability of knee was evaluated through the results of Lachman sign after surgery: the rate of negative is 90%; level 1 is 10% and no longer level 2,3 (Table 1). Compared to the Lachman before surgery, it was 76.7% in level 2 and level 3 was seen 16.7%.

Table 1: Lachman sign after surgery

| Lachman | Negative | Level 1 | Level 2 | Level 3 | Total |
|------------|----------|---------|---------|---------|-------|
| n | 27 | 3 | 0 | 0 | 30 |
| Percentage | 90% | 10% | 0% | 0% | 100% |

The stability of knee was evaluated through the results of anterior drawer test postoperation: the rate of negative is 96.7%; level 1 is 3.3% and no longer level 2,3. Compared to the Lachman before surgery, it was 96.7 positive (Table 2).

Table 2: Anterior drawer test after surgery

| Anterior drawer test | Negative | Level 1 | Level 2 | Level 3 | Total |
|----------------------|----------|---------|---------|---------|-------|
| N | 29 | 1 | 0 | 0 | 30 |
| Percentage | 96.7% | 3.3% | 0% | 0% | 100% |

These are two methods to determine the displacement of anterior tibial plateau compared with femoral condyle or the instability of knee joint. There was a significant improvement before and after surgery.

The percentage of stability knee in our research higher or lower in comparison with other authors may due to the rate of meniscus injury when ACL reconstruction. Because cutting the meniscus also contributes to the instability of knee joint after surgery.

The results of knee recovery following Pivot Shift test after 6 months: negative is 93.3%; level 1 is 6.7%; no longer level 2 and 3 (Table 3). Compared to before surgery, Pivot Shift test: there is 1 patient accounting for 3.3% at level 1; 25 patients occupy 83.3% at level 2; 13.3% at level 3.

Table 3: Pivot Shift test after surgery

| Pivot Shift | Negative | Level 1 | Level 2 | Level 3 | Total |
|-------------|----------|---------|---------|---------|-------|
| n | 28 | 2 | 0 | 0 | 30 |
| Percentage | 93.3% | 6.7% | 0% | 0% | 100% |

This shows a significant improvement before and after surgery.

Twenty-five patients (86.7%) achieved good outcome, 5 patients (13.3%) are medium and no patients achieved bad results (Table 4). The average Lysholm score after surgery of the study group is 95.13 ± 3.98 (highest is 99 and the smallest is 80) compared to Lysholm before surgery is 59 (highest is

69 score, smallest is 56 with statistically significance difference.

Table 4: Lysholm score after surgery

| Lysholm score | Good | Mediun | Bad | Total |
|---------------|-------|--------|-----|-------|
| Time | | | | |
| ≤ 6 months | 10 | 2 | 0 | 12 |
| 7 - 11 months | 8 | 1 | 0 | 9 |
| ≥ 12 months | 7 | 2 | 0 | 9 |
| Total | 25 | 5 | 0 | 30 |
| Rate % | 86.7% | 13.3% | 0% | 100% |

In our research, there is no case of infection or deterioration of strength first ray plantar flexion or foot eversion.

Ankle joint function after surgery

The function of ankle joint following AOFAS score before surgery is 97.3 ± 1.67 and after surgery is 97.3 ± 1.54 (smallest is 93 and the highest is 100 scoring). There was no complaint about the weakness of the ankle joint after surgery from the patients in the study. No vascular neurological complications were noted and no cases of ACL rupture recurrence.

Discussion

The average age of the researched patients is 35.4 ± 8.8 years, similar to the average age in previous studies by Nam Anh Ha Tang [12] (32.1 years), and Muoi Le Van [13] (28.73 years). ACL injury can be encountered at all ages, in this study, a large proportion of the patients is in the age group 31 to 40, accounts for 56.7%. This is the age group in which patients usually participate in highly combative sports.

A majority of our patients is male, accounts for 63.3%, or 1.7 times the number of female patients. This result is consistent with studies by other authors, for example, Hoang Anh Dang [14] reported 85.1% of the patients were male. This high proportion can be explained by the tendency of male patients in participating in intense activities, and their need for healthy knees to resume participating in such activities, thus more male patients choose surgery. The most common cause of for ACL injury in our study group is sport injury, accounts for 40%.

The average length of our graft is 60 ± 0.8 (60 – 65) mm, of Khanh Nguyen Manh [15] is 60.3 ± 0.5 , and of Nam Anh Ha Tang [12] is 67 ± 2.04 mm. The tendon length in most studies ranged from 61 mm to 69 mm.

The average diameter of our graft is 7.0 ± 0.8 mm, ranging from 6.0 mm to 8.5 mm, most of the grafts (66.7%) have a diameter of 7.0 to 7.5 mm, 16.6% of the grafts have a diameter of 7.5 to 8.0 mm.

Vinh Pham Quang [7] reported an average diameter of 7.5 ± 0.57 mm. Our diameter is smaller because we included more female patients, and our female patients have smaller tendons. Khanh Nguyen Manh [15] reported an average graft diameter of 7.6 ± 0.7 mm. In comparison with other technique, for example, a study by Hoang Anh Dang [14] using semitendinosus-gracilis graft with a diameter of 7.25 mm, our grafts were much larger.

We assessed the stability of the knees using Lachman and Pivot-Shift tests. Lachman test assesses the level of forward movement of the tibial plateau and has high sensitivity. Among 30 patients operated, 27 patients (90%) had a negative Lachman test, only 3 patients had a positive grade 1 result. This result is consistent with Khanh Nguyen Manh [15] who reported a 92.7% negative rate. Pivot-Shift test is used to assess rotational stability of the knee. In our study 93.3% of the patients had a negative result for this test, while 6.7% of the patients had a positive grade 1 result. Khanh Manh Nguyen [15] reported a 100% negative rate, while this rate, as reported by Hoang Anh Dang [14] was 97.6%. Average post-operative Lysholm Knee Score after 6 month for all-inside technique by Nam Anh Ha Tang [12] was 96.9 points, Khanh Nguyen Manh [15] was 96.5 points and Mohammad Mahdi Omidian [16] was 91.5 points. Average AOFAS score at 6 months after the operation was 97.2 ± 1.6 points, ranging from 93 to 100. Among that, very good and good results accounted for 96.7%, moderate result accounted for 3.3% and there was no case with bad result. One patient had an AOFAS score of 88 points because of unadequate postoperative physical therapy for their ankle. The increase in preoperative and postoperative AOFAS score is statistically significant.

Chayanin Angthong (2015) assessed biomechanical and clinical features of the ankle after using peroneus longus graft to reconstruct the ACL. The average follow-up time was 12.8 months. Average preoperative AOFAS score was 97.7 ± 1.1 points and after 13 months of follow-up, the postoperative score was 95.4 ± 12 points ($p = 0.09$). The author concluded that peroneus longus graft could be selected if more of the graft were needed to reconstruct ACL [3]. The average AOFAS score by Pham Quang Vinh [7] was 97.37 ± 1.67 before the operation, and the postoperative score was 97.3 ± 1.54 ($p = 0.88$).

Sholahuddin Rhatomy et al., (2019) [17] conducted a research on patients who suffered isolated ACL injury were enrolled and underwent isolated single bundle ACL reconstruction using peroneus longus autograft at pre-operative and 2-years after surgery. Graft diameter was measured intraoperative. Donor site morbidities were assessed with thigh circumference measurement and ankle scoring using AOFAS and FADI. Peroneus longus graft diameter was 8.38 ± 0.68 mm. There was significant difference between pre and 2-years post-

operative functional score in IKDC, Lysholm score. Mean of AOFAS was 98.93 ± 3.10 and FADI was 99.79 ± 0.59 .

Khajotia and Shakti Chauhan (2018) [18] conducted a research with 25 patients, ranging 18-42 years to evaluate the functional outcome of arthroscopic reconstruction of ACL tear using triple layered PLT autograft and to study its effect on ankle stability. IKDC score was normal or near normal in 21 patients and only 4 patients were rate as abnormal or severely abnormal. Mean IKDC Score was 83.53. Stability of the ACL was assessed using the Lachman test: normal in 18 cases (72%), 1+ laxity in 5 cases (20%), 2+ and 3+ in 1 case (4%) each. Pivot shift was negative in 15 cases (60%), Pivot glide was seen in 9 cases (36%) and gross pivot shift was seen in 1 patient. Partial meniscectomy of the medial meniscus was performed in 5 patients. No patient experienced ankle dysfunction however 2 patients had pressure pain in the region of the graft harvest.

Fu-Dong Shi et al., (2017) [19] utilized peroneus longus tendon as an autograft for ACL reconstruction of patients with ACL rupture and grade III MCL injury. Thirty-eight patients with acute ACL ruptures and grade III MCL injuries were treated with ACL reconstruction with a doubled autologous PLT or quadrupled autologous HT. Knee stability and function was evaluated clinically with the Lachman test and KT-2000 arthometer as well as subjectively with functional scores. Effects on the donor ankle were evaluated by biomechanical testing. For the results of subjective index appraisal at 6 months postoperatively, Lysholm scores between group A (94 ± 6.02) and group B (95 ± 2.35), nor was there a statistical difference of IKDC knee functional score (group A: 89.45 ± 2.89 , group B: 90.12 ± 4.56). For the results of ankle functional testing at 12 and 24 months, there were no significant differences in ankle dorsiflexion strength preoperatively (80.92 ± 0.26 N) and postoperatively (80.00 ± 0.57 N at 12 months and 81.46 ± 0.48 N at 24 months postoperatively) of the PLT resected donor ankle, and no marked differences in ankle plantar flexion strength preoperatively (147.96 ± 0.38 N) and postoperatively (147.76 ± 0.25 N at 12 months and 150.22 ± 0.35 N) of the donor ankle.

In conclusion, through the evaluation of the surgery results of 30 patients with ACL rupture were arthroscopic surgery ACL reconstructions, anterior half of peroneus longus tendon may be an alternative, complementing the source of the autologous graft in ACL reconstruction.

Ethical approval

This study is approved by the ethics committee of Hanoi Medical University in Vietnam

Informed consent

The consent and commitment were signed by the patients in the study

References

1. West RV, Harner CD. Graft selection in anterior cruciate ligament reconstruction. *The Journal of the American Academy of Orthopaedic Surgeons*. 2005; 13(3):197-207. <https://doi.org/10.5435/00124635-200505000-00006> PMID:15938608
2. Otis JC. Peroneus Brevis is a More Effective Evertor than Peroneus Longus. *Foot and Ankle International*. 2004; 25(4):242-6. <https://doi.org/10.1177/107110070402500408> PMID:15132932
3. Angthong C, Chernchujit B, Apivatgaroon A, Chaijenkij K, Nualon P, Suchao-in K. The Anterior Cruciate Ligament Reconstruction with the Peroneus Longus Tendon: A Biomechanical and Clinical Evaluation of the Donor Ankle Morbidity. *Journal of the Medical Association of Thailand = Chotmaihet thangphaet*. 2015; 98:555-60.
4. Zhao J, Huangfu X. The biomechanical and clinical application of using the anterior half of the peroneus longus tendon as an autograft source. *The American journal of sports medicine*. 2012; 40(3):662-71. <https://doi.org/10.1177/0363546511428782> PMID:22174343
5. Cao HB, Liang J, Xin JY. [Treatment of anterior cruciate ligament injury with peroneus longus tendon]. *Zhonghua yi xue za zhi*. 2012; 92(35):2460-2.
6. Trong NT, Hoang LP, Duong TM. " Evaluation of ACL reconstruction arthroscopy by peroneus longus tendon. 121 Military Hospital. 2016.
7. Quang VP. Anatomical and mechanical feature of peroneus longus tendon - applying ACL reconstruction: Ho Chi Minh medical university; 2017.
8. Paulos L.E KA, Walker J.A. 'Criteria' - Based Rehabilitation of surgically reconstructed and non-surgically treated Anterior Cruciate Ligament injuries. . fourth ed ed. Insall & Scott Surgery of the knee: Churchill Living Stone Elsevier; 2006.
9. Magnussen RA, Lawrence JT, West RL, Toth AP, Taylor DC, Garrett WE. Graft size and patient age are predictors of early revision after anterior cruciate ligament reconstruction with hamstring autograft. *Arthroscopy : the journal of arthroscopic & related surgery : official publication of the Arthroscopy Association of North America and the International Arthroscopy Association*. 2012; 28(4):526-31. <https://doi.org/10.1016/j.arthro.2011.11.024> PMID:22305299
10. Conte EJ, Hyatt AE, Gatt Jr CJ, Dhawan A. Hamstring autograft size can be predicted and is a potential risk factor for anterior cruciate ligament reconstruction failure. *Arthroscopy : the journal of arthroscopic & related surgery : official publication of the Arthroscopy Association of North America and the International Arthroscopy Association*. 2014; 30(7):882-90. <https://doi.org/10.1016/j.arthro.2014.03.028> PMID:24951356
11. Ho SW, Tan TJ, Lee KT. Role of anthropometric data in the prediction of 4-stranded hamstring graft size in anterior cruciate ligament reconstruction. *Acta Orthop Belg*. 2016; (82):72-7.
12. Tang NAH. Evaluation of ACL reconstruction arthroscopy using Hamstring by all-inside technique Vietnam Orthopedic Association Journal 2013:109-14.
13. Van ML. Evaluation of ACL reconstruction by all-inside technique in Da Nang hospital. *Vietnam Orthopedic Association Journal* 2015:105-10.
14. Dang HA. Research on ACL reconstruction arthroscopy by Hamstring tendon, 2009.
15. Nguyen KM. Preliminary results of ACL reconstruction with all-inside technique. *Vietnam Medical Journal*. 2015; 2:136-40.
16. Omidian MM, Sarzaeem MM, Kazemian GH. Arthroscopic Anterior Cruciate Ligament Reconstruction Using Hamstring Tendon Graft: Comparison of All-Inside and Outside-in Techniques. *J Orthop Spine Trauma*. 2016; 2(1).
17. Rhatomy S, Hartoko L, Setyawan R, Soekarno NR, Zainal Asikin AI, Pridianto D, et al. Single bundle ACL reconstruction with peroneus longus tendon graft: 2-years follow-up. *Journal of Clinical Orthopaedics and Trauma*. 2019. <https://doi.org/10.1016/j.jcot.2019.09.004>
18. Khajotia BL, Chauhan S, Sethia R, Chopra BL. Functional outcome of arthroscopic reconstruction of anterior cruciate ligament tear using peroneus longus tendon autograft. *International Journal of Research in Orthopaedics*. 2018; 4(6):898. <https://doi.org/10.18203/issn.2455-4510.IntJResOrthop20184382>
19. Shi FD, Hess DE, Zuo JZ, Liu SJ, Wang XC, Zhang Y, et al. Peroneus Longus Tendon Autograft is a Safe and Effective Alternative for Anterior Cruciate Ligament Reconstruction. *The journal of knee surgery*. 2019; 32(8):804-11. <https://doi.org/10.1055/s-0038-1669951> PMID:30206913