

Surgical Treatment for Parathyroid Adenoma: A Case Report

Prihantono Prihantono^{1*}, Emmy Palinggi², Haryasena Haryasena¹, William Hamdani¹, I Made Christian Binékada²

¹Department of Surgery, Faculty of Medicine, Hasanuddin University, Makassar, Indonesia; ²Department of Surgery, Faculty of Medicine, Haluoleo University, Kendari, Indonesia

Abstract

Citation: Prihantono P, Palinggi E, Haryasena H, Hamdani W, Binékada IMC. Surgical Treatment for Parathyroid Adenoma: A Case Report. Open Access Maced J Med Sci. 2019 Aug 15; 7(15):2497-2501. <https://doi.org/10.3889/oamjms.2019.418>

Keywords: Parathyroid adenoma; Hyperparathyroidism; Hypercalcemia; Fatigue; Fractures

***Correspondence:** Prihantono Prihantono, Department of Surgery, Faculty of Medicine, Hasanuddin University, Makassar, Indonesia. E-mail: prihantono.md@gmail.com

Received: 24-Apr-2019; **Revised:** 11-Jul-2019; **Accepted:** 15-Jul-2019; **Online first:** 13-Aug-2019

Copyright: © 2019 Prihantono Prihantono, Emmy Palinggi, Haryasena Haryasena, William Hamdani, I Made Christian Binékada. This is an open-access article distributed under the terms of the Creative Commons Attribution-NonCommercial 4.0 International License (CC BY-NC 4.0)

Funding: This research did not receive any financial support

Competing Interests: The authors have declared that no competing interests exist

BACKGROUND: Parathyroid adenoma is a rare disease. This article aimed to present the classic symptoms, diagnosis, and management of parathyroid adenoma.

CASE REPORT: We report the case of a 24-year-old Asian woman with a several-month-long history of prolonged fatigue, bone, and joint pain. The patient was admitted to our hospital with multiple fractures without significant trauma. Physical examination revealed no palpable masses in the neck. The bone survey showed multiple fractures and osteoporosis of the humerus, clavicle, femur, and lumbar vertebrae. The laboratory workup showed a significantly elevated parathyroid hormone (PTH) level of 1,276 pg/ml (reference range: 10-55 pg/ml) and hypercalcemia, at 11.3 mg/dl (reference range: 8.5-10.5 mg/dl). MRI revealed enlargement of the left inferior parathyroid gland. The patient was diagnosed with a parathyroid gland tumour. Surgical resection was performed, and histopathology revealed parathyroid adenoma. The clinical manifestations and PTH and calcium levels gradually decreased to normal after the surgery. At the two-year follow-up, there was no recurrence of the disease. The patient has resumed her daily life as a farmer.

CONCLUSIONS: Parathyroid adenoma has an excellent prognosis with surgical treatment.

Introduction

The parathyroid endocrine glands play a significant role in calcium homeostasis [1]. Cases of parathyroid adenoma are rare. Parathyroid adenoma causes excessive the autonomic formation and release of parathyroid hormone (PTH), called primary hyperparathyroidism. Primary hyperparathyroidism could be caused by solitary adenomas (80-85%), hyperplasia (10%), multiple adenomas (2%), and carcinomas (2-5%) [1], [2]. The prevalence of primary hyperparathyroidism is approximately 1:1000 in the United States. This condition occurs in women and men at a ratio of approximately 2:1. In Indonesia, there are about 1,000 cases of hyperparathyroidism every year. Women aged 50 years and over have twice as high a risk of this condition than men [2], [3].

Excess PTH secretion in hyperparathyroidism affects hypercalcemia, which directly influences receptors in the bones, intestinal tract, and kidneys.

Physiologically, PTH secretion is inhibited by high serum calcium ion levels. This mechanism is inactive in adenoma, as PTH hypersecretion occurs at the same time as hypercalcemia. Calcium resorption from the bones and increased absorption from the intestines have a direct effect on the PTH level [2], [4].

Most hyperparathyroidism patients are asymptomatic. The primary manifestation of hyperparathyroidism is mainly in the bones and kidneys. Osteoporosis and bone fractures are the most common symptoms of primary hyperthyroidism. Kidney abnormalities are mostly due to calcium deposits in the renal parenchyma or recurrent nephrolithiasis. Nephrolithiasis also results in decreased kidney function and phosphate retention [2], [5].

We report a case of parathyroid adenoma diagnosed late due to the difficulties of diagnosis in rural areas and the surgical management of the case.

Case Report

A 24-year-old Asian woman complaining of prolonged fatigue and bone and joint pain for ten months prior came to the hospital. Previous treatment at the Sidrap Healthcare Centre (rural healthcare centre approximately 250 km from the capital province of Makassar) for several months yielded no improvements.

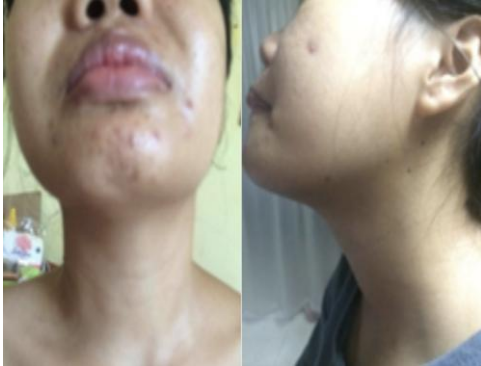

Figure 1: Appearance of the head and neck was within normal limits, no palpable neck masses

One month before admission to the hospital, the patient was walking and suddenly fell into a sitting position; after the incident, she had difficulty moving her lower limbs. Then, the patient was referred to Wahidin Sudirohusodo General Hospital, the top referral hospital for East Indonesia, due to multiple fractures. She had no history of kidney stones and no family history of endocrine neoplasia. The results of a physical examination of the head and neck were within the normal limits, and no palpable neck masses were detected (Figure 1).

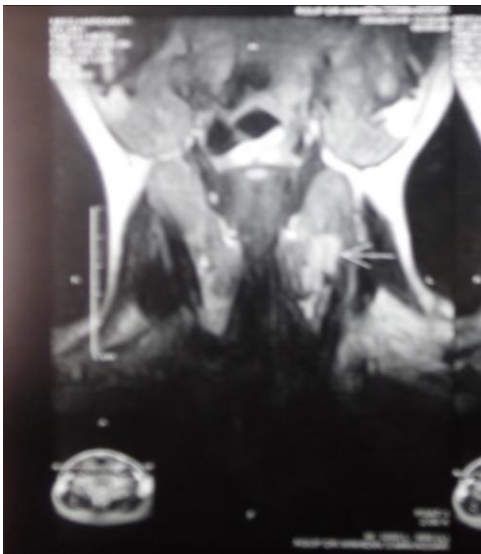


Figure 2: MRI showing left parathyroid lobe mass

Further evaluation revealed fractures of the left humerus and left femur. The bone survey showed

multiple fractures and osteoporosis of the humerus (Figure 3), lumbar vertebrae (Figure 4), femur (Figure 5), and clavicle (Figure 6).

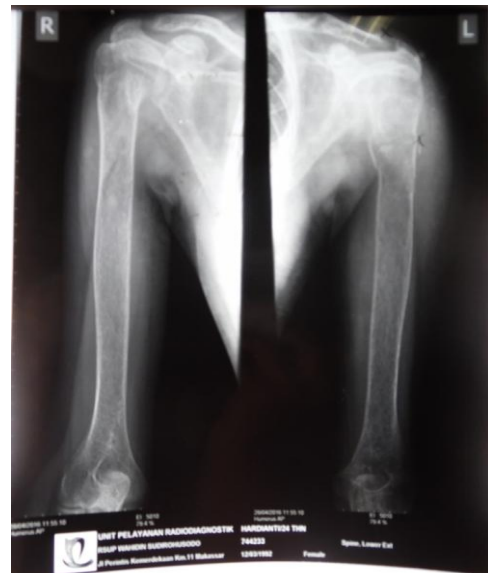


Figure 3: Humeral X-ray showing a transverse fracture of the left humeral bone, fracture of the left clavicle, and osteoporosis

The laboratory workup showed a significantly elevated parathyroid hormone (PTH) level of 1,276 pg/ml (reference range: 10-55 pg/mL) and hypercalcemia, at 11.3 mg/dl (reference range: 8.5-10.5 mg/dL). The vitamin D level was 11.2 ng/mL (30-100 ng/mL).

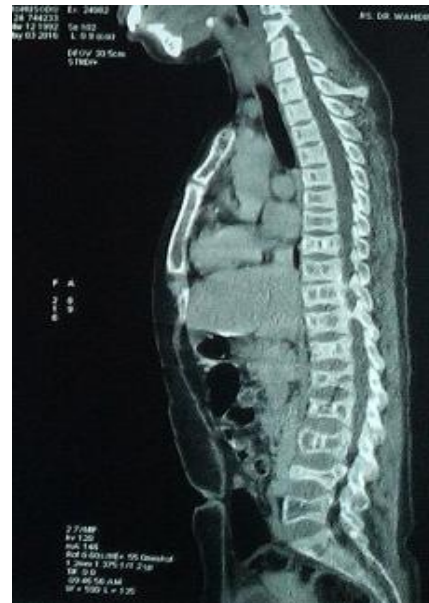


Figure 4: CT scan of lumbar vertebrae showing compression fractures of L1-L5 vertebrae

The abdominal ultrasound results were within the normal limits. Further examination by MRI identified a left parathyroid lobe mass, 1.6 x 0.8 cm, suggestive of adenoma (Figure 2). The patient was diagnosed with a parathyroid gland tumour.

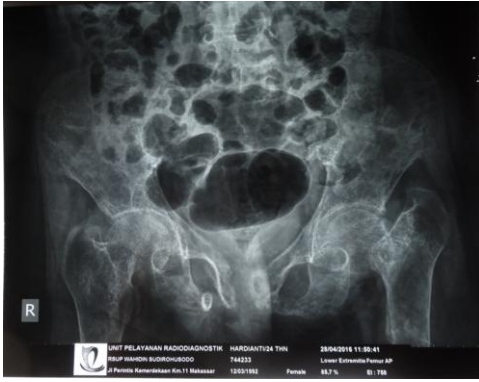

Figure 5: Pelvic X-ray showing the left femoral column fracture. Inferior ramus pubic bone fracture and osteoporosis

Surgical resection was performed using a collar incision, and the tumour was found to originate from the left lower parathyroid gland, with no infiltration into the surrounding structures (Figure 7).

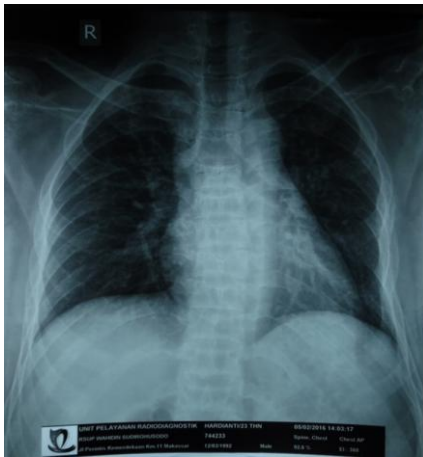


Figure 6: Left clavicle fracture and osteoporosis

Grossly, the surgical specimen was 0.9 x 0.9 x 0.8 cm (Figure 7). The tumour was excised and sent for cryosectioning, which revealed parathyroid adenoma. Histopathology confirmed parathyroid adenoma (Figure 8).

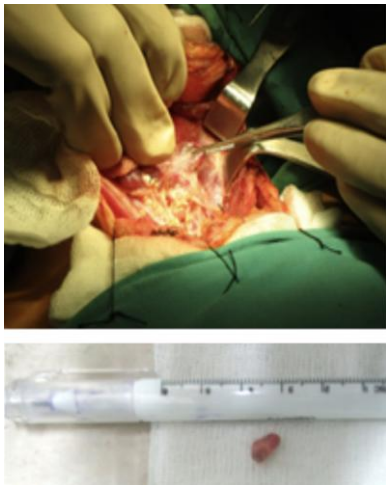


Figure 7: Intraoperative view of the parathyroid gland and specimen

The clinical manifestations and PTH and calcium levels gradually returned to normal postoperatively, as shown in Table 1. At the two-year follow-up, there were no signs or symptoms of recurrence (Figure 9). The patient has resumed her daily life as a farmer.

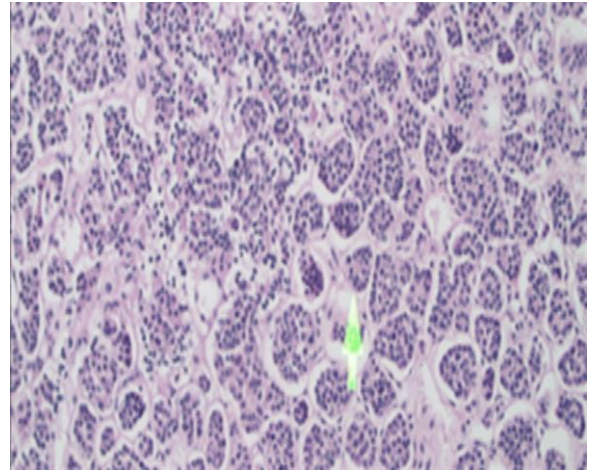


Figure 8: Histopathology found round core cells that were relatively small and monotonous and arranged in a follicular manner with little connective septal tissue. Impression: Parathyroid adenoma

Discussion

Parathyroid tumours are generally not visible or palpable clinically. The clinical symptoms of these patients are more often associated with the manifestation of hypercalcemia [1], [2]. In this case, the patient did not complain about the pain or enlargement of glands in the neck. Palpable neck masses can be found in cases of parathyroid cancer [6].

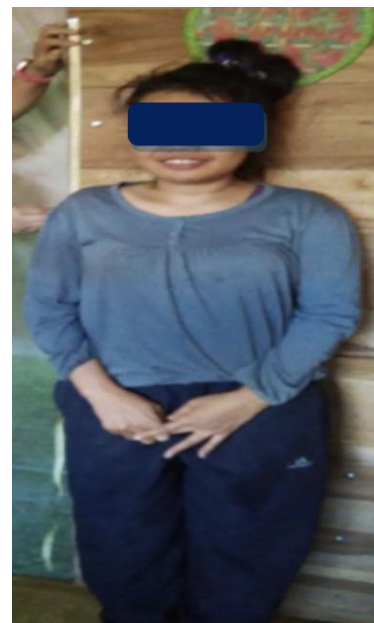

Figure 9: Follow up on 29/8/2018

Calcium affects almost all functions of the organ systems. Manifestations of hypercalcemia are very diverse [5], [6]. The classic pentad of hypercalcemia symptoms is kidney stones, painful bones, abdominal groans, psychic moans, and fatigue overtones [5], [6]. Symptoms of early hypercalcemia are often undiagnosed, especially in developing countries, in which limited laboratory facilities are available [5], [6]. Reduced bone mineral density causing osteopenia, osteoporosis, and fractures is a frequent complication in late-diagnosed hypercalcemia [6], [7].

Table 1: Laboratory analyses before and after the operation

	Baseline data	Data after the treatment	Reference value
PTH	1,276 pg/ml	95.47 pg/ml	10-55 pg/ml
Calcium	11.3 mg/dl	10.9 mg/dl	8.5-10.5 mg/dl
Vitamin D	11.2 ng/ml	15.4 ng/ml	30-100 ng/ml
Procalcitonin	0.16 ng/ml	0.15 ng/ml	< 0.05 ng/ml
FT4	1.10 ng/dl	0.96 ng/ml	0.932-1.71 ng/dl
TSH	0.57 mIU/ml	0.92 mIU/ml	0.270-4.20 mIU/ml

Neurological disorders and multiple fractures are manifestations of primary hyperparathyroidism [2], [4]. In such cases, the patient may frequently consult with neurologists complaining of fatigue overtones, bone and joint pain, osteopenia, and osteoporosis. Numerous fractures in the patient can be diagnosed as a neurological disorder. Other symptoms can include muscle weakness. In some studies, muscle biopsies showed that the cause of muscle weakness was neuropathy, not myopathy [8], [9].

The diagnosis of parathyroid adenoma is based on clinical symptoms confirmed by laboratory findings [10]. Significant laboratory findings are increased calcium and parathyroid hormone levels. There can be an inconsistency in the laboratory results, in which there is an increase in the PTH level, an increase in the calcium level with hypophosphatemia, and an increase in urinary calcium excretion, indicating impaired calcium homeostasis in the body [11], [12]. Patients with PHPT show decreased serum phosphate (50%) and increased calcium concentrations in urine over 24 hours (60%).

Approximately 80% of cases result in mild hyperchloremic metabolic acidosis. Elevated levels of alkaline phosphatase can be found in 10% of cases, along with complications related to bone disease. A serum and urine protein electrophoresis examination can be conducted to eliminate the possibility of multiple myeloma [13], [14].

In some cases, PHPT could also manifest normocalcemic conditions due to a vitamin D deficiency, low serum albumin levels, excessive hydration, a high-phosphate diet, and low calcium levels in the normal range [13], [14]. In such cases, the laboratory results show concurrent levels of calcium and parathyroid hormone (PTH), with normal levels of FT4 and TSH, normal kidney function, and no signs of infection. Extreme increases in the parathyroid hormone level compared with the level of

hypercalcemia raise suspicion of abnormalities in the parathyroid gland, which can be confirmed by radiological examination results.

Cases of hypercalcemia or PHPT with a vitamin D deficiency, determined by routine X-ray examinations of the hands and skull, could reveal osteitis fibrosa cystica, but this condition is rare. BMD examination with dual-energy absorptiometry could reveal bone conditions. Ultrasonography of the abdomen could detect stones in the kidneys or biliary tract [14], [15]. The process of locating the parathyroid glands through radiological examinations can be divided into non-invasive and invasive methods. Non-invasive methods include ultrasonography, CT, and MRI, or even radioisotope examination using Tc-99m sestamibi [16].

Parathyroid abnormalities usually cause glandular enlargement. Examination with scintigraphy has a high sensitivity of up to 80% in determining the location of a single parathyroid adenoma but of only 25% when used to locate multiple adenomas. Examination by contrast-enhanced CT and MRI can also be used primarily to determine the location of parathyroid adenomas outside of the parathyroid gland [14], [15]. The results of ultrasonography and neck CT, in this case, revealed an inferior left parathyroid lobe mass suggestive of an adenoma. Thus, the examination supported the diagnosis of parathyroid adenoma. Therefore, parathyroidectomy was performed on the patient.

In some cases, the parathyroid adenoma is diagnosed together with bone diseases, such as osteoporosis, and fractures, as reported by Mabulac and Twigt. Braverman stated that there were correlations among the PTH level, bone disease, and neuropsychiatric symptoms, in which the PTH level tended to increase the occurrence of bone disease and neuropsychiatric disorders [14], [15].

The treatment of parathyroid tumours is the surgical exploration of the neck and removal of pathological parathyroid glands followed by another parathyroid gland biopsy to determine the possibility of adenoma or multiple gland hyperplasia. If a parathyroid tumour was not found, it is necessary to consider the superior exploration of the mediastinum [16], [17].

The laboratory examination results for the patient in this case before surgery were as follows: calcium, 11.3 mg/dl; parathyroid hormone, 1,276 pg/mL; vitamin D, 11.2 ng/mL. After surgery, the calcium level was 10.9 mg/dl, and the PTH level was 95.47 pg/ml. According to these results, the levels of calcium and parathyroid hormone decreased significantly after surgery. Calo and Zawawi reported that in a case of primary hyperthyroidism, after removal of the parathyroid gland tumour, the parathyroid hormone and calcium levels would immediately decrease. In this case, during surgery, the left parathyroid gland was first removed; then, the

PTH level was measured, and the value was significantly decreased. This result indicates that parathyroid surgery decreases excessive PTH levels [15], [16].

Along with the postoperative decrease in the parathyroid hormone and calcium levels, the condition of the patient gradually improved with a reduction in the patient's perceived pain. The patient also consulted the physiotherapy unit for guidance regarding walking exercises. After surgery and physiotherapy, the patient's condition tended to improve; the patient could walk with a stick and experienced no more fractures. Regarding the osteoporosis, it was characterised by a decrease in height and multiple fractures. The patient's height before the disease was 153 cm; after surgery, her height was 150 cm, and after one year after surgery, her height was 150.2 cm, indicating a decrease in height after the illness.

In conclusion, parathyroid adenoma should be strongly suspected if a patient presents with any prolonged fatigue, bone pain, osteoporosis that is not associated with age, and multiple fractures without significant trauma — a delay in the diagnosis of parathyroid adenoma results in manifestations that can be avoided. Parathyroid adenoma has an excellent prognosis with surgical treatment.

References

- Lofrese JJ, Lappin SL. Physiology, Parathyroid. In: StatPearls [Internet]. Treasure Island (FL): StatPearls Publishing, 2019. Available from: <https://www.ncbi.nlm.nih.gov/books/NBK482510/>
- Bilezikian JP, Cusano NE, Khan AA, Liu JM, Marcocci C, Bandeira F. Primary hyperparathyroidism. *Nature reviews Disease primers*. 2016; 2:16033. <https://doi.org/10.1038/nrdp.2016.33> PMID:27194212 PMCID:PMC5385896
- Syamsu Hidayat, R., De Jong Wim. *Buku Ajar Ilmu Bedah, Edisi Revisi*. Jakarta: EGC, 2016.
- Levine BS, Rodríguez M, Felsenfeld AJ. Serum calcium and bone: effect of PTH, phosphate, vitamin D, and uremia. *Nefrología (English Edition)*. 2014; 34(5):658-69.
- Baum M. The bone-kidney axis. *Current opinion in pediatrics*. 2014; 26(2):177. <https://doi.org/10.1097/MOP.0000000000000071> PMID:24535498 PMCID:PMC4074396
- McClenaghan F, Qureshi YA. Parathyroid cancer. *Gland Surgery*. 2015; 4(4):329.
- Bhansali A, Gogate Y. Hyperparathyroidism. *Clinical Rounds in Endocrinology*. Springer, New Delhi, 2015:309-339. https://link.springer.com/chapter/10.1007/978-81-322-2398-6_14 https://doi.org/10.1007/978-81-322-2398-6_14
- Shinjo SK, Pereira RM, Borssatto AG, Kochen JA. Musculoskeletal manifestations in primary hyperparathyroidism. *Revista Brasileira de Reumatologia*. 2009; 49(6):703-11. <https://doi.org/10.1590/S0482-50042009000600007>
- El-Sayed, MA, El-Habashy HR, El-Taweel NS. *Progressive Muscle Weakness in Hyperparathyroidism*. 2010.
- Khan M, Sharma S. Physiology, parathyroid hormone (PTH). In: StatPearls [Internet]. StatPearls Publishing, 2018. <https://www.ncbi.nlm.nih.gov/books/NBK499940/>
- Calò PG, Pisano G, Loi G, Medas F, Barca L, Atzeni M, Nicolosi A. Intraoperative parathyroid hormone assay during focused parathyroidectomy: the importance of 20 minutes measurement. *BMC surgery*. 2013; 13(1):36. <https://doi.org/10.1186/1471-2482-13-36> PMID:24044556 PMCID:PMC3848580
- Twigt BA, Scholten A, Valk GD, Rinkes IH, Vriens MR. Differences between sporadic and MEN related primary hyperparathyroidism; clinical expression, preoperative workup, operative strategy, and follow-up. *Orphanet journal of rare diseases*. 2013; 8(1):50. <https://doi.org/10.1186/1750-1172-8-50> PMID:23547958 PMCID:PMC3623824
- Romanidis K, Karathanos E, Nagorni EA, Giatromanolaki A, Sibridis E, Zissimopoulos A, Vogiatzaki T, Simopoulos C, Pitiakoudis M. Parathyroid adenoma detected with 99m Tc-tetrofosmin dual-phase scintigraphy: a case report. *BMC research notes*. 2014; 7(1):335. <https://doi.org/10.1186/1756-0500-7-335> PMID:24894734 PMCID:PMC4076066
- Zawawi F, Mlynarek AM, Cantor A, Varshney R, Black MJ, Hier MP, Rochon L, Payne RJ. Intraoperative parathyroid hormone level in parathyroidectomy: which patients benefit from it? *Journal of Otolaryngology-Head & Neck Surgery*. 2013; 42(1):56. <https://doi.org/10.1186/1916-0216-42-56> PMID:24350891 PMCID:PMC3878236
- Le TN, Kerr PD, Sutherland DE, Lambert P. Validation of 1-hour post-thyroidectomy parathyroid hormone level in predicting hypocalcemia. *Journal of Otolaryngology-Head & Neck Surgery*. 2014; 43(1):5. <https://doi.org/10.1186/1916-0216-43-5> PMID:24476535 PMCID:PMC3922691
- Williams BA, Trites JR, Taylor SM, Bullock MJ, Hart RD. Surgical management of primary hyperparathyroidism in Canada. *Journal of Otolaryngology-Head & Neck Surgery*. 2014; 43(1):44. <https://doi.org/10.1186/s40463-014-0044-4> PMID:25367580 PMCID:PMC4221664
- Adler JT, Sippel RS, Schaefer S, Chen H. Preserving function and quality of life after thyroid and parathyroid surgery. *The lancet oncology*. 2008; 9(11):1069-75. [https://doi.org/10.1016/S1470-2045\(08\)70276-6](https://doi.org/10.1016/S1470-2045(08)70276-6)