

Alveolar Bone Osteoclast Profile in the Periodontitis Wistar Rats Model with the Snail Slime (*Achatina Fulica*) Application

I Gusti Agung Ayu Putu Swastini¹, Tjokorda Gde Bagus Mahadewa^{2*}, I Putu Eka Widyadharma³

¹Health Ministry Polytechnic, Denpasar, Bali, Indonesia; ²Department of Neurosurgery, Faculty of Medicine, Udayana University, Bali, Indonesia; ³Department of Neurology, Faculty of Medicine, Udayana University, Bali, Indonesia

Abstract

Citation: Swastini IGAAP, Mahadewa TGB, Widyadharma IPE. Alveolar Bone Osteoclast Profile in the Periodontitis Wistar Rats Model with the Snail Slime (*Achatina Fulica*) Application. Open Access Maced J Med Sci. <https://doi.org/10.3889/oamjms.2019.451>

Keywords: Snail slime; Aggregatibacter actinomycetemcomitans bacteria; Alveolar bone; Osteoclast

***Correspondence:** Tjokorda Gde Bagus Mahadewa. Department of Neurosurgery, Faculty of Medicine, Udayana University, Bali, Indonesia. E-mail: tjokmahadewa@unud.ac.id

Received: 04-Mar-2019; **Revised:** 16-May-2019; **Accepted:** 17-May-2019; **Online first:** 30-May-2019

Copyright: © 2019 I Gusti Agung Ayu Putu Swastini, Tjokorda Gde Bagus Mahadewa, I Putu Eka Widyadharma. This is an open-access article distributed under the terms of the Creative Commons Attribution-NonCommercial 4.0 International License (CC BY-NC 4.0)

Funding: This research did not receive any financial support

Competing Interests: The authors have declared that no competing interests exist

BACKGROUND: Bone damage is a result of periodontal disease that occurs due to changes in osteoclast and osteoblast activity in response to local inflammation. The bacteria *Aggregatibacter actinomycetemcomitans* produces Lipopolysaccharide (LPS), which can increase osteoclast activity.

AIM: This study aimed to analyse the decrease in alveolar bone osteoclasts in periodontitis rats' model with the application of snail slime.

METHODS: Wistar rats (27) with periodontitis divided into three groups, namely the control group (debridement), P1 group (debridement and application of oral snail slime) 300 Mg/Kg Body weight, P2 group (debridement, application of topical snail slime) 0.1 Mg. Osteoclast profile analysis was carried out by HE staining procedure to determine the histological feature of osteoclasts. The statistical significance was determined using the Shapiro-Wilk Test, One Way ANOVA, and Post Hoc test ($p < 0.05$).

RESULTS: Osteoclast profile in rats with periodontitis applied with snail slime significantly decreased the number of osteoclasts with both oral and topical administration, there were significant differences in the number of osteoclasts between groups (one way ANOVA, $p < 0.05$) and there were no significant differences between groups P1 and P2 (Post Hoc, $p > 0.05$).

CONCLUSION: In this study, there was a decrease in the number of osteoclasts which were slipped by snail slime in Wistar rats with periodontitis; this indicates a periodontitis healing process.

Introduction

Periodontitis is an inflammatory disease of the supporting tissues of the teeth caused by certain groups of microorganisms that usually originate from dental plaque which can result in the progressive destruction of periodontal connective tissue and alveolar bone [1]. Bone damage is a result of periodontal disease that occurs due to changes in osteoclast and osteoblast activity in response to local inflammation. Osteoclasts play a role in bone resorption with excessive expression of RANKL

produced through activation of T lymphocytes and B lymphocytes in response to secretion of inflammatory cytokines such as TNF α and IL- β [2]. Inflammatory cytokines can also play a role in inhibiting bone repair by osteoblasts [3]. The bacteria *Aggregatibacter actinomycetemcomitans* produces a lipopolysaccharide (LPS) which can increase osteoclast activity. Chronic inflammatory reactions stimulated by bacteria and their products around periapical can cause bone damage [4].

Bone destruction is mediated by the host immune and inflammatory response against the microbial activity. Bone resorption is followed by

activation of cells that resorb bone called osteoclasts. Osteoclasts are bone cells that affect the degenerative process. Osteoclasts and osteoblasts regulate dynamic balance in the bone remodelling process [5]. An imbalance of bone remodelling is caused by more osteoclast cells than osteoblasts resulting in the process of bone resorption. Bone resorption is affected by osteoclast activating factors, including prostaglandins, endotoxin bacteria, and complement activator products consisting of cytokines, IL-1, TNF-, TNF-, IL-6, and IL-11 [6]. In the process of osteoclast cell formation (osteoclastogenesis), an osteoclast bond differentiation factor occurs with its receptor. This increase in the osteoclastogenesis process results in increased bone resorption [7]. One of the natural ingredients for regenerating alveolar bone is snail slime. Snail slime reacts positively to testing the protein content that plays a role in cell regeneration and growth, including amino acids and enzymes. Protein can function and play a role in growth, defence, bodily functions and as a protective function, which is a substitute for damaged tissue and cells. Based on the purpose of this protein, it is estimated that the animal protein content in snail slime has a high biological value, namely in healing and inhibiting the inflammatory process [8].

Snail slime (*Achatina fulica*) has an active ingredient which plays a role in the process of wound healing. One of the active compounds found in snail slime is heparin sulfate, which functions as a factor that influences cell division. Besides, this substance also features as an aid to the attachment of proteins that function as signals for the cell division receptor stimulus on the cell membrane [9]. Addition of the concentration of heparin sulfate absorbed by the tissue will increase fibroblast proliferation. Fibroblast Growth Factor (FGF) initiates the cell proliferation process in injured tissue.

Another active compound is achasin isolate; the chemicals contained in snail slime give a positive reaction to the testing of protein content that plays a role in cell regeneration and growth. Achasin is a protein contained in snail slime, has essential biological functions, the leading organic compounds that makeup bone are proteins, and the main protein making up bone is type I collagen which is 90-95% of the leading organic matter while the rest is a homogeneous medium called basic substance [10]. Achasin isolates function as antibacterial and analgesic while Calcium plays a role in hemostatic. Calcium in periodontal tissues is found in the extracellular and intracellular matrix. In the extracellular matrix, it functions as signalling between cells and a source of calcium for hard teeth and periodontal tissues. Calcium in the intracellular matrix acts as a mediator for the actin preparation of fibroblast tissue and soft tissue [11].

Therefore, this study aimed to analyse the profile of the number of alveolar bone osteoclasts in

the rats with periodontitis model with the application of snail slime.

Material and Methods

Materials

This study used 27 male Wistar rats with a weight of 200-250 grams, aged 2-3 months, while for the treatment the slime taken from as many as 50 snails were used. Snail shells were disinfected using 70% alcohol to prevent bacterial contamination. Snail meat was stimulated using the tip of the pipette to remove its slime. Then the slime which collected in the bottle was added to ethanol and then centrifuged in the Chemical Analytical Laboratory of Udayana University, Denpasar, Bali, Indonesia. Snails slime were collected from the Banjar Umaanyar garden, Nyalian village, and Banjar Angkan Klungkung district, Bali. This study was an actual experimental study with a randomised post-test only control group design conducted at the Analytical and Veterinary Laboratory of Udayana University, Denpasar, Bali.

Preparation of research subjects

Periodontitis was induced in the study sample by attaching silk ligature to the incisive mandibular cervical, then *Aggregatibacter actinomycetemcomitans* bacteria were infiltrated in the gingival sulcus as much as 2.42×10^8 / ml CFU equivalent to 0.5 Mac Farland one time with a dose of 0.22 ml, topical anaesthesia was previously applied (Figure 1, 2, and 3). On the third day, the rats experienced acute inflammation of the gingiva; the rats were sick and did not want to eat. On the eleventh day after the infiltration of the *Aggregatibacter actinomycetemcomitans* bacteria, the mouse gingiva appeared bluish and swelled with the appearance of gingival pocket, third-degree tooth shake, and central diastema, the gingiva also became easily bleed, indicating the occurrence of periodontitis. Rats with periodontitis were divided into three groups. The Control Group (K) only carried out debridement with distilled water, while P1 group given debridement and administration of oral snail slime of 300 Mg/Kg Body Weight, and P2 group given debridement and administration of topical snail slime of 0.1 Mg.



Figure 1: A) Preparing silk Ligature; B) Infiltration with bacteria Aa; C) Periodontitis

Observations

Observations were carried out after treatment, on day 7, day 14, and day 21 after exposure. Considerations include a clinical examination and tissue examination taken from the alveolar bone. The tissue was preserved in 10% formalin buffer, decalcified with EDTA, and then stained with Hematoxylin-Eosin. Analyses were carried out under a 400x magnification of light microscope and seen from five fields of view.

Administration of snail slime

In group P1 the administration of snail slime was given once a day for seven days at a dose of 300 mg/kg body weight, P2 group (debridement and administration of topical snail slime), was given three times 0.1 mg for seven days. The first time is at 7:00 a.m., the second is at 13:00 a.m. and the third is at 6:00 p.m. The examination was carried out after the treatment, on the 7th day, 14th day, and 21st day. The experimental animals were euthanised using ether anaesthesia; then the jaw was cut in the mandibular incisor region. The sample was prepared using 10% formalin for 24 hours, decalcified using 14% EDTA, for 30 days, dehydrated, cleared, and embedded in paraffin, then cut in the longitudinal direction with a thickness of 5 microns for the Hematoxylin-Eosin (HE) painting procedure [12]. Staining procedures were performed using HE to determine the histological feature of osteoclasts. Analysis of the number of osteoclasts was examined under an electric microscope with 400 x magnification.

Effects of giving snail slime

There was a decrease in the number of osteoclasts in rats with periodontitis given snail slime both orally and topically.

Results

Analysis of the number of osteoclasts can be seen in histological features (Figure 2, 3, and 4).

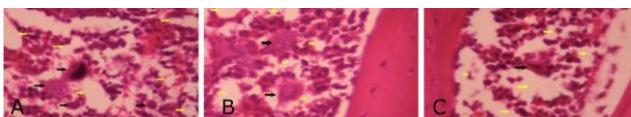


Figure 2: A), B), and C) Alveolar bone histology

Based on the clinical examination, pocket depth is reduced, 1st-degree tooth shake, there was no bleeding, no central diastema, healthy gingiva in the subject given snail slime.

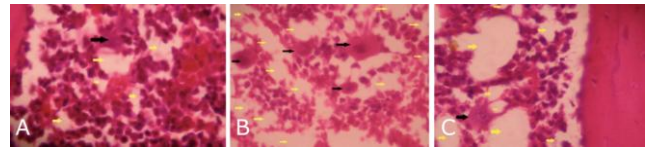


Figure 3: A), B), and C) Alveolar bone histology; Day 14 (K) Day 14 (P1) Day 14 (P2)

Figure 5 shows that the number of osteoclasts in the K group was the highest, namely on the 14th day amounted to 4.33, then the P1 group on the seventh day showed two cells and on the P2 group showed one cell.

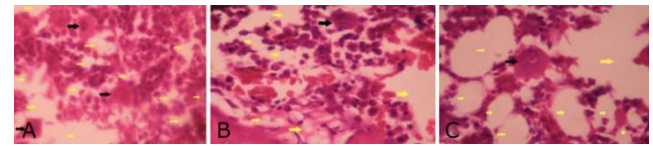


Figure 4: A), B), and C) Alveolar bone histology; Day 21 (K) Day 21 (P1) Day 21 (P2)

The normality test using Shapiro-Wilk test obtained a value of $p > 0.05$ indicating that the data on the number of osteoclasts was typically distributed, followed by the One-Way ANOVA test showing that the p -value < 0.05 means that there are statistically significant osteoclast numbers in all groups.

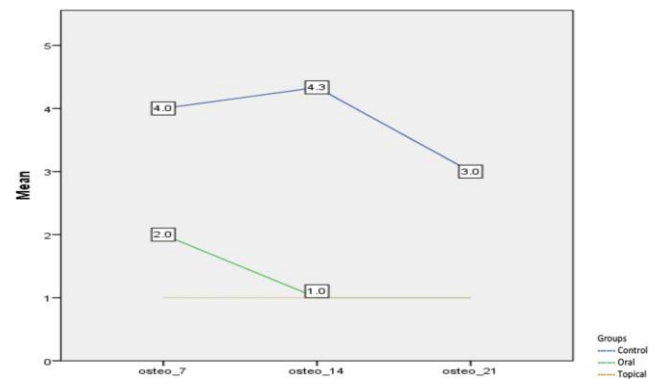


Figure 5: Diagram of the average number of osteoclasts

Table 1 shows that in the control group on day 14 the highest number of osteoclasts was 4.33 cells that differed significantly from groups P1 and P2, while the number of osteoclasts in the P2 group was one cell from the seventh day.

Table 1: Comparison of the number of osteoclasts based on the research group

Independent Variable	Day	Groups			P value
		Control	Oral	Topical	
Number of Osteoclast	7	4.00 ± 1.1	2.00 ± 0.00	1.00 ± 0.00	0.002
	14	4.33 ± 0.57	1.00 ± 0.00	1.00 ± 0.00	0.001
	21	3.00 ± 0.00	1.00 ± 0.00	1.00 ± 0.00	NA

We used the post-hoc test to see if the differences in osteoclasts between treatment groups were statistically significant on day 7, 14, and 21 (Tables 2 and 3).

Table 2: Post Hoc Test Results Between Groups on the 7th Day

Independent Variable	Groups	Groups	Mean Difference	P value
Number of Osteoclasts (day-7)	K	P ₁	2.000	0.005*
		P ₂	3.000	0.001*
	P ₁	K	-2.000	0.005*
		P ₂	1.000	0.078
	P ₂	K	-3.000	0.001*
		P ₁	-1.000	NA

Table 2 shows that the difference between the seventh-day groups on osteoclast cells examination was significantly different indicated by the value of $p < 0.05$ except that the differences in groups P1 and P2 were not significant.

Table 3: Post Hoc Test Results Between Groups on the 14th Day

Independent Variable	Groups	Groups	Mean Difference	P value
Number of Osteoclast (day-14)	K	P ₁	3.333	0.000
		P ₂	3.333	0.000
	P ₁	K	-3.333	0.000
		P ₂	0.000	1.000
	P ₂	K	-3.333	0.000
		P ₁	0.000	1.000

Table 3 shows that the difference between groups on day-14 of the examination of osteoclasts was significantly different indicated by the value of $p < 0.05$ except the difference between group P1 and P2 was not significant, with a value of $p > 0.05$.

Table 4: Results on the 21st Day Post Hoc Test Between Groups

Independent Variable	Groups	Groups	Mean Difference	P value
Number of Osteoclast (day- 21)	K	P ₁	3.333	0.029
		P ₂	3.333	0.029
	P ₁	K	-3.333	0.029
		P ₂	0.000	NA
	P ₂	K	-3.333	0.029
		P ₁	-3.333	0.029

Table 4 shows that the difference between groups on day-21 of the examination of osteoclasts was significantly different indicated by the value of $p < 0.05$ except the difference in groups P1 and P2 was not significant, the p-value is not available.

Discussion

The periodontal tissue is the tissue around the teeth, which functions as a support for the teeth, consisting of gingival tissue, cementum, periodontal ligament, and alveolar bone. Periodontitis is an inflammation of the supporting tissues of the teeth, which causes progressive damage to the periodontal ligament and alveolar bone [13]. Alveolar bone loss is

a hallmark of periodontitis progression, and its prevention is an essential clinical challenge in periodontal disease treatment. Bone destruction is mediated by the host immune and inflammatory response to the microbial challenge. However, the mechanisms by which the local immune response against periodontopathic bacteria disturbs the homeostatic balance of bone formation and resorption in favour of bone loss remain to be investigated [14].

The results showed that there were significant differences in the number of osteoclasts between the control groups, with groups P1 and P2 performed by the One-Way ANOVA test, so that it can be said that snail slime affects the reduction of osteoclast cells in bacterial-induced Wistar rats alveolar bone by *Aggregatibacter actinomycetemcomitans*. Ahasin isolate, glyconyugugate, glycosaminoglycans, calcium, can trigger angiogenesis. Vascular endothelial growth factor inhibits and decreases mitogen activity of fibroblast growth factor. The Vascular Endothelial Growth Factor (VEGF) is a cytokine involved in Sing angiogenesis, inducing new blood vessel formation in the periodontium by VEGF activation. VEGF is known to be an angiogenesis factor produced by various types of cells, including fibroblasts, smooth muscle cells, hypertrophic chondrocytes, osteoblasts, and others. VEGF immunoreactivity is found in vascular endothelial cells, in fibroblasts adjacent to hyaline tissue, a necrotic area in the pressure area of osteoblasts, osteoclasts, and mononuclear cells [15]. VEGF can modulate recruitment, differentiation, and activation of osteoclast precursors, thereby increasing bone resorption. VEGF indirectly causes bone resorption because it promotes angiogenesis in vitro, which allows new capillaries to help recruit osteoclasts near the bone surface to the resorption area; VEGF can induce neovascularisation [16].

In the control group, the number of osteoclasts was higher than that of the treatment group. This was caused by the bacteria *Actinobacillus actinomycetemcomitans* capable of producing an increase in the number of osteoclasts. The bacteria released their products in the form of Gram-negative bacterial lipopolysaccharide (LPS) on the cell wall. LPS has strong potential as an inflammatory stimulator if injected in vivo because LPS can penetrate the periradicular tissues and act as endotoxin in its host organisms which causes inflammation in periradicular and continues with bone damage [17].

IL-1 is known to stimulate fibroblasts to produce collagenase. IL-1 is known to have the most potential to induce bone demineralisation and is synergistic with tumour necrosis factor α in stimulating bone resorption, especially in altering the connective tissue matrix. Macrophages produce IL-1 as the primary mediator of tissue destruction in periodontal disease [18]. IL-6 cytokines can stimulate bone resorption, in this case, the influence of IL-6 cytokines

on RANKL expression (ligand of receptor activator of NF- κ B), RANK (receptor activator of NF- κ B), and OPG (osteoprotegerin). IL-6 type cytokine families are cytokines consisting of IL-6, IL-11, leukaemia inhibitory factor (LIF), oncostatin M (OSM), ciliary neurotrophic factor, cardiotrophin-1, and neutrophil-1 / B cell stimulatory factors 3. These agents use the same receptor subunit, gp130, as a signal [19].

There was a higher number of osteoclasts in the seventh-day P1 group than in P2 on the seventh day due to topical snail slime administration which could improve bioavailability and drug efficacy by avoiding the first-pass elimination in the liver. The Pocket acts as a natural reservoir and provides easy access to drug administration day 14, but after days 14 and 21 there is no difference because it has undergone cell regeneration and osteoclast, differentiation has decreased, and bone density has increased [20].

In conclusion, snail slime (*Achatina fulica*) affects decreasing the number of osteoclasts in the alveolar bone of Wistar rats induced by *Aggregatibacter actinomycetemcomitans* bacteria, either given orally 300 Mg/Kg Body Weight or topically using snail slime 0.1 Mg.

Acknowledgement

This study was conducted after the approval of the ethics committee of the Faculty of Veterinary Medicine Udayana University, Denpasar, Bali, Indonesia.

Author Contributions

All the authors have made substantial contributions to the work reported in the manuscript.

References

- Newmann MG, Takei HH. Carranza's Clinical Periodontology Philadelphia: WB Saunders, 10 ed., 2012:99-607.
- Cotti E, Dessi C, Piras A, Mercurio G. Can a chronic dental infection be considered a cause of cardiovascular disease? A review of the literature. International journal of cardiology. 2011; 148(1):4-10. <https://doi.org/10.1016/j.ijcard.2010.08.011> PMID:20851474
- Åberg CH, Kelk P, Johansson A. Aggregatibacter actinomycetemcomitans: virulence of its leukotoxin and association with aggressive periodontitis. Virulence. 2015; 6(3):188-95. <https://doi.org/10.4161/21505594.2014.982428> PMID:25494963 PMCid:PMC4601274
- Graves DT, Oates T, Garlet GP. Review of osteoimmunology and the host response in endodontic and periodontal lesions. Journal of oral microbiology. 2011; 3(1):5304. <https://doi.org/10.3402/jom.v3i0.5304> PMID:21547019 PMCid:PMC3087239
- Orbans. Oral Histology and Embryology. Chapter 7. 11Ed. US America: Mosby Year Book, 1991
- Ingle J, Bakland L. Endodontics 6. Hamilton: BC Decker Inc., 2008:502-503.
- Takayanagi H. Osteoimmunology: shared mechanisms and crosstalk between the immune and bone systems. Nature Reviews Immunology. 2007; 7(4):292. <https://doi.org/10.1038/nri2062> PMID:17380158
- Perez WP, Dina F, Iwang Y. Effect of Snail Slime (*Achatina fulica*) on Fibroblast Cell Number on Healing Wounds. Experimental Study on the Skin of Mice (*Mus musculus*). Science Medika. 2012; 4(2):195 - 203
- Nuringtyas 2008. Glikonjugat: Proteoglycan, Glikoprotein, dan Glycolipid, December 2018. Available from <http://elisa.ugm.ac.id>
- Ali GP. Rapid Comparative Test for Healing Clean Wounds in Rabbits (*Lepus negricollis negricollis* Lepus) Between Provision of 10% Povidone-iodine Solution and Snail Slime (*Achatina fulica*). 2009.
- Baron R. Anatomy and Ultrastructure of Bone Histogenesis, Growth and Remodeling, 2006. <http://www.endotext.org>
- Hikmah N. Osteoclast profiles and alveolar bone osteoblasts in the early stage diabetic mouse model with the application of orthodontic force, Eh Hayat, 2015; 5.
- Kesic L, Petrovic M, Obradovic R, Pejic A. The importance of aggregatibacter actinomycetemcomitans in etiology of periodontal disease-mini review. Acta Medica Medianae. 2009; 48:35-37.
- Teitelbaum S. L. Osteoclasts: what do they do and how do they do it? The American Journal of Pathology. 2007; 170(2):427-435. <https://doi.org/10.2353/ajpath.2007.060834> PMID:17255310 PMCid:PMC1851862
- Miyagawa A, Chiba M, Hayashi H, and Igarashi K. Compressive force induces VEGF production in periodontal tissues. Journal of Dental Research. 2009; 88(8):752-756. <https://doi.org/10.1177/0022034509341637> PMID:19734464
- Cheung WY, Liu C, Tonelli-Zasarsky RML, Simons CA, and You Lidan. Osteocyte apoptosis is mechanically regulated and induces angiogenesis in vitro. J Orthop Res. 2011; 29:523- 530. <https://doi.org/10.1002/jor.21283> PMID:21337392
- Kumar V, Cotran RS, Robbins SL. Buku ajar patologi. Edisi ke-7. Jakarta: EGC. 2007.
- Johansson, A. Aggregatibacter actinomycetemcomitans Leukotoxin: A powerful Tool With Capacity to cause Imbalance In The Host Inflammatory Response. Journal Toxin. 2001; 2011:3:242-59. <https://doi.org/10.3390/toxins2030242>
- Prahasanti, C. Immunohistochemical Analysis of NF-KB (P50/P65) in Patient with Aggressive and Chronic Periodontitis. Indonesian Journal of Tropical and Infectious Disease. 2013; 4(4):56-9. <https://doi.org/10.20473/ijtid.v4i4.235>
- Gunani SB. Power Test for Anti-Inflammatory Cream of Type A / M Ethanolic Extract of 10% Ginger (*Zingiberofficinale* Roscoe) Given Topically Against Udem of Caragenine-Induced Mice Feet, Research Report, Surakarta, 2009.