

An Atypical Presentation of a Strangulated Bochdalek Hernia in a 60-Year-Old Man

Danilo Coco¹, Silvana Leanza²

¹Ospedali Riuniti Marche Nord, Pesaro (PE), Italy; ²Carlo Urbani Hospital, Jesy, Italy

Abstract

Citation: Coco D, Leanza S. An Atypical Presentation of a Strangulated Bochdalek Hernia in a 60-Year-Old Man. Open Access Maced J Med Sci. <https://doi.org/10.3889/oamjms.2019.465>

Keywords: Bochdalek hernia; Adult; Occlusion; Ischaemia; Laparoscopic surgery technique

***Correspondence:** Danilo Coco, Ospedali Riuniti Marche Nord, Pesaro (PE), Italy. E-mail: webcostruction@msn.com

Received: 07-Apr-2019; **Revised:** 26-May-2019; **Accepted:** 27-May-2019; **Online first:** 14-Jun-2019

Copyright: © 2019 Danilo Coco, Silvana Leanza. This is an open-access article distributed under the terms of the Creative Commons Attribution-NonCommercial 4.0 International License (CC BY-NC 4.0)

Funding: This research did not receive any financial support

Competing Interests: The authors have declared that no competing interests exist

BACKGROUND: Bochdalek hernia is a type of congenital diaphragmatic hernia (CDH), which more commonly affects children. Congenital left diaphragmatic hernias, such as Bochdalek, rarely occur in adults. Most such cases do not present any symptoms.

CASE PRESENTATION: Here, we report the case of a 60-year-old male with a left-sided Bochdalek diaphragmatic hernia, who presented with abdominal pain and dyspnea. The patient was successfully treated by laparoscopic approach.

CONCLUSION: The 60-year-old male patient had left-sided BH and was successfully cured by the laparoscopic approach.

Introduction

Bochdalek hernia (BH) is a congenital diaphragmatic hernia, generally caused by the improper fusion of the posterolateral diaphragmatic foramina [1], resulting in the displacement of the abdominal components into the thoracic cavity (Figure 1).

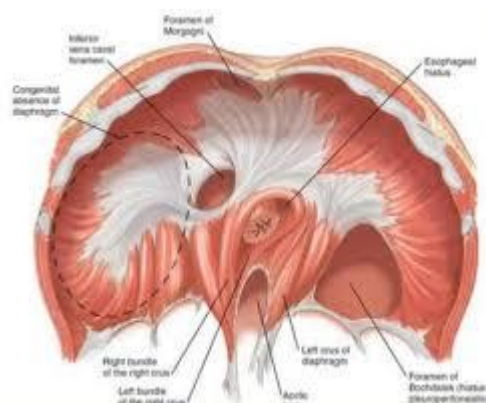


Figure 1: Anatomy of diaphragmatic hernia

Generally, it occurs in children, primarily during the 9th or 10th week of fetal life [2]. It rarely occurs in adults and accounts for 0.17-6% of all diaphragmatic hernias [3]. About 80-90% of BH usually occurs on the left side. Approximately 1 in 2,200-12,500 live births is affected by BH. It was first described by Vincent Alexander Bochdalek in 1848 [4]. The most common intra-abdominal organs, such as colon and small bowel that migrate through the diaphragmatic defect, are the most obstructed because of BH [5]. Most of the BH cases are incidental, asymptomatic posterolateral diaphragmatic defects. Rare cases of BH in adults where symptoms are present might result in incarcerated bowel, intra-abdominal organ dysfunction, or severe pulmonary disease [3], [6], [7].

Here, we report the case of a 60-year-old patient who arrived in the emergency room with dyspnea and bowel obstruction.

Case Report

A 60-year-old male patient was admitted to the emergency room with complaints of abdominal cramps, dysphagia, constipation, and shortness of breath. He had no record of thoracic or abdominal trauma, and his medical history was non-relevant. The psychosocial history of the patient as well as his family was normal. The patient had an arterial pressure of 90/60 mmHg, cardiac rate 120 b/min, and body temperature of 38°C. Laboratory analysis showed leukocytes is of 17 mm³/l and an elevated protein chain reaction (PCR). Blood Gas Analysis (BGA) showed PH 7.27, PCO₂ 50 mmHg, PO₂ 70 mmHg, HCO₃ 17, BE-7 mEq. Physical examination elicited diffuse abdominal pain with a positive Blumberg sign, suggesting peritonitis. Bowel sounds were audible on the left side of the chest. A chest Ray showed complete opacity of the left thorax (Figure 2).

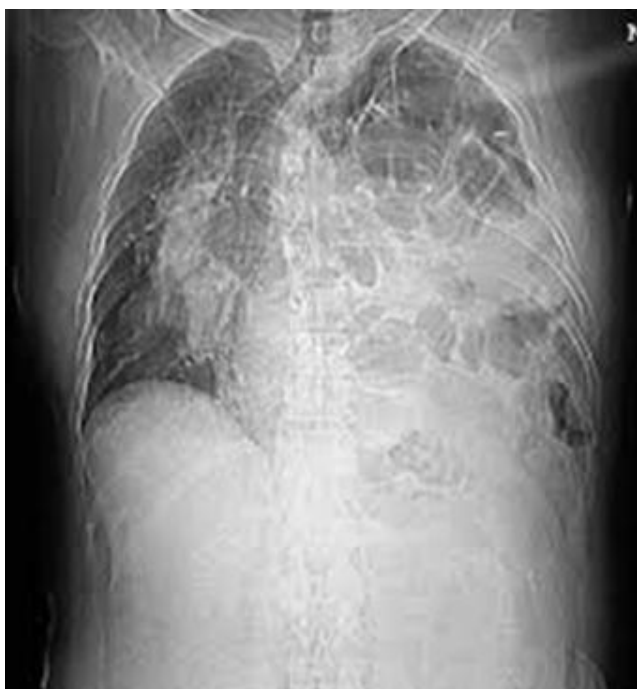

Figure 2: Chest radiography: complete opacity of the left thorax

Computer Tomography (CT) Scan showed a defect in the posterior left diaphragm and herniation of intra-abdominal fat and small bowel into the left hemithorax (Figure 3). BH was diagnosed based on the above findings. The surgery involved a laparoscopic approach. Reduction of the hernia sac and strangulated ischemic ileum was found. Ten cm of bowel was re-sectioned with lateral-lateral anastomosis. The patient was kept in the intensive care unit (ICU) for 10 days because of sepsis and acute respiratory distress syndrome (ARDS). He returned to the wards after 10 days and was discharged 19 days after surgery.

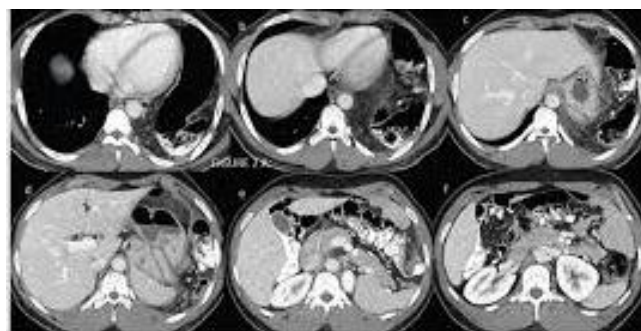

Fig.3 Computer Tomography (CT) Scan: images of a defect in the posterior left diaphragm and herniation of intra-abdominal fat and small bowel into the left hemithorax

Discussion

Generally, BH occurs during the initial weeks of a patient's life. Diagnosis of BH after the first 8 weeks of life is assessed to be 5 – 25%. BH is one of the foremost reasons for respiratory distresses among neonates, and is the most prevalent congenital anomaly of the thorax. Most of the neonatal BHs are found on the left side [8], [9]. BH in adults is mostly asymptomatic, due to which it is discovered incidentally. Patients of BH generally report chest discomfort or symptoms related to the gastrointestinal tract. In the literature reports, there is a predominance (70 – 90% of the cases) of left-sided BH. A left-sided hernia may comprise the enteric tract, the spleen, the liver, the pancreas, a kidney or fat. Right-sided hernias are more unusual because the right pleuroperitoneal canal constricts earlier, and the liver supports the right diaphragm [10]. Surgical treatment is necessary due to a range of potential complications, which, although often asymptomatic, may lead to tissue strangulation, a pneumothorax and intestinal necrosis [11], [12]. Laaksonen et al. reported a right-sided Bochdalek hernia in a 38-year-old woman who had a history of complaints regarding abdominal pain and nausea. After being diagnosed with endometriosis, her left ovary had been removed some years ago. She was not on medication and did not have any underlying illness. There was no history of any previous abdominal or thoracic trauma. She was treated via thoracotomy assisted with laparoscopy [13]. The postoperative process was completed without any untoward development, and the patient was released from the hospital 7 days after the surgery. Atef and Emna [14] reported a case of a 56-year-old woman with Bochdalek hernia, gastric volvulus and epigastric pain, cough, vomiting for 2 weeks and shortness of breath. The bochdalek hernia was an incidental discovery through a chest radiograph, computed tomography (CT), and barium swallow analysis. The stomach was within the thorax in the left side due to the left diaphragmatic hernia of a nontraumatic reason. It was hazardous to dissect

because of numerous adhesions. Therefore, the laparotomic approach was adopted through upper midline incision to decrease content, and prolene was used to join the diaphragmatic flaw. The patient recovered in the postoperative phase without any incident and was discharged 9 days later. Another case of BH was reported by Carrascosa et al., [15]. The case was that of a 68-year-old woman with a 4-week history of right-sided chest pain and dyspnea on minimum exertion. She was asymptomatic until the present hospitalisation. In particular, she had no complaints of chronic dyspnea, chest pain, vomiting, abdominal pain and postprandial fullness. After retracting the hernia sac and the projected organs (jejunum, ileum, part of the right colon and mesenterium) to the abdominal cavity, she went through surgery to repair the diaphragm. The recovery period of 12 days went through without any incident, following which the patient was discharged.

As can be observed from the above discussion, most Bochdalek hernias appear in children and are presented with acute respiratory symptoms, and are placed on the left side. Adulthood left-sided Bochdalek hernias are extremely rare. This abnormality should be known and managed suitably to avoid potential complications. Management can be through strangulation of the hernia contents, intestinal necrosis, hemothorax, and pneumothorax. Diagnosis of BH is more likely in patients exposed to factors that increase their intra-abdominal pressure.

Since there are no specific symptoms or signs, it is crucial to obtain a CT scan as soon as possible, especially when a case is presented with acute and unexplained pain in the abdomen. This is of critical importance in managing BH patients because any delay in diagnosis could enhance the risk of death. In our case, too, the 60-year-old male patient had left-sided BH and was successfully cured by the laparoscopic approach.

References

- Luther A, Mahajan A. Left-sided Bochdalek Hernia in an Adult: A Case Report with Review of Literature. *Journal of International Medical Sciences Academy*. 2015; 28(1):33-34.
- Alam A, Chander BN. Adult Bochdalek Hernia, Case report. *Medical Journal Armed Forces India*. 2005; 61(3):284-286. [https://doi.org/10.1016/S0377-1237\(05\)80177-7](https://doi.org/10.1016/S0377-1237(05)80177-7)
- Mullins ME, Stein J, Saini SS, Mueller PR. Prevalence of incidental Bochdalek's hernia in a large adult population. *American Journal of Roentgenology*. 2001; 177(2):363-366. <https://doi.org/10.2214/ajr.177.2.1770363> PMID:11461863
- Gale ME. Bochdalek hernia: prevalence and CT characteristics. *Radiology*. 1985; 156(2):449-52. <https://doi.org/10.1148/radiology.156.2.4011909> PMID:4011909
- Shin MS, Mulligan SA, Baxley WA, Ho KJ. Bochdalek hernia of diaphragm in the adult: diagnosis by computed tomography. *Chest*. 1987; 92(6):1098-101. <https://doi.org/10.1378/chest.92.6.1098> PMID:3677819
- Hung YH, Chien YH, Yan SL, Chen MF. Adult Bochdalek hernia with bowel incarceration. *J Chin Med Assoc*. 2008; 71:528-531. [https://doi.org/10.1016/S1726-4901\(08\)70162-X](https://doi.org/10.1016/S1726-4901(08)70162-X)
- Owen ME, Rowley GC, Tighe MJ, Wake PN. Delayed diagnosis of fractured small bowel due to right-sided Bochdalek hernia. *Ann R Coll Surg Engl*. 2007; 89:W1-2. <https://doi.org/10.1308/147870807X160407> PMID:17346388 PMCid:PMC3253648
- Puri P, Wester T. Historical aspects of congenital diaphragmatic hernia. *Pediatric Surgery International*. 1997; 12(2-3):95-100. <https://doi.org/10.1007/s003830050075>
- Langer JC. Congenital diaphragmatic hernia. *Chest Surgery Clinics of North America*. 1998; 8(2):295-314.
- Kanazawa A, Yoshioka Y, Inoi O, Murase J, Kinoshita H. Acute respiratory failure caused by an incarcerated right-sided adult Bochdalek hernia: report of a case. *Surgery today*. 2002; 32(9):812-5. <https://doi.org/10.1007/s005950200156> PMID:12203061
- Garófano-Jerez JM, López-González JD, Valero-González MA, Valenzuela-Barranco M. Posterolateral Bochdalek diaphragmatic hernia in adults. *Revista Española de Enfermedades Digestivas*. 2011; 103(9):484-491. <https://doi.org/10.4321/S1130-01082011000900009> PMID:21951119
- Vieira LH, Del Castanhel C, Tristão LJ, Guimarães A, Ribas CS. Hérnia diafragmática congênita simulando derrame pleural. Relato de caso. *Rev Bras Clin Med*. São Paulo. 2013; 11(1):94-6.
- Laaksonen E, Silvasti S, Hakala T. Right-sided Bochdalek hernia in an adult: a case report. *Journal of medical case reports*. 2009; 3(1):9291. <https://doi.org/10.1186/1752-1947-3-9291> PMID:20062780 PMCid:PMC2803814
- Atef M, Emna T. Bochdalek hernia with gastric volvulus in an adult: common symptoms for an original diagnosis. *Medicine*. 2015; 94(51). <https://doi.org/10.1097/MD.0000000000002197> PMID:26705205 PMCid:PMC4697971
- Carrascosa MF, Carrera IA, García JA, García MA, Tapia AD, Lavín AC, Caviedes JR. Symptomatic Bochdalek hernia in an adult patient. *BMJ case reports*. 2010; 2010:bcr0520102996. <https://doi.org/10.1136/bcr.05.2010.2996> PMID:22802326 PMCid:PMC3027423