

The Effect of Haramounting Leaf Ethanol Extract (*Rhodomyrtus tomentosa* (Aiton) Hassk.) on the Number of Leukocyte Type and Histology of Mice Pulmo (*Mus Musculus* L.) Exposed to Electronic Cigarette

Syafrudin Ilyas^{*}, Finn Murdela, Salomo Hutahaean, Putri Cahaya Situmorang

Department of Biology, Faculty of Mathematics and Natural Sciences, Universitas Sumatera Utara, Medan, Indonesia

Abstract

Citation: Ilyas S, Murdela F, Hutahaean S, Situmorang PC. The Effect of Haramounting Leaf Ethanol Extract (*Rhodomyrtus tomentosa* (Aiton) Hassk.) on the Number of Leukocyte Type and Histology of Mice Pulmo (*Mus Musculus* L.) Exposed to Electronic Cigarette. Open Access Maced J Med Sci. <https://doi.org/10.3889/oamjms.2019.467>

Keywords: Electronic cigarettes; Leukocytes; Mice; Pulmo; *Rhodomyrtus tomentosa*

***Correspondence:** Syafrudin Ilyas. Department of Biology, Faculty of Mathematics and Natural Sciences, Universitas Sumatera Utara, Medan, Indonesia. E-mail: syafrudin6@usu.ac.id

Received: 19-May-2019; **Revised:** 11-Jun-2019; **Accepted:** 12-Jun-2019; **Online first:** 13-Jun-2019

Copyright: © 2019 Syafrudin Ilyas, Finn Murdela, Salomo Hutahaean, Putri Cahaya Situmorang. This is an open-access article distributed under the terms of the Creative Commons Attribution-NonCommercial 4.0 International License (CC BY-NC 4.0)

Funding: This research was financially supported by Sumatera Utara from Talenta proposal program on Professor research grant number Certificate 2590/UNS.1.R/PPM/2018

Competing Interests: The authors have declared that no competing interests exist

BACKGROUND: Haramounting leaves have a large antioxidant activity as inhibitors oxidation and form non-free radical compounds that are not reactive and relatively stable. Electronic smoking is a choice who slowly want to quit conventional smoking.

AIM: This research aimed to determine the effect of ethanol extract on hard mounting leaves on leukocyte counts and histology Pulmo on male mice exposed to an electronic cigarette.

METHODS: The samples used in this study were healthy male mice aged 8-11 weeks and weight of 25-30 g as many as 25 individuals and ethanol extracts of hard mounting leaves with a dose of 100 mg/kgBW, 200 mg/kgBW and 300 mg/kgBW. Blood tests were carried out at the Health Laboratory of North Sumatra Office, and the preparation of Pulmo histology was carried out at the Pathology and Anatomy Laboratory of Adam Malik General Hospital Medan

RESULT: There were significant differences between the control group and all of the treatment groups in the number of lymphocytes, neutrophils, basophils and eosinophils. There was a tendency that electronic cigarette smoke could cause damage to pulmo tissue.

CONCLUSION: The results of this study indicate that the ethanol extract of hard mounting leaves could help the immune system in mice exposed to an electronic cigarette.

Introduction

One source of pollutants in the air is cigarette smoke which has toxic properties for the lungs, especially clove cigarettes (without filters). These toxic substances enter the lungs increasing free radicals that affect the imbalance of antioxidant levels in the lungs to fight oxidants. This situation is called oxidative stress. These gases include 2-nitropropane, acrylonitrile, acrolein, ammonia, acetaldehyde, dimethylnitrosamine, formaldehyde, hydrazine, hydrogen cyanide, carbon monoxide, nitrogen oxides, pyridine, urethane, vinyl chloride, and various other

nitrosamines [1].

Electronic smoking is a choice for active smokers who slowly want to quit conventional smoking. Electronic cigarettes are considered as healthy cigarettes with lower nicotine content and do not contain tobacco smoke compared to conventional cigarettes. Smoking is a major cause of lung cancer, as well as other lung diseases that are chronic and obstructive, such as bronchitis and emphysema. About 85% of people with this disease are caused by cigarettes — symptoms caused by chronic cough, phlegm, and respiratory problems. If a lung function test is carried out, then the test results on smokers are

worse than those of nonsmokers. Smoking is also associated with influenza and other pneumonia [2].

Death is generally not due to difficulty breathing because of enlarged cancer, but the position of the lungs in the circulatory system that makes cancer spread easily throughout the body. Exposure to secondhand smoke causes the body's natural antioxidants to no longer force the production of Reactive Oxygen Species (ROS). This results in the production of ROS as a reactive molecule that continues to be excessive and causes damage in various places. Excess ROS will damage the respiratory tract epithelial cells and surrounding cell membranes so that an inflammatory response occurs. The inflammatory response due to increased ROS from exposure to cigarette smoke will increase blood leukocyte levels. One parameter to assess the increase in leukocyte levels is to count the type of leukocytes [3].

According to [4] haramounting leaf extract has a large antioxidant activity. Antioxidants are defined as inhibitors that work to inhibit oxidation by reacting with reactive free radicals to form non-free radical compounds that are not reactive and relatively stable [5]. Haramounting stems and twigs have large antioxidant activity, and weak toxicity [6], [7] explained that ethanol extract of hard mounting leaves has antibacterial and anti-inflammatory activity. Haramounting leaves (*Rhodomyrtus tomentosa*) contain flavonoids, saponins, tannins and triterpenoids. Flavonoid content is a powerful antioxidant that can reduce lipid peroxidation, increase epithelialization speed, and is anti-microbial [8].

This research aimed to determine the effect of ethanol extract on hard mounting leaves on leukocyte counts and histology Pulmo on male mice exposed to an electronic cigarette.

Material and Methods

The material used is male mice (*Mus musculus L*) strain DDW, Haramounting leaves obtained from plantation residents in Tapanuli North Sumatera, Feed the mice no. PB 551, staining Hematoxylin and Eosin. This research used the Completely Randomized Design (CRD) using 30 male mice with an average weight of 20-25 g aged 12-18 weeks. Male mice are kept in Animal Cages Biological Laboratory, Faculty Mathematics and Natural Science, Universitas Sumatera Utara, Medan Indonesia. Experimental animal handling is done ethically (*Ethical Clearance*).

Rhodomyrtus tomentosa leaves are washed then dried by the requirements of water content. The treatment consisted of 5 groups consisting of 5 male

mice positive Control (K^+), Negative Control (K^-) in given exposure smoke cigarettes and treatment groups extract ethanol harmonising at a dosage of (100, 200, 300) mg/KgBW in 30 days. All mice killed by the method of disclasio cervicalis to take the tests. Furthermore, the parameters are leukocyte count, morphological observation and pulmonary histology. Pulmo is taken to make histology preparations using paraffin method. The histology study was carried out under a microscope with a magnification of 10 x 40. The method used in pulmonary histology observation was a scoring method using the microanatomy structure of the lung tissue of mice analysed qualitatively and made a score of degree of damage. In each field of view counted 20 cells at random and then the data processed with SPSS 22 program with *Kruskal Wallis* test.

Results

Based on this research Figure 1 shows that the monocytes count value in the negative control treatment was 2, the positive control was 1, in the treatment of 100 mg/kgBW was 8, in the treatment of 200 mg/kgBW, and 300 mg kgBW was 4. It was seen an increase in the value of monocytes in the blood mice after exposure to electronic cigarette smoke and given Haramounting ethanol extract. The results obtained are differences in monocytes values that were not significantly different in each group both in the control group and the treatment group. In the P1 group obtained higher than the control group, this occurred because of the influence of hard mounting ethanol extract and exposed to electronic cigarette smoke. Based on data from the normal monocytes count value, monocytes are still at normal levels, which is between 2 to 8. This shows that monocytes are still in good and normal condition in the blood of mice.

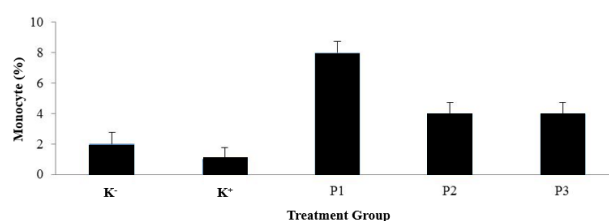


Figure 1: Percentage of Mice Blood Monocyte Count Counted by Electronic Cigarette Smoke and Haramounting Leaf Extract. Note; $p > 0.05$

The lymphocytes count value in the negative control treatment was 17, the positive control was 10, the treatment of 100 mg/kgBW was 78, the treatment of 200 mg/kgBW was 83, and the treatment of 300

mg/kgBW was 74 (Figure 2). The value of mice lymphocytes after exposure to electronic cigarette smoke and given haramounting ethanol extract. The results obtained are differences in basophil values that are significantly different between the control group and the treatment. The P2 group was higher than the other groups due given ethanol extract of hard mounting leaves at 200 mg/kgBW, but lymphocytes values in the K⁺ group are even lower than others.

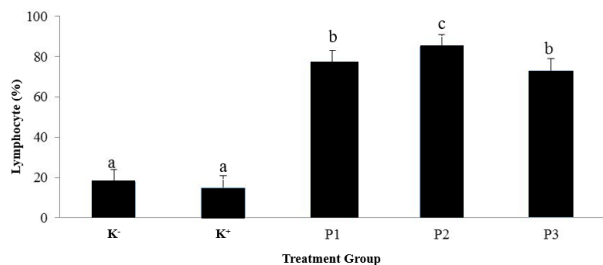


Figure 2: Percentage of Mice Blood Lymphocyte Count Counted by Electronic Cigarette Smoke and Haramounting Leaf Extract. Note; $p^{a,b} < 0.05$

Based on the data of normal lymphocyte count values between 20-40, the mice were negative and positive control was still in good and normal condition while mice treated at 100 mg/kgBW, 200 mg/kgBW and 300 mg/kgBW increased above normal values.

The neutrophil count value in the negative control (K⁻) treatment was 75, the positive control was 83, the treatment of 100 mg/kgBW was 5, the treatment of 200 mg/kgBW was 5, and the treatment of 300 mg/kgBW was 11 (Figure 3).

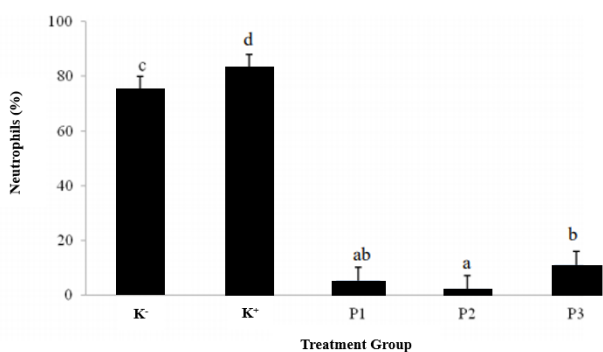


Figure 3: Percentage of Mice Blood Neutrophil Count Counted by Electronic Cigarette Smoke and Haramounting Leaf Extract. $p^{a,b} < 0.05$

Seen decrease in the neutrophil value of mice after exposure to electronic cigarette smoke and given haramounting ethanol extract. The results obtained were differences in neutrophil values that were significantly different between the control group and the treatment group. In the K⁺ group, which can be higher than the control group, this occurs because of

the influence of hard mounting ethanol extract and exposed to electronic cigarette smoke can increase the neutrophil value. But in the group of neutrophil values higher than the neutrophil value in the treatment group. Based on the data of normal neutrophil count values between 50-70. So, the mice treated with negative control was still in normal neutrophil conditions. The positive control treatment, neutrophils experienced a slight increase and in 100 mg/kgBW, 200 mg/kgBW and 300 mg/kgBW decreased neutrophils.

The value of basophil count in the negative control treatment was 2, the positive control was 0, the treatment of 100 mg/kgBW was 10, the treatment of 200 mg/kgBW was 8, and the treatment of 300 mg/kgBW was 10 (Figure 4). Seen Basophil values of mice after exposure to electronic cigarette smoke and given haramounting ethanol extract. The results obtained are differences in basophil values that are significantly different between the control group and the treatment group. The P3 group was higher than the other groups by giving 300mg/kgBW of hard mounting leaf ethanol extract. However, the basophil value in the K⁺ group was 0. Based on the data of the normal values of basophil count, i.e. 0 to 1, the mice in the positive control were in normal conditions. Whereas for mice in negative control and treatment of 100 mg/kgBW, 200 mg/kgBW and 300 mg/kgBW experienced an increase in basophil value.

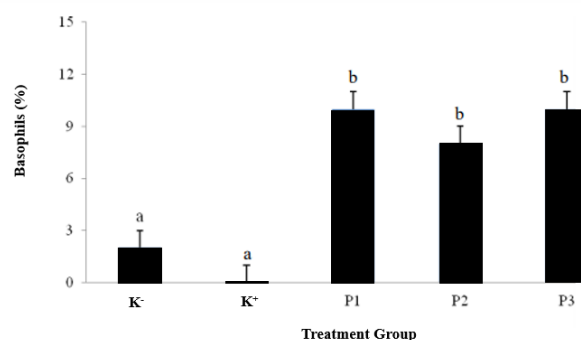


Figure 4: Percentage of Mice Blood Basophil Count Counted by Electronic Cigarette Smoke and Haramounting Leaf Extract. $p^{a,b} < 0.05$

The calculated value of the type of eosinophils in the negative control treatment was 3, the positive control was 1, in the treatment of 100 mg/kgBW was 0, the treatment of 200 mg/kgBW was 0, and the treatment of 300 mg/kgBW was 0 (Figure 5).

Eosinophil value in blood of mice after exposure to electronic cigarette smoke and given haramounting ethanol extract. The results obtained were differences in eosinophil values, which were significantly different between the control group and the treatment group.

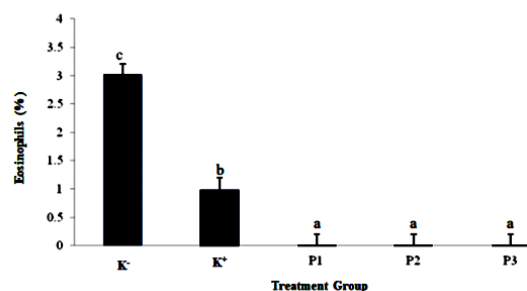


Figure 5: Percentage of Mice Blood Eosinophil Count Counted by Electronic Cigarette Smoke and Haramounting Leaf Extract. $p^{a,b} < 0.05$

The P1, P2 and P3 groups obtained lower than the other groups due to exposure to cigarette smoke, and hard mounting extracts can reduce eosinophil values. Based on the data of normal values of eosinophil count, i.e. 1 to 3, the eosinophil levels of mice in negative control and positive control were still in good and normal condition, while mice treated at 100 mg/kgBW, 200 mg/kgBW and 300 mg/kgBW decreased eosinophils value.

The average weight of pulmo mice in the negative control group (K⁻) was 0.33 g, the positive control group (K⁺) was 0.37 g, the treatment group 1 was 0.33 g, the treatment group 2 was 0.36 g and treatment group 3 was 0.34 g (Figure 6). It was seen that in the positive control group showed the highest average weight; this was probably due to the continuous use of mouse mice exposed to electronic cigarette smoke exposure without being given haramounting leaf extract which was thought to be an antioxidant. Cigarette smoke that enters the pulmo will cause pulmonary tissue damage and respiratory disorders so that for a long period, it will cause Pulmo smokers to become damaged.

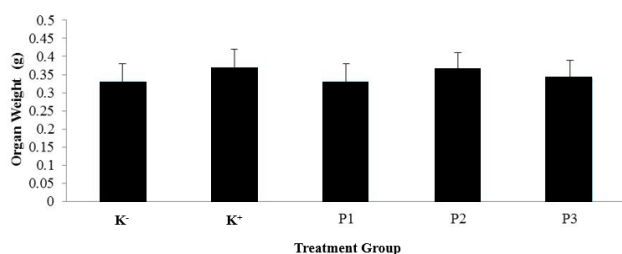


Figure 6: Average Weight of Pulmo Mice Exposed to Electronic Cigarette Smoke and Haramounting Leaf Extract. Note: $p > 0.05$

From Figure 7, the difference in the colour of pulmo mice in each treatment. Where the negative control (K⁻) looks pink coloured pulmo, positive control (K⁺) looks blackish pulmo, treatment 1 looks pink coloured Pulmo with a little black spot, treatment 2 looks pink coloured pulmo black, and 3 treatment looks coloured pulmo pink with black spots that almost cover the entire surface of pulmo. Pulmonary

morphology in the positive control (K⁺) shows that there are many black spots on the surface of pulmo, this is likely to occur due to the influence of electronic cigarette smoke-exposed to mice. While pulmo in treatment P1, P2 and P3 were seen to have black patches but not as much as pulmo in the positive control (K⁺), due to the possibility of the effect of hard mounting leaf extract and antioxidant for Pulmo mice.

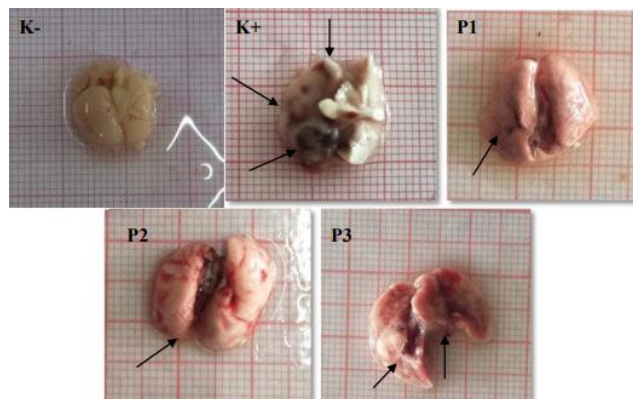


Figure 7: Pulmo Color of Mice Blood Exposed to Electronic Cigarette Smoke and Haramounting Leaf Extract. (Photo After Fixation Process) shows black spots on the surface of pulmo mice

The average score of the degree of damage from Pulmo tissue (Figure 8). Pulmonary tissue damage was done by *Kruskal-Wallis* test to see the differences in the five treatments. From the results of statistical analysis tests showed that for membrane damage, lumen damage and the relationship between alveoli have different scores on negative control, positive control and treatment. Based on the graph above, it can be seen that the greatest pulmonary tissue damage score occurs in positive control with a score of 3, in which the condition of the alveolar membrane is damaged and not intact with the alveolar lumen that is not rounded and the stretching between the alveoli. Whereas for all good treatment 100 mg/kgBW, 200 mg/kgBW and 300 mg/kgBW the pulmo tissue damage score was 2 where the condition of the alveolar membrane is still intact with the surrounding endothelial cells, the alveolar lumen was still intact rounded train and the alveolar relationship was quite tight. This shows that in positive control, pulmo exposed to cigarette smoke is damaged both in the alveolar membrane, alveolar lumen and also the relationship between the alveoli and it can be seen also in the treatment there is an effect of haramounting leaf extract on pulmo tissue so that damage to the pulmo tissue can be minimized.

The damage that occurred between the negative control group, positive control and the treatment was significantly different (Figure 9). This is consistent with the results of statistical analysis of pulmo tissue damage scores.

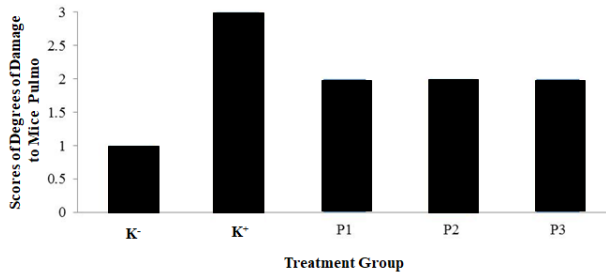


Figure 8: Scores of Degrees of Damage to Mice Pulmo Exposed to Electronic Cigarette Smoke and Haramounting Leaf Extract

For negative controls with a score of 1 where the alveolar membrane was intact, nucleated and complete with endothelial cells with the rounded alveolar lumen and tight interrelated alveolar connections. For negative control with a score of 3 where the alveolar membrane is not intact, it has no nucleus, and the surrounding endothelial cells are not visible with the alveolar lumen widened, and the relationship between the alveoli is stretched. P1, P2 and P3 groups with a score of 2 where the alveolar membrane is relatively intact with the alveolar lumen that is still rounded and the relationship between the alveoli is relatively tight.

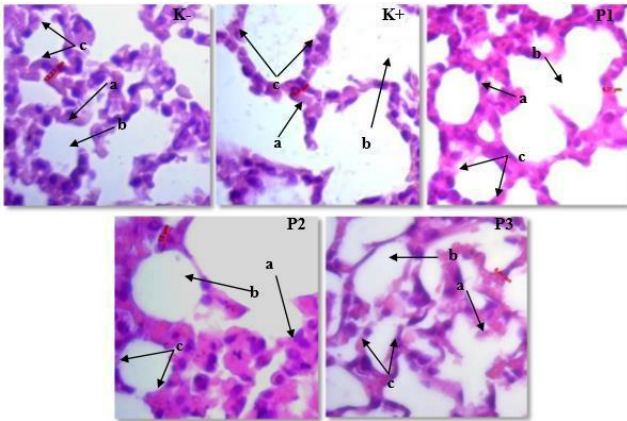


Figure 9: Histology of Pulmo Mice Exposed to Electronic Cigarette Smoke and Haramounting Leaf Extract. K- (negative control); K+ (positive control); P1, P2, P3 (treatment); Heilage HE Magnification 100 x; A) Alveolar membrane; B) Lumen alveolus; C) Relationship between alveoli

Discussions

Alveolar macrophages release cytokines such as tumour necrosis factor- α (TNF- α), and TNF- α can stimulate the bone marrow to accelerate the differentiation, proliferation and maturation of granulocyte cells, especially neutrophils and monocytes which can increase the amount in the blood. Excessive increase in ROS can cause an imbalance so oxidative stress will occur. If lipid

peroxidation occurs, the structure of the monocyte cell containing the most lipids is the cell membrane will be damaged. Damage to cell membranes results in disrupted biochemical activity in cells, so cells are unable to sustain their lives, and cell death occurs [2].

Antioxidants are compounds that can inhibit reactive oxygen species and also free radicals so that antioxidants can prevent diseases associated with free radicals such as carcinogenesis, cardiovascular and ageing [9].

Lymphocytes are a type of leukocytes that have a role in the immune response. Lymphocytes show very high heterogeneity in morphology and function because they are active and can change shape and size. Lymphocytes can break through soft tissues or organs because they provide immune substances for the body's defence. Lymphocytes play a role in responding to antigens (foreign objects) by forming antibodies and developing immunity [10] because lymphocytes are immune cells that play an important role in response systems humoral and cellular invulnerability [11].

A neutrophil can phagocyte 5-20 bacteria before inactive and dead neutrophils [14]. The number of neutrophils can be increased if there is an infection, inflammation and in a state of stress. Stressful conditions in mice can trigger an increase in the production of corticosteroid hormones. Corticosteroids are produced by the adrenal cortex, which can increase anti-inflammatory, physiological and metabolic activity in the body [15]. There was an increase in neutrophils in negative controls where mice were not given any treatment. The possibility is that the mouse is in a stressful condition both with the environment outside the cage and inside the cage. While the number of neutrophils in the treatment of 100mg/kgBW, 200mg/kgBW and 300 mg/kgBW decreased. This proves that mice do not experience any anti-inflammatory activity in which there is no tissue injury or infection in the mouse tissue. The highest number of leukocyte count results is neutrophil leukocytes; this is by the statement of [16] that has the potential as an immunomodulator and maintain an acute inflammatory response in the body. It is suspected that it can increase neutrophil production which serves to maintain an acute inflammatory response in the body, in this case, non-specific neutrophils can quickly recognise and respond to a pathogen, and are important for controlling bacterial infections. The effects of ethanol intoxication are measured in other tissues where there is a decrease in enzymes in the blood, liver and kidneys but not in the heart and lymph. This means that the effect of alcohol on the number of leukocytes is related to the effects of alcohol in a chronic way that affects the bone marrow, which is the place where blood cells are produced. With this theory, it can be concluded that the effects of alcohol can chronically interfere with the production of basophils. An increase in the number of basophils indicates a leukocyte

response in humoral and cellular ways to overcome the presence of substances that enter [17].

Basophils have the same function as mast cells, which generate acute inflammation in the antigen deposition site [18]. When the tissue experiences inflammation of the basophils, it releases heparin, histamine, a little bradykinin, and serotonin. Changes in the number of leukocytes in the blood circulation can be interpreted as the emergence of disease agents, inflammation, autoimmune diseases or allergic reactions [19].

Monocytes in carrying out the function of the immune system act as macrophages which swallow and destroy cells, microorganisms and foreign objects that are pathogenic. Eosinophils perform the function of the immune system by lysing as well as chemical functions, which are enzymatically [20].

Eosinophils function as phagocytes in the blood so that the presence of incoming chemicals is considered a foreign object. Therefore, eosinophil acts to repair damaged networks [15].

Eosinophils are present in the blood in small amounts, namely 1-3% of the total leukocyte population. The mechanism of action of eosinophils uses opsonisation with the help of immunoglobulin E (IgE), so eosinophils are strongly associated with its action with IgE. Eosinophils after being synthesised and enter the bloodstream then infiltrate the tissue. In this tissue eosinophils work against pathogens. The presence of pathogens will trigger an increase in the number of eosinophils in the blood. Eosinophils also play a role in the inflammatory process. Inflammation itself occurs using T helper (Th) cells. Th17 cells that are active will express IL-17, and the two cells then secrete several chemokines and cytokines such as erythropoietin, Transforming Growth Factor (TGF), MMP [21].

Cigarette smoke that enters the respiratory tract can cause airway reflex disturbances, impaired ciliary function (ciliotoxic) and increase mucus production. When smoking, various chemicals are absorbed in, and if it occurs for a long time there will be a work inhibition of the lungs, such as carbon monoxide, its presence in the lungs will reduce the blood's ability to bind oxygen from the lungs. This happens because red blood cells have a stronger affinity for carbon monoxide compared to oxygen. This situation causes shortness of breath and severe coughing for a long time [22].

The main toxins contained in cigarettes are tar, nicotine, and carbon monoxide. Cigarette smoke that enters the respiratory tract can cause airway reflex disturbances, impaired ciliary function (ciliotoxic) and increase mucus production [22]. The cough that occurs in smokers is an attempt to remove thick mucus that is difficult to be pushed out of the airway [23], states [24] that the components of cigarette smoke are CO, ammonia, hydroxylic acid

nitrogen oxides, and formaldehyde. The particles consist of tar, indole, nicotine, carbazole and cresol. This substance is toxic, irritating, and causes cancer (carcinogens). Statement [25] states that the additional flavour content in electronic cigarettes also contains carcinogens that are harmful to humans, including nitrosamines, toxic chemicals such as diethylene glycol, and components of anabasine, myosmine, and betanicyotin tobacco specific ingredients. People who smoke for a long time have a high prevalence of several diseases such as atherosclerosis and chronic obstructive pulmonary disease (COPD) with significant systemic effects [26]. Thus, the sufferer is not only his smoker (active smoker) but also people who are in the cigarette smoke environment or referred to as passive smoking [27].

According to [28], the relationship between the alveolus that is dense in the group that is not exposed to cigarette smoke shows that the extracellular matrix which consists of collagen and elastin fibres is still intact. Lumen alveolus It seems normal not enlarged, which is common when there are lung abnormalities.

According to [29], gas absorption through the respiratory tract depends directly on the concentration of gas in the air inhaled. Most gases can switch easily across the alveolus epithelium into the plasma. Also, the respiratory tract can excrete toxins that have been absorbed from pulmo or through other pathways and with a xenobiotic metabolic enzyme system, biotransforming many toxics that can produce oxygen radicals and reactive epoxides that can cause cell damage in pulmo. According to [30], the length of exposure for inhalation poisoning and behavioural poisoning tests can be acute, chronic and chronic. But acute understanding is more common with inhalation toxicology, and chronic understanding is more common with behavioural toxicology.

In conclusion, the effect of giving haramounting leaf extract (*Rhodomyrtus tomentosa* (Aiton) Hassk.) to the number of normal values of the type of leukocytes mice exposed to electronic cigarettes cannot help maintain the normal value of leukocyte count. But in statistical analysis, it was seen that the change in leukocyte count value did not experience an increase or decrease that was too significant so that it was still within reasonable limits and did not endanger mice. haramounting leaf extract (*Rhodomyrtus tomentosa* (Aiton) Hassk.) as much as 200mg/kgBW. The effect of giving electronic cigarette smoke to mice did not statistically affect the alveolar membrane, alveolar lumen and the relationship between alveoli. However, in histological observations there is a tendency that electronic cigarette smoke can cause the alveolar membrane to lose endothelium cells in it, the alveolar lumen which is widened and not rounded intact and the relationship between the alveoli tend to be stretched.

Acknowledgement

We are grateful to University of Sumatera Utara from Talenta proposal program on Professor research grant number Certificate 2590/UN5.1.R/PPM/2018.

References

- Rachmadi, Afdol, Lestari, Yuniar and Yenita. Relationship Knowledge and Attitudes Against Cigarettes With Smoking Smoking Junior High School Students In Padang City. *Journal of Medicine Andalas*. 2013; 2(1):6-7.
- William M., Trtchounian A, and Talbot P. Conventional and electronic cigarette (ecigarette) have different smoking characteristics. *Nicotine Tobacco Res*. 2010; 12:905-912. <https://doi.org/10.1093/ntr/ntq114> PMID:20644205
- Damayanti A. Penggunaan Rokok Elektronik Di Komunitas Personal Vaporizer Surabaya. *Jurnal Berkala Epidemiologi*. 2016; 4(2):250-261. <https://doi.org/10.20473/jbe.V4i22016.250-261>
- Lavanya G, Voravuthikunchai SP, Towatana NH. Acetone Extract from *Rhodomyrtus tomentosa*: A Potent Natural Antioxidant. Evidence-Based Complementary and Alternative Medicine. 2012; 2012. <https://doi.org/10.1155/2012/535479> PMID:23125869 PMCid:PMC3484404
- Djamil R. and Anelia T. Penapisan Fitokimia, Uji BSLT, dan Uji Antioksidan Ekstrak Metanol beberapa Spesies Papilionaceae. *Jurnal Ilmu Kefarmasian Indonesia*. 2009; 7(1):190-194.
- Kusuma IW, Ainiyati N, Suwinarti W. Search for Biological Activities from an Invasive Shrub Species Rose Myrtle (*Rhodomyrtus tomentosa*). *Jurnal Nusantara Bioscience*. 2016; 8(1):170-174. <https://doi.org/10.13057/nusbiosci/n080110>
- Mordmuang A, Voravuthikunchai SP. *Rhodomyrtus tomentosa* (Aiton) Hassk. leaf extract: An alternative approach for the treatment of staphylococcal bovine mastitis. *Research in veterinary science*. 2015; 102:242-6. <https://doi.org/10.1016/j.rvsc.2015.07.018> PMID:26412553
- Rupina W. Trianto HF and Fitrianingrum I. Efek Salep Ekstrak Etanol 70% Daun Haramounting Terhadap Re-epitelisasi Luka Insisi Kulit Tikus Wistar. *Jurnal Kerfarmasian*. 2016; 9(1):120-124. <https://doi.org/10.23886/eiki.4.5905.26-30>
- Hoffbrand V. *At a Glance Hematology*. Jakarta (ID). EMS. 2006.
- Bikrisirna SHL, Mahfudz LD, and Suthama N. Resilience of Broiler Chickens in Tropical Conditions Given Red Guava (*Psidium Guajava*) as a Source of Antioxidants. *Agromedia*. 2013; 31(2):46-57.
- Schalm OW, Jain NC, and Carrol EJ. *Veterinary Hematology*. 3rd ed. Lea and Febiger, Philadelphia, 1995.
- Lockwood W. *The Complete blood count and associated test*, 2018.
- Fajrunni'mah R. Noni Juice To Reduce The Amount Of Leukocytes And Neutrophils As An Indicator Of Inflammation On Exposure To Cigarette Smoke. *Journal of Health Science and Technology*. 2016; 3(2).
- Guyton AC, Hall JE. *Textbook on Medical Physiology*. Edition 11. Jakarta: EGCA. 2008
- Tortora GJ, Derrickson B. *Principles of anatomy & physiology*. John Wiley & Sons, Incorporated; 2017.
- Jang SAK, Park JD, Lim S, Kang KH, Yang S, Pyo and Sohn EH. The Comparative Immunomodulatory Effects of β glucan From Yeast, Bacteria, and Mushroom on the Function of Macrophages. *Journal of Food Science and Nutrition*. 2009; 14:102-108. <https://doi.org/10.3746/jfn.2009.14.2.102>
- Erlinger TP. WBC Count and the Risk of Cancer Mortality in a National Sample of U.S. Adults: Results from the Second National Health and Nutrition Examination Survey Mortality Study. *Cancer Epidemiology, Biomarkers & Prevention*. 2004;13:1052.
- Tizard IR. *Introduction to Veterinary Immunology*. Airlangga University Press, Surabaya, 1988.
- Lestari SHA, Ismoyowati, Indradji M. Study of leukocyte counts and differential leukocytes in various types of female local ducks which feed on probiotic supplementation. *J Scientific Animal Husbandry*. 2013; 1(2):699-709.
- Isroli S, Susanti E, Widiastuti T, Yudiarti, and Sugiharto. Observation of a number of second chicken hematological variables in intensive maintenance. *National Livestock Awakening Seminar, Semarang*. 2009; 548-557.
- Juwariyah, Arjana AZ, Rahayu ET, Rosita, Irfan RM. Leukocyte Pro Inflammatory Activity in Cases of Chronic Obstructive Pulmonary Disease Acute Exacerbation. *Journal of Medicine and Health*. 2017; 17(2). <https://doi.org/10.18196/mm.170202>
- Santosa S, Purwito J and Widjaja JT. Comparison of the Value of Peak Flow of Expiration Between Smokers and Non-Smokers. *JKM*. 2004;3(2):6.
- Surbakti NB. *Pathophysiology Pocket Book*. Third Edition. Jakarta: EGC Medical Book Publishers, 2007.
- Safitri W. *Dangers of Smoking for Health*. UMM; 2010.
- Westenberger BJ. Evaluation of ecigarettes. Department of Health and Human Services Food and drug Administration, center of drug evaluation and research division of pharmaceutical analysis. 2009; 1-8.
- Yanbaeva DG, Dentener MA, Creutzberg EC, Wesseling G, Wouters, Emiel FM. Systemic effect of smoking. *Chest*. 2007; 131:1557-66. <https://doi.org/10.1378/chest.06-2179> PMID:17494805
- Susanna D, Hartono B, Fauzan H. Determination of nicotine levels in cigarette smoke. *Makara Kesehatan*. 2003; 7:2.
- Marianti A. Antioxidant Activity of Tomato Juice in Prevention of Damage to Lung Tissues Exposed to Cigarettes. *Biosaintifika Journal*. 2009; 1(1):1-10.
- Lu FC. *Basic Toxicology: Principles, Target Organ and Risk Assessment*. Second Edition. Jakarta: University of Indonesia Publisher, 1995.
- Mansyur. *Toxicology. Selective Toxicity and Test*. Medan: USU Digital Library, 2002.