

# The Protective Effect of Nitroglycerin, N-Acetyl Cysteine and Metoprolol in CCL4 Induced Animal Model of Acute Liver Injury

Faruk H. Al-Jawad<sup>1\*</sup>, Zaid Al-Attar<sup>2</sup>, Muayyad S. Abbood<sup>3</sup>

<sup>1</sup>Department of Pharmacology & Therapeutics, Al-Nahrain College of Medicine, Al-Nahrain University, Baghdad, Iraq;  
<sup>2</sup>Department of Pharmacology, Al-Kindy College of Medicine, University of Baghdad, Baghdad, Iraq; <sup>3</sup>The High Institute for Infertility Diagnosis and Assisted Reproductive Technologies, Al-Nahrain University, Baghdad, Iraq

## Abstract

**Citation:** Al-Jawad FH, Al-Attar Z, Abbood, MS. The Protective Effect of Nitroglycerin, N-Acetyl Cysteine and Metoprolol in CCL4 Induced Animal Model of Acute Liver Injury. Open Access Maced J Med Sci. <https://doi.org/10.3889/oamjms.2019.469>

**Keywords:** Hepatoprotection; Metoprolol; N-acetyl cysteine; Nitroglycerin

**\*Correspondence:** Faruk H. Al-Jawad, Department of Pharmacology & Therapeutics, Al-Nahrain College of Medicine, Al-Nahrain University, Baghdad, Iraq. E-mail: [zaidattar@kmc.uobaghdad.edu.iq](mailto:zaidattar@kmc.uobaghdad.edu.iq)

**Received:** 25-Mar-2019; **Revised:** 27-May-2019;  
**Accepted:** 28-May-2019; **Online first:** 12-Jun-2019

**Copyright:** © 2019 Faruk H. Al-Jawad, Zaid Al-Attar, Muayyad S. Abbood. This is an open-access article distributed under the terms of the Creative Commons Attribution-NonCommercial 4.0 International License (CC BY-NC 4.0)

**Funding:** This research did not receive any financial support

**Competing Interests:** The authors have declared that no competing interests exist

**OBJECTIVE:** The current study was designed to determine the hepatoprotective effect of well-known drugs. Nitroglycerin, N-acetyl cysteine and Metoprolol in acute liver injury induced by CCL4. The antioxidant effects of b-blockers, especially carvedilol, have been described by several investigators. However, for metoprolol, the effect is a bit query as there is only one in-vitro study showing a little hepatoprotective effect. Thus, it is worthy to re-study the hepatoprotective effect of metoprolol.

**AIM:** To explore the possible hepatoprotective effect of Nitroglycerin, N-acetyl cysteine and Metoprolol Tartrate

**MATERIAL AND METHODS:** The normal serum values of ALP, AST, ALT, TSB and TSP were determined in 35 healthy rabbits allocated to 5 groups before CCL4 induction and at three occasions 24, 72, 120 hrs after induction by CCL4 and treatment with the tested drugs: Nitroglycerin, N-acetyl cysteine and Metoprolol for five successive days.

**RESULTS:** Showed significant decrease in serum levels of ALP, AST, ALT and TSB with a significant increase in TSP level of all the tested drugs measured at 120 hrs compared with the control and their levels measured at 24, 72 hrs.

**CONCLUSION:** All the tested drugs proved in having a hepatoprotective effect when they are given orally to animals. The histopathological sections of the liver tissue supported the real effect of these drugs in the management of ALI.

## Introduction

Acute liver injury (ALI), is a clinical state that results from severe and extensive damage of liver tissue with reduced cell mass and blood flow. It is associated with an increase in serum alanine aminotransferase (ALT), aspartate aminotransferase (AST), alkaline phosphatase (ALP), and total serum bilirubin (TSB) [1], [2], [3].

It is a serious condition caused by different agents toxins, drug intoxication, and other factors [4], [5]. It is characterised by rapid deterioration of the liver cells function, resulting in hepatic encephalopathy & coagulopathy in the liver of normal subjects [6].

Carbon tetrachloride (CCL4), is a famous hepatotoxic agent that used orally or intraperitoneally

in animals (especially in rodents) for the induction of ALI due to the formation of free radicals mediated lipid peroxidation [7].

Carbon tetrachloride (CCL4) is a well-known hepato-toxicant via causing oxidative stress-mediated liver injury and has a similar mechanism in animals and humans [8].

CCL4 toxicity results from its bioactivation to the highly toxic reactive trichloromethyl peroxy radical that subsequently attack the polyunsaturated fatty acids of cell membranes to propagate a chain reaction resulting in peroxidative decomposition of cytoplasmic membrane lipids [9], leading to progression of liver damage with subsequent hepatocellular carcinoma [10].

A single dose of CCL4 causes centrilobular necrosis and steatosis [11], while prolonged

administration causes liver fibrosis, cirrhosis, and hepatocellular carcinoma [12]. CCL4 affects hepatocytes directly by altering the permeability of the plasma, mitochondrial, and lysosomal membranes. Highly reactive free radicals are also produced by the mixed function oxidase system of CYP2E1 in hepatocytes, causing severe centrilobular necrosis [13], [14]. This model has been used extensively to examine the pathogenesis of cirrhosis. Liver fibrosis is the pathologic result of ongoing chronic inflammatory liver diseases that is characterised by hepatic stellate cell (HSC) proliferation and differentiation to myofibroblast-like cells, which deposit collagen and extracellular matrix [15].

Several familiar drugs had been proved in having hepatoprotective activity against CCL4 induced model of ALI [16]. It is interesting to explore the possible hepatoprotective effect of Nitroglycerin, N-acetyl cysteine and Metoprolol Tartrate in the current study.

## Material and Methods

### Chemicals

All chemicals used are of analytic grades. CCL4 was supplied by Merck-Germany as a pause liquid. Nitroglycerin by Amrit medical center-Syria, N-acetyl cysteine powder from Cimex AG Ltd-Switzerland, Metoprolol tartrate from Al Parma, Barnstaple. The UK. The kits for the estimation of ALP, AST, ALT was purchased from BioMérieux- France while that for TSB & TSP from Randox-England.

### Animals

Thirty-five healthy domestic rabbits weighing 700-800 gm were used in the present study. They were supplied by the animal house of Pharmacy College. Animals were housed in separated cages under good conditions of 28°C with 12 hrs of the light/dark cycle. They were fed standard oxid pellets and were given water ad libitum.

The study was conducted according to the animal ethics committee of Al-Nahrain College of Medicine (approval number: 2016/24156). The rabbits were normally allocated to five groups. They were given a single daily dose of the following drugs for five successive days at 8.00 am.

Group-1: (control), received 3 ml of distilled water orally and without CCL4 administration.

Group-2: (drug control), received 3 ml of distilled water orally.

Group-3: received Nitroglycerin 1 mg/kg orally.

Group-4: received N-acetyl cysteine 275 mg/kg orally.

Group-5: received Metoprolol 7 mg/kg orally.

The doses of Nitroglycerin, N-acetyl cysteine and Metoprolol tartrate had been chosen after many trials in a pilot study.

At 9.00 a.m. on the first day, CCL4 was given to animals of groups 2, 3, 4 and 5 in a dose of 1 mg/kg orally for induction of ALI. Blood samples were collected from marginal ear vein of the rabbits of all groups for biochemical analysis of serum AST, ALT, ALP, TSB and TSP at three occasions, 24, 72, 120 hrs using spectrophotometer method [17] for comparison between the value of these results.

Later on, all the rabbits were sacrificed under light anaesthesia of Diethyl ether (ether) to take specimens of the liver. The histopathological examination was carried out to check the microscopic changes in the liver tissue, using a polarised microscope after fixating the sections in 10% formalin for 48 hrs & staining with hematoxylin & eosin [18].

### Statistical analysis

The obtained results were expressed as means  $\pm$  SEM. The difference among means has been analysed by students t-test using SPSS version 12. P values < 0.05 were considered to be significant.

## Results

Administration of CCL4 to the rabbits in the group -2 produced a marked increase in serum AST, ALT, ALP & TSB levels with a decrease in TSP level compared with normal control (group-1). Both nitroglycerine (group-3) & N-acetylcysteine (group-4) revealed significant reduction in serum ALP, AST, ALT & TSB levels with significant elevation of TSP level when compared with the control (group-2) & their levels at 24, 72, 120 hrs. N-acetyl cysteine (NAC) was more potent than nitroglycerine in improving hepatic function test significantly especially ALT, AST & TSP with values  $30.17 \pm 3.46$ ,  $29.67 \pm 3.51$  and  $30.83 \pm 2.41$  and  $5.03 \pm 0.16$  respectively for nitroglycerin while nitroglycerin was more potent in changing ALP and TSB significantly than NAC with values  $44.45 \pm 3.3$ ,  $11.3 \pm 0.28$  respectively versus  $48.17 \pm 4.05$ ,  $11.6 \pm 0.21$  for NAC respectively measured at 120 hr. Metoprolol showed a significant decrease of AST at different occasions in comparison with the drug control while serum ALT, ALP levels significantly decreased at 24 hr  $p < 0.05$  in comparison with 72, and 120 hr.

**Table-1 Serum levels of ALT, AST, ALP with TSB & TSP of tested drugs: nitroglycerine, NAC, metoprolol tartrate after induction of ALI by CCL4 measured at 24, 72 & 120 hrs**

Group	Dose	Duration (hr)	S. ALT U/L	S. AST U/L	S. ALP U/L	TSB Umol/L	TSP g/dl
Normal control			23.72±0.94	23.38±1.38	49.03±3.23	11.27±0.61	5.58±0.11
CCL4 alone	1ml/Kg	24hr	133.32±2.72a	208.45±3.73a	206.35±3.3a	30.57±1.21a	4.3±0.23a
		72hr	115.12±4.76 b	194.38±5.15 a	204.05±4.25a	26.70±1.57ab	4.60±0.17a
		120hr	97.83±3.97b	146.52±6.15b	189.98±5.21a	20.13±1.56a	4.58±0.16a
Nitro-glycerine	1ml/Kg	24hr	92.17±1.17a	144.17±2.21a	126.83±2.80a	14.38±0.35a	4.45±0.57a
		72hr	78.50±4.02b	108.50±6.84b	44±3.87b	13.38±0.25b	5.03±0.08b
		120hr	40.42±3.10c	30.83±2.41c	44.45±3.30b	11.30±0.28c	5.03±0.16b
N-acetyl cysteine	275mg/kg	24hr	82.17±4.47a	118.17±4.94a	109.17±7.35a	13.73±0.40a	4.85±0.89a
		72hr	65.67±2.62b	84.67±4.41b	62.83±4.05b	11.77±0.30b	5.12±0.79ab
		120hr	30.17±3.46c	29.67±3.51c	48.17±4.05c	11.60±0.31b	5.28±0.13b
Metoprolol tartrate	7mg/kg	24hr	84.76±4.70a	102.53±2.12a	132.78±7.71a	13.62±0.68a	4.70±0.97a
		72hr	64.47±2.90b	93.87±1.83b	105.77±3.48b	12.30±0.38a	4.87±0.72a
		120hr	64.40±2.27b	85.70±2.45c	96.30±4b	11.58±0.49a	4.83±0.13a

Same letters mean non-significant lowering effect at (P> 0.05); -Different letters mean significant lowering effect at (P< 0.05).

Histopathological studies of liver sections supported the results obtained from serum enzymes assays, which demonstrated the normal architecture in rabbits of Group-1 (Figure 1).

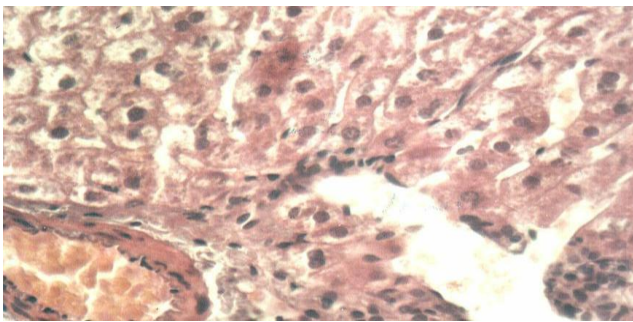


Figure 1: Normal rabbit liver section showing hepatocyte architecture with normal lobular appearance (40X, H&E stain)

Whereas the liver sections of rabbits in group-2 showed a total loss of hepatic architecture with massive fatty changes, intense necrosis, congestion and infiltration of the lymphocytes around the central vein (Figure 2).

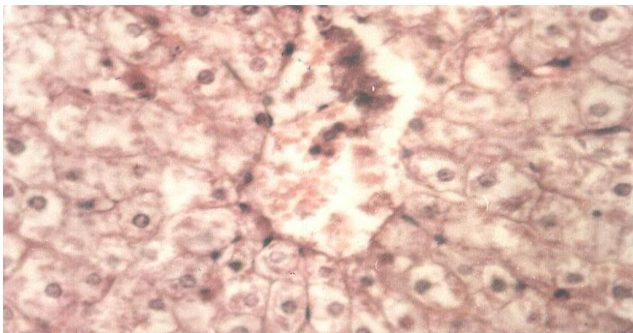
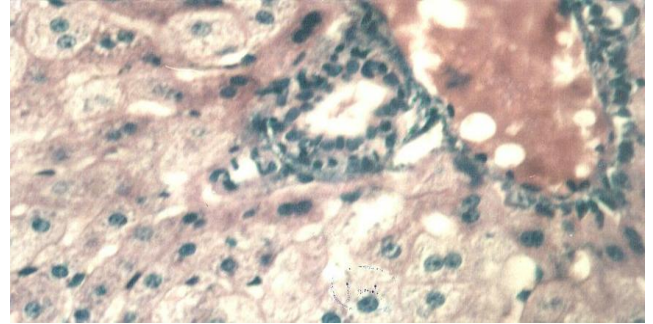


Figure 2: Liver section after administration of CCL4 showing massive necrosis, fatty changes, congestion and lymphocyte infiltration (40X, H&E stain)

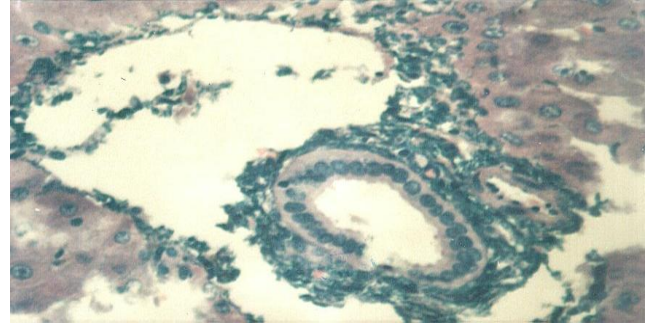
The liver sections in rabbits of Group 3, 4 and 5 showed a more or less normal lobular pattern with a mild degree of congestion, fatty changes and mild lymphocytes infiltration with minimal necrosis or no necrosis indicating the hepatoprotective effect of nitroglycerin NAC & metoprolol tartrate (Figures 3A,

3B, and 3C).

A)



B)



C)

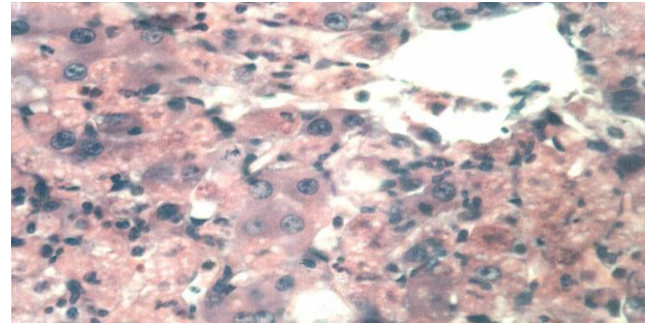


Figure 3: 3A) Liver section after CCL4 and nitroglycerine administration showing mild to moderate fatty changes, congestion & minimal necrosis (40X, H&E stain); 3B) Liver section after CCL4 and N-acetyl cysteine administration showing very minimal fatty changes with congestion and minimal necrosis (40X, H&E stain); 3C) Liver section after CCL4 and metoprolol tartrate administration showing severe fatty changes, mild congestion with multifocal hepatocellular necrosis (40X, H&E stain)

## Discussion

The hepatotoxicity of CCL4 is well known for the induction of ALI in the experimental animal model. CCL4 is biotransformed in the cytochrome P-450 system to its metabolite trichloro-methyl free radical (ccl3) which in the presence of O<sub>2</sub> forms trichloro-methyl-peroxyl free radical (ccl<sub>3</sub>O<sub>2</sub>) that attacks lipid of endoplasmic reticulum, eliciting lipid peroxidation with the leakage of hepatocellular enzymes AST, ALT and ALP in the serum causing a significant increase in

TSB and a decrease in TSP [18]. The results of the drug control (Group-2) in the current study are compatible with the results of others [19], [20] who demonstrated that changes of CCL4 at day one might correspond to liver intoxication then the changes decrease at day four due to the normal physiology of liver regeneration [21].

Administration of nitroglycerin, which is an effective vasodilator drug in the treatment of angina pectoris (Group-3) produced significant positive results in improving ALI induced by CCL4. The results were more evident when given in a dose-dependent manner [22]. Nitroglycerin is a member of organic nitrate with antioxidant activity [23]. It causes the release of nitric oxide (NO), thus the hepatoprotective effect of the drug attributed to the effect of NO inactivation of guanylyl cyclase leading to the synthesis of cAMP (T3) [24]. Nitric oxide proved in having antiapoptotic activity in the hepatocytes. It has been shown in the following study to ameliorate the rise of ALT, AST and improve the histopathological changes that were induced by CCL4 administration [25], [26].

N-acetyl cysteine (NAC) is a mucolytic agent that reduces the viscosity of secretions & used in paracetamol poisoning (Group-4) [27]. NAC has an antioxidant and anti-inflammatory effect [28] when used in vivo & in vitro. It is a source of sulfhydryl group that indirectly increase GSH supply for glutathione peroxidase & directly reacts with reactive oxygen species [29].

The results of NAC in the current study were similar to the results of others [30] who used NAC against liver damage induced by methotrexate causing a decrease in GSH level & superoxide dismutase and catalase activity & increase in malondialdehyde level. Moreover, N-acetyl cysteine has been shown in previous studies to improve the paracetamol and phenacetin induced hepatic and blood, biochemical, and histopathological disturbances. It has an antioxidant and hepatoprotective efficacy against the drug-induced liver injury [31].

Metoprolol tartrate is a selective B1 adrenoceptor blocking drug (Group-5) produces a negative chronotropic & inotropic effect and can lower HDL level used in prophylaxis of hypertension and angina pectoris [32]. The antioxidant effect of metoprolol in vitro has been studied and described previously [1]. The antioxidant properties of metoprolol in vivo are a little bit query as there is only one study showing a little hepatoprotective effect [2]. Many drugs with putative antioxidant effects require high concentration or show antioxidant effects only under in vitro conditions. Thus, the real contribution of the putative antioxidant effects of metoprolol to its efficacy as a hepatoprotective agent was explored in our study. This is a very important issue because this may provide a valuable contribution for the final

healing outcome.

In conclusion, nitroglycerine, N-acetyl cysteine & metoprolol tartrate had proved in having a hepatoprotective effect by increasing the normal hepatic function & enhancing the biodefense of the liver tissue against the oxidative damage produced by CCL4 administration.

## Acknowledgement

The authors would like to acknowledge Al-Nahrain College of Medicine for the provided support.

## References

- Gomes A, Costa D, Lima JL, Fernandes E. Antioxidant activity of beta-blockers: an effect mediated by scavenging reactive oxygen and nitrogen species? *Bioorganic & medicinal chemistry*. 2006; 14(13):4568-77. <https://doi.org/10.1016/j.bmc.2006.02.023> PMID:16510286
- Zubairi M, Ahmed J, Al-Haroon S. Effect of adrenergic blockers, carvedilol, prazosin, metoprolol and combination of prazosin and metoprolol on paracetamol-induced hepatotoxicity in rabbits. *Indian Journal of Pharmacology*. 2014; 46(6):644-8. <https://doi.org/10.4103/0253-7613.144937> PMID:25538338 PMID:PMC4264082
- Sabate M, Ibanez L, Perez E, Vidal X, Buti M, Xiol X, Mas A, Guarner C, Forne M, Sola R, Castellote J. Risk of acute liver injury associated with the use of drugs: a multicentre population survey. *Alimentary pharmacology & therapeutics*. 2007; 25(12):1401-9. <https://doi.org/10.1111/j.1365-2036.2007.03338.x> PMID:17539979
- Al-Attar Z. Characterisation of drug-specific T-cell responses in hypersensitive patients and healthy donors: University of Liverpool; 2016
- Sherlock S, Dooley J. *Diseases of the Liver and Biliary System*: 11th ed. Italy: Blackwell Science, 2002:111-23. <https://doi.org/10.1002/9780470986820>
- Polson J, Lee WM. AASLD position paper: the management of acute liver failure. *Hepatology* (Baltimore, Md). 2005; 41(5):1179-97. <https://doi.org/10.1002/hep.20703> PMID:15841455
- Zhen MC, Wang Q, Huang XH, Cao LQ, Chen XL, Sun K, et al. Green tea polyphenol epigallocatechin-3-gallate inhibits oxidative damage and preventive effects on carbon tetrachloride-induced hepatic fibrosis. *The Journal of nutritional biochemistry*. 2007; 18(12):795-805. <https://doi.org/10.1016/j.inutbio.2006.12.016> PMID:17481882
- Manubolu M, Goodla L, Ravilla S, Thanasekaran J, Dutta P, Malmlof K, et al. Protective effect of *Actinopterygii radiata* (Sw.) Link. against CCl(4) induced oxidative stress in albino rats. *Journal of ethnopharmacology*. 2014; 153(3):744-52. <https://doi.org/10.1016/j.jep.2014.03.040> PMID:24680994
- Plaa GL. Chlorinated methanes and liver injury: highlights of the past 50 years. *Annual review of pharmacology and toxicology*. 2000; 40:42-65. <https://doi.org/10.1146/annurev.pharmtox.40.1.43> PMID:10836127
- Nogueira CW, Borges LP, Souza AC. Oral administration of diphenyl diselenide potentiates hepatotoxicity induced by carbon tetrachloride in rats. *Journal of applied toxicology* : JAT. 2009;

- 29(2):156-64. <https://doi.org/10.1002/jat.1394> PMID:18989868
11. Pierce RA, Glaug MR, Greco RS, Mackenzie JW, Boyd CD, Deak SB. Increased procollagen mRNA levels in carbon tetrachloride-induced liver fibrosis in rats. *The Journal of biological chemistry*. 1987; 262(4):1652-8.
12. Perez Tamayo R. Is cirrhosis of the liver experimentally produced by CCl<sub>4</sub> and adequate model of human cirrhosis? *Hepatology (Baltimore, Md)*. 1983; 3(1):112-20. <https://doi.org/10.1002/hep.1840030118>
13. Shi J, Aisaki K, Ikawa Y, Wake K. Evidence of hepatocyte apoptosis in rat liver after the administration of carbon tetrachloride. *The American journal of pathology*. 1998; 153(2):515-25. [https://doi.org/10.1016/S0002-9440\(10\)65594-0](https://doi.org/10.1016/S0002-9440(10)65594-0)
14. Manibusan MK, Odin M, Eastmond DA. Postulated carbon tetrachloride mode of action: a review. *Journal of environmental science and health Part C, Environmental carcinogenesis & ecotoxicology reviews*. 2007; 25(3):185-209. <https://doi.org/10.1080/10590500701569398> PMID:17763046
15. Fujii T, Fuchs BC, Yamada S, Lauwers GY, Kulu Y, Goodwin JM, et al. Mouse model of carbon tetrachloride induced liver fibrosis: Histopathological changes and expression of CD133 and epidermal growth factor. *BMC Gastroenterol*. 2010; 10:79. <https://doi.org/10.1186/1471-230X-10-79> PMID:20618941 PMCid:PMC2912240
16. Al-Jawad FH, Al-Hussaini J. Hepatoprotective effect of some drugs in experimental model of acute liver injury. *The new Iraqi Journal of Medicine*. 2013; 9(2):62-5.
17. Coral AB, Edward R, Ashood T. *Textbook of Clinical Chemistry 3rd ed*: Saunders company, 1999.
18. Kiernan JA. *Histological & histochemical methods 3rd ed*: Taylor & Francis, 1999.
19. Recknagel RO, Glende EA, Jr., Dolak JA, Waller RL. Mechanisms of carbon tetrachloride toxicity. *Pharmacology & therapeutics*. 1989; 43(1):139-54. [https://doi.org/10.1016/0163-7258\(89\)90050-8](https://doi.org/10.1016/0163-7258(89)90050-8)
20. Taira Z, Yabe K, Hamaguchi Y, Hirayama K, Kishimoto M, Ishida S, et al. Effects of Sho-saiko-to extract and its components, Baicalin, baicalein, glycyrrhizin and glycyrrhetic acid, on pharmacokinetic behavior of salicylamide in carbon tetrachloride intoxicated rats. *Food and chemical toxicology : an international journal published for the British Industrial Biological Research Association*. 2004; 42(5):803-7. <https://doi.org/10.1016/j.fct.2003.12.017> PMID:15046826
21. Rang HP, Dale MN, Ritter JM, Flower RJ, Henderson G. *Rang & Dale's Pharmacology*: Elsevier Health Sciences, 2014.
22. Munzel T, Gori T. Nitrate therapy and nitrate tolerance in patients with coronary artery disease. *Current opinion in pharmacology*. 2013; 13(2):251-9. <https://doi.org/10.1016/j.coph.2012.12.008> PMID:23352691
23. Gewaltig MT, Kojda G. Vasoprotection by nitric oxide: mechanisms and therapeutic potential. *Cardiovascular research*. 2002; 55(2):250-60. [https://doi.org/10.1016/S0008-6363\(02\)00327-9](https://doi.org/10.1016/S0008-6363(02)00327-9)
24. Rockey DC, Shah V. Nitric oxide biology and the liver: Report of an AASLD research workshop. *Hepatology (Baltimore, Md)*. 2004; 39(1):250-7. <https://doi.org/10.1002/hep.20034> PMID:14752845
25. Al-Jawad FH, Abdulsahib WK, Al-Attar Z, Al-Hussaini J. Protective Effect of Cimetidine, Isosorbide Dinitrate & Vitamin C in Experimental Model of Acute Liver Injury. *Scholars Academic Journal of Pharmacy*. 2018; 7(7):308-13.
26. Rahman A, Vasenwala SM, Iqbal M. Hepatoprotective potential of glyceryl trinitrate against chemically induced oxidative stress and hepatic injury in rats. *Human & Experimental Toxicology*. 2016; 36(8):785-94. <https://doi.org/10.1177/0960327116665675> PMID:27758841
27. Reynolds JE. *The extra pharmacopoeia*. Pharmaceutical press; 1993.
28. Sadowska AM, Manuel YKB, De Backer WA. Antioxidant and anti-inflammatory efficacy of NAC in the treatment of COPD: discordant in vitro and in vivo dose-effects: a review. *Pulmonary pharmacology & therapeutics*. 2007; 20(1):9-22. <https://doi.org/10.1016/j.pupt.2005.12.007> PMID:16458553
29. Ocal K, Avlan D, Cinel I, Unlu A, Ozturk C, Yaylak F, et al. The effect of N-acetylcysteine on oxidative stress in intestine and bacterial translocation after thermal injury. *Burns*. 2004; 30(8):778-84. <https://doi.org/10.1016/j.burns.2004.05.006> PMID:15555789
30. Cetinkaya A, Bulbuloglu E, Kurutas EB, Kantarceken B. N-acetylcysteine ameliorates methotrexate-induced oxidative liver damage in rats. *Medical science monitor : international medical journal of experimental and clinical research*. 2006; 12(8):Br274-8.
31. Saleem TH, Abo El-Maali N, Hassan MH, Mohamed NA, Mostafa NA, Abdel-Kahaar E, Tammam AS. Comparative Protective Effects of N-Acetylcysteine, N-Acetyl Methionine, and N-Acetyl Glucosamine against Paracetamol and Phenacetin Therapeutic Doses-Induced Hepatotoxicity in Rats. *International journal of hepatology*. 2018; 2018:8. <https://doi.org/10.1155/2018/7603437> PMID:30245889 PMCid:PMC6139237
32. Benowitz N. Antihypertensive drugs. In: Katzung B, Trevor R, editors. *Basic & Clinical Pharmacology*. 13th ed: McGraw-Hill, 2015:178-86.