

Isolated Bilateral Pinna Swelling: A Rare Initial Presentation of Leprosy

Salma Yasmin Mohd Yusuf^{1*}, Ilham Ameera Ismail¹, Rumihati Abdul Hamid², Nur Adliah Jamil¹, Mazapuspavina Md Yasin¹

¹Primary Care Medicine Discipline, Faculty of Medicine, Universiti Teknologi MARA, 47000 Sungai Buloh, Selangor, Malaysia; ²Putatan Health Clinic, Jalan Pusir Putih, 88200, Putatan, Kota Kinabalu, Sabah, Malaysia

Abstract

Citation: Mohd Yusuf SY, Ismail IA, Abdul Hamid R, Jamil NA, Md Yasin M. Isolated Bilateral Pinna Swelling: A Rare Initial Presentation of Leprosy. Open Access Maced J Med Sci. <https://doi.org/10.3889/oamjms.2019.481>

Keywords: Hepatoprotection; Metoprolol; N-acetyl cysteine; Nitroglycerin

***Correspondence:** Salma Yasmin Mohd Yusuf. Primary Care Medicine Discipline, Faculty of Medicine, Universiti Teknologi MARA, 47000 Sungai Buloh, Selangor, Malaysia. E-mail: salmasoton@yahoo.com

Received: 02-Apr-2019; **Revised:** 22-May-2019; **Accepted:** 23-May-2019; **Online first:** 15-Jun-2019

Copyright: © 2019 Salma Yasmin Mohd Yusuf, Ilham Ameera Ismail, Rumihati Abdul Hamid, Nur Adliah Jamil, Mazapuspavina Md Yasin. This is an open-access article distributed under the terms of the Creative Commons Attribution-NonCommercial 4.0 International License (CC BY-NC 4.0)

Funding: This research did not receive any financial support

Competing Interests: The authors have declared that no competing interests exist

BACKGROUND: Leprosy or Hansen disease is a chronic infectious disease that causes social stigma due to its deforming bodily appearance and physical disability. It has a wide spectrum of presentation affecting diagnosis.

CASE REPORT: A 21-year-old man who presented with chronic isolated bilateral pinna swelling as a result of leprosy is reported. The bilateral pinna swelling started as multiple shiny papules with an erythematous background and progressively became hyperpigmented and lobular over two years. This rare presentation of leprosy poses initial diagnostic difficulties, leading to misdiagnoses by various health care professionals. Diagnoses ascribed include eczema, insect bite and perichondritis. A suspicion of leprosy was raised when hyperaesthetic hypopigmentation of skin started to appear on the body after two years, with worsening of the pinna swellings. This was confirmed by identification of *Mycobacterium leprae* in slit skin smear test and skin biopsy.

CONCLUSION: Isolated involvement of pinna in a patient without lesions in other body parts is an unusual initial presentation of leprosy. However, leprosy should be kept as a rare differential diagnosis of isolated lesions on the ear in patients not responding to conventional treatment.

Introduction

Leprosy, also known as Hansen disease, is a chronic, infectious disease caused by *Mycobacterium leprae* (*M. leprae*) [1]. Without timely treatment, leprosy leads to disfigurement, paralysed extremities and physical disabilities [2]. Much stigma has been associated with it and colonies of sufferers were isolated on islands and asylums in the effort to prevent the spread of the disease. *M. leprae* transmission occurs from prolonged close contact between susceptible and genetically predisposed individuals and untreated multibacillary patients. The nasal mucosa has been hypothesised as the main entry and exit route of *M. leprae* where the disease is thought to spread via respiratory droplets.

Leprosy has a systemic involvement of the dermatological, neurological and rheumatological systems [3]. Due to its systemic manifestations, it is difficult to differentiate leprosy from other systemic

diseases. Incubation period also varies from 6 months to 20 years. Hence it is not uncommon for leprosy to be misdiagnosed, resulting in patients receiving late treatment [1]. The patient in this case report was subjected to repeated consultations to the healthcare professionals before a diagnosis could be established due to the unique presentation.

Up to date literature search using Pubmed/Medline, Cinahl database and Google Scholar using Mesh terms "Leprosy" [Mesh] OR "Leprosy, Multibacillary" [Mesh] OR "Leprosy, Paucibacillary" [Mesh] OR "Leprosy, Tuberculoid" [Mesh] OR "Leprosy, Lepromatous" [Mesh] OR "Leprosy, Borderline" [Mesh] revealed limited reported cases of isolated pinna swelling as an initial presentation of leprosy. Of these, five cases were of unilateral pinna involvement [3], [4], [5]. There was only one reported case of isolated bilateral pinna involvement [6].

Case Report

A 21-year-old male patient from Malaysia, with no significant past medical history, presented with complaint of painless erythematous bilateral pinna skin lesions for two weeks. He had no history of contact to any irritant or trauma and has no other skin lesions elsewhere. He was afebrile at the time of presentation and had a normal pulse rate and blood pressure. Dermatologic examination revealed erythematous and skin-coloured subcutaneous papules on both his pinna, which were painless (Figure 1). There were no other skin lesions or areas of paraesthesia on the body. Cardiovascular, respiratory and other system examinations were also normal. He was diagnosed to have infective perichondritis and received a course of broad-spectrum antibiotics, without any relief.

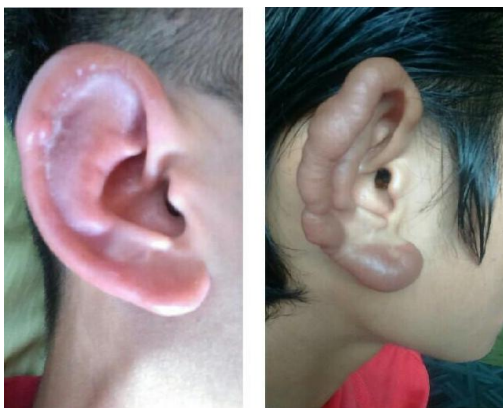

Figure 1: Left – initial presentation. Right – after 2 years

Over two years, he was seen by a few physicians, and progressive enlargement of the pinna swelling triggered a referral to the otolaryngologist who suggested for cosmetic surgery due to the chondral deformities or “cauliflower ear”. However, the patient did not go for cosmetic treatment. It was not until he presented again at the end of the two years to the local health clinic, with new areas of hyperaesthetic hypopigmentation over his chest and arm combined with progressive loss of sensation in the pinna area that leprosy was suspected and diagnosed.

Slit skin smear tests of his pinna, chest, palms and elbows were done, which confirmed the presence of acid-fast bacilli (AFB) of *M. leprae*. The slit skin smear showed high bacteriological index (Figure 2). Microscopy examination of the skin biopsy specimen reveals epidermis with spongiosis, hyperkeratosis and hypergranulosis. Sheets of histiocytes were seen within the dermis with the presence of Grenz zone. Some of the histiocytes were distended with large groups of leprosy bacilli (globe), highlighted by wide fire stain. Perivascular lymphohistiocytic infiltrates were also observed. These changes were consistent with lepromatous leprosy.

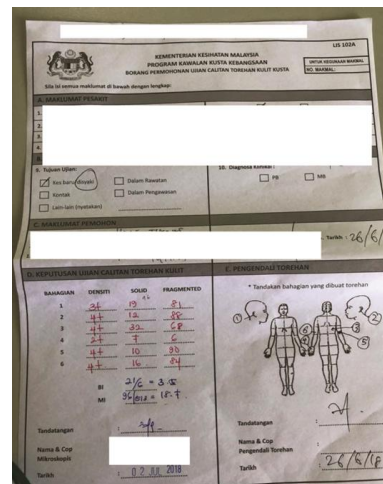


Figure 2: Patient's slit skin smear reading

With the confirmation of diagnosis, the patient was treated with multi-drug therapy consisting of Rifampicin 600 mg, Clofazimine 300 mg and Dapsone 100 mg. Skin lesion over the chest resolved with gradual resolution of the ear lesions. Persistence of hyperpigmentation of the pinna, however, is a cause for despondency in the patient, warranting counselling.

Discussion

A disease once thought to be on the verge of becoming obsolete following the introduction of multi-drug treatment, leprosy is, unfortunately, still a public health concern in Malaysia and globally. The prevalence varies worldwide, but the resurgence of the incidence, particularly of multibacillary leprosy is a cause for concern [1], [7].

Leprosy has a wide spectrum of disease presentation, classified by Ridley and Jopling into six classes, ranging from tuberculoid pole on one end to the lepromatous pole on the other end [1], [3]. At the tuberculoid pole, the patients have cell-mediated immunity towards *M. leprae*, and elimination of mycobacteria can occur [3]. At the lepromatous pole, there is a lack of effective cell-mediated immunity to *M. leprae*, and thus bacilli proliferate [3]. The WHO classifies leprosy into paucibacillary and multibacillary based on the number of lesions [8]. Paucibacillary is less than 5 lesions, while multibacillary is more than 5 lesions [8].

Leprosy involvement of the ear pinna ranges from discrete nodules with minimal pain to ulceration with a “nibbled” defect [3], [9]. Megalobule of the pinna where the earlobe becomes greatly elongated or appear to wrinkle and hangs loose can also occur [9]. As mentioned, isolated pinna involvement, especially bilateral, without other systemic or cutaneous

manifestation, is very rare.

Other differential diagnoses to pinna swellings include systemic conditions like sarcoidosis, relapsing polychondritis, and otophyma [3]. Perichondritis of the non-infective nature, for example, trauma, insect bites, piercings of the affected ear and leukaemic infiltration also cause similar pinna skin lesions [10]. Otitis externa or furunculosis of the external canal and malignant external otitis are infective causes of perichondritis that must be considered [10].

In conclusion, isolated involvement of pinna in a patient without lesions in other body parts is an unusual initial presentation of leprosy. However, leprosy should be kept as a rare differential diagnosis of perichondritis in patients not responding to conventional treatment.

Timely and proper implementation of treatment will break the chain of transmission and prevent disfigurement or physical disabilities that are responsible for the stigma associated with this disease.

Acknowledgements

We would like to appreciate the cooperation of the patient and Dr Nor Haizura, Pathologist from Hospital Queen Elizabeth, Sabah for the histopathology slides.

References

1. Lastória JC. Etiopathogenic aspects - Part 1. 2014; 89(2):205-18. <https://doi.org/10.1590/abd1806-4841.20142450> PMID:24770495 PMCID:PMC4008049
2. Bauer B, Trautmann A. Pediatric dermatology photoquiz. :863-4.
3. Pruthi P, Munganda H, Bangia A, Rani U, Budhiraja R, Brajpuriya S. Case Report Leprosy with Atypical Skin Lesions Masquerading as Relapsing Polychondritis. 2016; 2016. <https://doi.org/10.1155/2016/7802423> PMID:28116186 PMCID:PMC5220437
4. Ramos-e-silva M, Oliveira MLW, Munhoz-da-fontoura GH. Leprosy: uncommon presentations. 2005; 509-14. <https://doi.org/10.1016/j.clindermatol.2005.01.012> PMID:16179185
5. Bubna AK. Localized Glistening Nodules of the Right Ear: A Rare De novo Occurrence of Histoid Leprosy. 2016; 61(6):193701-4. <https://doi.org/10.4103/0019-5154.193703> PMID:27904201 PMCID:PMC5122298
6. Liddell L, Holcomb M. Dermatologic Look-Alikes Nodules on the ear. (April 2015):65-70.
7. Kwan Z, Pailoor J, Tan LL, Robinson S, Wong S-M, Ismail R. Leprosy-an imported disease. *Lepr Rev.* 2014; 85(3).
8. Gaschignard J, Grant AV, Thuc N Van, Orlova M, Cobat A, Huong NT, et al. Pauci- and Multibacillary Leprosy : Two Distinct, Genetically Neglected Diseases. 2016;1-20. <https://doi.org/10.1371/journal.pntd.0004345> PMID:27219008 PMCID:PMC4878860
9. Ma S, Kovarik C. Erythema and induration on the right ear and maxilla. *Cutis.* 2016 Jul;98(1):26-9.
10. Lucerna A, Espinosa J. Acute atraumatic pinna (auricular) perichondritis. *World J Emerg Med.* 2018; 9(2):2017-8. <https://doi.org/10.5847/wjem.j.1920-8642.2018.02.013> PMID:29576831 PMCID:PMC5847504