

Cranioplasty: A New Perspective

Amr Abdelmonam Abdelaziz Mostafa Elkatatny^{*}, Karim Abdelaziz Eldabaa

Kasr Alainy Medical school, Cairo University, Cairo, Egypt

Abstract

Citation: Mostafa Elkatatny AAA, Eldabaa KA. Cranioplasty: A New Perspective. Open Access Maced J Med Sci. <https://doi.org/10.3889/oamjms.2019.489>

Keywords: Cranioplasty; Skull defect; Head contour

***Correspondence:** Amr Abdelmonam Abdelaziz Mostafa Elkatatny, Kasr Alainy Medical school, Cairo University, Cairo, Egypt. E-mail: amramostafa2013@gmail.com

Received: 21-Apr-2019; **Revised:** 27-May-2019;
Accepted: 28-May-2019; **Online first:** 30-Jun-2019

Copyright: © 2019 Amr Abdelmonam Abdelaziz Mostafa Elkatatny, Karim Abdelaziz Eldabaa. This is an open-access article distributed under the terms of the Creative Commons Attribution-NonCommercial 4.0 International License (CC BY-NC 4.0)

Funding: This research did not receive any financial support

Competing Interests: The authors have declared that no competing interests exist

AIM: This work aims to present the different indication, benefits, possible complications and methods used for fixation of methyl methacrylate in cranioplasty. Also, 50 cases will be presented demonstrating the different aetiologies of the defects, and the different techniques used for fixation of methyl methacrylate in cranioplasty.

METHODS: This investigation included a prospective study to be carried out on 50 patients with cranial defects of different aetiologies, sites and sizes to be operated upon in Cairo University Hospitals starting from August 2016 to April 2017.

RESULTS: The principal aims of cranioplasty in this study are to restore aesthetic contour and to provide cerebral protection. However, it has been noted that a great improvement occurs in cerebral blood flow and cerebral perfusion after cranioplasty.

CONCLUSION: Ball and socket technique appear to be a simple, safe economic and efficient method for fixation of cranioplasty flap. The high incidence of development of postoperative seroma suggests the necessity of-of a subgaleal drain placement for 48 hours.

Introduction

The repair of skull bone defects is known as cranioplasty. Historically, such procedures date as early as BC 3000, where the Incas used gold to cover cranial defects resulting from trauma. There are several techniques for the repair of the cranial vault defects that can be broadly divided according to the graft used into autologous bone cranioplasty and allograft cranioplasty.

Material and Methods

This was a prospective study carried out on 50 patients with cranial defects of different etiologies, sites and sizes to be operated upon in Cairo University Hospitals starting from August 2016 to April 2017.

Methods

Clinical history was taken. The aetiology of the skull defect was determined from the history given by the patient. General and neurological examination was done to all patients. The general examination includes an examination of the defect to determine the site and size of the defect and to detect any signs of inflammation in the overlying skin. Complete neurological assessment of the patients was done with particular emphasis on motor power.

A preoperative CT scan with a bone window was done for all patients to demonstrate the defect and complementary MRI brain to detect any underlying brain pathology. A preoperative and postoperative CT with 3D reconstruction was done when available for patients with sphenoid wing and orbital lesions.

Operative details including surgical technique, operative time and blood loss.

Inclusion Criteria: - Patients with symptomatic supratentorial skull defects more than 1 cm causing cosmetic problems or large defects causing liability to cerebral injury or syndrome of the trephined; - Cases

of different etiologies of vault defects as neoplastic, traumatic, and inflammatory; - Patients older than 3 years.

Exclusion Criteria: - Patients with skull defects less than 1cm in diameter; - Patients with overlying skin defects that couldn't be approximated with primary sutures; - Patients who are not fit for surgery; - Presence of any sign of infection; - Patients younger than 3 years.

Preparation of the patients

The scalp was scrubbed with disinfectant soap. The entire head was shaved immediately before surgery. Prophylactic 3rd generation cephalosporin was given to all patients, active against *Staphylococcus* species because the mesh and acrylic are foreign materials.

Surgical Procedures

After induction of general anaesthesia, the head was positioned according to the site of the defect, with the plane of the defect parallel to the ground. Scalp incision was designed to be outside the defect, behind the hairline, never parallel to previous incisions or scars to avoid ischemic necrosis, and with a broad flap base to accommodate the vascular supply to the flap. Proper sterilisation of the skin using povidone iodine was done. Injection of adrenaline 1:200000 (5 mcg: ml) mixed with 10 ml of 0.5% xylocaine to minimise bleeding from the skin was administered. After injection, the wound was re-sterilised. In case of frontal defects (anterior to the hairline), a bicoronal scalp incision was done.

The methods of repair of the defects were methylmethacrylate alone (ball and socket technique). Methylmethacrylate was reinforced with titanium mesh in some of our patients, or fixed with mini plates, and method of repair was randomly selected.

Ball and socket technique

After obvious bone edges were obtained and watertight closure of any dural openings or tears, several notches were buried in the edge of the surrounding cranium, preserving the inner table (Figure 1).

The notches are designed in a way to be slightly wider at the level of the diploe by manual rotation of the burr used in an angulated clockwise manner when the level of the diploe is reached. This notch shape is necessary for fixation of the cranioplasty flap and to prevent flap extrusion being supported by the part of the outer table left above the drilled diploe.

PMMA flap is designed and applied to the cranial defect preserving the normal cranial contour.

Overflow of PMMA into the notches ensures solid fixation with the surrounding cranium (Figure 2). No mesh, mini plates, wires or sutures are required.

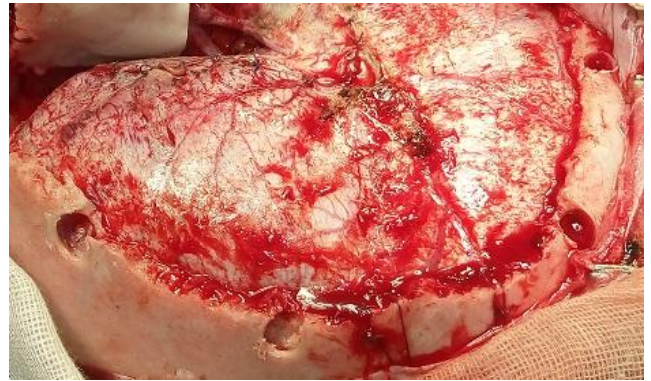

Figure 1: Notches buried in the margins of the surrounding cranium

Twenty-two cases had a posttraumatic defect in the form of compound depressed fracture 12 cases, intracranial bullet following defect 5 cases and orbital fracture 5 cases. Twenty-one cases had tumour invading bone, one case post infectious with osteomyelitis of the bone flap that is removed and repair was done after 6 months, 3 cases had bony lesion in the form of one case with interosseous haemangioma and 2 cases of aneurysmal bone cyst, 2 cases following acute subdural haematoma treated with decompressive craniectomy with bone flap removal and repair was done after 6 month, and 1 case with fits due to extra-axial lesion with bone hyperostosis treated by excision with skull defect after surgery.

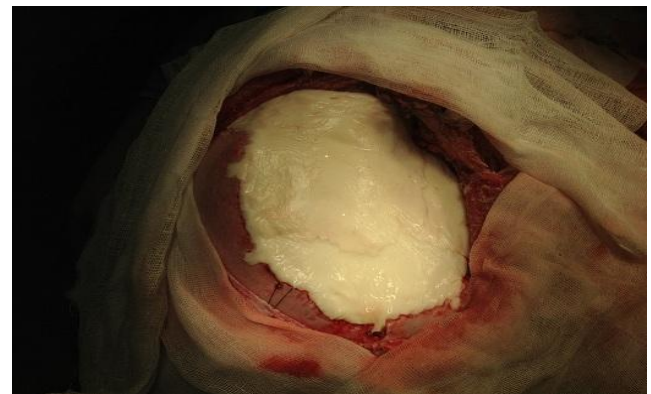

Figure 2: Overflow of PMMA into the notches

Methylmethacrylate was used alone in the repair of the skull defects in 28 of the patients. In these patients, a piece of gel foam and sterile gauze were placed over the dura before placing the methylmethacrylate and moulding it insitu as it was continuously irrigated with saline to protect the brain from the heat produced. The gauze was then removed before fixing the graft in place using ball and socket technique.

In 18 cases, the skull defects were repaired

using methylmethacrylate enforced with titanium mesh, and 4 cases with methylmethacrylate fixed with mini plates (Figure 3).

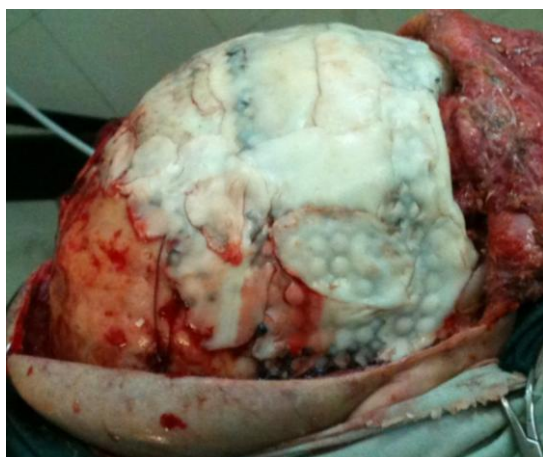

Figure 3: Intraoperative picture of methyl methacrylate graft enforced with a titanium mesh

Four cases are presenting with a growing skull fracture. Intraoperative, the dural tear was found to be larger than the bone defect, so a craniotomy including the defect was done. Neuroplasty was done using a temporalis fascia graft then repair of the defect was done using methylmethacrylate fixed by mini plates.

Postoperative care

Surgical wound care was done using povidone iodine daily for 10 days. All patients received postoperative antibiotics in the form of third generation cephalosporin (ceftriaxone). Stitches were removed for all patients within two weeks from surgery (stitches were done using prolene sutures and in mattress manner). The drain was left for 48 hours following surgery.

Follow-up

Follow-up CT scan was done two days following surgery. Clinical follow up was done for all patients up to 6 months.

Results

This study included 50 patients with skull defects of different aetiologies and sites.

Age and duration of symptoms

Regarding the age distribution of our cases, it ranged between (3 and 60 years), the largest

proportion of cases encountered during 3 rd. A decade of life, twenty cases is constituting 40%. Regarding the duration of symptoms, it ranged from just one month to a maximum of 10 years.

Table 1: Age and duration of symptoms

	mean	Standard deviation	median	minimum	maximum
Age (years)	27.67	18.65	30	3	60
Duration (month)	12.24	16.96	8.5	1	120

Gender distribution

We found that 30 cases were males (60%), and 20 cases were females (40%).

Table 2: Sex of the patients

Sex	Number	Per cent %
Male	30	60%
Female	20	40%

The aetiologies of the skull defects

As shown in Table 3, the aetiology of the skull defect was:

Table 3: Different Etiologies of Cranial Defects

Aetiology	Number of patients	% per cent
Tumour	21	42 %
Infection	1	2 %
Trauma	22	44 %
Fits for 10 years	1	2 %
Bony lesion	3	6 %
Decompressive craniectomy	2	4 %
Total	50	100 %

Twenty-two cases had a posttraumatic defect in the form of compound depressed fracture twelve cases, intracranial bullet following defect five cases and orbital fracture five cases. Twenty-one cases had tumour invading bone (meningioma en plaque), one case post infectious with osteomyelitis of the bone flap that is removed and repair was done after 6 months, three cases had bony lesion one case was interosseous haemangioma, and two cases were aneurysmal bone cyst, two cases following acute subdural haematoma treated with decompressive craniectomy with bone flap removal and repair was done after 6 month, and one case presented with fits due to extra-axial lesion with bone hyperostosis treated by lesion and bone removal.

The sites of the skull defects

As shown in Table 4, 17 cases were with frontal defect due to compound depressed fractures ten cases were on the right side and seven cases were in the left side of which 5 cases with orbital fracture, 21 cases with frontotemporal defect due to meningioma en plaque of which thirteen cases were in the right side and eight cases were in the left side, 10 cases with parietal defect, 7 were in the rt side and 3

were left, and 2 cases with front temporal parietal due to decompressive craniectomy, one in the right side and the other in the left side.

Table 4: Sites of skull effects

Site	Number	Per cent %
Frontal	17	34 %
Parietal	10	20 %
Fronto-Temporal	21	42 %
Fronto tempo parietal	2	4 %

Methods of repair

Twenty-eight cases were done using PMMA by ball and socket technique done, while eighteen patients titanium mesh was used to enforce PMMA and only four cases we used mini plates to fix PMMA cranioplasty flap (Table 5).

Table 5: Methods of repair

Method of repair	Number of patients
PMMA + Ball and socket technique	28
Methylmethacrylate + titanium mesh	18
Methylmethacrylate + mini plates	4
Total	50 patients

Investigations

As regarding investigations 19 cases were diagnosed with MRI pre CT brain pre and post with 3D reconstruction, 20 cases with CT brain pre and post with 3D reconstruction, 9 cases with CT brain pre and post without 3D reconstruction, and 2 cases with MRI pre CT brain pre and post without 3D reconstruction, MRI was used in tumor cases to diagnose soft tissue lesions, and CT 3D was helpful to delineate outline of the flap and to assess in alignment and contour of flap (Table 6).

Table 6. Table of investigations

Investigation	Number	% percent
MRI pre, CT brain pre and post with 3D reconstruction	19	38 %
MRI pre, CT brain pre and post without 3D reconstruction	2	4 %
Ct brain pre and post with 3D reconstruction	20	40 %
Ct brain pre and post without 3D reconstruction	9	18 %

Clinical picture

As regarding clinical picture 17 cases present with skull defect, 10 cases presented with proptosis, One case with visual affection due to meningioma en plaque, 10 cases with just headache, 9 cases with swelling either due to growing skull fracture or due to hyperostosis of bone secondary to intracranial lesion, one case with fits due to presence of an extraxial lesion and bone hyperostosis treated by excision of the lesion and bone, one case with disturbed conscious level due to acute subdural haematoma that was treated by decompressive craniectomy and then cranioplasty to repair defect, and one case with post infectious osteomyelitis following previous brain tumor surgery that was treated by debridement and removal of bone and then repair of the defect after six month (Table 7).

Table 7: Table of the clinical picture

Clinical picture	No.	Per cent
Wound infection and cerebritis	1	2 %
Swelling and visual affection	1	2 %
Swelling	9	18 %
Skull defect	17	34 %
Proptosis	10	20 %
Headache	10	20 %
Fits for 10 years	1	2 %
DCL	1	2 %

Complications

As regarding to the complication three cases with infection, one case with swelling and fever patient treated conservatively by broad spectrum antibiotics (intravenous cefoperazone + sulbactame and amikacin for ten days and oral antibiotics in the form of amoxicillin + clavulanate, ofloxacin for two weeks) and passed without need for intervention, two cases were complicated by wound infection and bone cement exposure following meningioma en plaque surgery and needed removal of PMMA and repeated dressing, antibiotics and then treated by PMMA again after 6 months one patient with collection as reaction to bone cement treated conservatively and the collection is absorbed within two weeks, one patient complicated with skin necrosis due to edge of titanium mesh and patient treated by repeated dressing for about two weeks, four cases complaint of skin irritation (unpleasant sensation) due to the edge of mesh and just reassurance, two cases complicated by mesh broken that need replacement by another one, one case complicated by CSF leak that was treated by lumbar drain and medical treatment (cidamex and Lasix), and one case complicated with fracture of bone cement that was fixed with miniplates as he was a child liable for trauma, and this explains why titanium mesh is better for children and was replaced with titanium mesh (Table 8).

Table 8: Table of complications

Complications	Methods used	Number of patients	% per cent
Swelling (subgaleal collection)	Ball and socket technique	1	2 %
Skin necrosis	Titanium mesh	1	2 %
Skin irritation	Titanium mesh	4	8 %
Mesh broken	Titanium mesh	2	4 %
CSF Leak	Ball and socket technique	1	2 %
Infection	Ball and socket technique	3	6 %
Fracture of MMA	Mini plates	1	2 %

The outcome of the patients

About 45 cases (90%) have good outcome cosmetically and functionally, two cases (4%) needed removal of bone cement, they were meningioma en plaque treated with excision of the tumour, orbit decompression and cranioplasty. Later on, they came back within one month with wound infection and one of them with bone cement exposure. Both were treated by debridement, antibiotics, removal of bone cement and cranioplasty again after six months. Three cases (6%) needed replacement by another

prosthesis. Two cases of titanium mesh were replaced by another because they were broken and one case of a child that was PMMA fixed with mini plates which were broken; hence, it was replaced with titanium mesh (Table 9).

Table 9: Table of outcome

Outcome	Number	Per cent
Replaced by another	3	6 %
Removal of bone	2	4 %
Good	45	90 %

Review of Selected Cases

Case 1: A 43 years old female patient with a history of 11-month protrusion of Lt eyeball, was operated by excision of soft tissue and decompression of the orbit (roof, lat wall and floor of the orbit). And the bone defect was replaced by PMMA (ball and socket technique). There were no neurological deficits present, and pathology revealed meningioma plaque. The drain was removed after two days in the third postoperative day, and there was no collection, the patient received intravenous antibiotic (cefoperazone) for 5 days and discharged on an oral antibiotic (amoxicillin, clavulanate) for ten days, follow up CT with 3D done in the third day post-operative (Figure 4 and 5).

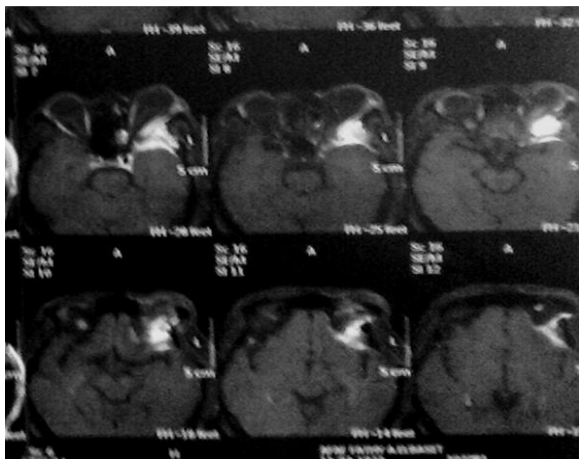


Figure 4: Preoperative MRI of the patient showing Lt sided (meningioma plaque)

There was no evidence of infection, and the patient was discharged on the 5th postoperative day.

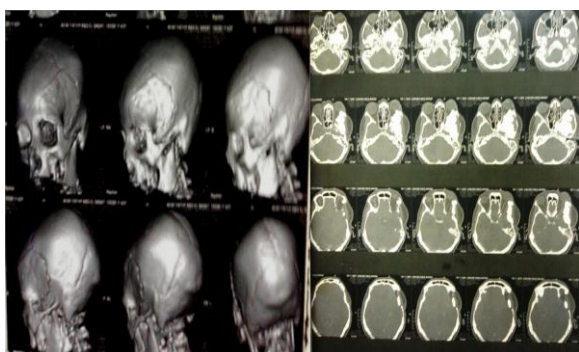


Figure 5: Postoperative CT brain with 3D reconstruction

Case 2: A 40 years old female patient that was complaining of headache for 9 months CT brain and MRI was done showing parasagittal and suprasellar meningiomas, the parasagittal was operated first, the invaded bone was also removed, and the bone defect was repaired using bone cement that was fixated by ball and socket technique. There was no neurological deficit pre and post-operative. The drain was removed in the third post-operative day.

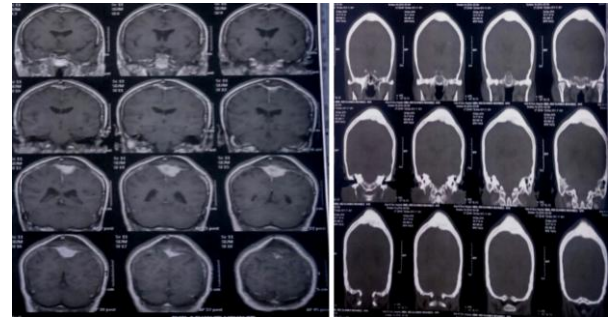


Figure 6: Preoperative MRI and CT bone window of the brain showing parasagittal meningioma

There was no collection and, the patient received an intravenous antibiotic for five days (cefoperazone) and discharged on oral antibiotics (amoxicillin + clavulanate) for one week. CT post was done after removal of the drain (Figure 6 and 7).

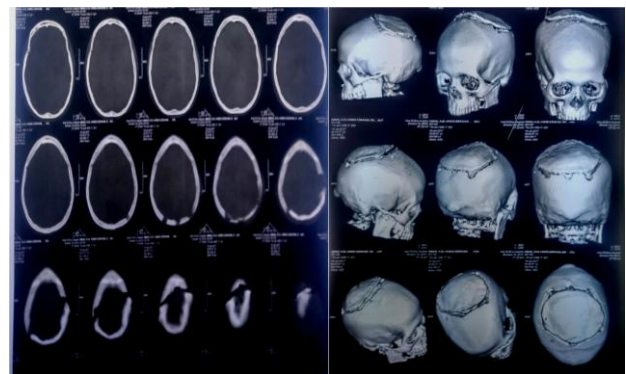


Figure 7: Postoperative CT brain with 3D reconstruction

Case 3: A 10 years old male patient presented in the outpatient clinic with disfigurement and defect in the front orbital region due to the history of trauma 2 years ago when the patient came with a compound depressed fracture.

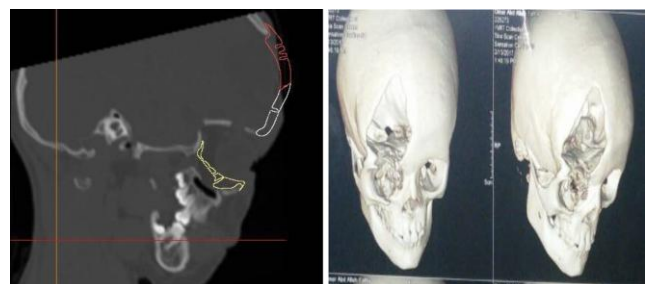

Figure 8: Preoperative CT of the brain showing Orbital defect

Debridement and removal of bone fragments were done, and closure of skin for later cranioplasty CT bone window and 3D reconstruction was done to outline the defect and show the orbit he was operated through biclinal skin incision and reconstruction was done using PMMA that was fixed by ball and socket technique. There was no neurological deficit pre and post-operative. The drain was removed in the third day, and postoperative CT with 3D reconstruction was done. The patient received intravenous antibiotics (cefoperazone) for 5 days then discharged on oral antibiotics (amoxicillin + clavulanate for ten days. The post-operative recovery was smooth and the patient was discharged in the 5th post-operative day (Figure 8 and 9).

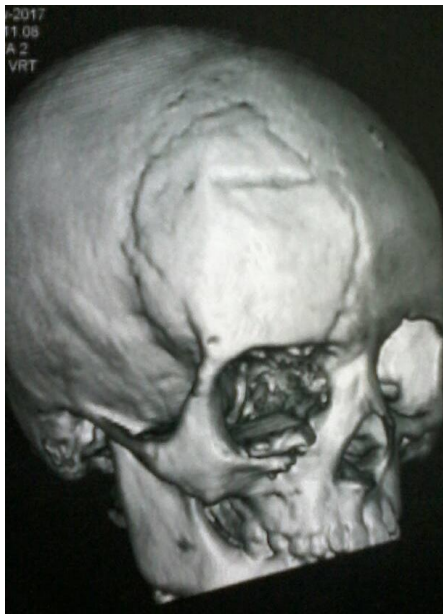


Figure 9: Postoperative CT brain showing repair of fronto orbital defect with PMMA

Case 4: A 43 years old female patient that was complaining of It eye protrusion for 3 months before presentation CT brain and MRI was done showing meningioma en plaque with soft tissue intradural.

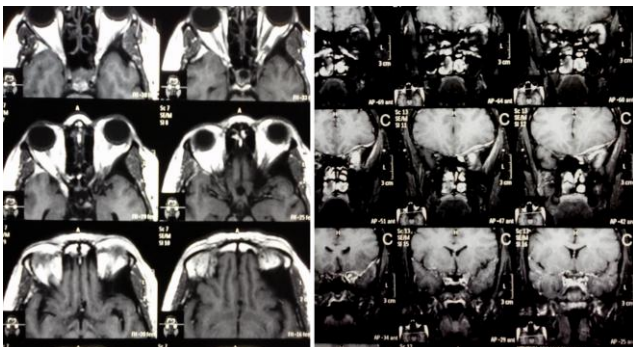


Figure 10: Preoperative MRI showing It sided meningioma en plaque

The patient was ttt by excision of soft tissue

and decompression of the orbit (lat wall, floor and medial wall) then reconstruction of bone defect was done using bone cement that was fixed using ball and socket technique there was no neurological deficit pre and post-operative (Figure 10 and 11).

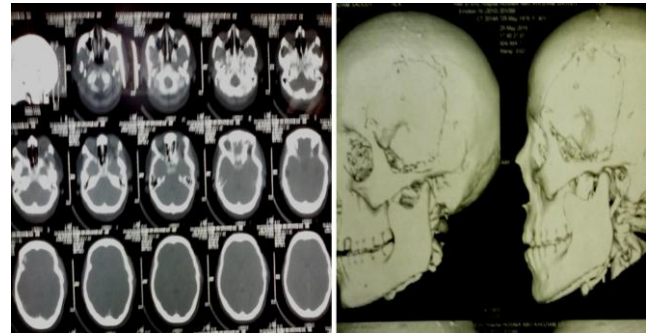


Figure 11: Postoperative CT brain showing excision of tumour and repair of the defect using methyl methacrylate

Case 5: A3-year-old child patient that was presenting with swelling for 6 months CT and MRI brain was done showing growing skull fracture treated by repair of the dural defect and repair of the bony defect by bone cement that was fixed by mini plates a.

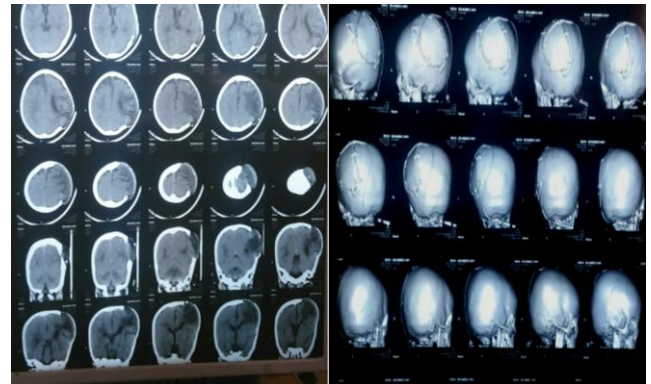


Figure 12: Preoperative CT brain showing growing skull fracture and post-operative ct brain showing repair of the defect by bone cement and mini plates

After 6 months follow up CT brain was done showing a fracture of bone cement that was replaced by titanium mesh (Figure 12 and 13).

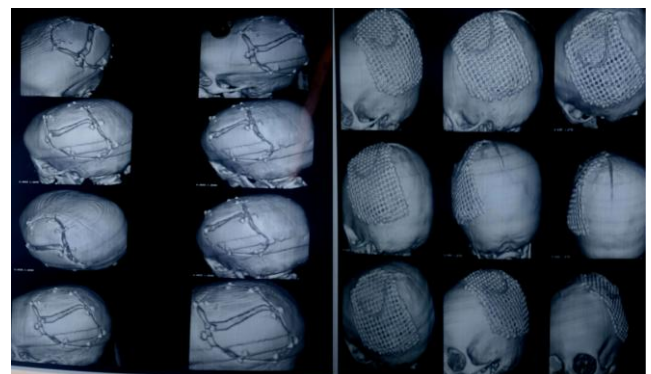


Figure 13: Follow up CT showing fracture of CT brain showing titanium mesh replacing Bone cement

Case 6: A 40-year-old male patient that was complaining of swelling and visual affection in the form of visual acuity 6/36.

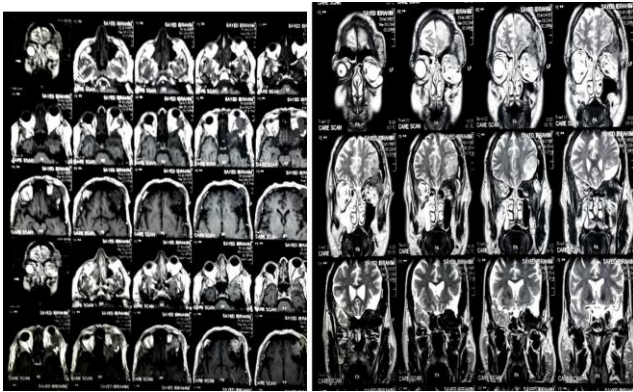


Figure 14: Preoperative MRI showing Ict sphenoid wing meningioma

CT brain and MRI was done showing sphenoid wing meningioma that was treated by surgical excision with removal of invaded dura and its repair by pericranium and removal of invaded bone and its replacement by bone cement fixed by ball and socket technique.

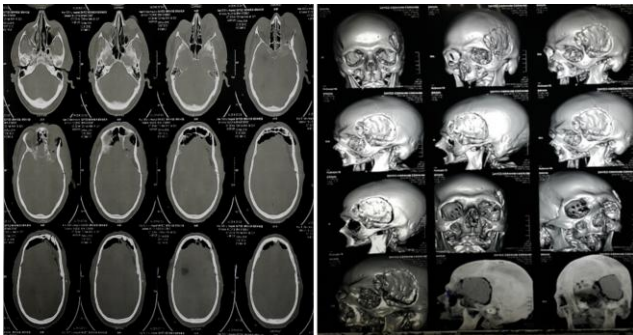


Figure 15: Postoperative CT brain showing tumour excision and replacement of bone by methyl methacrylate using ball and socket technique

The patient did not have any neurological deficits except visual affection (Figure 14, 15, and 16).

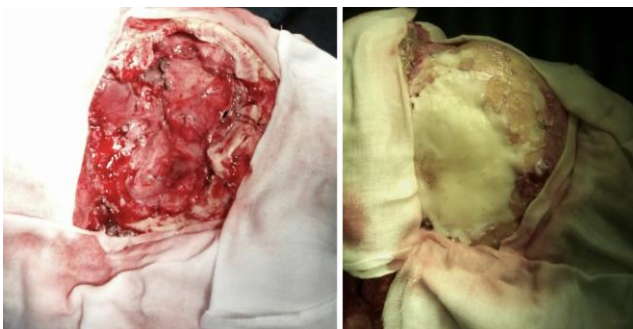

Figure 16: An intraoperative picture showing the details of the ball and socket technique before and after insertion of bone cement

Discussion

The principal values of cranioplasty are to restore aesthetic contour and to provide cerebral protection. Thirty of our patients (60%) were males, and the remaining twenty patients (40%) were females. The male prevalence had also been noted in one study by Andrea Mareira et al., [1] carried out over 312 patients where 54.5% of the patients were males while the remaining 45.5% were females. However, this is purely random as the study was directed towards a surgical procedure used for repair of skull defects caused by a wide variety of pathologies and therefore, we cannot use it to make statistical findings regarding age and gender distribution.

In the study mentioned above by Andrea Mareira et al., [1] listed post-tumour resection to be the most common cause of the defect, it was in 32.4% of the cases. Another study carried out by Alexander VanGool et al., on 45 patients [2] listed trauma as the leading aetiology as was found in 46.7% of their cases.

The most common aetiology of the defect in this study was post-traumatic (44% of the patients) whereas post-tumour resection was the second aetiology of the skull defect in (42%) of our patients.

In the two previously mentioned studies the commonest site was frontal (53.2% of the cases in the study by Andrea Mareira et al., [1] and 46.7% of the cases in the study by Alexander VanGool et al., [2].

The most common site of the skull defect noted in our study was found to be frontotemporal (42%), as related to meningioma en plaque, frontal (34%) related to compound depressed fractures and orbital fractures, parietal (20%) and front tempo parietal (4%) due to acute subdural haematoma treated by decompressive craniectomy.

In our study, the highest number was frontotemporal defect related to meningioma en plaque cases followed by frontal defect related to trauma cases

In the study mentioned above by Alexander VanGool et al., [2], the authors mentioned that 33 of their 45 patients (73.3%) mentioned cerebral protection as their main indication for surgery while only 7 patients (15.6%) mentioned cosmetic appearance as their main concern. The remaining 5 patients (11.1%) presented by both cosmetic problem and cerebral protection for which they sought surgery. In our study, the main indication of surgery was cerebral protection alone in 20 of our 50 patients (40%) and a cosmetic problem in 30 patients (60%).

In our study the main indication for cranioplasty was cosmetic (60%) as most of our patients were either tumour cases or post-traumatic with small disfiguring defects, while in the Alexandre

VanGool et al., the main issue was cerebral protection as most cases were traumatic with large defects.

As in all studies carried out on cranioplasty, the main preoperative imaging done for all patients was a CT-scan with a bone window to show the defect. But in our study, 3-D reconstruction was done for 39 patients (78%) because it is better showing the outline of defects [3].

In the study by Alexander VanGool et al., [2] that included 45 cases, 2 cases were reported to be infected and required flap removal. All cases were operated upon using polymethylmethacrylate for the repair. In another study by Victor Chang et al., [4] involving 212 cases over 13 years, the infection was reported in 15 cases.

Of the 15 cases, 8 (4.6%) out of a total of 175 were operated upon by repair using autologous bone, while 7 cases (18.9%) out of a total of 37 patients, had repaired by other materials as methylmethacrylate or titanium mesh.

We believe that our overall infection rate (6%) is not high compared to most studies. One case with swelling and fever patient treated conservatively by broad-spectrum antibiotics (intravenous cefoperazone and amikacin for ten days and oral antibiotics in the form of amoxicillin + clavulanate, ofloxacin for two weeks) and passed without need for intervention, two cases were complicated by wound infection and bone cement exposure following meningioma en plaque surgery and need removal of PMMA and repeated dressing, antibiotics and then treated by PMMA again after 6 months.

One case was complicated by CSF leak that was treated conservatively by lumbar drain left for three days, and another one complicated by collection treated conservatively.

The three cases that complicated by broken bone cement and titanium mesh required replacement by titanium mesh (one case of bone cement and two cases of titanium mesh), this complication is only reported in our study, and they did not mention it in their study.

A case of cranial defect due to infection reason must not be tackled operatively before complete resolution of the infection. Repair must not be done before at least 6 months. Also, it is important to ensure the application of all aseptic precautions. The use of antibiotic-impregnated methylmethacrylate has proved to be more superior than using one not impregnated with antibiotics that were used in the second case complicated by infection in our study; this issue is not discussed in the above two studies.

Even following perfect hemostasis, a subgaleal drain must be placed and left for 48 hours due to the possibility of developing the subgaleal collection. This observation was also noted in several studies made. In the study by Victor Chang et al., [4]

covering a total of 212 patients, a drain was left in 84 patients and not in the remaining 128. In the 84 patients with a drain, a subgaleal collection was noted in 2 patients only (2.4%), while 11 of the 128 patients (8.6%) without drains developed the subgaleal collection. In the study by Andrea Mareira et al., [1], a seroma was noted in 9 out of 312 cases (7.9%). However, the mentioned study did not correlate the results to the use of a subgaleal drain.

In our study, the subgaleal drain was left for two days routinely, and this was reflected in the number of cases that develop collection (only one case).

The use of titanium mesh has the advantage of being more resistant to fracture especially for large skull defects, and less likely to develop infection when compared to methylmethacrylate and stainless, thus titanium alloy surfaces are thought to minimize bacterial adhesion and thereby lower the rate of infection, recently immediate titanium mesh cranioplasty has been proposed for the treatment of post-craniotomy infection and is widely used in Japan. However, the use of antibiotic-impregnated methylmethacrylate markedly reduces the risk of infection.

Our surgical technique (ball and socket technique) was a meticulous technique regarding hemostasis and watertight dural closure with subgaleal drains in all patients to avoid the possible compromise of the structural integrity of the MMA when exposed to CSF and blood. Methylmethacrylate also has the advantages of being cheaper and more readily available for cases where cranioplasty was not planned (e.g., in intraoperative surprise at finding the bone flap infiltrated with a tumour or in the unfortunate event of the bone flap falling on the floor) [5].

Also, our technique does not need to fixate PMMA with stitches or manipulates, and it is suitable for difficult places as orbital defects that need special contouring and configuration, where titanium mesh is difficult to attain this contour.

In conclusion, the principal aims of cranioplasty in this study are to restore aesthetic contour and to provide cerebral protection. However, it has been noted that a great improvement occurs in cerebral blood flow and cerebral perfusion after cranioplasty, most probably due to the protection from the atmospheric pressure [6].

Thorough history taking and clinical evaluation to determine the cause of the defect when considering cranioplasty. A case of cranial defect due to an inflammatory reason must not be tackled operatively before complete resolution of the infection. Also, in cases where the defect was following a decompressive craniotomy, care must be taken not to perform the cranioplasty before complete normalisation of the intracranial pressure.

Ball and socket technique appears to be a

simple, safe economic and efficient method for fixation of cranioplasty flap. Methylmethacrylate has several advantages when compared to titanium mesh. It's more malleable and therefore easier to place at areas of skull convexities and orbital walls, more easily available in the operating theatre and doesn't have to be prepared in advance. The high incidence of development of postoperative seroma suggests the necessity of a subgaleal drain placement for 48 hours.

References

1. Moreira-Gonzalez A, Jackson IT, Miyawaki T, Barakat K, DiNick V. Clinical outcome in cranioplasty: a critical review in long-term follow-up. *Journal of Craniofacial Surgery*. 2003; 14(2):144-53. <https://doi.org/10.1097/00001665-200303000-00003> PMID:12621283
2. van Gool AV. Preformed polymethylmethacrylate cranioplasties: Report of 45 cases. *Journal of maxillofacial surgery*. 1985; 13:2-8. [https://doi.org/10.1016/S0301-0503\(85\)80005-9](https://doi.org/10.1016/S0301-0503(85)80005-9)
3. Eufinger H, Wehmöller M, Machtens E, Heuser L, Harders A, Kruse D. Reconstruction of craniofacial bone defects with individual alloplastic implants based on CAD/CAM-manipulated CT-data. *Journal of Cranio-Maxillofacial Surgery*. 1995; 23(3):175-81. [https://doi.org/10.1016/S1010-5182\(05\)80007-1](https://doi.org/10.1016/S1010-5182(05)80007-1)
4. Chang V, Hartzfeld P, Langlois M, Mahmood A, Seyfried D. Outcomes of cranial repair after craniectomy. *Journal of neurosurgery*. 2010; 112(5):1120-4. <https://doi.org/10.3171/2009.6.JNS09133> PMID:19612971
5. Jankowitz BT, Kondziolka DS. When the bone flap hits the floor. *Neurosurgery*. 2006; 59(3):585-90. <https://doi.org/10.1227/01.NEU.0000231849.12751.B9> PMID:16955041
6. Winkler PA, Stummer W, Linke R,
7. Krishnan KG, Tasch K. Influence of cranioplasty on postural Blood Flow Regulation, Cerebrovascular Reserve Capacity and Cerebral Glucose Metabolism. *J Neurosurg*. 2000; 93:53-61. <https://doi.org/10.3171/jns.2000.93.1.0053> PMID:10883905