

# Traumatic Dural Venous Sinuses Injury

Amr Abdelmonam Abdelaziz Mostafa Elkatatny<sup>1\*</sup>, Yasser Ahmed Abd Elreheem<sup>2</sup>, Tarek Hamdy<sup>1</sup>

<sup>1</sup>Department of Neurosurgery, Kasr Alainy Medical school, Cairo University, Cairo, Egypt; <sup>2</sup>Beni Suef University, Faculty of Medicine, Beni Suef, Egypt

## Abstract

**Citation:** Mostafa Elkatatny AAA, Abd Elreheem YA, Hamdy T. Traumatic Dural Venous Sinuses Injury. Open Access Maced J Med Sci. 2019 Oct 15; 7(19):3225-3234. https://doi.org/10.3889/oamjms.2019.535

**Keywords:** Traumatic dural; Dural border cell; Injury severity score

**\*Correspondence:** Amr Abdelmonam Abdelaziz Mostafa Elkatatny. Department of Neurosurgery, Kasr Alainy Medical school, Cairo University, Cairo, Egypt. E-mail: amramostafa2013@gmail.com

**Received:** 21-Apr-2019; **Revised:** 25-Jun-2019; **Accepted:** 26-Jun-2019; **Online first:** 15-Aug-2019

**Copyright:** © 2019 Amr Abdelmonam Abdelaziz Mostafa Elkatatny, Yasser Ahmed Abd Elreheem, Tarek Hamdy. This is an open-access article distributed under the terms of the Creative Commons Attribution-NonCommercial 4.0 International License (CC BY-NC 4.0)

**Funding:** This research did not receive any financial support

**Competing Interests:** The authors have declared that no competing interests exist

The traumatic dural venous sinus injury is one of the most dangerous complications of TBI, either due to fatal intracranial compressing venous bleeding, or disturbing the intracranial pressure which could be caused by injury to the SSS

On the other hand, post traumatic dural sinus thrombosis is considered a rare complication which may lead to hemorrhagic infarction with its serious consequences including epilepsy, neurological deficits, or death. Therefore, knowledge of the appropriate treatment of this kind of head injury is essential.

## Introduction

The study was done prospectively in the Neurosurgery Department, Trauma Casualty Unit, Cairo University on patient admitted in the period from August 2013 to March 2014, suffering from traumatic brain injuries associated with dural venous sinus injury.

Forty patients with traumatic brain injuries associated with dural venous sinus injury requiring surgical intervention then followed up clinically and radiologically.

Inclusion criteria were: - All patients with traumatic brain injuries associated with dural venous sinus injury requiring surgical intervention; - No sex predilection and - No age predilection.

Exclusion criteria were: - All patients with traumatic brain injuries not associated with dural venous sinus injury; - Shock (the systolic blood pressure less than 90 mm Hg) for longer than 30 minutes; - Hypoxia [pulse oxygen saturation (SPO<sub>2</sub>) less than 90%] for longer than 30 minutes; - Serious

extracranial injuries; - Bleeding tendency and - Clinical brain death on admission.

## Prehospital Report

The patients were all treated with similar prehospital emergency treatment, and routine brain CT scan was performed (Table 1).

**Table 1: Prehospital emergency treatment and routine brain CT scan**

Mechanism	How did injury occur? Presence of drugs or alcohol. Deaths at the scene. Confounding issues.
Injury	Primary survey. Glasgow Coma Scale.
Vital data	Heart rate. Blood pressure. Respiratory rate. Oxygen saturation. Temperature (if applicable).
Treatment	Airway (airway management). Breathing (oxygen administration, needle or tube thoracostomy). Circulation (intravenous access established and fluids administered) Disability—neurologic (spine precautions). Extra information (medications administered, procedures performed).

## History

Taken from the patient, or his relatives for; age, mechanism of injury, time of trauma, Time of loss of consciousness, presence of lucid interval and pre-hospital post-traumatic fits.

## Clinical Findings

Conscious level (preoperative GCS), presenting symptom, scalp injuries, bleeding orifices, pupils and associated injuries (spine, cardiothoracic, orthopaedic ...etc).

## Radiological Findings

A) All patients underwent CT imaging with bone window to determine the type of intracranial injury (EDH, ICH, ASDH or compound depressed fracture) before a decision was made about the surgical procedure.

B) Imaging for associated injuries, (spine, cardiothoracic, orthopaedic, ...etc).

## Surgical procedures

In our study 10 cases (50%) the bleeding is controlled by direct compression by gel foam (gelatin compressed sponge), which is absorbable haemostatic material for few minutes, 5 cases (25%) the bleeding is controlled by direct application of gel foam on the sinus injury followed by stitching the dura up to the adjacent bone, 4 cases (20%) the bleeding is controlled by direct stitching the dural tear followed by gel foam compression and 1 case (5%) the bleeding is controlled by free muscle duroplasty. In some cases (not faced in the study) there is severe sinus injury with hemorrhage is out of control, ligation can be performed in non-critical areas (in the first quarter of the superior sagittal sinus). A temporary sinus-sinus shunt may be necessary to repair the sinus tear without compromising sinus blood flow properly, but we did not face that in our study. Blood transfusion is required in such cases.

## Postoperative care

The conscious level will be assessed frequently using the Glasgow coma scale.

Follow up CT brain within 24 hours after surgery. MRV may be needed if there are manifestations of increased ICP, or venous infarction in follow up CT.

## The following will be assessed

A) Clinical improvement of symptoms.

Table 2: Master table

No.	Sex	Age (year)	Mode of trauma	GCS	Associated	Image Preoperative	Sinus injury	Operative technique	Image Postoperative	Complications	Other surgery
1	F	2	Falling from height	15	-	LT frontal CD# crossing midline	Anterior part of SSS	Direct gel foam compression	Good	No	No
2	M	25	Blunt trauma	15	-	LT frontal CD# reaching midline	Anterior part of SSS	Direct gel foam compression	Good	No	No
3	M	42	Blunt trauma	15	-	RT frontal CD# reaching midline	Anterior part of SSS	Direct gel foam compression	Good	No	No
4	F	55	Road traffic accident	5	# ribs and haemothorax	LT parieto occipital CD#, massive brain edema, massive brain hypo perfusion	Left TS	Direct stitching of the tear with gel foam compression	Good control of sinus bleeding + Multiple brain infarctions	Multiple brain infarctions	No
5	M	29	Blunt trauma	9	-		Middle part of SSS	Stitching the dura up after application of gel foam on the tear	Good evacuation of the hematoma, Collection of EDH on contra lateral side	Collection of EDH on contra lateral side	Evacuation of hematoma
6	M	14	Trauma by sharp object	14	-	Occipital D#, bilateral occipital contusions	Posterior part of SSS, TS	Stitching the dura up after application of gel foam on the tear	Good control of sinus bleeding	Intra operative bleeding → 3 unites blood transfusion	No
7	M	80	Falling from height	7	# long bones	ASDH	Middle part of SSS	Direct gel foam compression	Massive ICH	ICH	Yes
8	M	19	Road traffic accident	15	-	RT parieto occipital CD# reaching sub occipital region	RT sigmoid sinus	Direct gel foam compression	Good control of sinus bleeding	No	No
9	M	25	Blunt trauma	7	-	LT fronto-temporo-parietal EDH	Middle part of SSS	Direct stitching of the tear with gel foam compression	Good evacuation of the hematoma, Collection of EDH on contra lateral side + Small RT parietal hemorrhagic infarction	=Collection of EDH on contra lateral side =Intra operative bleeding → 3 unites blood transfusion =Post traumatic transverse sinus thrombosis	Evacuation of hematoma
10	F	3	Blunt trauma	15	-	RT frontal CD# crossing midline, underlying EDH	Middle part of SSS	Direct gel foam compression	Good evacuation of the hematoma	No	No
11	M	23	Road traffic accident	14	-	LT temporal EDH, frontal air sinus #	Anterior part of SSS	Direct gel foam compression + frontal air sinus repair	Good evacuation of the hematoma	NO	NO
12	M	35	Trauma by sharp object	5	-	LT high parietal CD#, underlying ICH	Middle part of SSS	Direct stitching of the tear with gel foam compression	Good evacuation of the hematoma	NO	NO
13	M	25	Road traffic accident	9	-	LT prieto-occipital EDH reaching sub occipital region	LT TS	Free muscle duroplasty	=Good evacuation of the hematoma	=Complete obstruction of LT TS → Hemorrhagic infarctions → RT hemi paresis grade 3, Intra operative bleeding → 3 unites blood transfusion	NO
14	M	25	Blunt trauma	15	-	LT high parietal EDH	Middle part of SSS	Direct stitching of the tear with gel foam compression	ICH	=ICH = Intra operative bleeding → 4 unites blood transfusion	NO
15	M	15	Blunt trauma	15	-	RT high parietal CD#	Middle part of SSS	Direct gel foam compression	Good control of sinus bleeding	NO	NO
16	F	20	Road traffic accident	14	Mild pelvic collection	RT frontal EDH	Anterior part of SSS	Stitching the dura up after application of gel foam on the tear	Good evacuation of the hematoma	NO	NO
17	M	42	Blunt trauma	14	-	LT high parietal CD# + underlying EDH	Middle part of SSS	Direct gel foam compression	Good control of sinus bleeding	NO	NO
18	M	8	Blunt trauma	15	-	Mid line frontal CD#	Anterior part of SSS	Direct gel foam compression	Good control of sinus bleeding	NO	NO
19	M	47	Falling from height	5	# long bones	ASDH	Middle part of SSS	Stitching the dura up after application of gel foam on the tear	Good control of sinus bleeding	Intra operative bleeding → 4 unites blood transfusion	NO
20	M	4	Falling from height	15	-	LT parieto-occipital CD#	LT TS	Stitching the dura up after application of gel foam on the tear	Good control of sinus bleeding	NO	NO

M: Male; F: Female; LT: Left; RT: Right; CD#: Compound depressed fracture; EDH: Extra dural hematoma; ASDH: Acute sub dural hematoma; ICH: Intra cerebral hematoma; SSS: Superior sagittal sinus; TS: Transverse sinus.

B) The rate of complications.

C) The need for subsequent lines of management.

D) Wound healing.

E) The outcome was graded using the Glasgow Outcome Score (GOS), which defines.

1. Grade I as death,

2. Grade II as persistent vegetative state,

3. Grade III as severe disability (being conscious but disabled),

4. Grade IV as moderate disability (being disabled but independent), and

5. Grade V as good recovery.

## Case Presentation

### Case 1

The patient was operated upon by elevation of the depressed bone, carefully evacuation of EDH. There was bleeding from 2 small lacerations of the middle part of SSS, which was controlled by the direct application of gel foam on the lacerations with gentle compression for a few minutes (Figure 1).

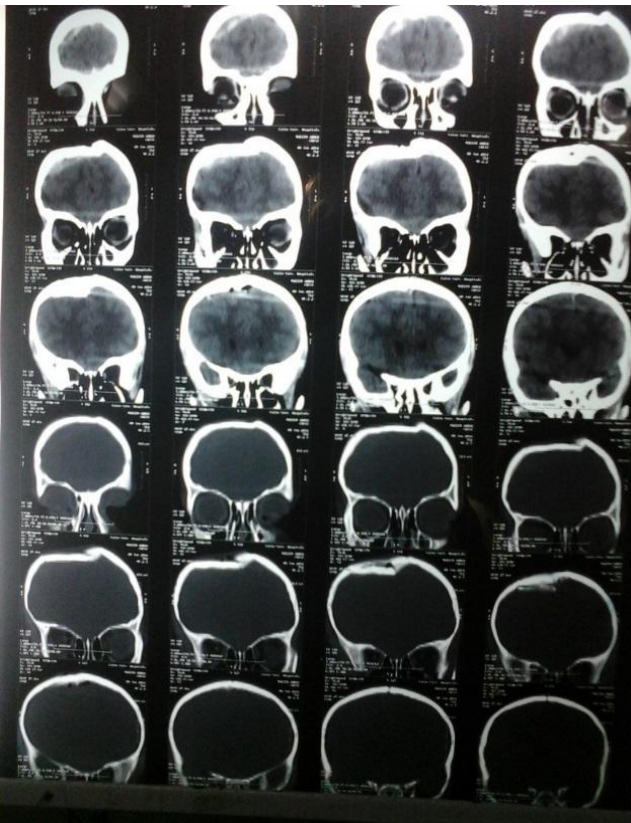


Figure 1: Pre-operative CT of Case 1

Postoperatively patient had the same GCS15/15, and there is no neurological deficit (Figure 2).

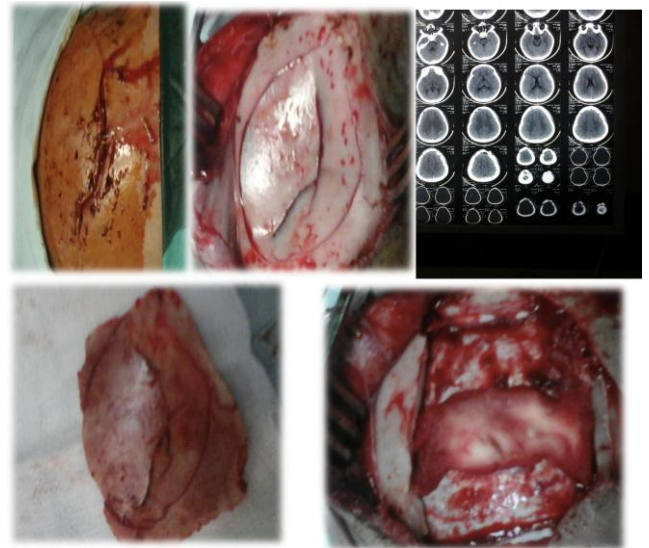


Figure 2: Postoperative CT of Case 1

### Case 2

The patient was operated upon by careful evacuation of EDH. There was severe intraoperative bleeding from large injury of the left transverse sinus, which was controlled by free muscle duroplasty followed by application of gel foam and compression for a few minutes. During the operation, we need a massive blood transfusion, and there was severe brain oedema and the elevated bone cannot be replaced again (Figure 3).

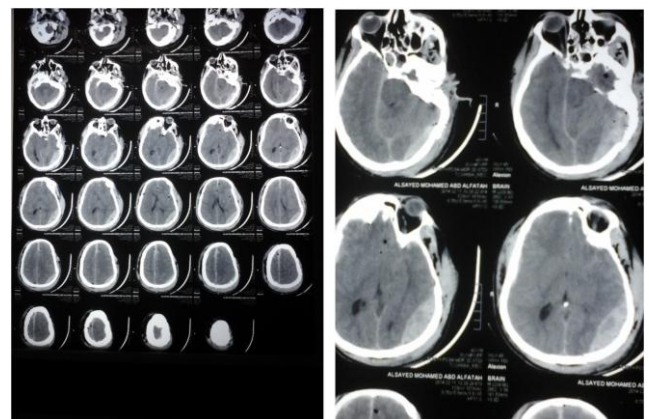


Figure 3: Pre-operative CT brain of Case 2

Postoperatively patient had the same GCS9/15, and there was contralateral hemiparesis motor power and was grade 2.

Postoperative CT scan showed good evacuation of the hematoma, but there were severe brain oedema and multiple hemorrhagic infarctions of left cerebral hemisphere (Figure 4).



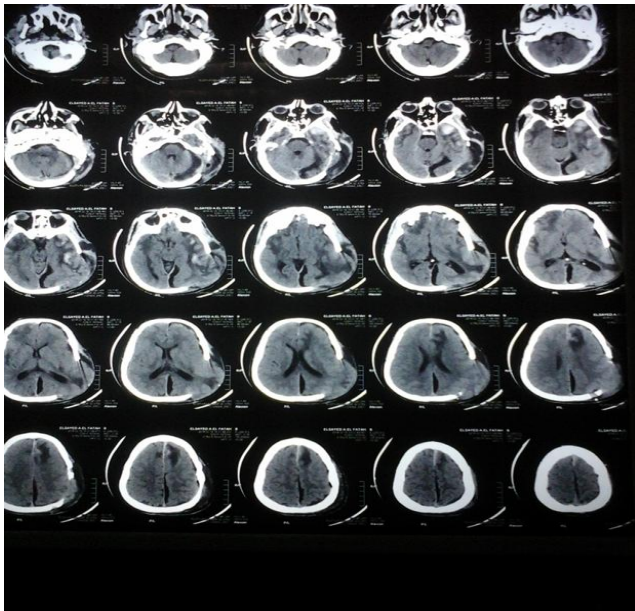


Figure 4: Post-operative CT brain of Case 2

MRV showed complete obstruction of the left transverse sinus (Figure 5).

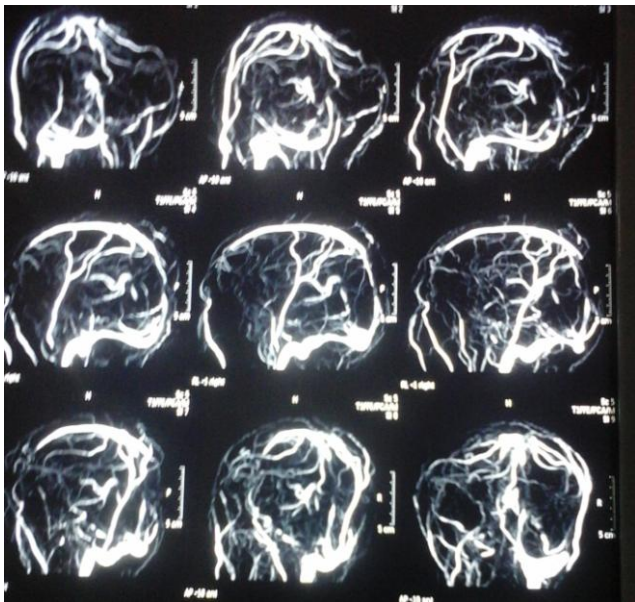


Figure 5: Post-operative MRV of Case 2

The patient gradually improved on dehydrating measures (mannitol 20% and Lasix), clexan (60 unites subcutaneous every 12 hours) and physiotherapy.

After one-week GCS became 14/15 and motor power improved in the right side up to grade 4.

**Case 3**

The patient was operated upon by elevation of the depressed bone, and duroplasty using ipsilateral pericranium. There was bleeding from small

lacerations of the middle part of SSS, which was controlled by putting on the direct haemostatic sheath of gel foam on the lacerations and stitching the dura up (Figure 6).

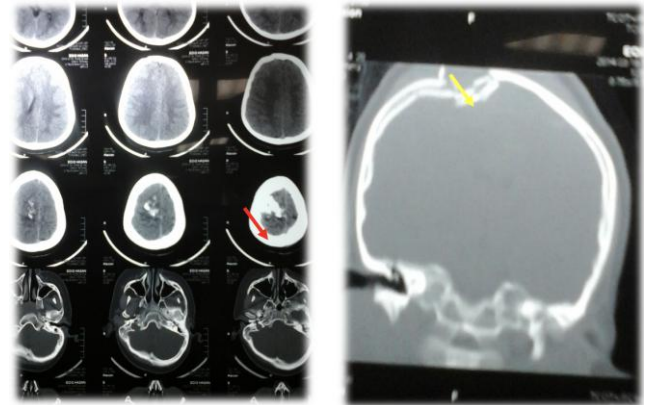


Figure 6: Pre-operative CT of Case 3

Postoperatively patient had the same GCS15/15, and there was an improvement in the motor power (Figure 7).

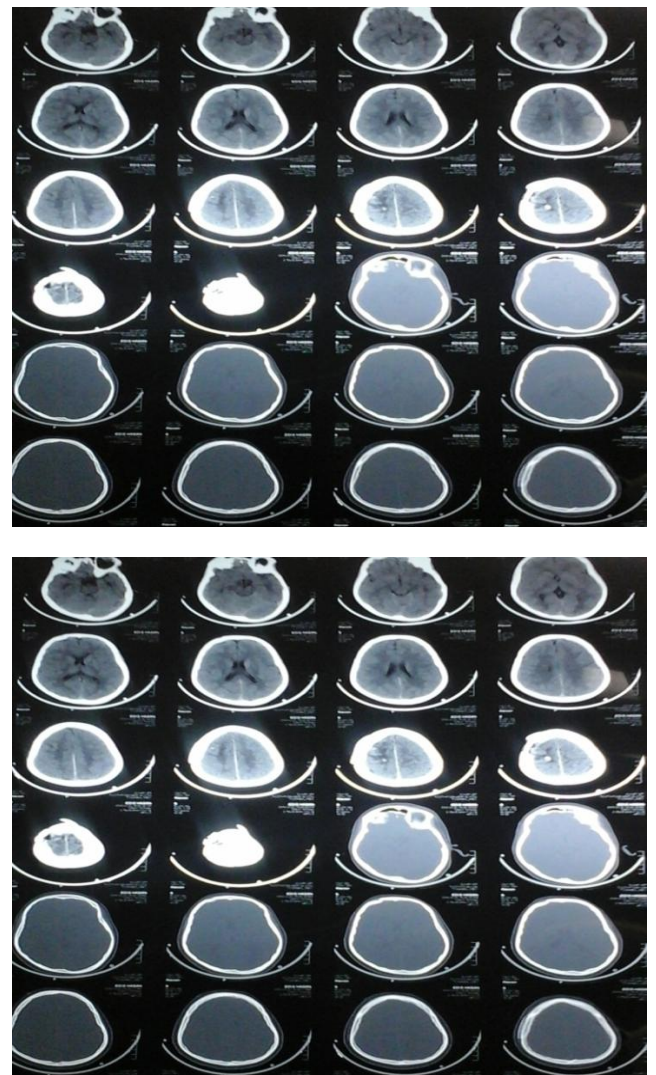


Figure 7: The depressed bone before its elevation (top); Post-operative CT brain of Case 3 (bottom)



## Case 4

The patient was operated upon by careful evacuation of EDH. There was severe intraoperative bleeding from large injury of the middle part of SSS, which was controlled by direct stitching the tear followed by application of gel foam and gentle pressure for a few minutes. During the operation, we need a blood transfusion (Figure 8).

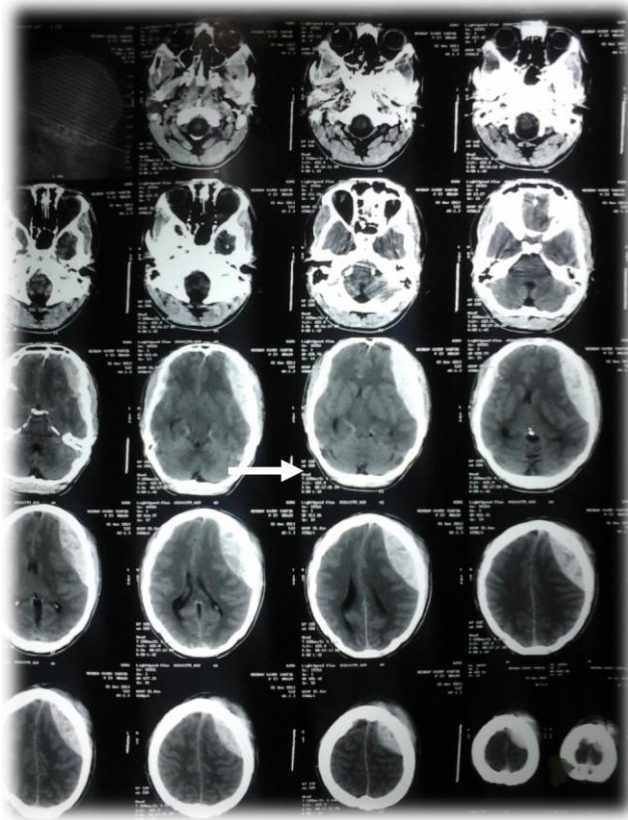


Figure 8: Pre-operative CT brain of Case 4

Postoperatively patient had the same GCS7/15.

Postoperative CT scan showed good evacuation of the hematoma, but there was a collection of EDH on the contralateral side which was evacuated, and there was small right parietal hemorrhagic infarction (Figure 9).

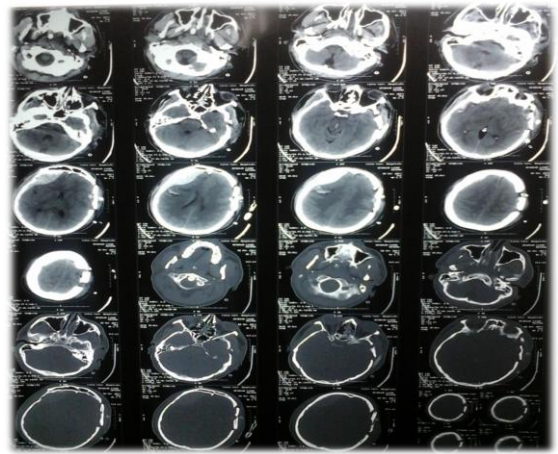


Figure 9: Post-operative CT brain of Case 4 showing RT frontal EDH and hemorrhagic infarction

MRV showed thrombosis of the medial half of the right transverse sinus and attenuated calibre of the middle part of SSS with no evidence of complete occlusion. Anticoagulation was used clexan (60 unites subcutaneous every 12 hours) (Figure 10).

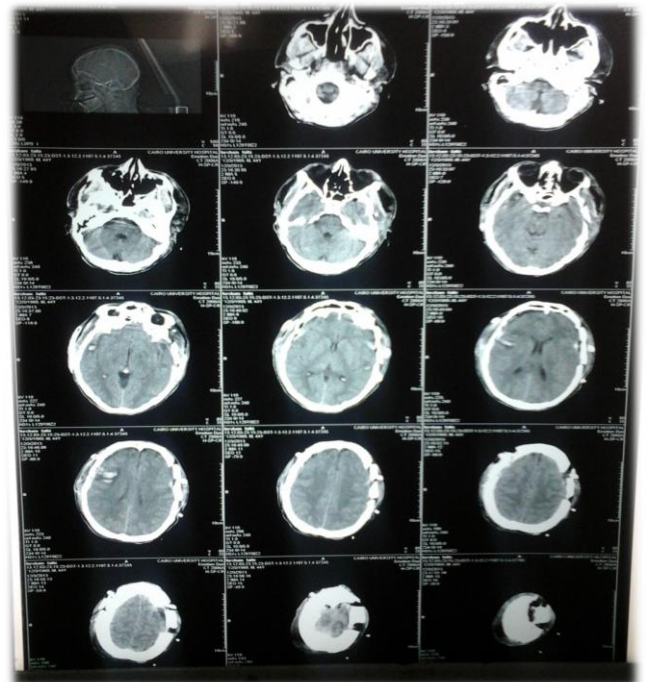


Figure 10: CT brain of case no (4) after the second operation

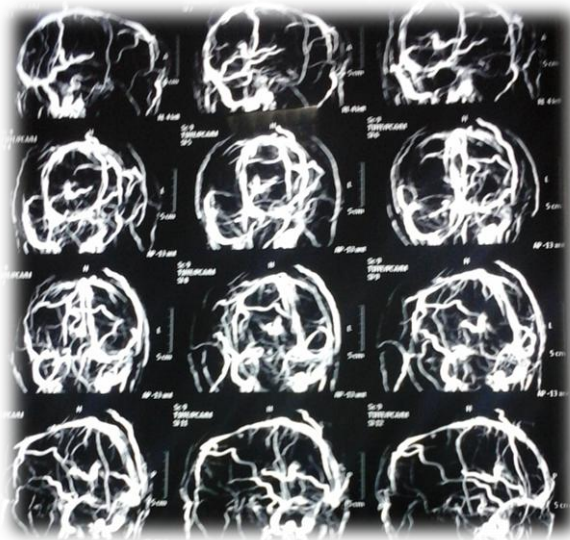


Figure 10: Post-operative MRV

## Results

The data collected from 20 cases of traumatic dural venous sinus injuries in this study were evaluated. The study included 20 patients, 14 males and 6 females. Their age ranges between 2 and 55 years with a mean age of 28.5 years.

### Sex

There were 6 female and 14 males. Male to female ratio was 3:1. Mode of trauma is shown in Fig. 11.

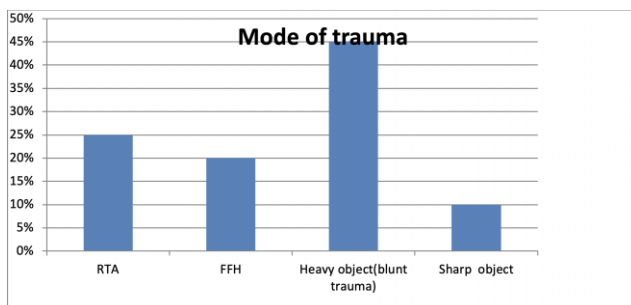


Figure 11: The mode of trauma

### The GCS

Stated in Table 2 are GCS.

Table 2: GCS in the patients

No of patients	GCS	Percent
3	5/15	15%
2	7/15	10%
2	9/15	10%
4	14/15	20%
9	15/15	45%

### The site of sinus injury

Table 3 shows the various dural sinuses injuries according to their localisation.

Table 3: The various dural sinuses injuries according to their localisation

The localisation of sinus injury	No of patients	Percent
Superior sagittal sinus	15	75%
Anterior part		
Middle part	6	
Posterior part	9	
	1 (in combination with TS)	
Transverse sinus	3	15%
Sigmoid sinus	1	5%
Multiple sinuses	1 (TS with the posterior part of SSS)	5%

### The lesions associated with the sinus injury

The associated injuries were present in 20% (4 out of 20 cases) mainly orthopedic fractures of long bones (2 cases) 10%, hemothorax with fracture ribs (1 case) 5% and mild abdominal collection (1 case) 5%. The case with hemothorax and the two cases with fractures of long bones died indicating more severe trauma to the patients.

Table 4 shows different intracranial lesions associated with dural sinus injuries.

Table 4: Different intracranial lesions associated with dural sinus injury

The lesion	No of patients	Percent
CD#	7	35%
EDH	5	25%
ASDH	2	10%
Multiple lesions	6	30%

### The operative techniques used in the treatment of sinus injury

Figure 12 shows different operative techniques used in the treatment of dural sinus injury.

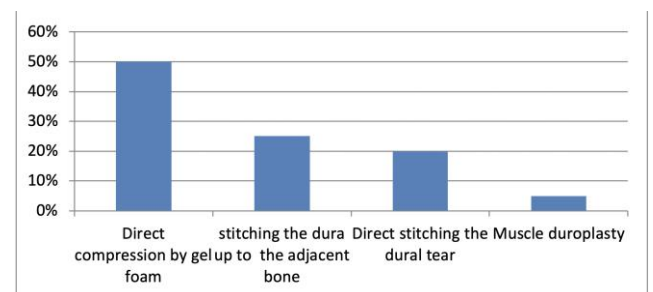


Figure 12: Different operative techniques used in the treatment of dural sinus injury

In this study, 12 cases passed without any complications, either intra-operative or post-operative. Five cases had severe intra-operative bleeding and take blood transfusion, two cases of our study were complicated with extradural collection in the contralateral side which were managed by surgical evacuation, two cases were complicated by intracerebral hematoma one of them was managed conservatively and the other surgically, one case was

complicated with post-traumatic sinus thrombosis and hemorrhagic venous infarction, and one case was complicated with complete transverse sinus occlusion after free muscle duroplasty leading to hemorrhagic venous infarction and contralateral side weakness. As stated in (Table 5 and Table 6).

**Table 5: Complications in the studied group**

Complication	No of patients
No	12
Massive intraoperative bleeding	5
EDH collection on the other side	2
ICH collection	2
Post-traumatic sinus thrombosis	1
Complete transverse sinus occlusion after free muscle duroplasty	1

### **Glasgow outcome scale**

The overall mortality (Grade I) was 15%, (Grades II vegetative) and (grade III severely disabled) were 0%, (Grades IV moderate disability) was 5% and (grade V functional recovery) was 80%. In our study, 3 patients died due to associated intracranial lesions and other coexisting injuries in polytraumatized patients as haemothorax and bone fractures. The remaining 17 patients returned to daily living activity in the follow up period. In all patients the outcome was dependant on the primary and secondary brain injury and coexisting injuries in polytraumatized patients.

**Table 6: Need for further surgical intervention**

Further surgical intervention	No of patients
No	17
Yes	3

## **Discussion**

Traumatic brain injury (TBI) is frequently encountered in the emergency department, and one of the most common causes of morbidity and mortality in developing countries. The traumatic dural venous sinus injury is one of the most dangerous complications of TBI, with its incidence to be raised to 4-12% of all TBI, with a reported mortality rate of 41% [1].

To understand the leading causes of the dangerous complications of traumatic dural venous sinus injury, we reviewed the literature and published papers which were concerned with the previous. So, we realised that either fatal intracranial compressing venous bleeding, or disturbing the intracranial pressure, which could be caused by injury to the SSS [2]. It is believed that cerebrospinal fluid (CSF) drains through the arachnoid granulations into the superior sagittal sinus [3].

The hematoma due to sinus bleeding may compress the SSS leading to impairment of cerebral venous drainage, so the absorption of cerebrospinal

fluid is impaired, which may lead to the presence of venous blood hypertension and hydrocephalus leading to increasing intracranial pressure with restricted cerebral blood supply then occur, upon that, patients may be presented with clinical picture of increased intracranial pressure. If intracranial hypertension develops, it can induce uncal herniation and reflex brady-cardia, which may then result in sudden death. On the other hand, post traumatic dural sinus thrombosis is considered a rare complication which may lead to hemorrhagic infarction with its serious consequences including epilepsy, neurological deficits, or death [4].

The common causes of intracranial dural venous sinus thrombosis include head and neck infections, pregnancy and puerperium, use of oral contraceptives, and dehydration [5]. Following head injury, skull fractures or intracranial hematomas can cause thrombosis either by direct compression of the sinus [6] or by damaging endothelial lining of the sinus wall which will be followed by activation of the coagulation system resulting in sinus occlusion. Uncommonly, sinus thrombosis can occur after mild closed head injury with suture diastasis [5]. Early detection is important as early management with anticoagulation of this potentially treatable condition will result in good outcome, and thrombi in the sinuses frequently recanalize with time due to fibrinolysis [5].

Treating traumatic dural sinus injuries puts a high demand on every neurosurgeon as this kind of injury cannot be diagnosed in all cases pre operatively. Therefore, knowledge of appropriate treatment of this kind of head injury is essential. Recent development in computed tomography (CT) scan in the form of 3D reconstruction is helpful in this scenario as the preoperative knowledge of the anatomical site is essential for proper planning of surgical management of dural sinus injury. Sinus injury should be suspected if preoperative CT shows hematoma overlying venous sinuses, or fractures which crossed the sinus [7].

Follow up MRV should be a good definitive diagnostic tool for those suspected cases especially if the patient starting to have manifestations of increased intracranial pressure or follow up CT showed evidence of venous infarction in the form of hyperdense petechial hemorrhages and hypo dense edema may be seen in the cortical grey matter and sub cortical white matter due to sinus obstruction. The other challenging issue is how to deal properly with the massive bleeding coming from the injured dural venous sinuses during surgically treated head injured patients. So we reviewed The literature that was concerned with the proper dealing with that issue which stated that Small holes or tears of the venous sinus can be managed with either by using absorbable haemostatic materials as Gel foam (gelatin compressed sponge) and Surgicel or fibrillar (oxidized regenerated cellulose), or by gentle pressure with baking with cottonoid bads [8], [9].

Direct closure of tears can be performed if it does not result in sinus stenosis. For larger ruptures, patch repair using a vein graft, per cranium or the fascia lata is required [10], [8].

If the hemorrhage is out of control, ligation can be performed in non-critical areas as in the first quarter of the SSS. A temporary sinus- sinus shunt may be necessary to properly repair the sinus tear without compromising sinus blood flow [11].

There are some respectable technical aspects, as follows, that may greatly facilitate proper management. Before the elevation of the bone fragments, preparations for rapid haemorrhage and air embolism should be in place and an assistant should be ready to manoeuvre the operating — table at a moment's notice [12]. Continuous generous irrigation over the sinus during the elevation of the bone fragments reduces the chance of embolism. Wet swabs should be at hand to immediately cover the sinus. The semi-sitting (lounging) position allows a good venous return without increased intracranial pressure. The operative exposure should be as extensive as possible. The skin flap and craniotomy should extend across the midline to permit visualisation of both sides of the sinus [13].

The bridging veins, especially in the rolandic outflow area, should be preserved [14]. To facilitate venous sinus patency after surgery, blood pressure, volume and viscosity must be carefully monitored.

To supplement knowledge in this field, we describe here the results of 20 patients with traumatic dural venous sinus injury were managed in Cairo University hospitals, in the emergency department.

In our study, male: female ratio was almost (2:1) [14 males and 6 females]. Similarly, other studies reported more incidence of trauma in males. e.g. [15], [16] found that 61.9% of people with TBI were males. Also, Andersson et al., at 2003 [17] concluded that TBI in Sweden males had 1.46 higher rate than females.

In our study we found that 85% of patients were in this age group (15-45 years), similarly, Gan et al., (2004) [18] concluded that the incidence of TBI peak in the younger patients aged 20-40 years.

In our study, the mortality increases with age, the incidence of mortality in patients > 40 years was 50%, while in patients < 40 years was 0%. Similarly, other studies reported that morbidity and mortality increase as age increase, with a mortality rate of 70% in patients older than 40 years [19], [20], [21].

The mechanism of injury had no significant difference in mortality rate. There was no significant difference in the prognosis between males and females in spite of a 3:1 male predominance. Similarly, other studies had the same results [22].

Mohanty et al., 1995 [23] and Kuday, et al., 1994 [24] have reported that lower GCS correlated

with a more unfavourable outcome. In our study, 9 cases have GCS 15/15 45%, 4 cases with GCS 14/15 20%, 2 cases with GCS 9/15 10%, 2 cases with GCS 7/15 10%, and 3 cases with GCS 5/15 15%, and there is mortality rate 75% (3 cases) in patients with GCS under 8/15.

In our study, we found that the SSS is the most common dural sinus injury, the anterior and central parts of the SSS 75% of cases, the transverse sinus injury 15% of cases, the sigmoid sinus injury 5% and combined injuries of different dural sinuses 5%. Similarly, other studies reported that SSS is the most injured sinus and the central part is the most affected e.g. [1], [15], [25].

Meier U et al., 1992 found that 69% of the cases with traumatic dural sinus injury had a closed head injury together with intracranial hematoma as EDH and ASDH, 31% of cases had an open head injury, but the results of our study didn't match with this result, as 65% of the cases with traumatic dural sinus injury had an open head injury while 35% of cases had a closed head injury together with intracranial hematoma as EDH and ASDH. As in our study, we had 7 cases (35%) with compound depressed fracture, 5 cases (25%) with EDH, 2 cases (10%) with ASDH and 6 cases (30%) have multiple cranial lesions, mainly compound depressed fracture associated with other intracranial lesions as, EDH, ICH and brain contusions, and this result correlates with [15], [25]

In our study, 10 cases (50%) the bleeding is controlled by direct compression by gel foam for few minutes, 5 cases (25%) the bleeding is controlled by direct application of gel foam on the sinus injury followed by stitching the dura up. In 4 cases (20%) the bleeding cannot be controlled by direct compression by gel foam only due to larger tears and needed direct closure of tears by sutures followed by gel foam compression. One case (5%) the bleeding is controlled by free muscle flap duroplasty, but during operation after control of sinus bleeding, there was sudden severe brain oedema with herniation of brain through the craniotomy, so we could not replace the bone flap again during the operation. The case was complicated by contralateral hemiparesis. Post-operative CT brain was done revealed hemorrhagic infarction. MRV was done that revealed complete obstruction of the transverse sinus. Anticoagulation and dehydrating measures were used with regular physiotherapy, and there was a gradual improvement. In the study of Ozer FD, et al., 2005 [15] massive blood loss occurred intra operatively could be controlled by digital pressure with gel foam or with a free muscle flap.

In this study, 12 cases passed without any complications, either intraoperative or postoperative. Five cases had severe intraoperative bleeding and take blood transfusion from (2-3 L). Two cases of our study were complicated with delayed extradural



collection in the contralateral side which was managed by surgical evacuation. The cause of this contralateral delayed EDH in our two cases was bleeding from the superior sagittal sinus in one case, and multiple fissure fractures in the other case. We reviewed the literature and published papers which were concerned with delayed EDH; we found that delayed EDH is one which either is not present or is in insignificant amount on initial CT scan but is found in significant quantity on subsequent CT scan. It comprises 9-10% of all EDH [26]. Almost half of them occur after a craniotomy to relieve another hematoma, possibly caused by loss of tamponade effect on the bleeding vessel [27], and are often related to a skull fracture of the overlying bone [28]. Low ICP, high BP, rapid correction of hypotension favours development of delayed EDH. Low ICP can bring about intracranial bleeding by itself without trauma as in cases of extracerebral haemorrhage complicating shunt surgery, ventricular and subarachnoid drainage, spinal anaesthesia, posterior fossa and spinal intradural operations [29].

Two cases were complicated by intracerebral hematoma; one of them was managed conservatively and the other surgically with no any apparent source of bleeding during the operation. One case was complicated with complete transverse sinus occlusion after free muscle duroplasty leading to hemorrhagic venous infarction and contralateral side weakness. One case had post-traumatic sinus thrombosis and hemorrhagic venous infarction without any neurological deficit just headache. Anticoagulation was used, and there was a gradual improvement.

In our study, 3 patients died due to associated intracranial lesions and other coexisting injuries in polytraumatized patients as haemothorax and bone fractures. The remaining 17 patients returned to daily living activity in the follow-up period. In all patients the outcome was dependant on the primary and secondary brain injury and coexisting injuries in polytraumatized patients, and this results nearly similar to the results of the study of Ozer FD, et al., 2005 [15] in which 2 cases died due to associated intracranial lesions, the remaining 15 patients returned to daily living activity in the follow-up period and the clinical success was 88%. In our study, clinical success was 85%.

## References

1. Meier U, Gärtner F, Knopf W, Klötzer R, Wolf O. The traumatic dural sinus injury—a clinical study. *Acta neurochirurgica*. 1992; 119(1-4):91-3. <https://doi.org/10.1007/BF01541788> PMID:1481760
2. Forbes JA, Reig AS, Tomycz LD, Tulipan N. Intracranial hypertension caused by a depressed skull fracture resulting in superior sagittal sinus thrombosis in a pediatric patient: treatment with ventriculoperitoneal shunt insertion. *J Neuro-surg Pediatr*. 2010; 6:23-28. <https://doi.org/10.3171/2010.3.PEDS09441>
3. Fishman RA. *Cerebrospinal Fluid in Diseases of the Nervous System*. WB Saunders company, 1980.
4. De Bruijn SF, Stam J. Randomized, placebo-controlled trial of anticoagulant treatment with low-molecular-weight heparin for cerebral sinus thrombosis. *Stroke*. 1999; 30(3):484-8. <https://doi.org/10.1161/01.STR.30.3.484> PMID:10066840
5. Satoh H, Kumano K, Ogami R, Nishi T, Onda J, Nishimura S, Kurisu K. Sigmoid sinus thrombosis after mild closed head injury in an infant: Diagnosis by Magnetic resonance imaging in the acute phase. *Neurologia medico-chirurgica*. 2000; 40(7):361-5. <https://doi.org/10.2176/nmc.40.361> PMID:10927903
6. Yuen HW, Gan BK, Seow WT, Tan HK. Dural sinus thrombosis after minor head injury in a child. *Annals-Academy of Medicine Singapore*. 2005; 34(10):639-41.
7. Yilmazlar S, Kocaeli H, Dogan S, Abas F, Aksoy K, Korfali E, Doygun M. *Acta Neurochir*. 2005; 147(12):1241-8. <https://doi.org/10.1007/s00701-005-0623-2> PMID:16133767
8. Sindou MP, Alvernia JE. Results of attempted radical tumor removal and venous repair in 100 consecutive meningiomas involving the major dural sinuses. *Journal of neurosurgery*. 2006; 105(4):514-25. <https://doi.org/10.3171/jns.2006.105.4.514> PMID:17044551
9. Malik NK, Makhdoomi R, Indira B, Shankar S, Sastry K. Posterior fossa extradural hematoma: our experience and review of the literature. *Surgical neurology*. 2007; 68(2):155-8. <https://doi.org/10.1016/j.surneu.2006.10.051> PMID:17662347
10. Sani S, Jobe KW, Byrne RW. Successful repair of an intracranial nail-gun injury involving the parietal region and the superior sagittal sinus: Case report. *Journal of neurosurgery*. 2005; 103(3):567-9. <https://doi.org/10.3171/jns.2005.103.3.0567> PMID:16235693
11. Huang SQ. Surgical treatment of intracranial venous sinus injury. A report of 111 cases. *Zhonghua wai ke za zhi [Chinese journal of surgery]*. 1989; 27(3):166-8.
12. Jallo J, Narayan RK. General principles of craniocerebral trauma and traumatic hematomas. *Atlas of Neurosurgical Techniques: Brain*. New York: Thieme. 2006:895-905.
13. Sindou M. Meningiomas Involving the Major Dural Sinuses: Management of the Sinus Invasion. In *Practical Handbook of Neurosurgery*. Springer: Vienna, 2009:669-680. [https://doi.org/10.1007/978-3-211-84820-3\\_41](https://doi.org/10.1007/978-3-211-84820-3_41)
14. Steiger HJ, Reulen HJ, Huber P, Boll J. Radical resection of superior sagittal sinus meningioma with venous interposition graft and reimplantation of the rolandic veins. *Acta neurochirurgica*. 1989; 100(3-4):108-11. <https://doi.org/10.1007/BF01403595> PMID:2589116
15. Ozer FD, Yurt A, Sucu HK, Tektas S. *J Emerg Med*. 2005; 29(2):137-9. <https://doi.org/10.1016/j.jemermed.2005.03.006> PMID:16029821
16. Larking P. *Traumatic brain injury: Analysis of data*. ACC, Wellington. 2004.
17. Andersson, E. H. Bjoorklund, R, Emanuelson, Stalhammar, D. Epidemiology of traumatic brain injury: a population based study in western Sweden. original articles. *Acta Neurologica Scandinavica*. 2003; 71:124-133.
18. Gan BK, Lim JHG, Ng IHB. Outcome of moderate and severe TBI amongst the elderly in Singapore. *Ann Acad Med Singapore*. 2004; 33:36-7.
19. Marshall LF, Gauttillie T, Klauber MR, Eisenberg HM, Jane JA, Luerssen TG, Marmarou A, Foulkes MA. The outcome of severe closed head injury. *Journal of Neurosurgery*. 1991; 75(Supplement):S28-36. <https://doi.org/10.3171/sup.1991.75.1s.0s28>
20. Vollmer DG, Torner JC, Jane JA, Sadovnic B, Charlebois D, Eisenberg HM, Foulkes MA, Marmarou A, Marshall LF. Age and outcome following traumatic coma: why do older patients fare worse?. *Journal of Neurosurgery*. 1991; 75(Supplement):S37-49.

<https://doi.org/10.3171/sup.1991.75.1s.0s37>

21. Howard MA, Gross AS, Dacey RG, Winn HR. Acute subdural hematomas: an age-dependent clinical entity. *Journal of neurosurgery*. 1989; 71(6):858-63. <https://doi.org/10.3171/jns.1989.71.6.0858> PMID:2585078
22. Hong Z, Bai XJ. Influence of operative timing on prognosis of patients with acute subdural hematoma. *Chinese Journal of Traumatology (English Edition)*. 2009; 12(5):296-8.
23. Mohanty A, Kolluri VS, Subbakrishna DK, Satish S, Mouli BC, Das BS. Prognosis of extradural haematomas in children. *Pediatric neurosurgery*. 1995; 23(2):57-63. <https://doi.org/10.1159/000120936> PMID:8555096
24. Kaday C, Uzan M, Hanci M. Statistical analysis of the factors affecting the outcome of extradural haematomas: 115 cases. *Acta neurochirurgica*. 1994; 131(3-4):203-6. <https://doi.org/10.1007/BF01808613> PMID:7754821
25. Lefevre D, Tayler A, Peter K. *Surg Neurol*. 3004; 62(2):121-5;

discussion 125-6. <https://doi.org/10.1016/j.surneu.2003.10.048> PMID:15261501

26. Piepmeier JM, Wagner JF. Delayed post-traumatic extracerebral hematomas. *The Journal of trauma*. 1982; 22(6):455-60. <https://doi.org/10.1097/00005373-198206000-00003> PMID:7086910
27. Di Rocco A, Ellis SJ, Landes C. Delayed epidural hematoma. *Neuroradiology*. 1991; 33:253-254. <https://doi.org/10.1007/BF00588229> PMID:1881545
28. Riesgo P, Piquer J, Botella C, Orozco M, Navarro J, Cabanes J. Delayed extradural hematoma after mild head injury: report of three cases. *Surgical neurology*. 1997; 48(3):226-31. [https://doi.org/10.1016/S0090-3019\(97\)00194-8](https://doi.org/10.1016/S0090-3019(97)00194-8)
29. Alappat JP, Baiju P, Jayakumar K, Sanalkumar P. Delayed extradural hematoma: a case report. *Neurology India*. 2002; 50(3):313-15.